

# DT Journal

**3** 2022

**Journal of Diagnostics and  
Treatment of Oral and  
Maxillofacial Pathology**



Editors  
Oleksii Tymofieiev • Rui Fernandes  
(Kyiv, Ukraine • Jacksonville, FL, USA)



Official Journal of the  
Ukrainian Association for  
Maxillofacial and Oral Surgeons

[DTJournal.org](http://DTJournal.org)

# TANTUM VERDE®

QUICK RELIEF FROM PAIN  
AND INFLAMMATION IN THE  
MOUTH AND THROAT<sup>1</sup>

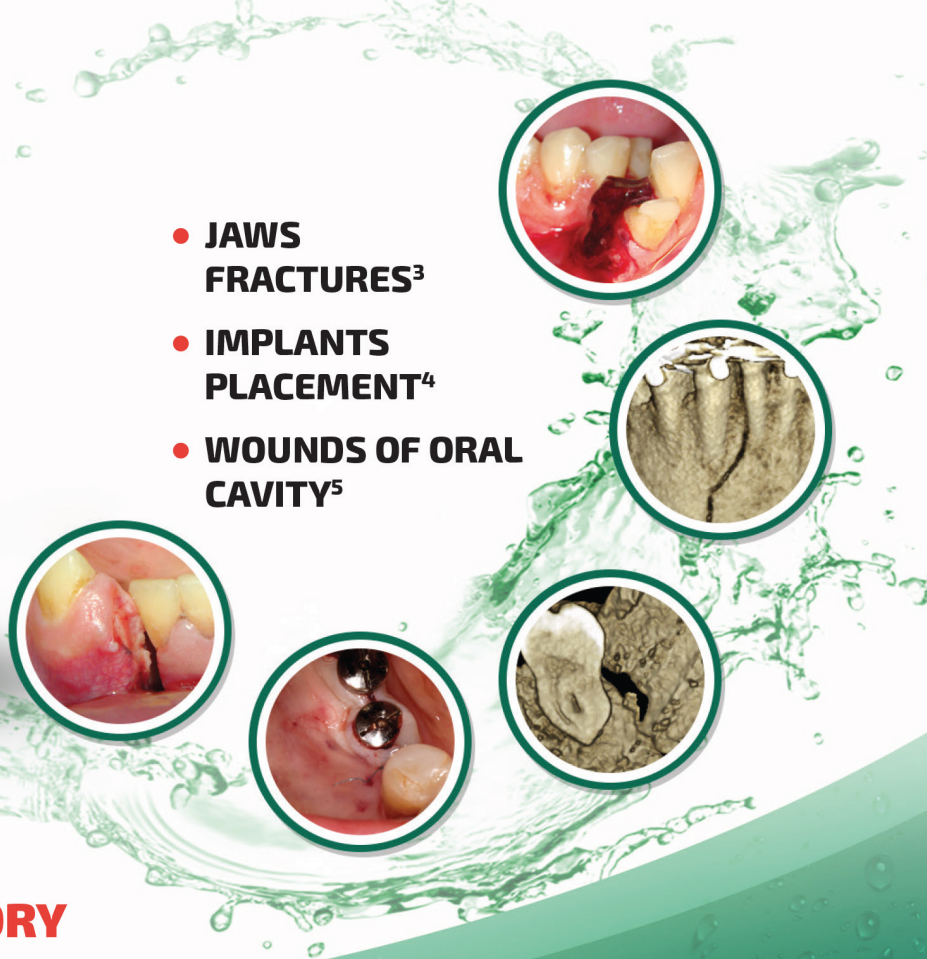
**AN INTEGRAL COMPONENT OF THE TREATMENT  
OF PAIN AND INFLAMMATION IN THE ORAL CAVITY  
IN 60 COUNTRIES WORLDWIDE!<sup>2</sup>**



Reg. № UA/3920/01/01

**LOCAL ANESTHETIC  
AND ANTI-INFLAMMATORY  
EFFECT<sup>1</sup>**

- **JAWS FRACTURES<sup>3</sup>**
- **IMPLANTS PLACEMENT<sup>4</sup>**
- **WOUNDS OF ORAL CAVITY<sup>5</sup>**



#### SUMMARY OF PRODUCT CHARACTERISTICS

**NAME OF THE MEDICINAL PRODUCT.** Tantum Verde 0.15% mouthwash. **QUALITATIVE AND QUANTITATIVE COMPOSITION.** Each 100 ml contains: active ingredient: benzydamine hydrochloride 0.15 g (equivalent to 0.134 g of benzydamine). **Therapeutic indications.** Treatment of symptoms such as irritation/inflammation including those associated with pain in the oropharyngeal cavity (e.g. gingivitis, stomatitis and pharyngitis), including those resulting from conservative or extractive dental therapy. **Posology and method of administration.** Pour 15 ml of Tantum Verde mouthwash into the measuring cup, 2-3 times per day, using it either at full concentration or diluted. If diluted, add 15 ml of water to the graduated cup. Do not exceed the recommended dosage. **Contraindications.** Hypersensitivity to benzydamine or to any of the excipient. **PHARMACOLOGICAL PROPERTIES. Pharmacodynamic properties.** Pharmacotherapeutic group: Stomatologic drugs: other agents for local oral treatment, ATC code: A01AD02. Clinical studies demonstrate that benzydamine is effective in relieving suffering from localised irritation of the mouth and pharynx. In addition, benzydamine possesses a moderate local anaesthetic effect. **Pharmacokinetic properties. Absorption.** Absorption through the oropharyngeal mucosa is demonstrated by the presence of measurable quantities of benzydamine in human plasma. These levels are insufficient to produce systemic effects. **Distribution.** When applied locally, benzydamine has been shown to accumulate in inflamed tissues where it reaches effective concentrations because of its capacity to penetrate the epithelial lining.

**Information about medicines. Information for health care professionals for use in professional activities.**

1. Інструкція для медичного застосування лікарського засобу Тантум Верде®, розчин для ротової порожнини, РПН № UA/3920/01/01, затверджено Наказом Міністерства охорони здоров'я України № 636 від 01.10.2015.

2. <http://www.angelini-pharma.com/wps/wcm/connect/com/home/Angelini+Pharma+in+the+world/>

3. Тимофеев А.А. и др. "Особенности гигиены полости рта для профилактики воспалительных осложнений при переломах нижней челюсти". Современная стоматология 2015;1(75):52-8.

4, 4.5. Tymofiejew O.O. et al "Prevention of inflammatory complications upon surgeries in maxillofacial region". J Diagn Treat Oral Maxillofac Pathol. 2017;1:105-12.

Clinical and CT images are courtesy of: Ievgen Fesenko (Department of Oral & Maxillofacial Surgery, PHEI "Kyiv Medical University", Kyiv, Ukraine), Oleg Mastakov ("SCIEDECE—Scientific Center of Dentistry & Ultrasound Surgery" Kyiv, Ukraine)



04119, Kiev, Melnikova str. 83D, of. 404.

Tel.: (044) 538-01-26

Fax: (044) 538-01-27



# About the Journal: Aims and Scope

MARCH 2022 • VOLUME 6 • ISSUE 3  
www.djournal.org

## Official Title

*Journal of Diagnostics and Treatment of Oral and Maxillofacial Pathology*

## Standard Abbreviation: ISO 4

*J. Diagn. Treat. Oral Maxillofac. Pathol.*

## Acronym

JDTOMP

## International Standard Serial Number (ISSN)

Electronic ISSN 2522-1965

## Aims & Scope

This is a monthly peer-reviewed oral and maxillofacial surgery journal focused on: Microvascular and jaw reconstructive surgery, dental implants, salivary gland tumors/diseases, TMJ lesions, virtual surgical planning, implementation of ultrasonography into the practice of oral and maxillofacial surgeons.

## Editorial Board (EB) Composition

- EB shows significant geographic diversity representing 29 opinion leaders from 13 countries: Brazil, Canada, Colombia, Greece, Hong Kong (SAR, China), India, Israel, Italy, Slovak Republic, Spain, Ukraine, United Arab Emirates, and United States.
- The majority of the EB Members have a discernible publication history in Scopus, Web of Science, and journals with a high impact factor.
- The publication records of all EB members are consistent with the stated scope and published content of the journal.
- The journal has a several full-time professional editors.
- Gender distribution of the editors: 10.34% women, 89.65% men, 0% non-binary/other, and 0% prefer not to disclose.

## Frequency

12 print/online issues a year (from January 2020)

## Publication History

2017: 4 issues a year

2018: 4 issues a year

2019: 10 issues a year

From 2020: 12 issues a year

## Publishing Model

*Journal of Diagnostics and Treatment of Oral and Maxillofacial Pathology* is a fully open access and peer-reviewed publication.

## Type of Peer Review

The journal employs “double blind” reviewing.

## Article Publishing Charge (APC)

During hard times of Covid-19 pandemic our journal trying to support authors by reducing the APC by 50%. And by the end of March 2022 the APC will be 100 USD and 50 USD (excluding taxes) depending on the article's type. Details at website: [dtjournal.org](http://dtjournal.org).

## 13 Types of Articles Currently Published by the Journal

Editorials/Guest Editorials/Post Scriptum Editorials, Images, Case Reports/Case Series, Original Articles, Review Articles, Discussions, Paper Scans (*synonyms*: Review of Articles, Literature Scan), Book Scans (*synonym*: Book Reviews), Letters to the Editor (*synonym*: Letters), and Viewpoints.

## State Registration: Ministry of Justice of Ukraine

Registration: Jul 28, 2016 (Certificate: KB № 22251-12151 P)

Re-registration: May 21, 2019 (Certificate: KB № 23999-13839 IIP)

Re-registration: Aug 10, 2021 (Certificate: KB № 24951-14891 IIP)

## Co-Founders

1. Shupyk National Healthcare University of Ukraine (formerly known as Shupyk National Medical Academy of Postgraduate Education).
2. Private Higher Educational Establishment “Kyiv Medical University.”
3. OMF Publishing, Limited Liability Company.

## Publisher

OMF Publishing, LLC is an academic publisher focused on medical and linguistic sciences.

Address: 13-A Simferopolska Street, Office 121, Kyiv 02096, Ukraine.

## Crossref Membership

OMF Publishing, LLC is a member of Publishers International Linking Association, Inc. which doing business as a Crossref. OMF Publishing's active membership: From February 2017 to present.

## Official Journal of the Association

Ukrainian Association for Maxillofacial and Oral Surgeons

## Ukrainian Association for Maxillofacial and Oral Surgeons (UAMOS)

Address: 4-A Profesora Pidvysotskoho Street, Kyiv 01103, Ukraine.

Tel., fax: +38 044 528 35 17.

Website: [uamos.org](http://uamos.org).

© 2022 OMF PUBLISHING, LLC

# Editorial Board

MARCH 2022 • VOLUME 6 • ISSUE 3  
www.djournal.org

## Editor in Chief

**Oleksii O. Tymofieiev, ScD**  
Kyiv, Ukraine

## Deputy Editor in Chief

**Rui P. Fernandes, MD, DMD, FACS, FRCS(Ed)**  
Jacksonville, Florida, United States

## Section Editors

### Bone Augmentation Techniques

**Nardy Casap, MD, DMD**  
Jerusalem, Israel

### Business

**Ivan V. Nagorniak, MSc, PhD**  
Kyiv, Ukraine

### Craniofacial Deformities

**Sunil Richardson, MDS**  
Nagercoil, Tamil Nadu, India

### Facial Feminization Surgery

**Kyle Keojampa, MD, FACS**  
Los Angeles, California, United States

### Facial Plastic Surgery

**Tirbod Fattahi, MD, DDS, FACS**  
Jacksonville, Florida, United States

### Head & Neck Oncologic Surgery

**Todd C. Hanna, MD, DDS, FACS**  
New York, New York, United States

### Head & Neck Radiology

**Anil T. Ahuja, MBBS, MD, FRCR, FHKCR, FHKAM**  
Hong Kong, SAR, China

### Images

**Camilo Mosquera, DDS**  
Bogotá, D.C., Colombia

### Orthognathic Surgery

**Mario Brinhole**  
São Paulo, São Paulo, Brazil

### Robotic Surgery

**Salam O. Salman, MD, DDS, FACS**  
Jacksonville, Florida, United States

### TMJ Lesions/Disorders

**Belmiro C. Vasconcelos, DDS, PhD**  
Recife, Pernambuco, Brazil

## Editorial Board Members

**Oleh M. Antonyshyn, MD, FRCS(C)**  
Toronto, Ontario, Canada

**Anthony M. Bunnell, MD, DMD, FACS**  
Jacksonville, Florida, United States

**Nur A. Hatab, DMD, PhD**  
Ras Al Khaimah, United Arab Emirates

**Andrey V. Kopchak, ScD**  
Kyiv, Ukraine

**Olindo Massarelli, MD, PhD, FEBOMFS**  
Sassari, Italy

**Anastasiya Quimby, DDS, MD**  
Fort Lauderdale, Florida, United States

**Daniel Robles Cantero, DDS, MSc**  
Madrid, Spain

**Peter Stanko, MD, PhD**  
Bratislava, Slovak Republic

**Rostyslav M. Stupnytskyi, ScD**  
Kyiv, Ukraine

**Olexander O. Tymofieiev, ScD**  
Kyiv, Ukraine

**Natalia O. Ushko, ScD**  
Kyiv, Ukraine

**Andrew Yampolsky, DDS, MD**  
Philadelphia, Pennsylvania, United States

### Web & Social Media Editor

**João L. Monteiro, DDS**  
Boston, Massachusetts, United States

### Director, Journal Development Department

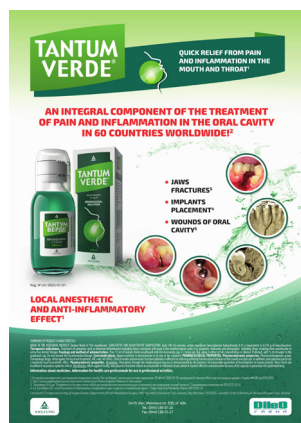**Evangelos G. Kilipiris, DMD**  
Thessaloniki, Greece | Bratislava, Slovak  
Republic

### Managing Editor

**Ievgen I. Fesenko, PhD**  
Kyiv, Ukraine

### Resident Ambassador

**John M. Le, DDS, MD**  
Birmingham, Alabama, United States



# TANTUM VERDE®

## INFORMATION LEAFLET

### for the medicinal product

#### **Composition:**

**active substance: benzydamine hydrochloride;**  
100 mL of solution contain benzydamine hydrochloride 0.15 g;

**excipients:** ethanol 96%, glycerol, methyl parahydroxybenzoate (E 218), flavor (menthol), saccharin, sodium hydrocarbonate, Polysorbate 20, Quinoline Yellow (E 104), Patent Blue V (E 131), purified water.

**Dosage form.** Oromucosal solution.

**Basic physical and chemical properties:** a clear green liquid with a typical mint flavor.

**Pharmacotherapeutic group.** Dental preparations. Other agents for local oral treatment.

ATC code: A01A D02.

#### **Pharmacological properties.**

##### *Pharmacodynamics.*

Benzydamine is a non-steroidal anti-inflammatory drug (NSAID) with analgesic and antiexudative properties.

Clinical studies have shown that benzydamine is effective in the relief of symptoms accompanying localized irritation conditions of the oral cavity and pharynx. Moreover, benzydamine has anti-inflammatory and local analgesic properties, and also exerts a local anesthetic effect on the oral mucosa.

##### *Pharmacokinetics.*

Absorption through the oral and pharyngeal mucosa has been proven by the presence of measurable quantities of benzydamine in human plasma. However, they are insufficient to produce any systemic pharmacological effect. The excretion occurs mainly in urine, mostly as inactive metabolites or conjugated compounds.

When applied locally, benzydamine has been shown to cumulate in inflamed tissues in an effective concentration

due to its ability to permeate through the mucous membrane.

#### **Clinical particulars.**

##### **Indications.**

Symptomatic treatment of oropharyngeal irritation and inflammation; to relieve pain caused by gingivitis, stomatitis, pharyngitis; in dentistry after tooth extraction or as a preventive measure.

##### **Contraindications.**

Hypersensitivity to the active substance or to any other ingredients of the product.

#### **Interaction with other medicinal products and other types of interaction.**

No drug interaction studies have been performed.

#### **Warnings and precautions.**

If sensitivity develops with long-term use, the treatment should be discontinued and a doctor should be consulted to get appropriate treatment.

In some patients, buccal/pharyngeal ulceration may be caused by severe pathological processes. Therefore, the patients, whose symptoms worsen or do not improve within 3 days or who appear feverish or develop other symptoms, should seek advice of a physician or a dentist, as appropriate.

Benzydamine is not recommended for use in patients hypersensitive to acetylsalicylic acid or other non-steroidal anti-inflammatory drugs (NSAIDs).

The product can trigger bronchospasm in patients suffering from or with a history of asthma. Such patients should be warned of this.

For athletes: the use of medicinal products containing ethyl alcohol might result in positive antidoping tests considering the limits established by some sports federations.

#### *Use during pregnancy or breast-feeding*

No adequate data are currently available on the use of benzydamine in pregnant and breastfeeding women. Excretion of the product into breast milk has not been studied. The findings of animal studies are insufficient to make any conclusions about the effects of this product during pregnancy and lactation.

The potential risk for humans is unknown.

TANTUM VERDE should not be used during pregnancy or breast-feeding.

#### *Effects on reaction time when driving or using machines*

When used in recommended doses, the product does not produce any effect on the ability to drive and operate machinery.

#### **Method of administration and doses.**

Pour 15 mL of TANTUM VERDE solution from the bottle into the measuring cup and gargle with undiluted or diluted product (15 mL of the measured solution can be diluted with 15 mL of water). Gargle 2 or 3 times daily. Do not exceed the recommended dose.

#### *Children.*

The product should not be used in children under 12 years due to a possibility of ingestion of the solution when gargling.

#### **Overdosage.**

No overdose has been reported with benzydamine when used locally. However, it is known that benzydamine, when ingested in high doses (hundreds times higher than those possible with this dosage form), especially in children, can cause agitation, convulsions, tremor, nausea, increased sweating, ataxia, and vomiting. Such acute overdose requires immediate gastric lavage, treatment of fluid/salt imbalance, symptomatic treatment, and adequate hydration.

#### **Adverse reactions.**

Within each frequency group, the undesirable effects are presented in order of their decreasing seriousness.

Adverse reactions are classified according to their frequency: very common ( $\geq 1/10$ ); common ( $\geq 1/100$  to  $<1/10$ ); uncommon ( $\geq 1/1,000$  to  $<1/100$ ); rare ( $\geq 1/10,000$  to  $<1/1,000$ ); very rare ( $<1/10,000$ ); frequency unknown (cannot be estimated from the available data).

*Gastrointestinal disorders:* rare – burning mouth, dry mouth; *unknown* – oral hypesthesia, nausea, vomiting, tongue edema and discoloration, dysgeusia.

*Immune system disorders:* rare – hypersensitivity reaction, *unknown* – anaphylactic reaction.

*Respiratory, thoracic and mediastinal disorders:* very rare – laryngospasm; *unknown* – bronchospasm.

*Skin and subcutaneous tissue disorders:* uncommon – photosensitivity; very rare – angioedema; *unknown* – rash, pruritus, urticaria.

*Nervous system disorders:* *unknown* – dizziness, headache.

TANTUM VERDE contains methyl parahydroxybenzoate, which can cause allergic reactions (including delayed-type reactions).

**Shelf life.** 4 years.

#### **Storage conditions.**

Do not store above 25°C. Keep out of reach of children.

#### **Packaging.**

120 mL of solution in a bottle with a measuring cup; 1 bottle per cardboard box.

#### **Dispensing category.**

Over-the-counter medicinal product.

#### **Manufacturer.**

Aziende Chimiche Riunite Angelini Francesco A.C.R.A.F. S.p.A., Italy.

Location of the manufacturer and its business address.  
Via Vecchia del Pinocchio, 22 – 60100 Ancona (AN), Italy.

#### **Date of the last revision of the text.**

September 26, 2018.

Information leaflet is

**APPROVED** by

Order of the

**Ministry of Health of Ukraine**

No. 636 dated 01.10.2015

**Registration Certificate**

No. UA/3920/01/01

# Our Supporters

MARCH 2022 • VOLUME 6 • ISSUE 3  
www.djournal.org

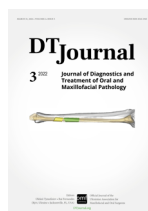


**FIGURE.** Evangelos G. Kilipiris, MD, DMD from the National Institute of Children's Diseases and Faculty of Medicine at Comenius University, Bratislava, Slovak Republic. A kind support of Dr. Kilipiris during the 5 years at the position of Director, Journal Development Department helped our journal to move forward and to evolve. An honorary plaque was presented to him on behalf of the Chief Editor with words "To a Founding Director, Author of Multiple Articles and Reviews, Great Thanks and Appreciation." Photo was taken on November 23, 2021.

# Content

of the Volume 6 • Issue 3 • March 2022

	A1	<b>Publisher &amp; Editorial Office Information</b>
	A2	<b>Editorial Board</b>
	A5	<b>Our Supporters</b>
	A6	<b>Content, Courtesy, &amp; Erratum</b>
BUSINESS: EDITORIAL	35	<b>Managing Private Practice in a War Zone</b> Ivan V. Nagorniak
EDITORIAL	37	<b>The Heroes of the 21st Century</b> Evangelos G. Kilipiris
TECHNIQUE	39	<b>The “Beveled One-and-a-Half-Barrel” Fibula Transplant with Virtual Surgical Planning and CT-Guided Implant Surgery for Prosthetic Rehabilitation in Posterior Mandible Defects: A Pictorial Essay</b> Olindo Massarelli & Silvio Mario Meloni



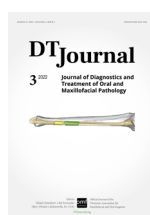COURTESY

*Journal's* cover image (virtual surgical planning for a segmental mandibular reconstruction with fibula transplant) is courtesy of Rui P. Fernandes, MD, DMD, FACS, FRCS.

Image was taken from the article: Fernandes RP, Quimby A, Salman S. Comprehensive reconstruction of mandibular defects with free fibula flaps and endosseous implants. *J Diagn Treat Oral Maxillofac Pathol* 2017;1(1):6–10.

<https://doi.org/10.23999/j.dtomp.2017.1.1>





## BUSINESS: EDITORIAL

Ivan V. Nagorniak, MSc, PhD, *Section Editor*

# Managing Private Practice in a War Zone

Ivan V. Nagorniak

*The private sector [in a war time] can help push the whole social and economic environment in a better, more functional direction.<sup>1</sup>*

—James Robinson  
Professor

Eighteen days of the full-scale Russian invasion into Ukraine<sup>2,3</sup> gave us urgently a need to rethink the ways we can run private dental and oral surgery practice. Wartime dictate us completely different and sometimes highly risky agenda.

For the need to provide emergency dental care and oral surgery to those residents of the city/village who cannot or do not want to be evacuated from the regions of hostilities, some private practices continue to work. Although they are not providing a full range of services, they are highly efficient even carrying out emergency care, e.g. 16 private practices in Kyiv during the first 13 days of Russian-Ukraine war of February-March 2022.<sup>4</sup>

*Let's pray for our businessmen. ... Every workplace [in wartime] is sacred.<sup>5</sup>*

—Oleksiy Honcharenko  
Deputy of Verkhovna Rada of Ukraine

Among problematic sides of managing private clinic in war zones are: (1) supply chain disruption (Williams, 2013)<sup>6</sup> of the dental and oral surgery materials, (2) interruption in work of dental technicians or complete cessation of their activities due to the evacuation or absence of materials, (3) termination of work of diagnostic centers that are important for diagnosis establishment and for control of treatment results, (4) difficulties (increased price for taxi and risks for life) for patients and staff members on transfer to the clinic, (5) significant decrease of clinic's personnel members due to the possible evacuation, (6) decrease of the number of performed procedures due to the paragraphs 1, 2, 3, and 5, (7) the need to go down to the bomb shelters in case of air alarm, forcing the interruption of treatment procedure, (8) injury of the staff members, (9) significant decrease of amount of financial resources due to the paragraphs 1, 2, 3, 4, 6, etc.

In some cases the whole clinic's staff may be evacuated from the work place and town. Of course, modern video technologies with a remote control via your laptop or smartphone can assist in controlling the condition of the private practice infrastructure and gave a possibility to call the local police in case marauders

MSc, PhD; Head Doctor, Private Entrepreneur Nagorniak I.V., Kyiv, Ukraine.

Author's address: Private Practice (Certificate for management system according to ISO 9001:2015 – Private Entrepreneur Nagorniak I.V.), 6-G Andruschenka Street, Office 6, Kyiv 01135, Ukraine.  
E-mail: [ivan.nagorniak@gmail.com](mailto:ivan.nagorniak@gmail.com)

Please cite this article as: Nagorniak IV. Managing private practice in a war zone. *J Diagn Treat Oral Maxillofac Pathol* 2022;6(3):35–6.

Paper received 13 March 2022  
Accepted 14 March 2022  
Available online 15 March 2022

<https://doi.org/10.23999/j.dtmp.2022.3.1>

© 2022 OMF Publishing LLC. This is an open access article under the CC BY license (<http://creativecommons.org/licenses/by-nc/4.0/>).

break into your premises. But, if this happened and the police do not have enough staff to send it to your business location—defending the property with a rifle in own hands could be a measure what will stop the marauders from the criminal act.

The other positive aspect for practice owners to remain in private practice, even in wartime, include the gratitude of patients who have been helped with acute pain, maxillofacial trauma, post-operative complication, and a sharp increase in the reputation of this particular medical institution in the region.

Williams (2013) emphasized—for businesses (i.e., private clinics) that take a risk and survive, the long-term rewards in the rapidly expanding market can be high.<sup>6</sup>

Doing business in zones of conflict is well-described in the work of Rosenau et al (2009).<sup>7</sup> Their conclusions are: doing business contributes to “state-building,” organization of the security measures, improving local community relations, and establishment of an acceptable level of risk for the business (*predictable environment is acceptable even if it’s not peaceful*).<sup>7</sup> The “state-building”<sup>7</sup> and “defense forces-supporting” can be done by paying salaries, taxes, and even creating new jobs<sup>5</sup> for the temporarily displaced people.

Thus, each clinic’s owner decides whether to stay in the clinic and support the work of the practice in wartime. Depending on the decision, the business may even grow, the owner may save expensive equipment, and make her/his own direct (financial transfer) or indirect contribution (jobs, salaries, and taxes) to the national militaries and economy what can help the army to achieve victory over the occupiers faster and to make the state economic situation stronger. Although the safety of life of the employees is a priority, some owners of the practice may remain, taking into account the activity of hostilities and the presence of the missile defense systems in that particular region of the country

*The private sector creates wealth, promotes socio-economic development and contributes to preventing and resolving conflict.*<sup>8</sup>

—Dean C. Alexander

Associate Professor of Homeland Security at Western Illinois University, IL, USA

*The government will do everything possible to help the regions adapt to new realities [of wartime].*<sup>9</sup>

—Oleksii Reznikov

Minister of Defense of Ukraine

## REFERENCES (9)

1. Doing business in a war zone [document on the internet]; Oct 15, 2018 [cited 2022 Mar 08]. Available from: <https://www.london.edu/news/doing-business-in-a-war-zone-1563>
2. Fesenko II. Stop the war! Europeans, homes, kindergartens, hospitals, universities, and global science are under the missiles. *J Diagn Treat Oral Maxillofac Pathol* 2022;6(2):32–4. <https://doi.org/10.23999/j.dtemp.2022.2.3>
3. Winsor M, Shapiro E, El-Bawab N, Pereira I, Jacobo J, Deliso M, Hutchinson B, Shalvey K, Darrrough C. Russia-Ukraine updates: Zelenskyy claims nearly 13,000 Russian soldiers dead [document on the internet]; Mar 13, 2018 [cited 2022 Mar 13]. Available from: <https://abcnews.go.com/International/live-updates/russia-ukraine/?id=83390885>
4. Osadcha Y. Where in Kyiv you can treat your teeth for free - the addresses of dental clinics [in Ukrainian] [document on the internet]; Mar 05, 2022 [cited 2022 Mar 08]. Available from: <https://life.pravda.com.ua/health/2022/03/5/247682/>
5. Putin’s biggest fear! Honcharenko told why it is important to work and when the war will end [in Ukrainian] [document on the internet]; Mar 13, 2022 [cited 2022 Mar 13]. Available from: [https://m.youtube.com/watch?v=lgGL1r4\\_a7I&feature=youtu.be](https://m.youtube.com/watch?v=lgGL1r4_a7I&feature=youtu.be)
6. Williams J. Creating sustainable business in a conflict zone [document on the internet]; Oct 31, 2013 [cited 2022 Mar 09]. Available from: <https://knowledge.insead.edu/economics-politics/creating-sustainable-business-in-a-conflict-zone-2944>
7. Rosenau W, Chalk P, McPherson R, Parker M, Long A. Doing business in zones of conflict. In: Rosenau W, Chalk P, McPherson R, Parker M, Long A. Corporations and counterinsurgency. 1st edition. Santa Monica: RAND Corporation, 2009:3–8. <http://www.jstor.org/stable/10.7249/op259>
8. Alexander DC. Threats and opportunities of doing business in conflict zones [document on the internet]; May 08, 2013 [cited 2022 Mar 10]. Available from: <https://www.securitymagazine.com/articles/84288-doing-business-in-conflict-zones-threats-and-opportunities>
9. Address of the Minister of Defense of Ukraine Oleksii Reznikov on the 15th day of heroic resistance of the Ukrainian people [in Ukrainian] [document on the internet]; Mar 10, 2022 [cited 2022 Mar 10]. Available from: <https://www.youtube.com/watch?v=0yyYO3aJjmc>



## EDITORIAL

# The Heroes of the 21st Century

Evangelos G. Kilipiris

*If freedom is to survive and prosper, it will require the sacrifice, the effort, and the thoughtful attention of every citizen.*

—John F. Kennedy  
35th President of the USA

Like many of you, I closely follow the horrifying situation unfolding in Ukraine. Russia has launched a full-scale attack against Ukraine with an unimaginable magnitude. The news and pictures from Kyiv, Kharkiv, and elsewhere, with indiscriminate attacks of airstrikes and missiles hitting hospitals and universities, rockets dropping in residential buildings, are almost unbearable to watch. The stories of untold death of civilians, including children, and colossal destruction by creating millions of refugees are hard to absorb. And the prospect of much worse to come tragically real lies in front of us.

This war occurs in a period where authoritarian regimes are surging globally within a highly interconnected world, with the consequences extending well beyond Ukraine. Many hazards lie ahead based on the nature of the conflict, but all the odds are on the Ukraine's side. The valiant Ukrainian population is willing to fight to the end, and the West has found the unity and resolve to aid it. At this

moment, the important thing is to move with scale and urgency in support of such an insurgency. Since February 24, 2022, Ukrainians have written a new chapter in global history by defending the truth and their freedom. Every individual who would like to stand on this golden side of history has a remarkable job.

As an engine of genuine democratic progress, physicians, including oral and maxillofacial surgeons, their healthcare institutions, academic organizations, and journals, have a clear role. In the frontline facilities by directly providing advanced oral and maxillofacial surgical care and humanitarian assistance, and on the backstage, by mobilizing the communities worldwide as trusted voices of truth.

Today, Ukraine is facing a vicious form of nationalism from a country that saw a million more deaths than births last year, that is burdened with a corrupt and limited economy, and an isolated, aging dictator leading that. A dictator, who I should acknowledge, has only one advantage: he knows how to play head games with his enemies. However, these games have been heavily crashed on the courage of Ukrainians as they bravely fight for their right to live in a sovereign country. Fear is not the consequence

---

MD, DMD; Director, Journal Development Department, *Journal of Diagnostics and Treatment of Oral and Maxillofacial Pathology (JDTOMP)*, Bratislava, Slovak Republic.

Corresponding author's address: National Institute of Children's Diseases and Faculty of Medicine at Comenius University, 1 Limbova Street, Bratislava 83340, Slovak Republic.  
E-mail: [varonos@live.co.uk](mailto:varonos@live.co.uk)

Please cite this article as: Kilipiris EG. The heroes of the 21st century. *J Diagn Treat Oral Maxillofac Pathol* 2022;6(3):37–8.

Paper received 11 March 2022

Accepted 12 March 2022

Available online 14 March 2022

<https://doi.org/10.23999/j.dtmp.2022.3.2>

© 2022 OMF Publishing, LLC. This is an open access article under the CC BY license (<http://creativecommons.org/licenses/by-nc/4.0/>).

of Russian actions but rather their objective.

The last weeks have been saturated with significant trauma, physical and emotional exhaustion on the battlefield. However, surprisingly, we can discover real hope in these deadly events. Now is the most suitable time to ask the biggest questions about how a nation wishes to look once this war is over. We should look beyond the dark horizon by preparing the building blocks of our reconstructive phase. Under normal circumstances, future imagination is limited, indicating that the inspiration for a nation's long-term vision must begin now. Yes, it might sound crazy to do this in the present days. But at the same time, as missiles and rockets fall in cities, villages, and neighborhoods, more fertile seeds are planted in the nation...

Because in the end, the globe will remember Ukraine on how it emerged stronger from this experience!!!

To all those who fight in the battlefield to defend Ukraine, I address: “Ἡ τὰν ἢ ἐπὶ τᾶς.”\*

To all those who died defending Ukraine or trying to escape the attacks against civilians, I narrate: “Ἀνδρῶν γὰρ ἐπιφανῶν πᾶσα γῆ τάφος, καὶ οὐ στηλῶν μόνον ἐν τῇ οἰκείᾳ σημαίνει ἐπιγραφή, ἀλλὰ καὶ ἐν τῇ μὴ προσηκούσῃ ἄγραφος μνήμη παρ’ ἐκάστῳ τῆς γνώμης μᾶλλον ἢ τοῦ ἔργου ἐνδιδαιτᾶται.”\*\*

Concluding, to all those defenders in Ukraine and all Ukrainians around the world, I will continue to keep you at the forefront of my thoughts, and please let me take this opportunity and recite: “At the dawn of 2022, hence, I will not say that Ukrainians fight like heroes, but i shall say that heroes fight like Ukrainians.”\*\*\*

With brave regards,  
The author

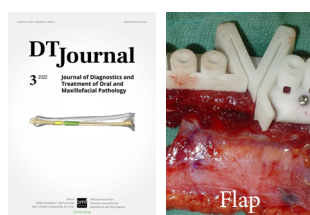---

\* “Either with it or on it.” Found in Lacaenarum Apophthegmata by Plutarch, it is the farewell phrase Spartan mothers or wives said to their departing warrior sons or husbands upon giving them their shield. A warrior returning with his shield meant that he did not flee the battlefield. Had he done so, he must have dropped the large, heavy bronze shield to run faster. A warrior returning on his shield was dead, and his corpse would have been carried home thus. Therefore a Spartan warrior's options were to return either victorious or dead. Returning in shame without a shield was not an option. Spartans were the most powerful and famous warriors in ancient times...

\*\* “The whole earth is the tomb of famous men, and not only inscriptions set up in their country mark it but even in foreign lands an unwritten memorial, present not in the monument but in mind, abides within

each man.” Written in Pericles' Funeral Oration, a famous speech in Thucydides' book “History of the Peloponnesian War.” The address was supposed to have been delivered by Pericles, the eminent Athenian politician, at the end of the first year of the Peloponnesian War (431-404 Before the Common Era [BCE]) as a part of the annual public funeral for praising the war dead...

\*\*\* The iconic British statesman Winston Churchill, who led the United Kingdom during World War II, famously praised the Greek people in a BBC speech during the first days of the war for their incredible courage and fierce resistance against the evil Fascist and Nazi invaders by stating: “Hence we will not say that Greeks fight like heroes, but that heroes fight like Greeks.”



## TECHNIQUE

# The “Beveled One-and-a-Half-Barrel” Fibula Transplant with Virtual Surgical Planning and CT-Guided Implant Surgery for Prosthetic Rehabilitation in Posterior Mandible Defects: A Pictorial Essay

Olindo Massarelli<sup>a,\*</sup> & Silvio Mario Meloni<sup>b</sup>

## SUMMARY

In this study, we present a new case of segmental oro-mandibular reconstruction with fibula transplant, first described as “beveled one-and-a-half-barrel” shape, highlighting tips and tricks for not jeopardizing its vascularity and our technical considerations for adequate dental rehabilitation. A report of all reconstructive stages and secondary implant-rehabilitation phases, outlining the reliability of this new technique together with a comparative analysis of advantages and disadvantages of different reconstructive techniques for alveolar bone reconstruction, was made. This technique was applied in our hospital for a 49-year-old Caucasian woman with an aggressive recurrent ameloblastoma of the left mandible. Post-operative computed tomography with clinical intra- and extraoral photography are presented. We believe that this pictorial essay presented in our paper could be useful as a goal-oriented step-by-step highly detailed surgical guide to achieve a reliable and good shaped bone hardware for further dental rehabilitation in case of segmental posterolateral mandibular reconstruction.

<sup>a</sup> MD, PhD, FEBOMFS; Maxillofacial Surgery Unit, University Hospital of Sassari, Sassari, Italy.

<sup>b</sup> DDS, PhD; Associate Professor, Medical Surgical and Experimental Sciences, University of Sassari, Italy.

\* Correspondence: Principal address: Maxillofacial Surgery Unit, University Hospital of Sassari, Viale San Pietro 43/B, Sassari 07100, Italy.  
Permanent address: Maxillofacial Surgery Operative Unit, Santa Maria delle Scotte University Hospital, Viale Mario Bracci 16, 53100 Siena, Italy.  
E-mails: [molindo74@gmail.com](mailto:molindo74@gmail.com) (Olindo Massarelli)  
[olindo.massarelli@ao-siena.toscana.it](mailto:olindo.massarelli@ao-siena.toscana.it)

Instagram: [@dott.olindomassarelli](https://www.instagram.com/dott.olindomassarelli)

ResearchGate: <https://www.researchgate.net/profile/Olindo-Massarelli>

ORCID: <https://orcid.org/0000-0001-7674-0134>

Please cite this article as: Massarelli O, Meloni SM. The “beveled one-and-a-half-barrel” fibula transplant with virtual surgical planning and CT-guided implant surgery for prosthetic rehabilitation in posterior mandible defects: a pictorial essay. *J Diagn Treat Oral Maxillofac Pathol* 2022;6(3):39–59.

The word 'Flap' at the upper right icon means that article contains intraoperative fibula flap image.

Paper received 19 January 2022

Accepted 10 March 2022

Available online 12 March 2022

<https://doi.org/10.23999/j.dtomp.2022.3.3>

© 2022 OMF Publishing, LLC. This is an open access article under the CC BY license (<http://creativecommons.org/licenses/by-nc/4.0/>).

## INTRODUCTION

Four years have passed from the first report of fibula free flap (FFF) for mandibular reconstruction described by Hidalgo<sup>1</sup> in 1989, when in 1993 Sadove et al<sup>2</sup> reported a simultaneous maxillary and mandibular reconstruction with one osteocutaneous fibula free flap, removing the median portion and utilizing the two distal ends. This was the first evidence in head and neck reconstruction field of the fibular periosteal feeding ability, that represents the fundamental vascular principle on which is based the “double barrel fibular graft” harvesting popularized in 1995 by Horiuchi et al<sup>3</sup> among the head and neck surgeons community.

Later in 2004 Lee et al<sup>4</sup> designed a non-vascularized residual fibula graft for 2-strut type mandibular reconstruction as double barrel hybrid fashion FFF.

A secondary vertical distraction osteogenesis of a fibular graft followed by implant therapy has been fundamentally analyzed by Siciliano et al<sup>5</sup> in 1998 and then followed by others during next 21 years<sup>6-8</sup>. Many technical efforts were made to overcome the main limitation of “single barrel” and “double barrel” FFF to allow prosthetic rehabilitation with an implant-based denture by functional and aesthetic points of view, but all were unsuccessful till 2013. The problem of height discrepancy between native mandible and fibula flap was brilliantly solved by Ulkur et al<sup>9</sup>, who first described the “one-and-a-half-barrel FFF” technique in a case of right mandibular body reconstruction following a giant cell reparative granuloma resection.

The defect extended between the ascending branch and the distal part of the canine tooth and measured almost 8 cm in length.<sup>9</sup> A 17-cm long free fibular flap was designed and harvested.<sup>9</sup> After removing a small piece of fibular bone to fold the transplant, the authors split longitudinally the distal half of the free fibula flap and removed the bone segment away from the perforating vessels.<sup>9</sup> Then the remaining 2 fibula segments were doubled and placed parallel to each other to proper fill the defect and a dental rehabilitation by secondary dental implantation was performed 1.5 year later using a surgical guide based on a cone beam dental volumetric tomography (CBDVT).<sup>9</sup>

Even though, the “one-and-a-half barrel” technique<sup>9</sup> may be a good solution to improve volume

insufficiency of the classical single-strut technique and volume excess of the double-barrel technique for almost all mandibular segments, we believe that for the premolar-molar region, as in cases of defects of the retromolar trigon, it is less effective.

The purpose of this study is to present a new case of oro-mandibular reconstruction with this type of flap modeling in order to confirm its technical feasibility, highlighting our technical innovations compared to the originally described by Ulkur et al.<sup>9</sup>

The computer-aided three-dimensional virtual planning together with customized cutting guides manufacturing, prompted us to raising, for the first time in literature, the one-and-a-half-barrel FFF in a “bevel shape” in a case of segmental mandibular reconstruction. This technical improvement has allowed us a tremendous mandibular reconstructive precision, especially in the premolar-molar region where an adequate prosthetic space is necessary for a very precise and long-lasting implant-supported rehabilitation. A CT-guided implant surgery helped us finalize the case in a more functional and precise way. A report of all reconstructive stages and secondary implant-rehabilitation phases, outlining the reliability of this new technique together with a comparative analysis of advantages and disadvantages of different reconstructive techniques for alveolar bone reconstruction was made.

## CASE

A 49-year-old Caucasian woman, a professional teacher, with the suspicion of recurrent aggressive ameloblastoma of the left mandible was referred to the Maxillofacial Surgery Unit, University Hospital of Sassari (Sassari, Italy) in May 2016, after having performed a conservative treatment (tumor enucleation) in another center two years earlier. She denied experiencing any bleeding, but complained some pain and dysesthesia in the mandibular nerve area.

On physical examination, facial asymmetry due to swelling on the left side of the face was moderately noticed (Fig 1). The intraoral examination revealed some trigon-shape scarring of the mucosa, the absence of 3.7, extracted in previous intervention, and an ill-defined solitary swelling in the left lower posterior buccal vestibule. This extended anterioposteriorly from 3.6 to the retromolar region and mediolaterally to the buccal sulcus. The overlying

mucosa was stretched and slightly whitish, but similar to adjacent mucosal color (Fig 2). On palpation, the swelling was found to be firm, bony hard in consistency, non-tender, non-fluctuant, irreducible, non-compressible and non-pulsatile. The teeth in the vicinity were non-tender to percussion, but slight mobility of 3.6 was present. On electric pulp vitality testing, all teeth in the affected area were vital except 3.6. No lymphadenopathy or fistulas were present. An incisional biopsy was made and the specimen was subjected to histopathological examination. The lesion was found to be a desmoplastic (ie, follicular) ameloblastoma. The CT scans of the mandible (Fig 3A-B) showed a large well-defined expansive radiolucent lesion with a multilocular aspect centered in the left retromolar trigon region. This was responsible for the mandibular body expansion from the mesial surface of the first left lower molar to the mesial surface of the ramus, approximately measuring 5 × 4 cm in size.

The patient underwent left angular and body mandibular resection with simultaneously reconstruction by mean a left fibula free flap that was

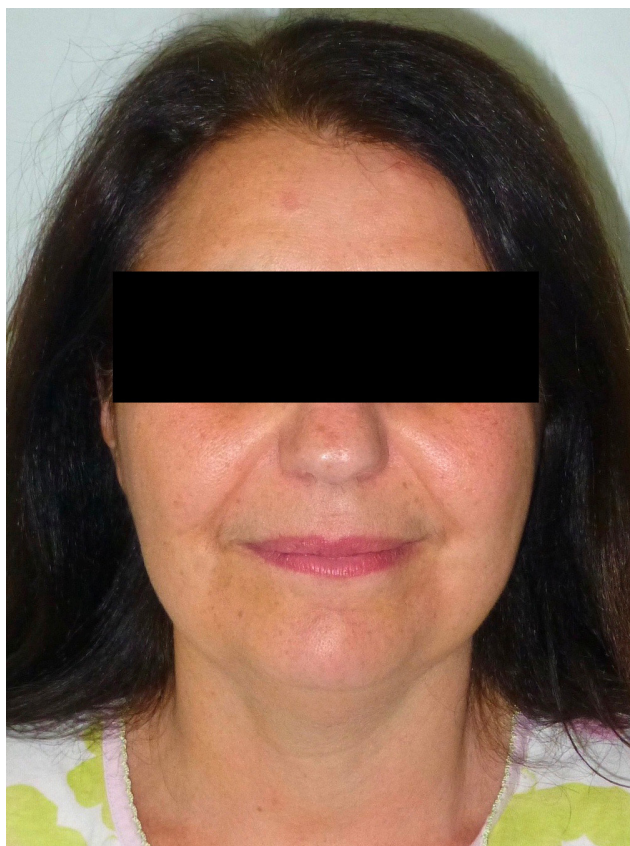planned and shaped thanks to the Synthes ProPlan software (Synthes GmbH, Oberdorf, Switzerland), while the implant-prosthetic rehabilitation was planned according to the NobelClinician® protocol.

After informed consent had been obtained, plaster models, dental impressions (Fig 4A-B), initial photographs, and measurements with a facebow for aesthetic-functional evaluation, were taken.

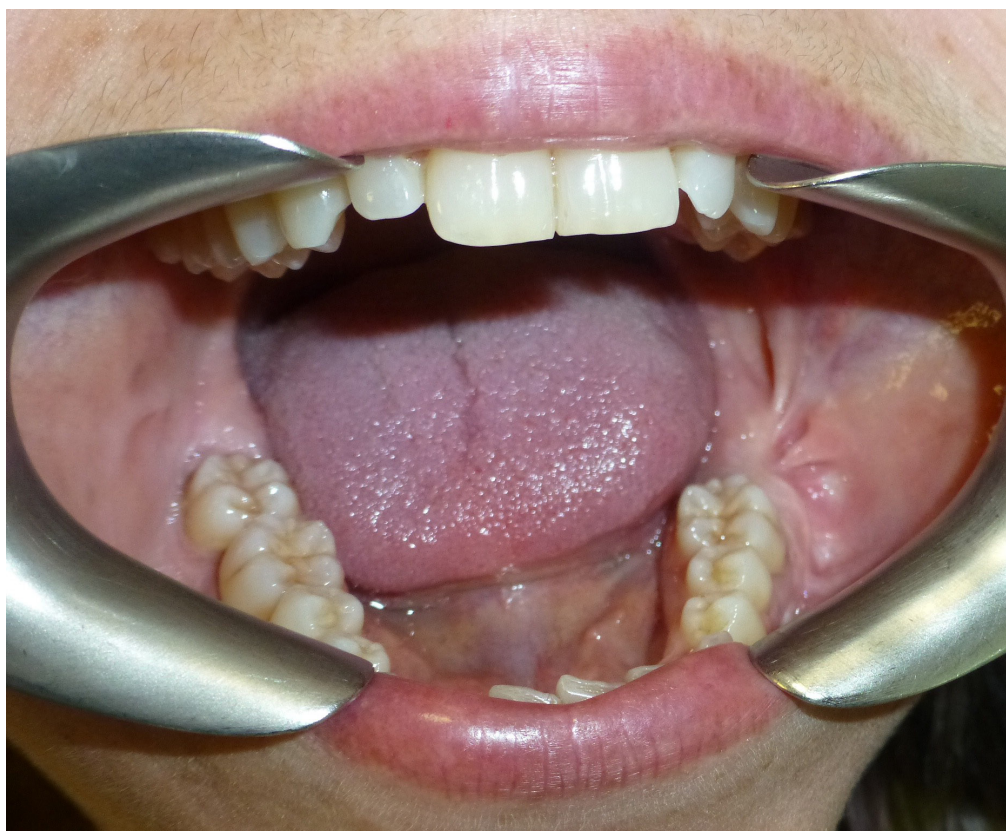The acquisition of high resolution CT data of the maxillofacial skeleton, the plaster models of the jaw and of the donor site have been performed. The data obtained were converted into three-dimensional models thanks to the ProPlan software.

The safety margins for the lesion removal (Fig 5A-D), the number and the orientation of the fibula osteotomies (Fig 6A-B) are established through a videoconference for surgery planning.

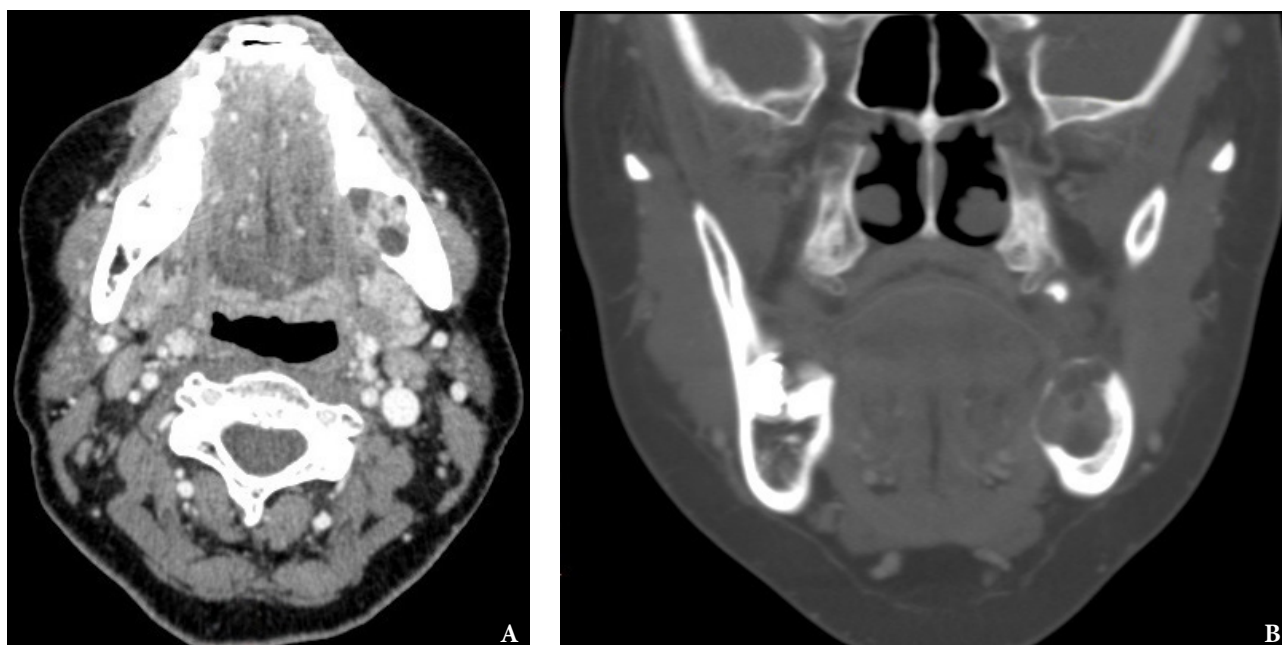
For greater precision in mandibular reconstruction the jaws' plaster models scans were overlay on the preoperative CT mandibular data and then on the mandibular osteotomized planned model in order to preview the future proper position of the dental



**FIGURE 1.** The facial asymmetry due to swelling on the left side of the face was moderately noticed.



**FIGURE 2.** Intraoral examination showed trigon-shape scarring of the mucosa, the absence of 3.7, extracted in previous intervention and an ill-defined solitary swelling in the left lower posterior buccal vestibule. This extended anteroposteriorly from 3.6 to the retromolar region and mediolaterally to the buccal sulcus. The overlying mucosa was stretched and slightly whitish, but similar to adjacent mucosal color.



**FIGURE 3A-B.** The contrast-enhanced CT: Axial (A) and coronal (B) scans. Notes a large well-defined expansive radiolucent lesion with a multilocular aspect centered in the left retromolar trigon region.



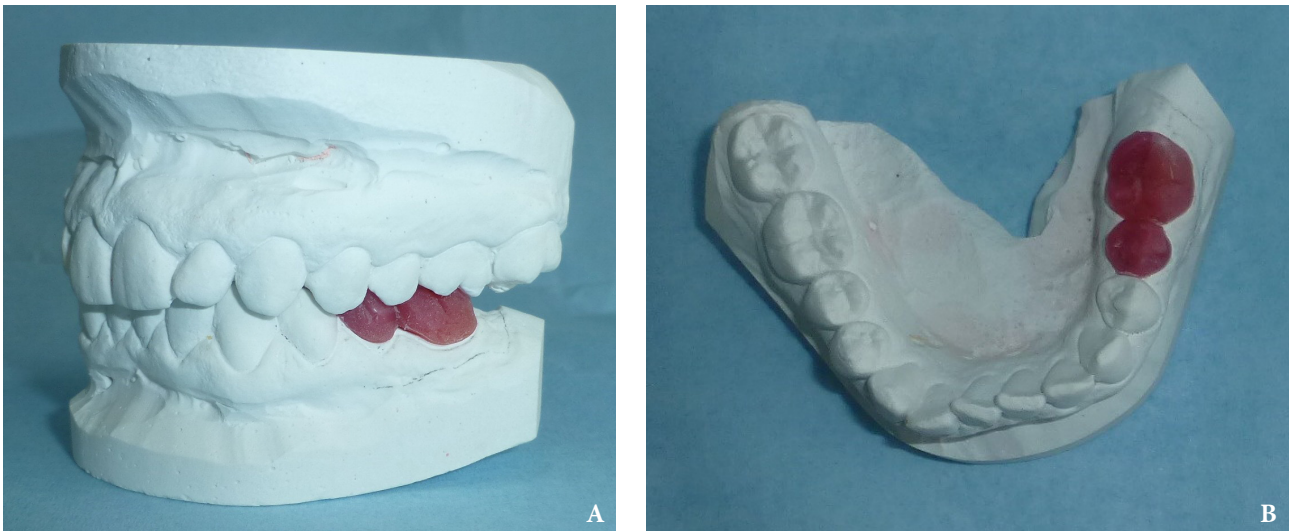


FIGURE 4A-B. Plaster models.

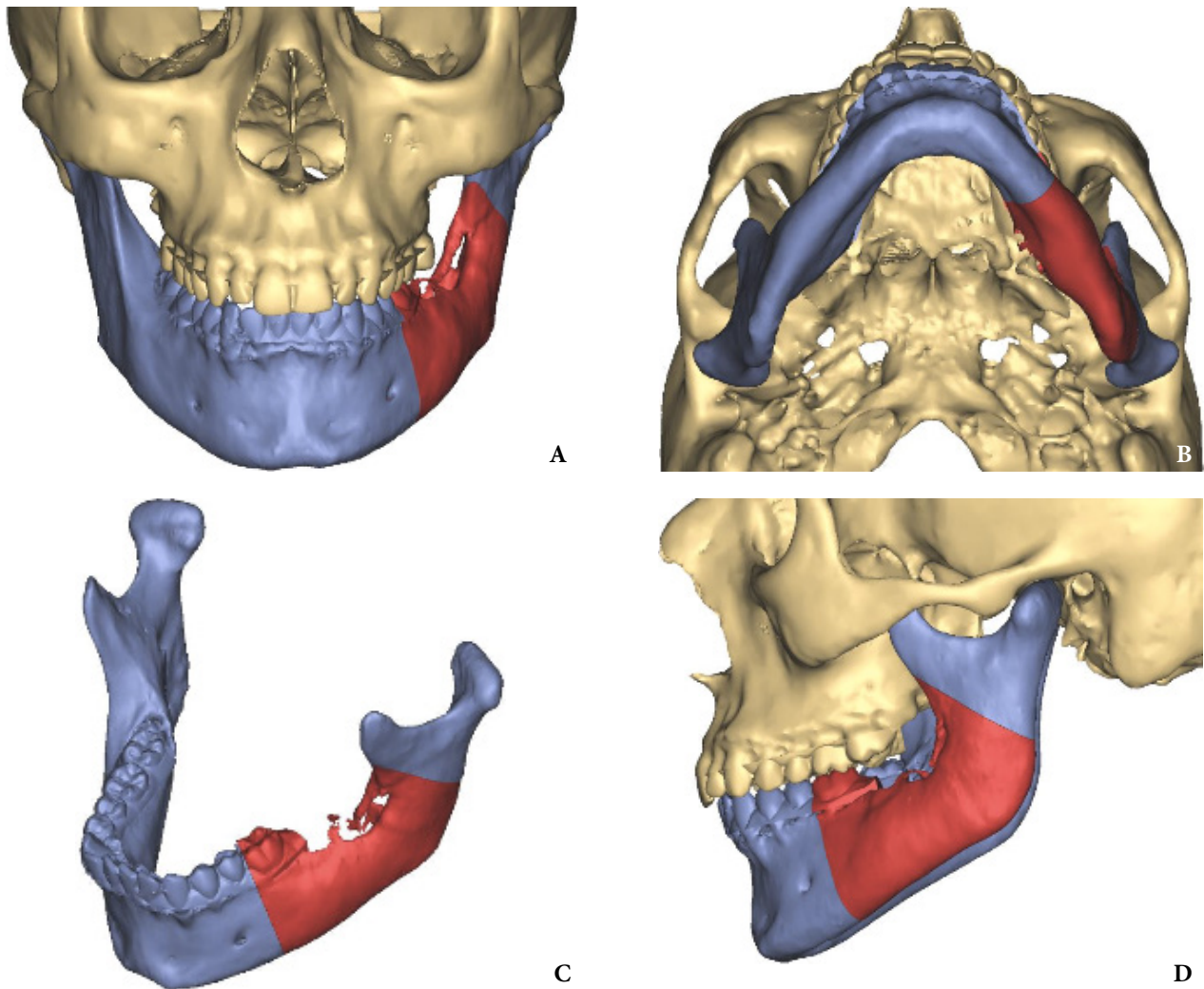
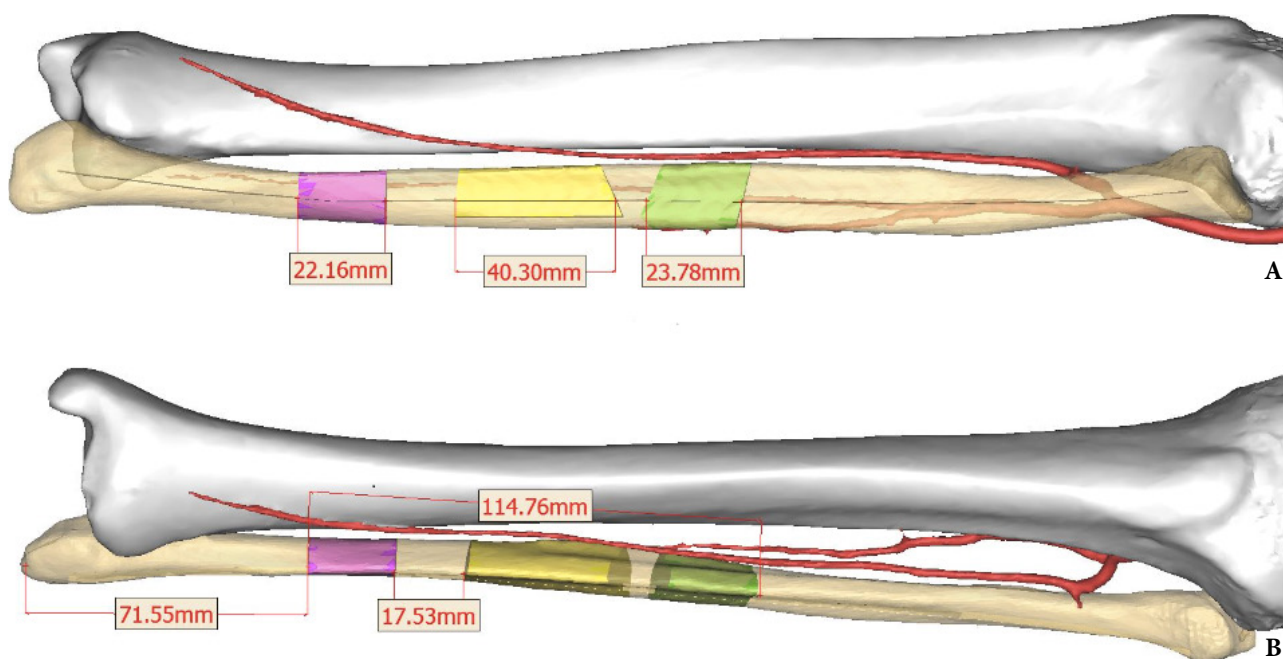


FIGURE 5A-D. Virtual surgical planning of the cutting margins (in red).



**FIGURE 6A-B.** Surgical reconstructive plan: Left fibula graft (3 segments). Image **A** shows lateral view and image **B** – anterior view.

element in the reconstructed jaw (Fig 7A-C). This suggested us to split the doubled segment obliquely in order to obtain the exact mandibular bone height and consequently the correct prosthetic space.

A patient specific mandible cutting guide (Fig 8A-B) as well a patient specific fibula harvesting guide with a minislot for oblique bone splitting (Fig 9A-B) have been manufactured. The latter allowed to trim safely the fibular shaft longitudinally, having considered exactly where was the vascular pedicle and avoiding sectioning it.

Finally, a stereolithographic model and a patient-specific plate were made and sent to us helping to carry out the reconstructive plan in the operative theatre (Fig 10A-B).

The cutting guides have fitted very well to the mandible. Resection was performed using a combined intraoral and external (preauricular) approach (Fig 11A-B) which allowed a safe resection.

The surgical specimen consisting of a jaw segment with the lesion and associated tooth was found to have tumor-free margins (Fig 12A-B). The osteo-fasciocutaneous beveled one-and-a-half FFF transplant was harvested thanks to the planned fibula guide (Fig 13). The transplant survived completely (Fig 14). The post-operative period was uneventful and the intraoral healing was excellent (Fig 15A-B).

The patient underwent computer-assisted guided

implant surgery following the NobelClinician® implant protocol, 14 months after the reconstructive surgery.

The study dental casts were performed mounting them in a mean value articulator, and a diagnostic wax model was made.

A provisional denture was made and the same was filled with radiopaque markers (gutta-percha) as reference points, and used as a radiographic guide for the subsequent installation of the implant. A silicone interocclusal record was made as a radiographic index.

In accordance with the NobelGuide® protocol for the acquisition of data, CT (Cone Beam CT, KaVo Dental GmbH, Biberach, Germany) was taken twice: the first time with the patient wearing the denture (radiological guide) and the radiological index, and the second – with the denture alone. The CT data were transferred to the NobelGuide Procera® software for three-dimensional diagnostic and virtual implant planning. The CT virtual implant planning allowed the insertion of implants while avoiding screws and the plate in the fibular flap (Fig 16A-D). The software planning data were sent to Nobel Biocare (Goteborg, Sweden), where a surgical template was made with the guide implant in the position planned virtually. Then a metal and acrylic resin provisional prosthesis was manufactured (Fig 17A-B).

Under local anesthesia after the template had been

placed, a flapless implant (Replace Tapered Groovy) was inserted using a torque of 35-45 Ncm (Fig 18A-B). The Figure 19 demonstrates panoramic radiography with flapless dental implant positioned into the beveled one-and-a-half-barrel fibula transplant.

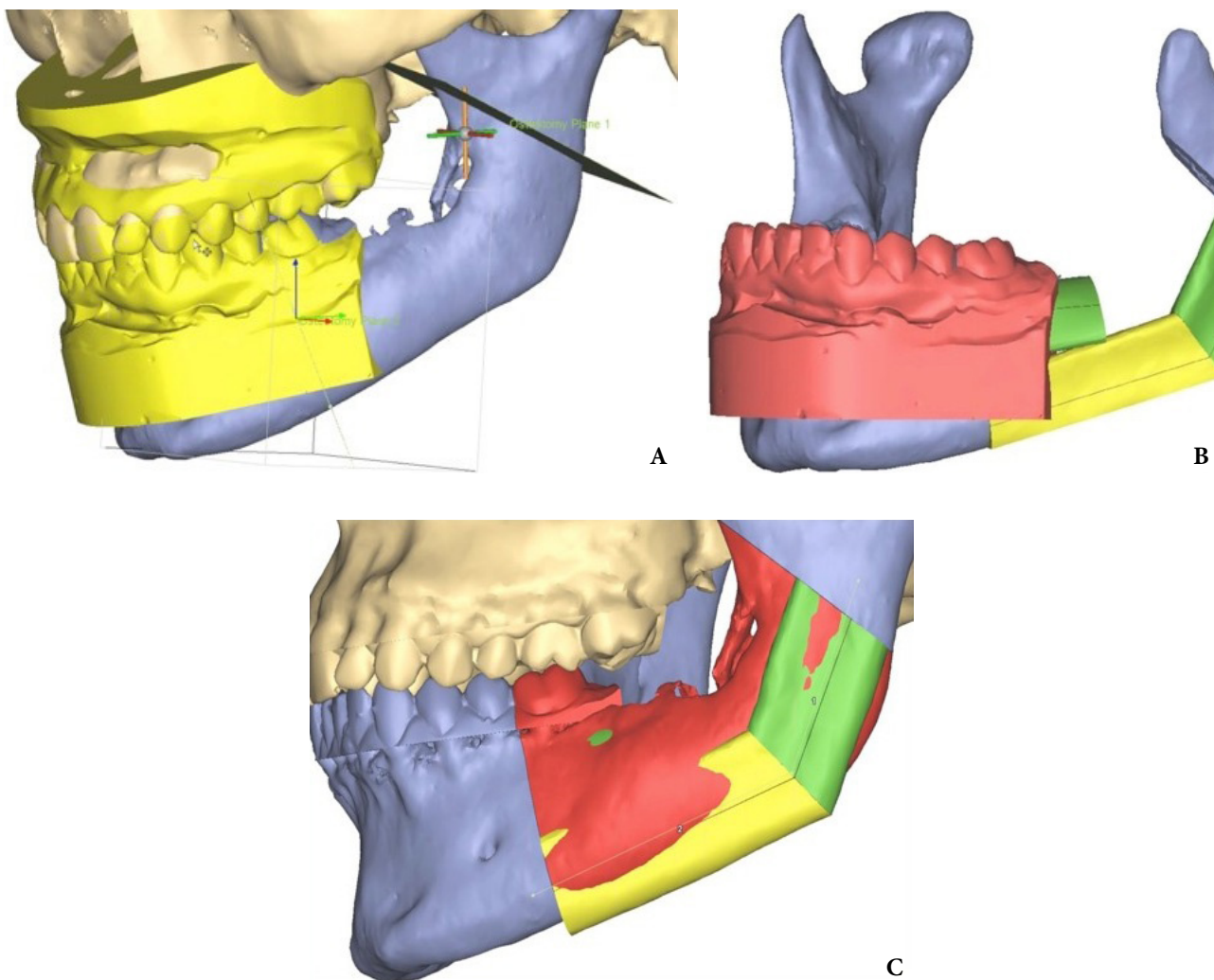
A zirconium oxide crown was performed as a final dental restoration (Fig 20A-B).

Currently at 5-year follow-up (Fig 21), the patient is free from disease or relapses and her implant-supported prosthesis shows no signs of peri-implant bone resorption with full satisfaction from the patient.

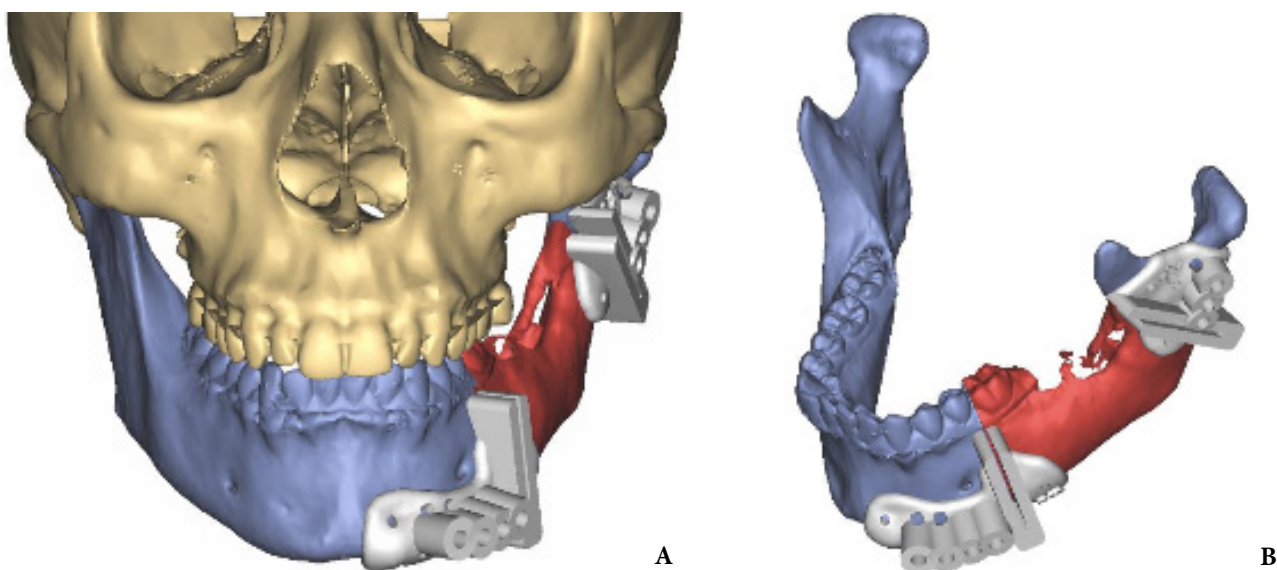
**DISCUSSION**

An implant-supported fixed prosthesis represents a reliable option for stable and functional dental

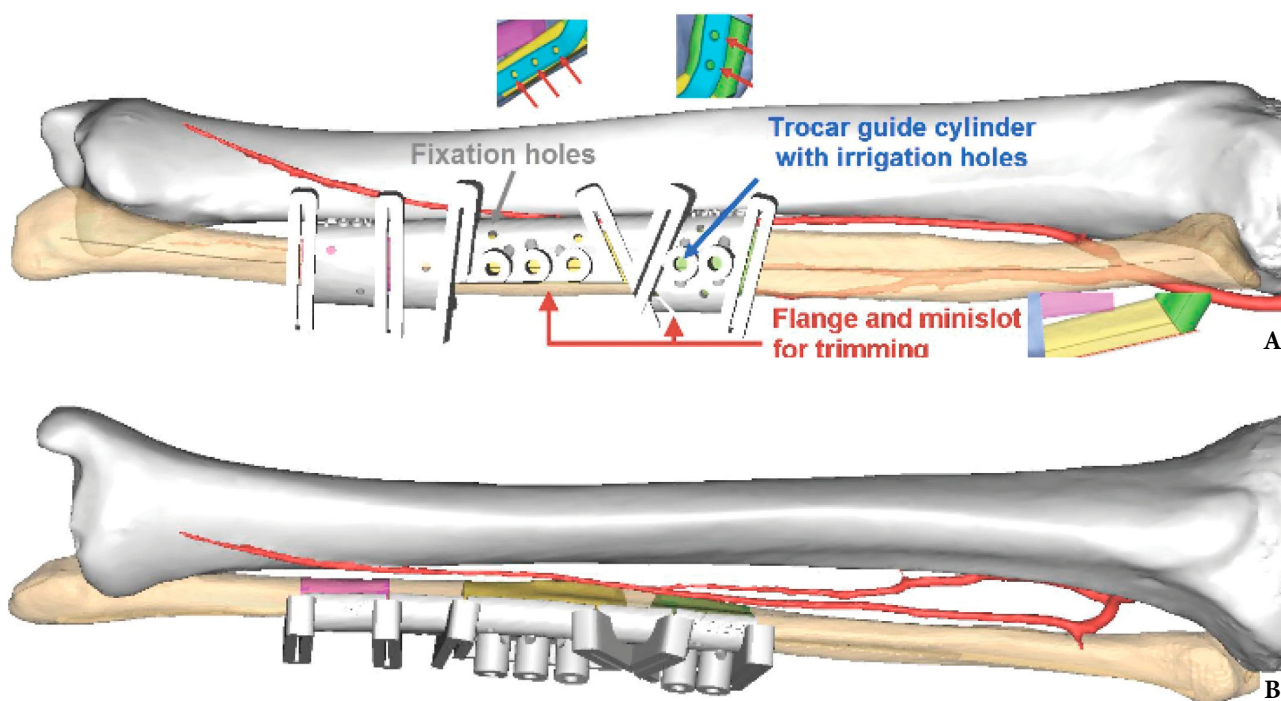
rehabilitation in osseous free flaps<sup>10</sup>. Individually, implant-based dental restorations in patients reconstructed with fibula flaps have been shown to confer many benefits, such as sufficient stabilization of the prosthesis, even in patients with marked irregularities of the hard and soft tissue anatomy, the possibility of compensating for smaller local soft tissues deficiencies, and contributing to an improved aesthetic result (i.e., by supporting the lip profile). Functional aspects, such as chewing, swallowing, and speech, are preserved much better than with conventional dentures. Unfortunately, many problems such as prosthetic guided implant positioning<sup>11,12</sup>, prosthesis encumbrance and soft tissue healing around implants<sup>13</sup>, arise when an implant-based prosthesis is planned for the



**FIGURE 7A-C.** The jaws` plaster models scans were overlay on the preoperative CT mandibular data (A) and then on the mandibular osteotomized planned model (B) in order to preview the future proper position of the dental element in the reconstructed jaw (C).



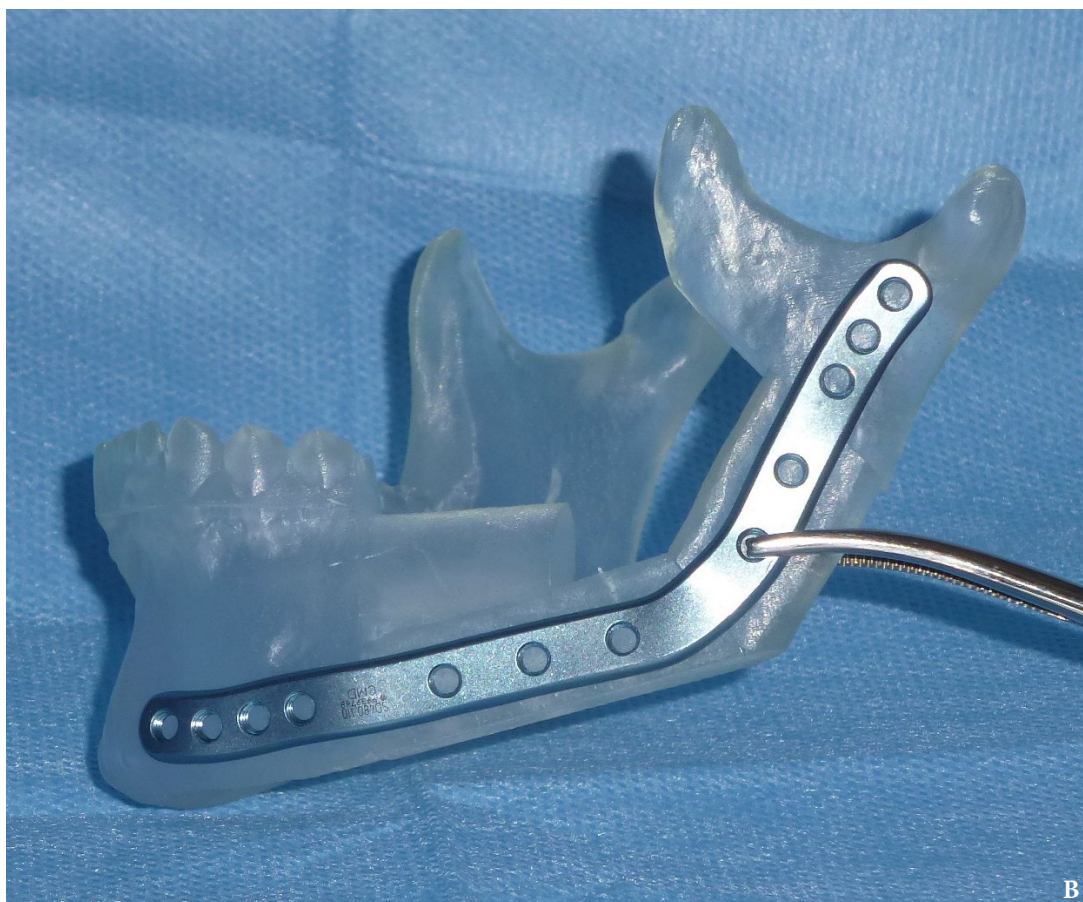
**FIGURE 8A-B.** Virtual surgical planning of patient specific mandible cutting guide.



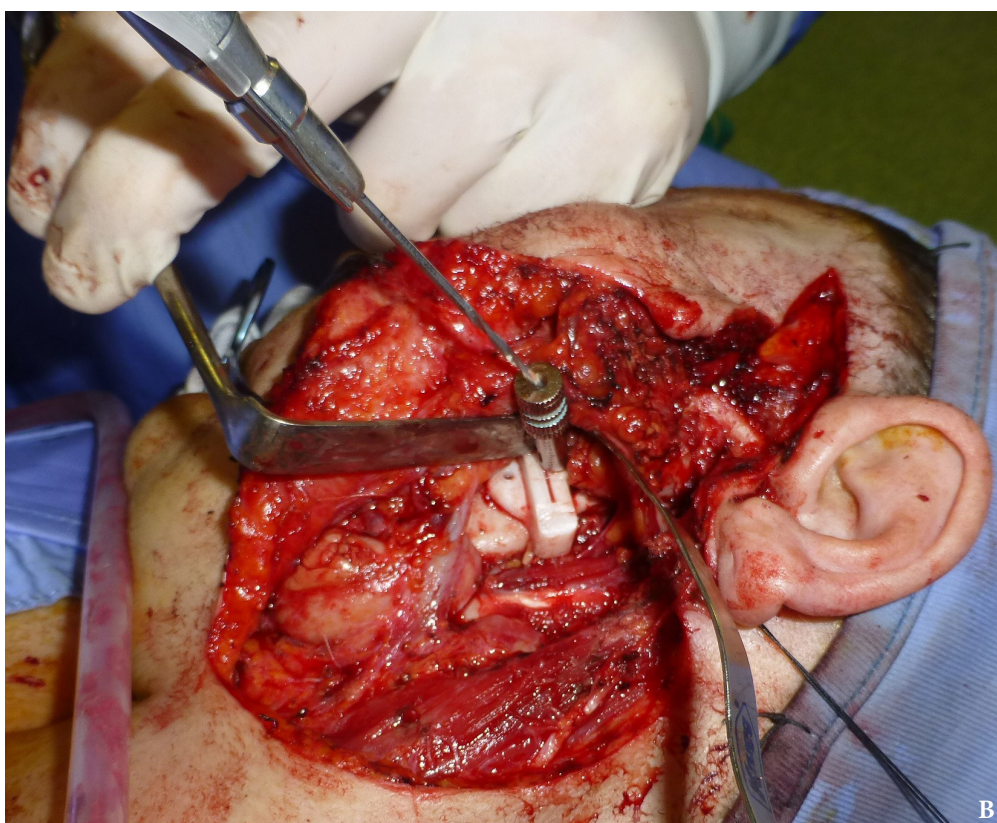
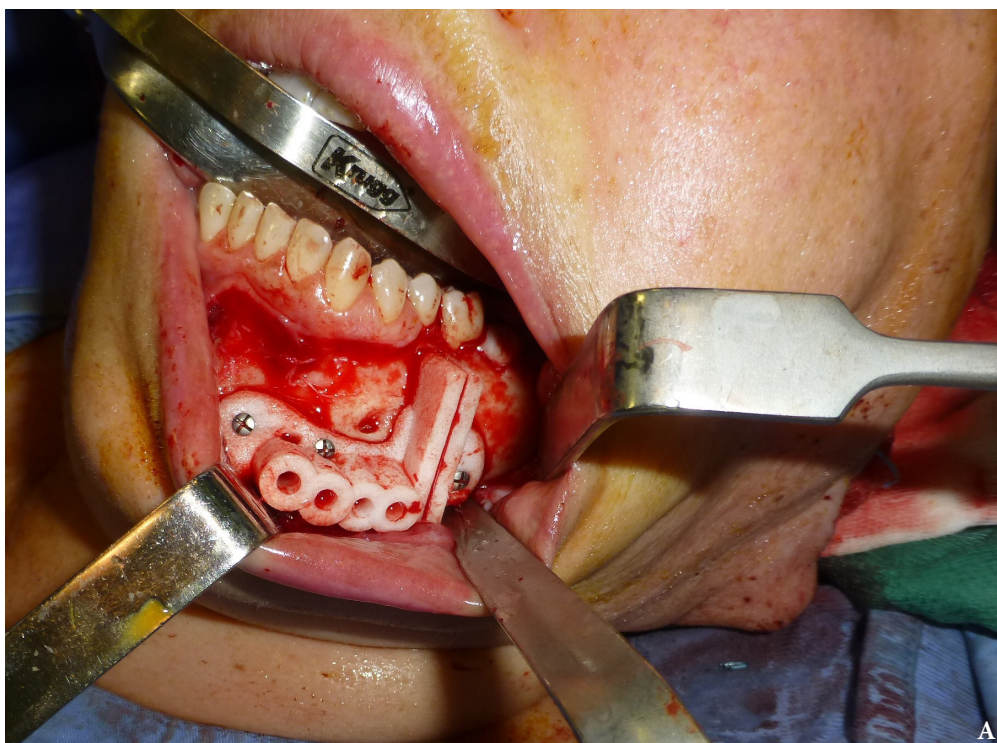
**FIGURE 9A-B.** Planning of a patient specific fibula harvesting guide with a flange and minislots for oblique bone trimming. Image **A** represents lateral view and image **B** – anterior view. Guide design:

- Slot width: 1 mm.
- Trocar guide cylinders: For use with Synthes trocar drill guide 03.503.045 (indicated in *blue*).
- Fixation hole diameter: 2.2 mm (suitable for 1.5 mm drill, 2.0 mm screws) (indicated in *gray*).
- Fixation holes are intended for temporary fixation of the guide.

THE "BEVELED ONE-AND-A-HALF-BARREL" FIBULA TRANSPLANT

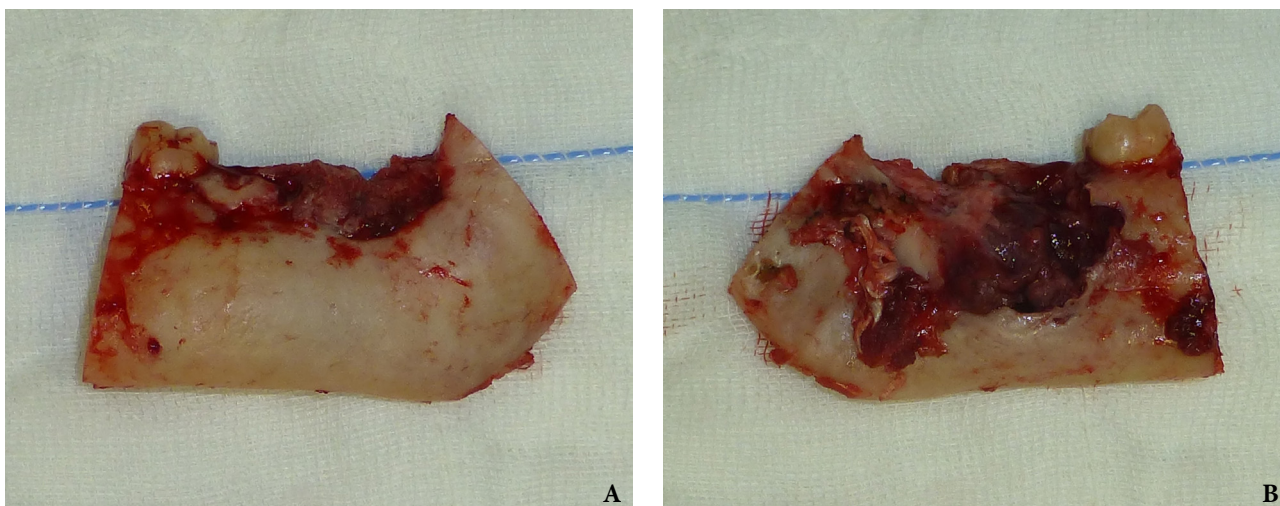


**FIGURE 10A-B.** Patient specific fibula harvesting guide with a flange and minislot for oblique bone trimming (**A**) and a stereolithographic model with a patient-specific plate (**B**).

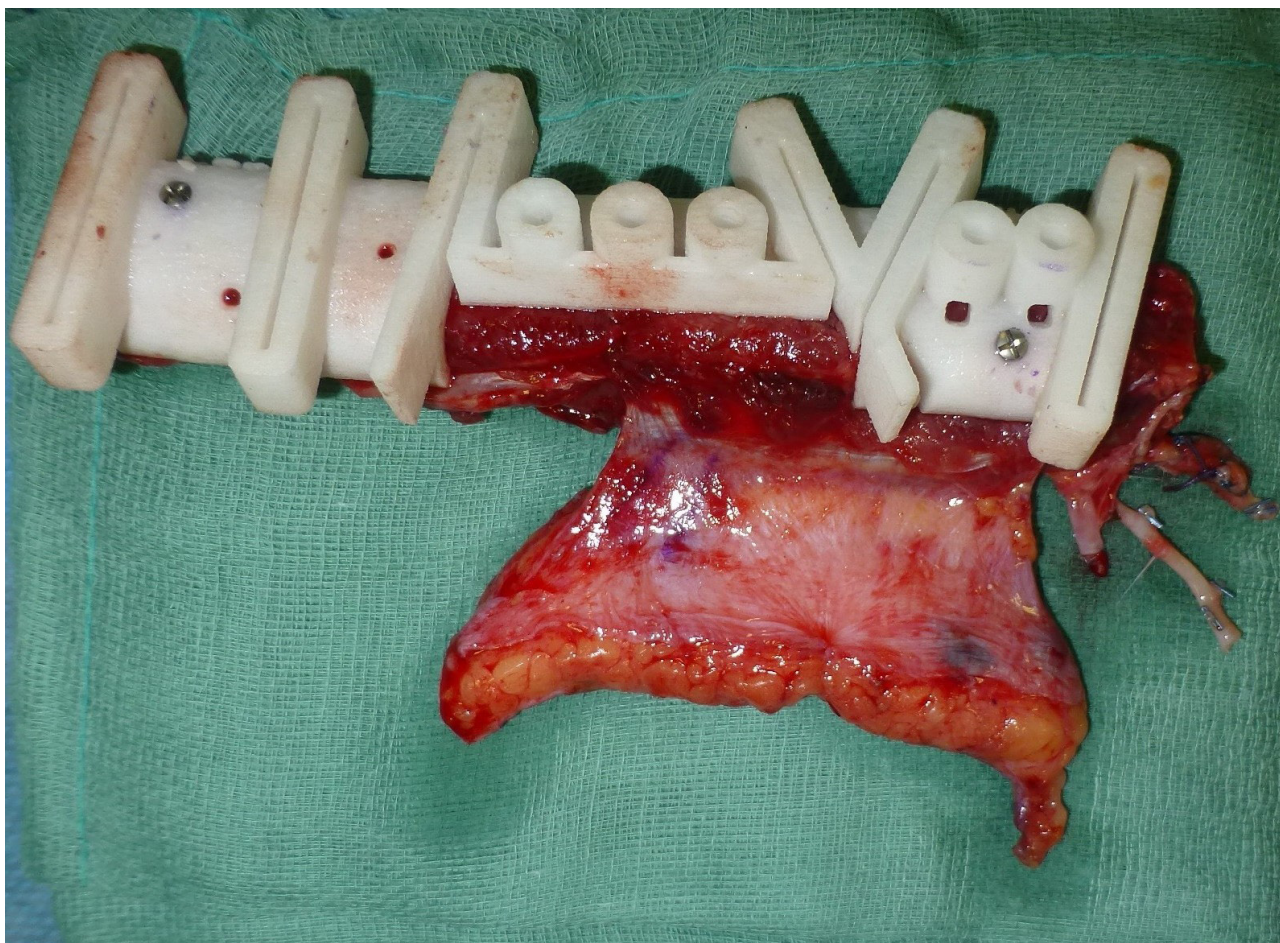


**FIGURE 11A-B.** Resection was performed using a combined intraoral (A) and external preauricular (B) approach.

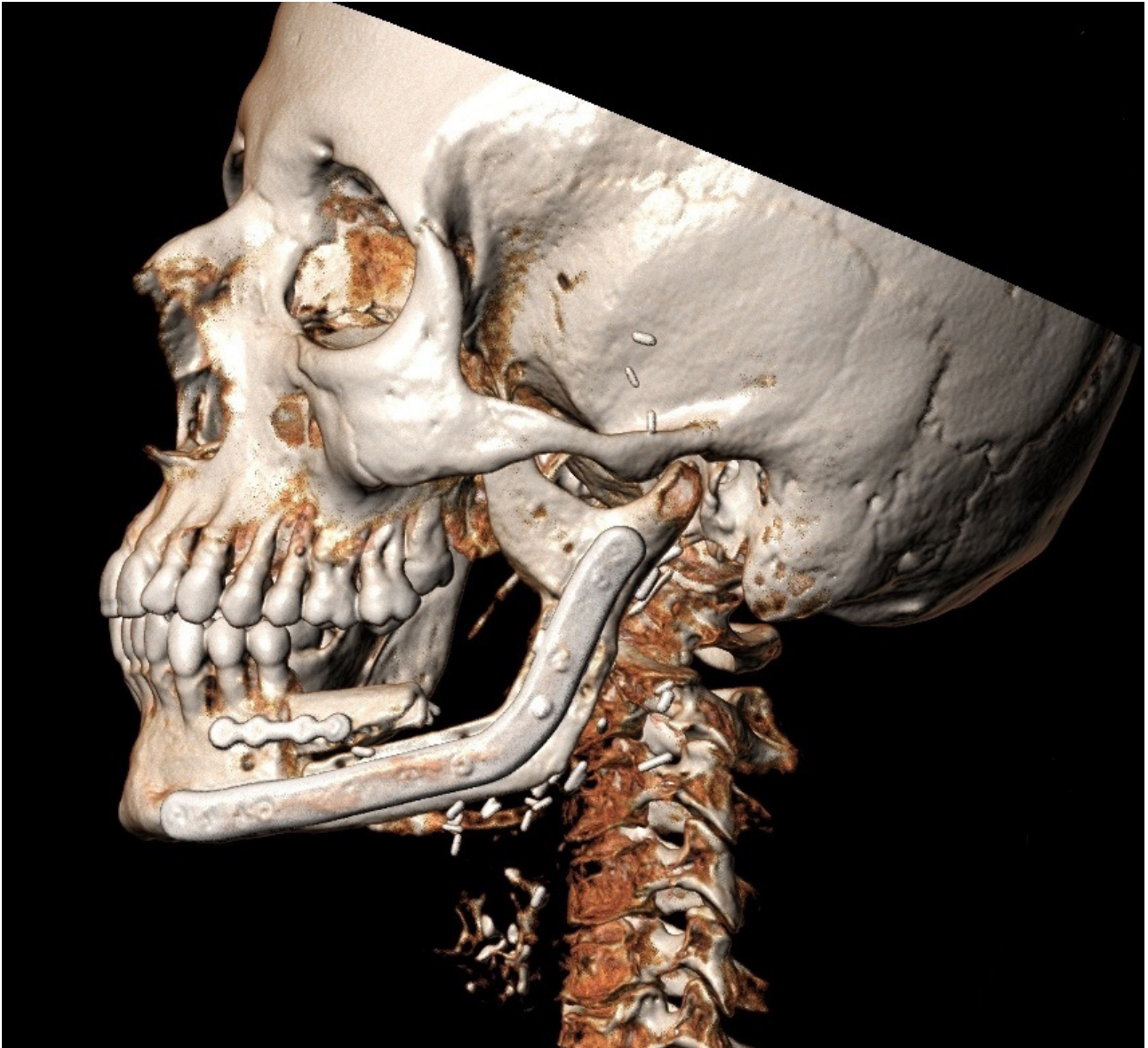THE "BEVELED ONE-AND-A-HALF-BARREL" FIBULA TRANSPLANT



**FIGURE 12A-B.** Buccal (A) and lingual (B) view of the surgical specimen consisting of a jaw segment with the lesion and associated tooth. Specimen was found to have tumor-free margins.

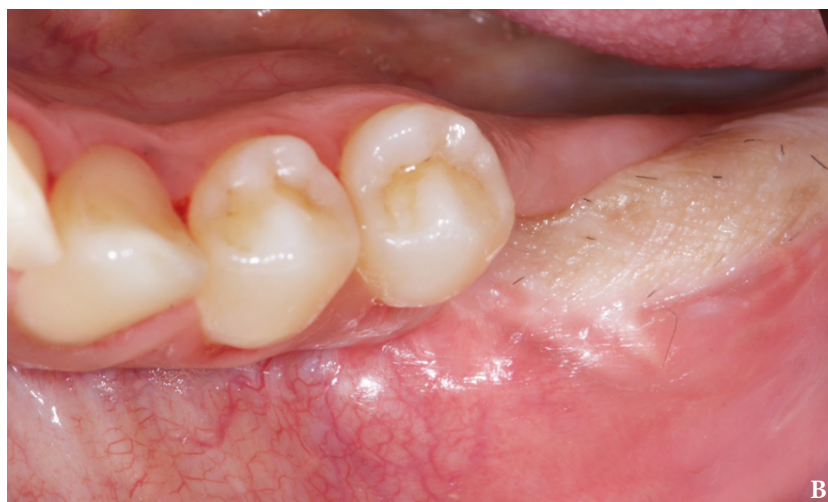
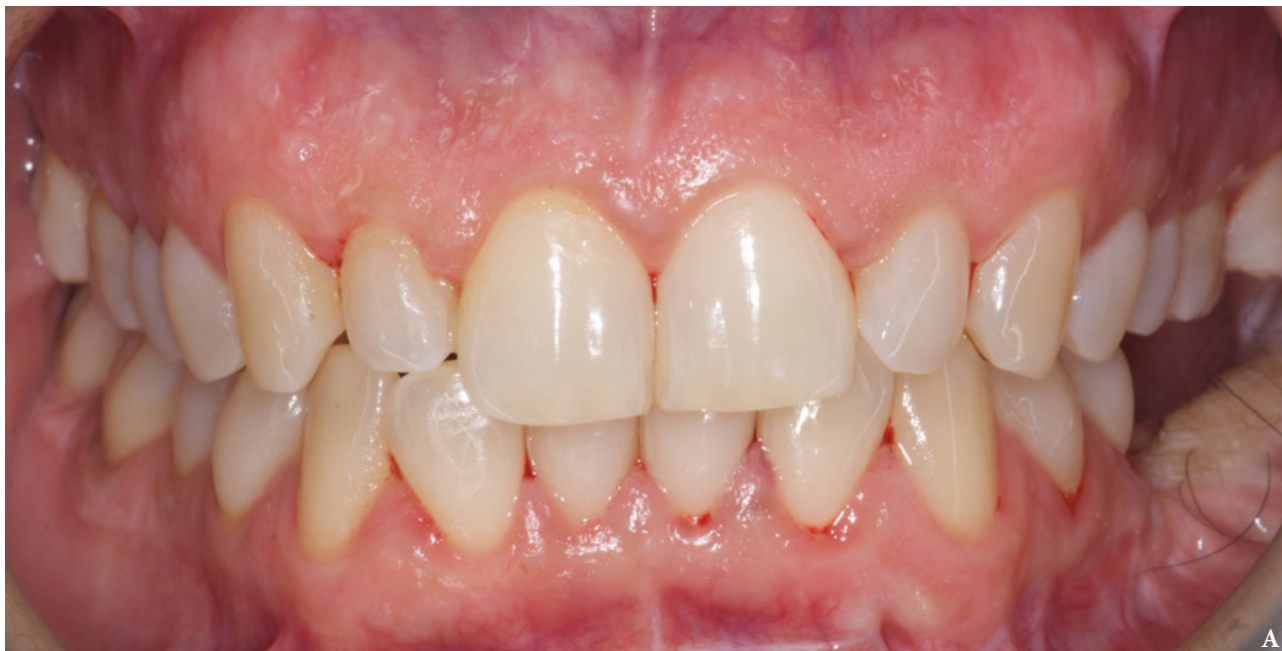
**FIGURE 13.** The osteo-fasciocutaneous beveled one-and-a-half-barrel fibular transplant was harvested thanks to the planned fibula guide.

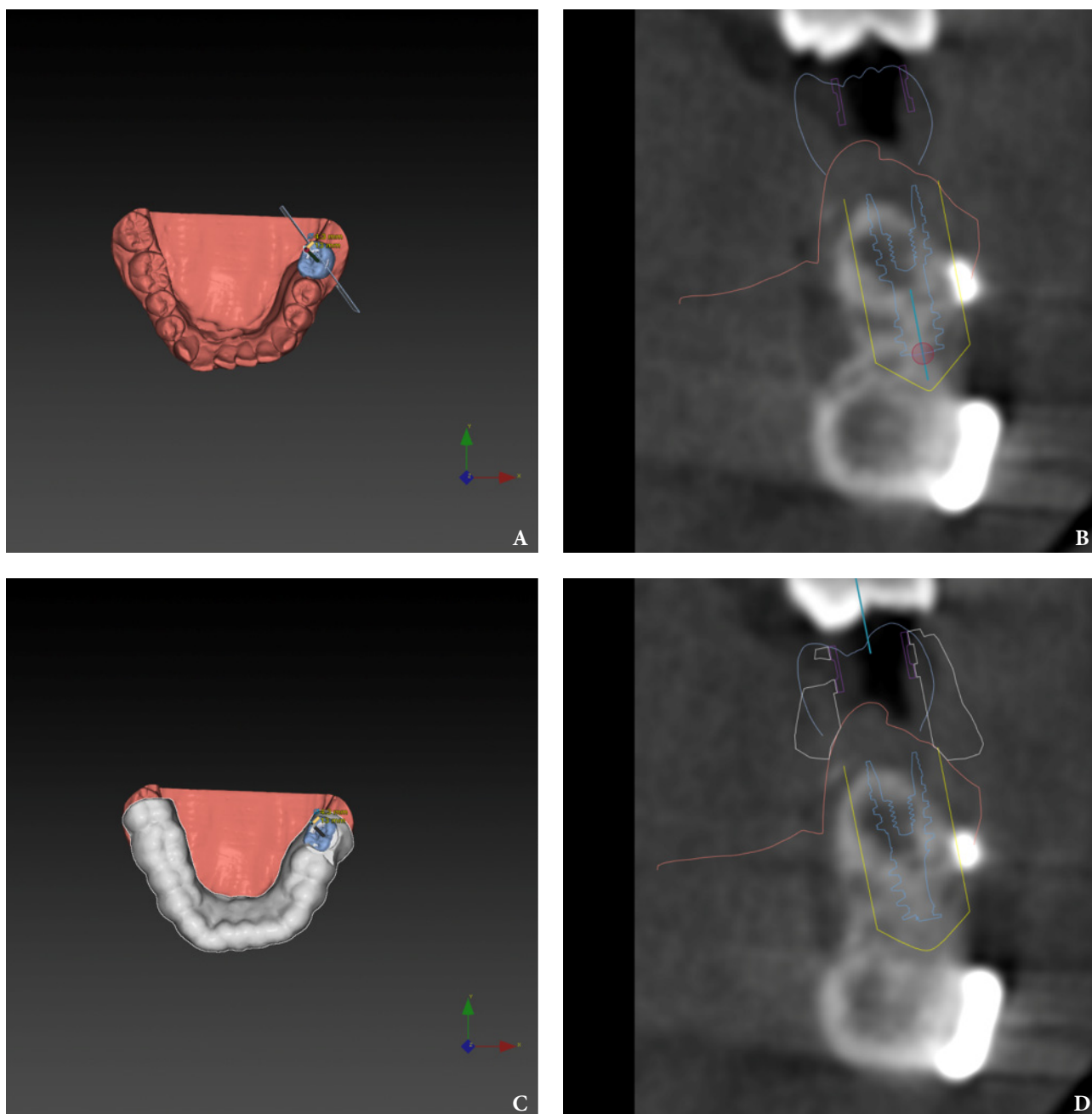


**FIGURE 14.** Post-operative 3-dimensional CT shows complete survival of beveled one-and-a-half-barrel fibular transplant with proper height of alveolar ridge together with a good anatomical shape of mandibular angle and inferior border.



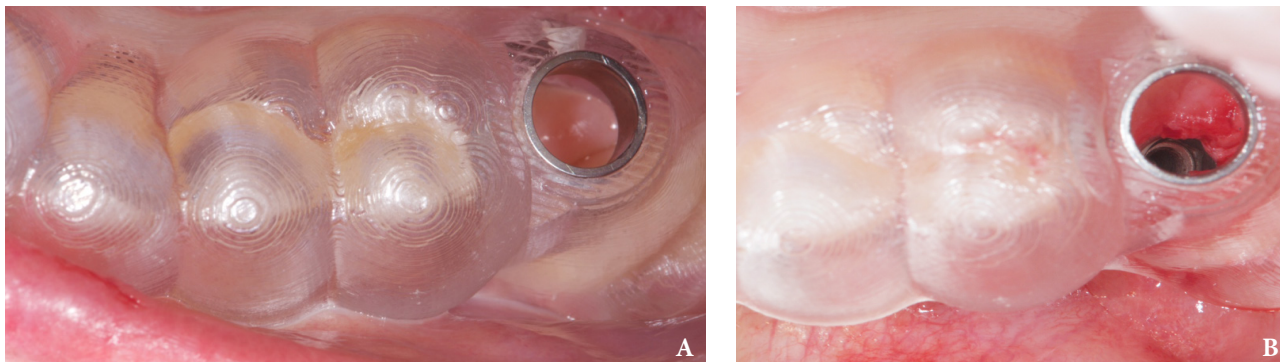


**FIGURE 15A-B.** The post-operative period was uneventful and the intraoral healing was excellent with adequate posterior restorative space re-established.

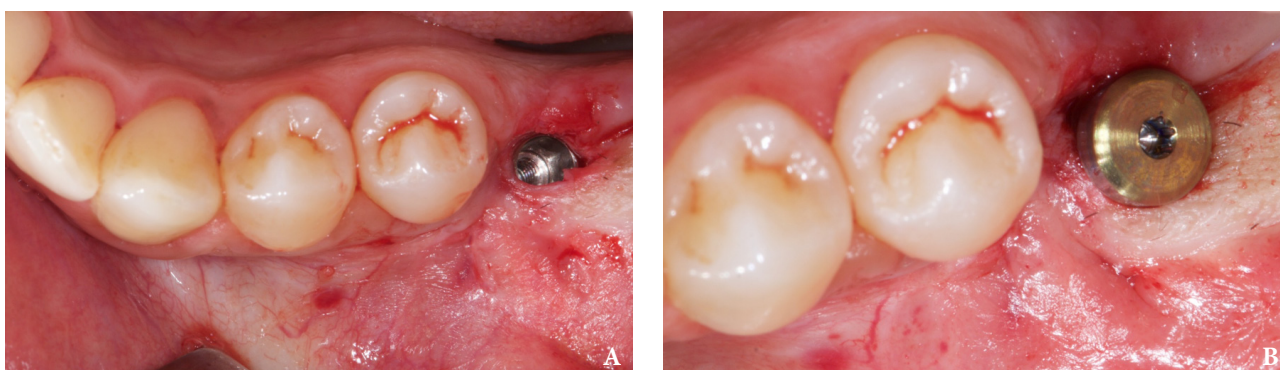


**FIGURE 16A-D.** The CT virtual implant planning allowed the insertion of implants while avoiding screws and the plate in the fibular flap.

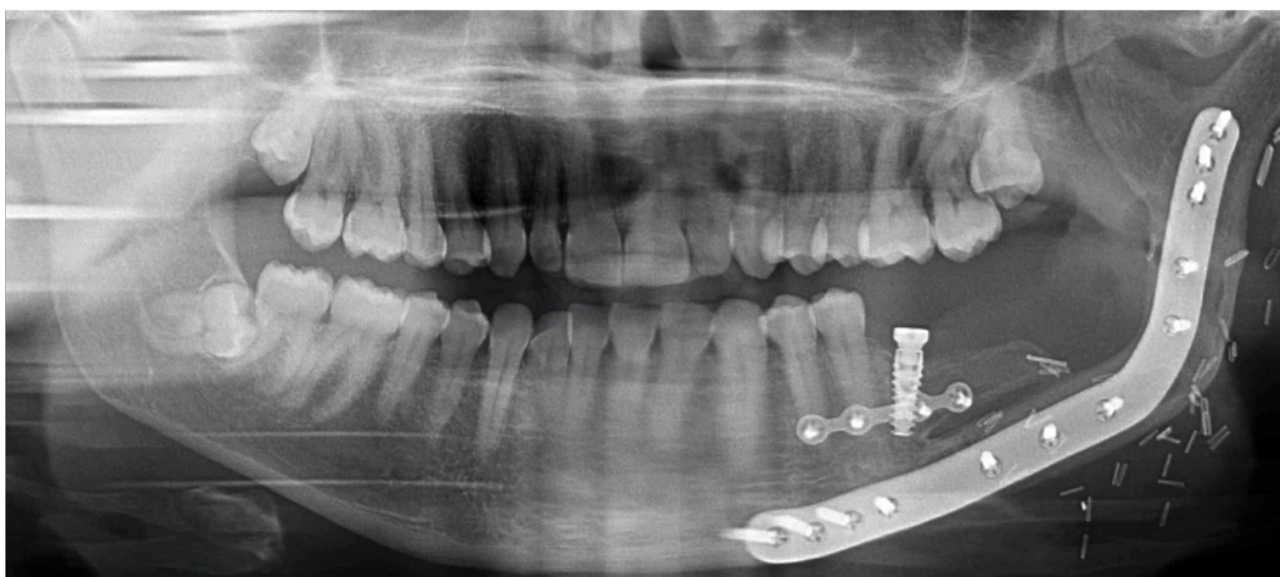
THE "BEVELED ONE-AND-A-HALF-BARREL" FIBULA TRANSPLANT



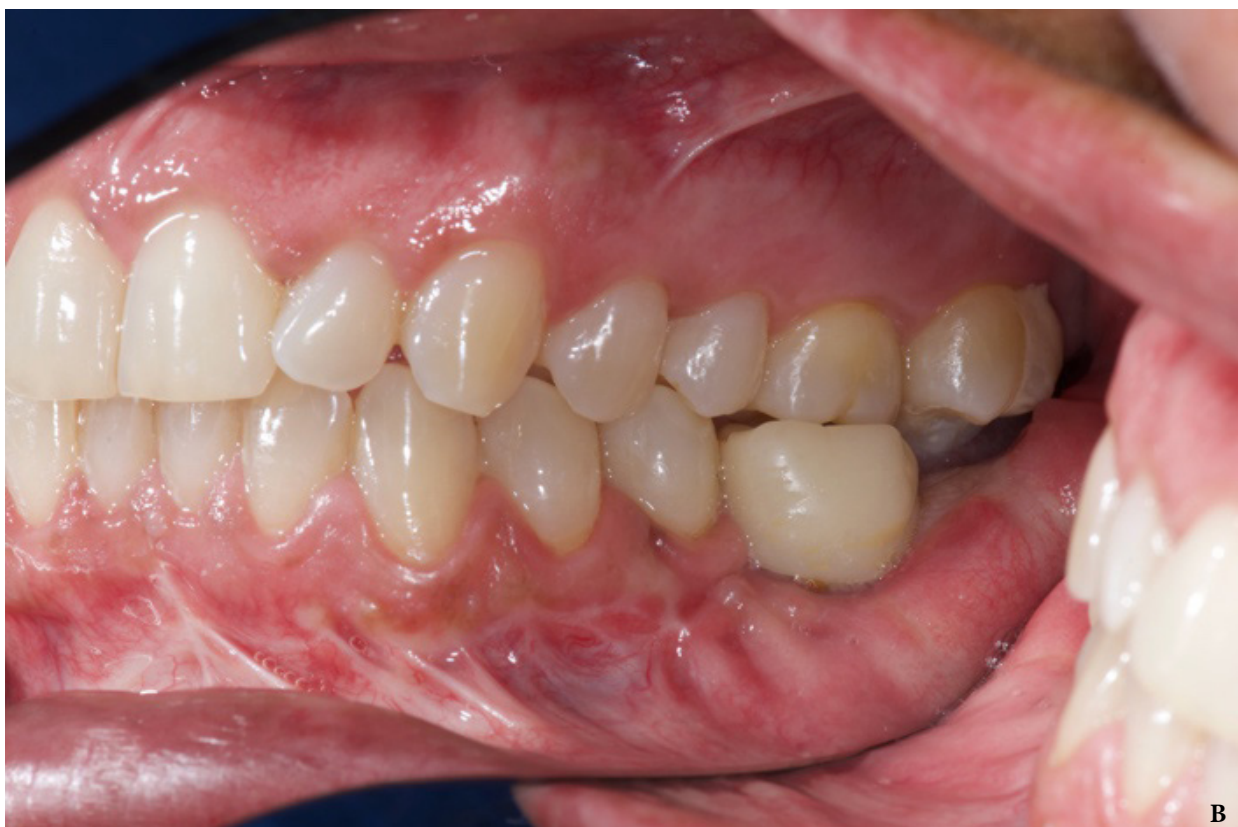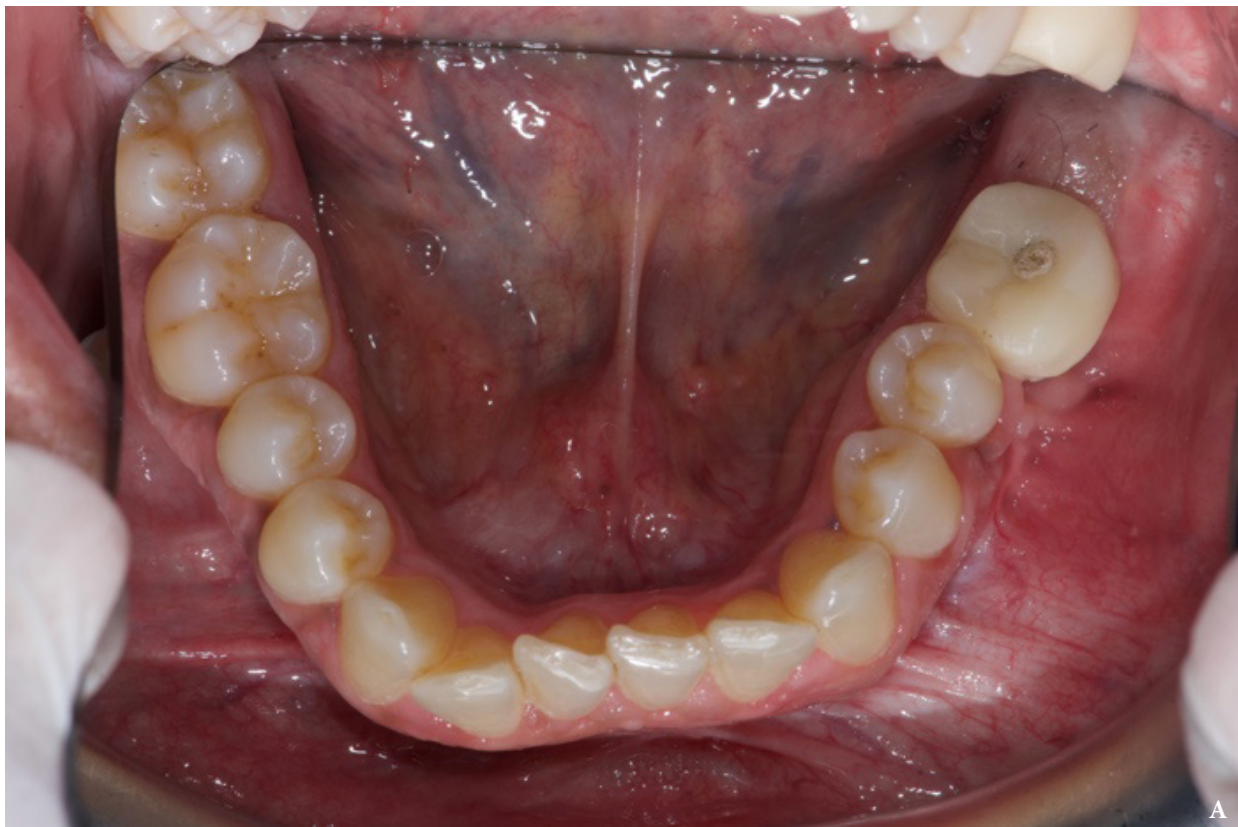**FIGURE 17A-B.** Metal and acrylic resin provisional prosthesis was manufactured.



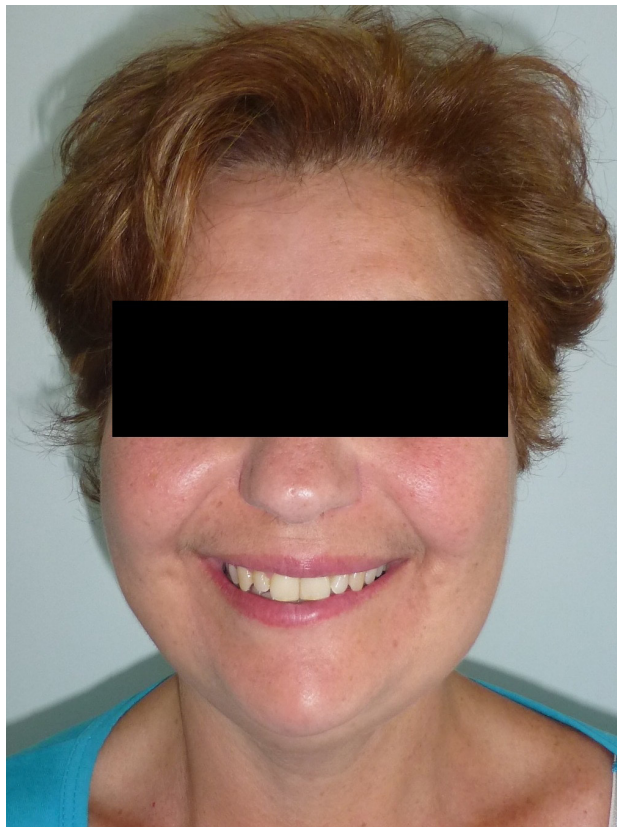**FIGURE 18A-B.** Placement of flapless dental implant into beveled one-and-a-half-barrel fibula mandible.



**FIGURE 19.** Panoramic radiography demonstrates position of flapless dental implant in the left mandible reconstructed with a beveled one-and-a-half-barrel fibula transplant.



**FIGURE 20A-B.** A zirconium oxide crown was performed as a final dental restoration.



**FIGURE 21.** View at 5-year follow-up after rehabilitation by beveled one-and-a-half-barrel fibula transplant and CT-guided secondary dental implantation; the patient fully satisfied.

rehabilitation of these patients<sup>14</sup>. These problems have been partially overcome with the use of computer guided implant placement in patients reconstructed with osseous free flaps with highly predictive dental implantation<sup>15-17</sup>.

Despite these improvements in oral dental rehabilitation it is very difficult to correct an insufficient or too large intermaxillary space, especially in the premolar region due to its particular shape. Usually the vertical occlusal dimension provides a minimum interocclusal distance of 2-4 mm, but it is difficult to predict in advance.

Failure to provide a sufficient prosthetic space may lead to discomfort, pain, and bone resorption while excessive free-way space may lead to discomfort from the temporomandibular joints, cheek-biting, angular cheilitis, and poor appearance<sup>18</sup>.

The main limiting feature of FFF therefore remains the residual discrepancy between native jaw and fibula graft, which causes aesthetic and functional problems.<sup>7,9,17</sup>

The fibula flap placement at the inferior border

of the mandible yields excellent skeletal and soft-tissue contour but results in implant overloading, compromising long-term success.

In fact, the low height of the newly reconstructed mandible or maxillary bone leads to the need to use longer abutments to restore the occlusion, but in the same way excessive chewing forces will be discharged on the above abutments, the crown-implant relationship becomes unfavorable, which will produce instability of the same and invalidate the prosthetic-implant rehabilitation.<sup>19</sup> To solve this problem, many surgeons have been driven to use one of following techniques: (1) placement of the fibula 0.5 to 1 cm higher than the inferior border of the remaining mandible in a functional relationship with the maxillary in order to recreate the alveolar ridge height,<sup>20,21</sup> but to the detriment of inferior mandibular contour in which a step deformity remains, especially noticeable after radiotherapy; (2) using a single barrel fibula free flap and a low-profile reconstruction plate with dental implantation<sup>22</sup> to achieve esthetic and functional mandibular reconstruction. However,

this approach is selectively fashioned for patients with benign disease and adequate overlying soft tissue; (3) a double barrel fibular flap design has been proposed<sup>23,24</sup> to overcome this problem, however it may result in excessive height that encroached on the prosthetic space, needing aggressive alveoplasty or extended below the inferior mandible border, worsening the facial height; (4) a 2-struct type of reconstruction in which a conventional vascularized fibular segment was placed at the inferior basal portion and a nonvascularized residual fibular segment<sup>4</sup> or an iliac onlay bone graft<sup>25</sup> was placed on the top of the fibula as onlay graft, which may lead to greater height resorption, however, infection and fistula formation, which can be disastrous for the patient if they occur; (5) alveolar vertical distraction of the FFF<sup>5-8,26-29</sup> which, however, is associated with increased bone resorption processes during functional loading.

In every way the prosthodontic space, especially in the posterior mandibular area, may be excessively large or too small for proper occlusal guidance and dental restoration using traditional mandibular reconstruction techniques with single or double-barreled FFF even if vertical distraction is performed.

In 2013, a surgical team from Turkey<sup>9</sup> described a new technique for restoring the height in the posterior fibular jaw area. A vascularized fibular flap was harvested and shaped so that a small piece of bone was removed in the middle to allow folding the flap, as usually done for a double-barrel technique. However, the distal half of the flap has been split longitudinally, and the bone segment away from the perforator vessels was removed. Then two remaining fibula segments, i.e. the “basal” and the split one, were folded and placed in parallel fashion to fit the defect. This technique was named by the authors “one-and-a-half-barrel” fibula free flap. Although it is a brilliant adaptive technique to solve the previous techniques disadvantages, we believe that the parallel orientation of the two pieces of the fibula leads to a still too high reconstruction that interferes with an adequate prosthetic restoration in premolar-molar area. Furthermore, the authors described the placement of three fixtures in their transplant, one year after removal removing the rigid internal fixation materials, but the description of planning and implant surgical procedure lacks technical details.

In 2022, a novel one-stage method for composite

lateral head and neck reconstructions was introduced<sup>30</sup>. The report is illustrating how the chimeric lateral supramalleolar artery perforator (LSMAP) FFF<sup>31</sup> can be modeled safely into a double-barrel shape. Although this new harvest technique allows the reconstruction of challenging lateral oro-mandibular defects thanks to raising of two independent skin paddles, the height of the neomandible does not allow adequate prosthetic rehabilitation in the premolar-molar area.

Furthermore, Saito et al<sup>8</sup> appeal to the works of Bähr et al<sup>32</sup> and He et al<sup>33</sup> which stated that the bridging of mandibular defects of >9.0 cm in length is extremely challenging with the double-barrel technique due to the fact that the pedicle may be not long enough to reach the recipient vessels with increased risk of thrombosis by anastomosis with tension or vessels bridging limited fibula length of pedicle.

The possibility to customize the fibula free-flap reconstruction with virtual surgery planning in accordance with a pre-established dental wax-up is in our opinion a fundamental point in order to achieve the best final prosthesis.

The Synthes ProPlan® system allows preoperative planning, the study and production of specific surgical guides for accurate application of the reconstructive surgical plan and the CT guided flapless surgery by the NobelClinician® software allows precise positioning of the implant without the need to remove the plates and bone synthesis screws.

The “beveled one-a-half-barrel” technique combined with CT-guided implant surgery showed its usefulness in our practice.

The combination of these two useful technological tools, together with advanced reconstructive surgical skills, can allow three-dimensional mandibular reconstructions and aesthetic and long-lasting dental rehabilitations.

All fixtures survived. Satisfactory union was achieved in our case with no evidence of recurrence. The patient had adequate cosmetics, masticatory efforts and speech.

Our case have clearly confirmed the possibility of using “beveled one-a-half-barrel” FFF in reconstruction (fibula class 3: two osteotomies)<sup>21</sup> of the long basal bone defect and alveolar bone with a needed length less than 9.0 cm. Comparison of two cases with dental implants placement into one-and-a-half barrel fibula free flaps, “longitudinal” and “beveled” respectively, is depicted in [Table 1](#).

**TABLE 1.** Comparison of Two Cases with Dental Implants Placement into Longitudinal One-and-a-Half-Barrel Fibula Free Flap and into Beveled One-and-a-Half-Barrel Fibula Free Flap.

#	Cases	Year of Surgery	Patient Age/Sex	Diagnosis	Location of Mandibular Defect According to Jewer Classification	No. of 'Basal' Barrels	Length of the 'Alveolar' Barrel	No. of Bone Surfaces with which an 'Alveolar' Barrel Contacts	Height of the Fixed 'Alveolar' Barrel in Anterior-Posterior Direction	Type of fixation of the 'Alveolar' Barrel	No. of Inserted Implants into 'Alveolar' Barrel	Timing of Implant Placement (Months) after FFF	Implant Failures   Peri-Implant Radiolucency   Follow-up (months)
1	Case of Ulkur et al <sup>9</sup>	2011	23/M	Giant cell reparative granuloma of the right mandible	Lateral right side defect	1	8.0 cm	Three: <ul style="list-style-type: none"> <li>• Surface of the mandible in the area of distal part of canine.</li> <li>• Anterior surface of ascending ramus.</li> <li>• Superior surface of the 'basal' barrel</li> </ul>	Height is similar	Rigid fixation (with no data about type of plates)	2	18 months	No   No   20 months
2	Our case	2016	49/F	Recurrence of aggressive ameloblastoma of the left mandibular trigone	Lateral left side defect	2	2.2 cm	Two: <ul style="list-style-type: none"> <li>• Surface of the mandible in the area of distal part second premolar.</li> <li>• Superior surface of the anterior 'basal' barrel</li> </ul>	Height is decreased with a purpose of better corresponding to occlusal plane. It was achieved using modified bevel.	A straight four-holes titanium miniplate was fixed to the alveolar bone portion of the native mandible and a reconstructive titanium plate was fixed at the basal bone	1	14 months	No   No   60 months

Based on the present study, the authors found that using the customized “beveled one-and-a-half barrel” FFF for the reconstruction of the posterior segmental mandible should be considered a cutting-edge technique that allows easily to follow the ideal position of the occlusal plane making the fixtures implantation more precise and long-lasting, markedly improving the facial symmetry and lower face plumpness in patients.

### PATIENT CONSENT

The patient provided written consent for the use of her images.

### AUTHOR CONTRIBUTIONS

Conceptualization: Massarelli O. Data acquisition: Meloni SM, Massarelli O. Data analysis, interpretation, and drafting of the manuscript: Massarelli O. Critical revision of the manuscript: Massarelli O, Meloni SM. Approval of the final version of the manuscript: both authors.

### ACKNOWLEDGMENTS

We would like to thank Todd C. Hanna, MD, DDS, FACS from New York, New York, United States of America for the kind support in preparing the manuscript.

### REFERENCES (33)

- Hidalgo DA. Fibula free flap: a new method of mandible reconstruction. *Plast Reconstr Surg* **1989**;84(1):71–9.
- Sadove RC, Powell LA. Simultaneous maxillary and mandibular reconstruction with one free osteocutaneous flap. *Plast Reconstr Surg* **1993**;92(1):141–6.  
<https://doi.org/10.1097/00006534-199307000-00022>
- Horiuchi K, Hattori A, Inada I, Kamibayashi T, Sugimura M, Yajima H, Tamai S. Mandibular reconstruction using the double barrel fibular graft. *Microsurgery* **1995**;16(7):450–4.  
<https://doi.org/10.1002/micr.1920160704>
- Lee JH, Kim MJ, Choi WS, Yoon PY, Ahn KM, Myung H, Hwang SJ, Seo BM, Choi JY, Choung PH, Kim SM. Concomitant reconstruction of mandibular basal and alveolar bone with a free fibular flap. *Int J Oral Maxillofac Surg* **2004**;33(2):150–6.  
<https://doi.org/10.1054/ijom.2003.0487>
- Siciliano S, Lengelé B, Reyhler H. Distraction osteogenesis of a fibula free flap used for mandibular reconstruction: preliminary report. *J Craniomaxillofac Surg* **1998**;26(6):386–90.  
[https://doi.org/10.1016/s1010-5182\(98\)80072-3](https://doi.org/10.1016/s1010-5182(98)80072-3)
- Ortakoglu K, Suer BT, Ozyigit A, Ozen T, Sencimen M. Vertical distraction osteogenesis of fibula transplant for mandibular reconstruction: a case report. *Oral Surg Oral Med Oral Pathol Oral Radiol Endod* **2006**;102(4):e8–11.  
<https://doi.org/10.1016/j.tripleo.2006.01.020>
- Cho-Lee GY, Naval-Gías L, Martos-Díaz PL, González-García R, Rodríguez-Campo FJ. Vertical distraction osteogenesis of a free vascularized fibula flap in a reconstructed hemimandible for mandibular reconstruction and optimization of the implant prosthetic rehabilitation. Report of a case. *Med Oral Patol Oral Cir Bucal* **2011**;16(1):e74–8.  
<https://doi.org/10.4317/medoral.16.e74>
- Saito N, Funayama A, Arai Y, Suda D, Takata Y, Kobayashi T. Vertical distraction osteogenesis of a reconstructed mandible with a free vascularized fibula flap: a report of two cases. *Maxillofac Plast Reconstr Surg* **2018**;40(1):32.  
<https://doi.org/10.1186/s40902-018-0172-2>
- Ulkur E, Karagoz H, Kulahci Y, Suer BT, Oksuz S, Kocyigit ID, Acikel C, Urhan M. One-and-a-half-barrel vascularized free fibular flap for the reconstruction of segmental mandibular defect. *J Craniofac Surg* **2013**;24(2):e167–9.  
<https://doi.org/10.1097/SCS.0b013e31827c840f>
- Massarelli O, Hanna TC, Ganry L, Nagorniak IV, Fesenko II. Impact of surgeon’s Instagram television (IGTV): a case of chimeric fibula and soleus muscle transplant in a reconstruction of Cordeiro type IIIA total maxillectomy defect. *J Diagn Treat Oral Maxillofac Pathol* **2020**;4(1):3–20.  
<https://doi.org/10.23999/j.dtopm.2020.1.1>
- Iizuka T, Häfliger J, Seto I, Rahal A, Mericske-Stern R, Smolka K. Oral rehabilitation after mandibular reconstruction using an osteocutaneous fibula free flap with endosseous implants. Factors affecting the functional outcome in patients with oral cancer. *Clin Oral Implants Res* **2005**;16(1):69–79.  
<http://doi.org/10.1111/j.1600-0501.2004.01076.x>
- Hayter JP, Cawood JI. Oral rehabilitation with endosteal implants and free flaps. *Int J Oral Maxillofac Surg* **1996**;25(1):3–12.  
[https://doi.org/10.1016/S0901-5027\(96\)80004-X](https://doi.org/10.1016/S0901-5027(96)80004-X)
- Meloni SM, Tallarico M, Canullo L, De Riu G., Massarelli O. Periimplant soft-tissue management in patients with a fibula free flap reconstruction: case series and description of a new technique. *J Oral Science Rehabil* **2016**;2(4):26–30.
- Fernandes RP, Quimby A, Salman S. Comprehensive reconstruction of mandibular defects with free fibula



- flaps and endosseous implants. *J Diagn Treat Oral Maxillofac Pathol* **2017**;1(1):6–10.  
<https://doi.org/10.23999/j.dtmp.2017.1.1>
15. De Riu G, Meloni SM, Pisano M, Massarelli O, Tullio A. Computed tomography-guided implant surgery for dental rehabilitation in mandible reconstructed with a fibular free flap: description of the technique. *Br J Oral Maxillofac Surg* **2012**;50(1):30–5.  
<https://doi.org/10.1016/j.bjoms.2010.11.012>
  16. Meloni SM, De Riu G, Pisano M, Massarelli O, Tullio A. Computer assisted dental rehabilitation in free flaps reconstructed jaws: one year follow-up of a prospective clinical study. *Br J Oral Maxillofac Surg* **2012**;50(8):726–31.  
<https://doi.org/10.1016/j.bjoms.2011.12.006>
  17. Meloni SM, Tallarico M, De Riu G, Pisano M, Deledda A, Lolli FM, Massarelli O, Tullio A. Guided implant surgery after free-flap reconstruction: four-year results from a prospective clinical trial. *J Craniomaxillofac Surg* **2015**;43(8):1348–55.  
<https://doi.org/10.1016/j.jcms.2015.06.046>
  18. Jensen WO. Occlusion for the class II jaw relations patient. *J Prosthet Dent* **1990**;64(4):432–4.  
[https://doi.org/10.1016/0022-3913\(90\)90039-f](https://doi.org/10.1016/0022-3913(90)90039-f)
  19. Chen J, Yin P, Li N, Wu L, Jian X, Jiang C. Functional mandibular reconstruction with double-barrel fibular flap and primary osseointegrated dental implants improve facial esthetic outcome. *J Oral Maxillofac Surg* **2019**;77(1):218–25.  
<https://doi.org/10.1016/j.joms.2018.08.008>
  20. Wei FC, Santamaria E, Chang YM, Chen HC. Mandibular reconstruction with fibular osteoseptocutaneous free flap and simultaneous placement of osseointegrated dental implants. *J Craniomaxillofac Surg* **1997**;8(6):513–21.  
<https://doi.org/10.1097/00001665-199711000-00018>
  21. Smolka K, Kraehenbuehl M, Eggensperger N, Hallermann W, Thoren H, Iizuka T, Smolka W. Fibula free flap reconstruction of the mandible in cancer patients: evaluation of a combined surgical and prosthodontic treatment concept. *Oral Oncol* **2008**;44(6):571–81.  
<https://doi.org/10.1016/j.oraloncology.2007.07.005>
  22. Shen YF, Rodriguez ED, Wei FC, Tsai CY, Chang YM. Aesthetic and functional mandibular reconstruction with immediate dental implants in a free fibular flap and a low-profile reconstruction plate: five-year follow-up. *Ann Plast Surg* **2015**;74(4):442–6.  
<https://doi.org/10.1097/sap.0b013e3182a0dedf>
  23. Chang YM, Wallace CG, Tsai CY, Shen YF, Hsu YM, Wei FC. Dental implant outcome after primary implantation into double-barreled fibula osteoseptocutaneous free flap-reconstructed mandible. *Plast Reconstr Surg* **2011**;128(6):1220–8.  
<https://doi.org/10.1097/prs.0b013e318230c6a9>
  24. Chang YM, Tsai CY, Wei FC. One-stage, double-barrel fibula osteoseptocutaneous flap and immediate dental implants for functional and aesthetic reconstruction of segmental mandibular defects. *Plast Reconstr Surg* **2008**;122(1):14–5.  
<https://doi.org/10.1097/PRS.0b013e3181774135>
  25. Kreuzsch T, Kersch A, Behrens E. Maxillary and mandibular reconstruction with bone sandwich plasty and implants. Presented at the 8th International Congress on Reconstructive Preprosthetic Surgery; San Diego, CA; April 15, **1999**.
  26. Cheung LK, Chua HD, Hariri F, Pow EH, Zheng L. Alveolar distraction osteogenesis for dental implant rehabilitation following fibular reconstruction: a case series. *J Oral Maxillofac Surg* **2013**;71(2):255–71.  
<https://doi.org/10.1016/j.joms.2012.09.028>
  27. Chiapasco M, Brusati R, Galioto S. Distraction osteogenesis of a fibular revascularized flap for improvement of oral implant positioning in a tumor patient: a case report. *J Oral Maxillofac Surg* **2000**;58(12):1434–40.  
<https://doi.org/10.1053/joms.2000.16632>
  28. Nocini PF, Wangerin K, Albanese M, Kretschmer W, Cortelazzi R. Vertical distraction of a free vascularized fibula flap in a reconstructed hemimandible: case report. *J Craniomaxillofac Surg* **2000**;28(1):20–4.  
<https://doi.org/10.1054/jcms.2000.0106>
  29. Wang F, Huang W, Zhang C, Sun J, Kaigler D, Wu Y. Comparative analysis of dental implant treatment outcomes following mandibular reconstruction with double-barrel fibula bone grafting or vertical distraction osteogenesis fibula: a retrospective study. *Clin Oral Implants Res* **2015**;26(2):157–65.  
<https://doi.org/10.1111/clr.12300>
  30. Massarelli O. Chimeric LSMAP double-barrel fibula free flap: goal-oriented surgical technique and tips for one-stage mandibular reconstruction. *Plast Reconstr Surg Glob Open* **2022**;10(1):e4040.  
<https://doi.org/10.1097/GOX.0000000000004040>
  31. Massarelli O, Gobbi R, Biglio A, Soma D, Tullio A. Chimeric lateral supramalleolar artery perforator fibula free flap in the reconstruction of composite head and neck defects. *Plast Reconstr Surg* **2014**;133(1):130–6.  
<https://doi.org/10.1097/01.prs.0000435845.33670.64>
  32. Bähr W, Stoll P, Wachter R. Use of the “double barrel” free vascularized fibula in mandibular reconstruction. *J Oral Maxillofac Surg* **1998**;56(1):38–44.  
[https://doi.org/10.1016/S0278-2391\(98\)90914-4](https://doi.org/10.1016/S0278-2391(98)90914-4)
  33. He Y, Zhang ZY, Zhu HG, Wu YQ, Fu HH. Double-barrel fibula vascularized free flap with dental rehabilitation for mandibular reconstruction. *J Oral Maxillofac Surg* **2011**;69(10):2663–9.  
<https://doi.org/10.1016/j.joms.2011.02.051>

# U-Impl<sup>®</sup>

SWITZERLAND



№ R3M 804 252 B2

Сертифікат відповідності  
технічного регламенту  
щодо медичних виробів



Switzerland Aarbergerstrasse 107A, CH-2502  
Biel, Phone/Fax +41 323230188  
info@u-impl.com  
www.u-impl.com