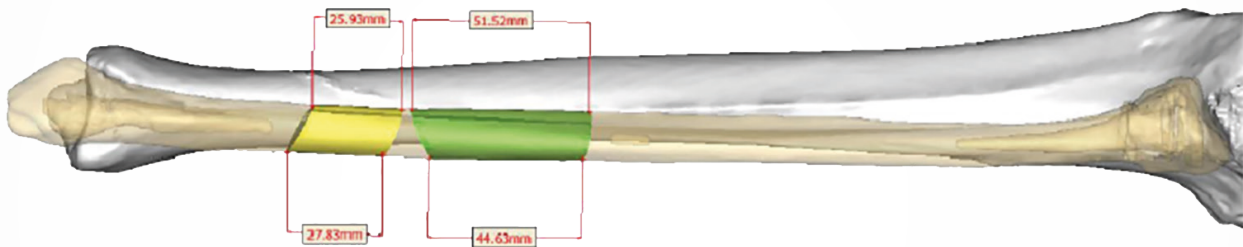


Journal of

# DIAGNOSTICS & TREATMENT

of Oral & Maxillofacial Pathology

5<sup>2019</sup>



**31<sup>st</sup> World Congress  
of the International College for  
Maxillo-Facial-Surgery**

In Conjunction with the **Annual Conference of the  
Israeli Association for Oral and Maxillofacial Surgery**

October 29 - November 1, 2019 | Hilton Hotel, Tel Aviv, Israel



Deputy Editor in Chief and  
Section Editor–Microvascular Surgery  
Rui P. Fernandes (Jacksonville, FL, USA)



Official Journal of the  
Ukrainian Association for  
Maxillofacial and Oral Surgeons

# U-Impl<sup>®</sup>

SWITZERLAND



№ R3M 804 252 B2

Сертифікат відповідності  
технічного регламенту  
щодо медичних виробів



Switzerland Aarbergerstrasse 107A, CH-2502  
Biel, Phone/Fax +41 323230188  
info@u-impl.com  
www.u-impl.com

# Goals & Scope

*Journal of Diagnostics & Treatment of Oral & Maxillofacial Pathology* goals to publish the cutting-edge and peer-reviewed articles on work in oral and maxillofacial surgery and neighboring specialties. The journal includes the following topics: implants surgery, head and neck imaging, microvascular and reconstructive surgery, oral and maxillofacial pathology, head and neck surgery/oncology, TMJ lesions/disorders, head and neck trauma, plastic surgery, pharmacology/drugs.

The *Journal* is registered in Ministry of Justice of Ukraine  
Registration Certificate: KB №22251-12151P  
Issued on July 28, 2016  
ISSN 2522-1965 (Online)  
ISSN 2519-2086 (Print)

3 (5) 2019

**Frequency:** 12 times a year

SUBSCRIPTION INDEX IN UKRAINE: 60077. Details at page A7

The *Journal* is included to the list of scientific professional publications (issued on December 28, 2017; protocol #1714) of Ministry of Education and Science of Ukraine. In that *Journal* the results of dissertation papers can be published for obtaining the degrees of Candidate and Doctor of Medical Sciences.

## Citations

CrossRef, Google Scholar

## Co-founders

Shupyk National Medical Academy of Postgraduate Education  
Private Higher Educational Establishment  
“Kyiv Medical University”  
OMF Publishing, LLC

## Investments

Ellet E. (Ukraine)

## Marketing and Advertising

Dushyna A.I. (Canada)

## Ukrainian Association for Maxillofacial and Oral Surgeons (UAMOS)

4-A Profesora Pidvysotskogo Street, Kyiv 01103, Ukraine.  
Tel., fax: +38 (044) 528 35 17.  
E-mail: [info.uamos@gmail.com](mailto:info.uamos@gmail.com)  
UAMOS webpage: [www.uamos.org](http://www.uamos.org)



© 2019 Shupyk National Medical Academy of Postgraduate Education  
© 2019 Private Higher Educational Establishment “Kyiv Medical University”  
© 2019 OMF PUBLISHING, LLC

## Director, Journal Development Department

Kilipiris E. (Greece/Slovak Republic)  
[varonos@live.co.uk](mailto:varonos@live.co.uk)  
Instagram: [evangeloskilipiris](https://www.instagram.com/evangeloskilipiris)

## Members of Journal Development Department

Burtyn O.V. (Ukraine)  
Cruz R.L. (Brazil)  
Starodub Y. (New Zealand)  
Zaramello Costa B. (Brazil)

## English Language Editors

Grishko T. (United Kingdom)  
Fesenko I.P., ScD, Leading Researcher (Ukraine)

## Ukrainian Language Editor

Fesenko O.D. (Ukraine)

## Layout

Smirnova L.Ie. (Ukraine)

## Scientific Adviser

Goushcha O., PhD (USA)  
Sirenko O.E., PhD, Assoc Prof (Ukraine)

## Director, Legal Department

Popovych K.O. (Ukraine)  
[kostiantyn.popovych@dtjournal.org](mailto:kostiantyn.popovych@dtjournal.org)

## Associate Legal Advisers

Vashulenko O.V. (Ukraine)  
Vlasiuk T.O. (Ukraine)

## Is Recommended by

Ukrainian Association for Maxillofacial and Oral Surgeons.

## Published by

OMF Publishing, LLC  
13-A Simferopolska Street, office 121, Kyiv, Ukraine, 02096  
Tel: +38 (063) 293 18 13,  
Instagram: [omf\\_publishing](https://www.instagram.com/omf_publishing)  
Printed in Ukraine

A majority of the articles published in the *Journal of Diagnostics and Treatment of Oral and Maxillofacial Pathology* are distributed under the terms of the Creative Commons Attribution 4.0 International License (<http://creativecommons.org/licenses/by/4.0/>), which permits unrestricted use, distribution, and reproduction in any medium, provided you give appropriate credit to the original author(s) and the source, provide a link to the Creative Commons license, and indicate if changes were made. The Creative Commons Public Domain Dedication waiver (<http://creativecommons.org/publicdomain/zero/1.0/>) applies to the data made available in this article, unless otherwise stated.

# Editorial Board

MAY 2019 · VOLUME 3 · ISSUE 5  
[www.djournal.org](http://www.djournal.org)

## Editor in Chief

### Tymofieiev O.O.

ScD, Prof, Honored Science and Technology Worker of Ukraine. The chair of both the Department for Maxillofacial Surgery at the Shupyk National Medical Academy of Postgraduate Education & the Department of Oral and Maxillofacial Surgery at the PHEE "Kyiv Medical University". President of Ukrainian Association for Maxillofacial & Oral Surgeons ([uamos.org](http://uamos.org)). Director General in the American Biographical Institute (USA). Deputy Director General in the International Biographical Centre (England).

Key textbooks: *Diseases of the Salivary Glands* [Ukrainian] (Tymofieiev, 1st ed, 2007), *Manual of Maxillofacial & Oral Surgery* [Russian] (Tymofieiev, 6th ed, 2019), *Aesthetic, Plastic & Reconstructive Surgery of Maxillofacial Area & Neck* [Georgian] (Tymofieiev, 1st ed, 2014), *Anesthesia in Oral & Maxillofacial Surgery* (Tymofieiev, Fesenko, 1st ed, 2016), *Tumors of the Salivary Glands* [Russian] (Tymofieiev, Beridze, 1st ed, 2017), *Ameloblastomas of the Jaws: Features of the Clinical Course, Treatment & Prevention* [Russian] (Tymofieiev, Ushko, 1st ed, 2018),

Address: 4-a Prof Pidvysotskogo Street, Kyiv 01103, Ukraine. Tel., fax: +38 (044) 528 35 17

[tymofeev@gmail.com](mailto:tymofeev@gmail.com); Instagram: [oleksii.tymofieiev](https://www.instagram.com/oleksii.tymofieiev)

## Deputy Editors in Chief

### Fernandes R.P.

MD, DMD, FACS, FRCS(Ed), Prof, Departments of Oral & Maxillofacial Surgery; Orthopedics, Neurosurgery, & General Surgery. Director, Head & Neck Oncology and Microvascular Surgery Fellowship. Chief, Division of Head & Neck Cancer. College of Medicine. University of Florida. Regent – Region III (Southeast) of American College of Oral & Maxillofacial Surgeons ([acom.s.org](http://acom.s.org)).

Consulting Editor in 1) *Oral and Maxillofacial Surgery Clinics of North America* and

2) *Atlas of the Oral and Maxillofacial Surgery Clinics of North America*.

Key textbooks: *Local & Regional Flaps in Head & Neck Reconstruction: A Practical Approach* (Fernandes, 1st ed, 2014), *Oral, Head & Neck Oncology & Reconstructive Surgery* (Bell, Fernandes, Andersen, 1st ed, 2017)

(Jacksonville, Florida, USA)

Instagram: [rui\\_fernandes\\_](https://www.instagram.com/rui_fernandes_)

### Savychuk N.O.

ScD, Prof, Honored Science and Technology Worker of Ukraine. Vice-Rector for Science at Shupyk National Medical Academy of Postgraduate Education (Kyiv, Ukraine)



**FIGURE.** Professor Oleksii O. Tymofieiev (*left*) and Professor Rui P. Fernandes (*right*) at 1st International Scientific Congress of the Azerbaijan Society of Oral and Maxillofacial Surgeons. 14 March, 2019; Baku, Azerbaijan.

# Editorial Board

MAY 2019 · VOLUME 3 · ISSUE 5  
www.djournal.org

## Section Editors

### Autoimmune Diseases

**Naishtetik I.M.**, PhD  
(Kyiv, Ukraine)  
Instagram: *irina\_nayshtetik*

### Benign Clinical Conditions

**Tymofieiev O.O.**, ScD, Prof  
(Ukraine)

### Bone Augmentation Techniques

**Casap N.**, Prof  
(Jerusalem, Israel)

### Craniofacial Deformities

**Richardson S.**, Visit Prof  
(Nagercoil, Tamil Nadu, India)  
Instagram: *drsunilrichardson*

### Facial Feminization Surgery

**Keojampa K.**  
(Los Angeles, California, USA)  
Instagram: *keojampamd*

### Head & Neck Oncological Surgery

**Todd Hanna**  
(New York, New York, USA)  
Instagram: *doctor.hanna*

### Head & Neck Radiology

**Ahuja A.T.**, Prof  
(Hong Kong, SAR, China)

### Web & Social Media Editor

**Monteiro J.L.**  
(Recife, Pernambuco, Brazil)  
*j.l.monteiro@dtjournal.org*  
Instagram: *joaoluizmonteiro*

### Review of Events

**Khadem A.A.**  
(Kyiv, Ukraine)  
*ariana.khadem@dtjournal.org*  
Instagram: *aria\_ni*

### Microvascular Surgery

**Fernandes R.P.**, Prof  
(Jacksonville, Florida, USA)  
Instagram: *rui\_fernandes\_*

### Mohs Surgery

**Khan M.**, Assis Prof  
(New York, New York, USA)  
Instagram: *khanmisbah6*

### MRONJ

**Hatab N.**, PhD, Assis Prof  
(Ras Al Khaimah, UAE)

### Myofascial Pain|Disorders

**Zhehulovych Z.Y.**, ScD, Prof  
(Kyiv, Ukraine)

### Orthognathic Surgery

**Brinhole M.**  
(São Paulo, São Paulo, Brazil)  
Instagram: *dr\_mario\_brinhole*

### Osteosynthesis of Facial Bones

**Kopchak A.V.**, ScD, Prof  
(Kyiv, Ukraine)

### Managing Editor

**Fesenko Ie.I.**, PhD, Assis Prof  
(Kyiv, Ukraine)  
*i.i.fesenko@dtjournal.org*  
Instagram: *dr\_eugenfesenko*

### Statistical Editor

**Petasyuk G.A.**, ScD, Leading Researcher  
(Kyiv, Ukraine)

### Plastic Surgery

**Fattahi T.**, Prof  
(Jacksonville, Florida, USA)

### Robotic Surgery

**Salman S.O.**, Assis Prof  
(Jacksonville, Florida, USA)  
Instagram: *sosalman*

### Salivary Glands Diseases

**Lisova I.G.**, ScD, Prof  
(Kharkiv, Ukraine)

### TMJ Lesions|Disorders

**Vasconcelos B.C.**, PhD, Prof  
(Recife, Pernambuco, Brazil)

### Trigeminal|Facial Nerve Trauma

**Vesova O.P.**, ScD, Prof  
(Kyiv, Ukraine)

### Zygoma & Orbital Trauma

**Chepurnii Y.V.**, PhD, Assoc Prof  
(Kyiv, Ukraine)

### Pathology

**Tuffaha M.S.**, ScD, Prof  
(Cottbus, Germany)

### Assistant Managing Editors

**Szmirnova I.**  
(Budapest, Hungary)  
**Dushyn I.I.**  
(Vancouver, British Columbia, Canada)

### Books Scan (Radiology)

**Babkina T.M.**, ScD, Prof  
(Kyiv, Ukraine)

# Editorial Board

MAY 2019 · VOLUME 3 · ISSUE 5  
www.djournal.org

## Editorial Board

**Ankin M.L.**, ScD, Prof  
(Kyiv, Ukraine)

**Antonyshyn O.M.**, Prof  
(Toronto, Ontario, Canada)

**Araujo M.M.**, Prof  
(São José dos Campos, São Paulo, Brazil)

**Beridze B.**, PhD  
(Batumi, Georgia)

**Bida V.I.**, ScD, Prof  
(Kyiv, Ukraine)

**Bunnell A.**, Assis Prof  
(Jacksonville, Florida, USA)

**Cantero D.R.**  
(Madrid, Spain)  
Instagram: *robles\_drc*

**Chichua Z.**, ScD, Prof  
(Tbilisi, Georgia)

**Constantini S.**, Prof  
(Tel Aviv, Israel)

**Doroshenko O.M.**, ScD, Prof  
(Kyiv, Ukraine)

**Gichka S.G.**, ScD, Prof  
(Kyiv, Ukraine)

**Guliuk A.G.**, ScD, Prof  
(Odessa, Ukraine)

**Hala Zakaria**, PhD, Assoc Prof  
(Ras Al Khaimah, UAE)

**Horn F.**, PhD  
(Bratislava, Slovak Republic)

**Iefymenko V.P.**, PhD, Assoc Prof  
(Kyiv, Ukraine)

**Ivnev B.B.**, ScD, Prof  
(Kyiv, Ukraine)

**Kabanova A.A.**, PhD, Assoc Prof  
(Vitebsk, Belarus)  
Instagram: *kabanova.arina*

**Kabat M.**, PhD  
(Bratislava, Slovak Republic)

**Komskiy M.P.**, ScD, Prof  
(Dnipro, Ukraine)

**Kulbashna Y.A.**, ScD, Prof  
(Kyiv, Ukraine)

**Lesnukhin V.L.**, PhD, Assoc Prof  
(Gothenburg, Sweden)

**Lutskaia I.K.**, ScD, Prof  
Laureate of State Prize for Republic of Belarus  
(Minsk, Belarus)

**Lykhota A.M.**, ScD, Prof  
(Kyiv, Ukraine)

**Maksymcha S.V.**, PhD, Assoc Prof  
(Kyiv, Ukraine)

**Mazen Tamimi**, PhD  
(Amman, Jordan)

**Medvediev V.E.**, ScD, Prof,  
Honored Science & Technology  
Worker of Ukraine  
(Kyiv, Ukraine)

**Pavlenko O.V.**, ScD, Prof,  
Honored Science & Technology  
Worker of Ukraine  
(Kyiv, Ukraine)

**Peredkov K.I.**, PhD, Assoc Prof  
(Kyiv, Ukraine)

**Petrik M.**  
(Bratislava, Slovak Republic)

**Potapchuk A.M.**, ScD, Prof,  
Honored Science & Technology  
Worker of Ukraine  
(Uzhhorod, Ukraine)

**Protsyk V.S.**, ScD, Prof  
(Kyiv, Ukraine)

**Rahimov C.R.**, ScD, Prof  
(Baku, Azerbaijan)

**Ruslin M.**  
(Makassar, Indonesia)

**Savychuk O.V.**, ScD, Prof  
(Kyiv, Ukraine)

**Stanko P.**, PhD, Prof  
(Bratislava, Slovakia)

**Szabó G.**, Prof Emeritus  
(Budapest, Hungary)

**Tkachenko P.I.**, ScD, Prof  
(Poltava, Ukraine)

**Trnka J.**, PhD, Assoc Prof  
(Bratislava, Slovak Republic)

**Tsekhmister Y.V.**, ScD, Prof  
Corresponding Member in NAPS of Ukraine  
(Kyiv, Ukraine)

**Tymofieiev O.O.**, ScD, Assoc Prof  
(Kyiv, Ukraine)

**Ushko N.O.**, ScD, Assoc Prof  
(Kyiv, Ukraine)

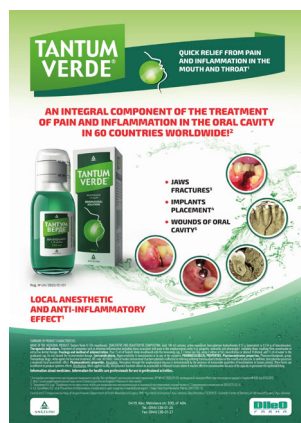**Vares Y.E.**, ScD, Prof  
(Lviv, Ukraine)

**Voronenko Y.V.**, Academician of NAMS,  
ScD, Prof, Honored Science & Technology  
Worker of Ukraine  
(Kyiv, Ukraine)

**Iakovenko L.M.**, ScD, Prof  
(Kyiv, Ukraine)

**Zaritska V.I.**, PhD, Assoc Prof  
(Kyiv, Ukraine)

**Jezzini A.A.**, PhD, Assoc Prof  
(Beirut, Lebanon)



# TANTUM VERDE®

## INFORMATION LEAFLET for the medicinal product

### **Composition:**

*active substance:* **benzydamine hydrochloride;**  
100 mL of solution contain benzydamine hydrochloride  
0.15 g;

*excipients:* ethanol 96%, glycerol, methyl  
parahydroxybenzoate (E 218), flavor (menthol), saccharin,  
sodium hydrocarbonate, Polysorbate 20, Quinoline Yellow  
(E 104), Patent Blue V (E 131), purified water.

**Dosage form.** Oromucosal solution.

*Basic physical and chemical properties:* a clear green liquid  
with a typical mint flavor.

**Pharmacotherapeutic group.** Dental preparations. Other  
agents for local oral treatment.

ATC code: A01A D02.

### **Pharmacological properties.**

#### *Pharmacodynamics.*

Benzydamine is a non-steroidal anti-inflammatory drug  
(NSAID) with analgesic and antiexudative properties.

Clinical studies have shown that benzydamine is  
effective in the relief of symptoms accompanying localized  
irritation conditions of the oral cavity and pharynx.  
Moreover, benzydamine has anti-inflammatory and local  
analgesic properties, and also exerts a local anesthetic  
effect on the oral mucosa.

#### *Pharmacokinetics.*

Absorption through the oral and pharyngeal mucosa has  
been proven by the presence of measurable quantities  
of benzydamine in human plasma. However, they are  
insufficient to produce any systemic pharmacological  
effect. The excretion occurs mainly in urine, mostly as  
inactive metabolites or conjugated compounds.

When applied locally, benzydamine has been shown to  
cumulate in inflamed tissues in an effective concentration

due to its ability to permeate through the mucous  
membrane.

### **Clinical particulars.**

#### **Indications.**

Symptomatic treatment of oropharyngeal irritation  
and inflammation; to relieve pain caused by gingivitis,  
stomatitis, pharyngitis; in dentistry after tooth extraction  
or as a preventive measure.

#### **Contraindications.**

Hypersensitivity to the active substance or to any other  
ingredients of the product.

### **Interaction with other medicinal products and other types of interaction.**

No drug interaction studies have been performed.

### **Warnings and precautions.**

If sensitivity develops with long-term use, the treatment  
should be discontinued and a doctor should be consulted  
to get appropriate treatment.

In some patients, buccal/pharyngeal ulceration may  
be caused by severe pathological processes. Therefore,  
the patients, whose symptoms worsen or do not improve  
within 3 days or who appear feverish or develop other  
symptoms, should seek advice of a physician or a dentist,  
as appropriate.

Benzydamine is not recommended for use in patients  
hypersensitive to acetylsalicylic acid or other non-steroidal  
anti-inflammatory drugs (NSAIDs).

The product can trigger bronchospasm in patients  
suffering from or with a history of asthma. Such patients  
should be warned of this.

For athletes: the use of medicinal products containing  
ethyl alcohol might result in positive antidoping tests  
considering the limits established by some sports  
federations.

*Use during pregnancy or breast-feeding*

No adequate data are currently available on the use of benzydamine in pregnant and breastfeeding women. Excretion of the product into breast milk has not been studied. The findings of animal studies are insufficient to make any conclusions about the effects of this product during pregnancy and lactation.

The potential risk for humans is unknown.

TANTUM VERDE should not be used during pregnancy or breast-feeding.

*Effects on reaction time when driving or using machines*

When used in recommended doses, the product does not produce any effect on the ability to drive and operate machinery.

**Method of administration and doses.**

Pour 15 mL of TANTUM VERDE solution from the bottle into the measuring cup and gargle with undiluted or diluted product (15 mL of the measured solution can be diluted with 15 mL of water). Gargle 2 or 3 times daily. Do not exceed the recommended dose.

*Children.*

The product should not be used in children under 12 years due to a possibility of ingestion of the solution when gargling.

**Overdosage.**

No overdose has been reported with benzydamine when used locally. However, it is known that benzydamine, when ingested in high doses (hundreds times higher than those possible with this dosage form), especially in children, can cause agitation, convulsions, tremor, nausea, increased sweating, ataxia, and vomiting. Such acute overdose requires immediate gastric lavage, treatment of fluid/salt imbalance, symptomatic treatment, and adequate hydration.

**Adverse reactions.**

Within each frequency group, the undesirable effects are presented in order of their decreasing seriousness.

Adverse reactions are classified according to their frequency: very common ( $\geq 1/10$ ); common ( $\geq 1/100$  to  $<1/10$ ); uncommon ( $\geq 1/1,000$  to  $<1/100$ ); rare ( $\geq 1/10,000$  to  $<1/1,000$ ); very rare ( $<1/10,000$ ); frequency unknown (cannot be estimated from the available data).

*Gastrointestinal disorders:* rare – burning mouth, dry mouth; *unknown* – oral hypesthesia, nausea, vomiting, tongue edema and discoloration, dysgeusia.

*Immune system disorders:* rare – hypersensitivity reaction, *unknown* – anaphylactic reaction.

*Respiratory, thoracic and mediastinal disorders:* very rare – laryngospasm; *unknown* – bronchospasm.

*Skin and subcutaneous tissue disorders:* uncommon – photosensitivity; very rare – angioedema; *unknown* – rash, pruritus, urticaria.

*Nervous system disorders:* *unknown* – dizziness, headache.

TANTUM VERDE contains methyl parahydroxybenzoate, which can cause allergic reactions (including delayed-type reactions).

**Shelf life.** 4 years.

**Storage conditions.**

Do not store above 25°C. Keep out of reach of children.

**Packaging.**

120 mL of solution in a bottle with a measuring cup; 1 bottle per cardboard box.

**Dispensing category.**

Over-the-counter medicinal product.

**Manufacturer.**

Aziende Chimiche Riunite Angelini Francesco A.C.R.A.F. S.p.A., Italy.

Location of the manufacturer and its business address.  
Via Vecchia del Pinocchio, 22 – 60100 Ancona (AN), Italy.

**Date of the last revision of the text.**

September 26, 2018.

Information leaflet is

**APPROVED** by

Order of the

**Ministry of Health of Ukraine**

No. 636 dated 01.10.2015

**Registration Certificate**

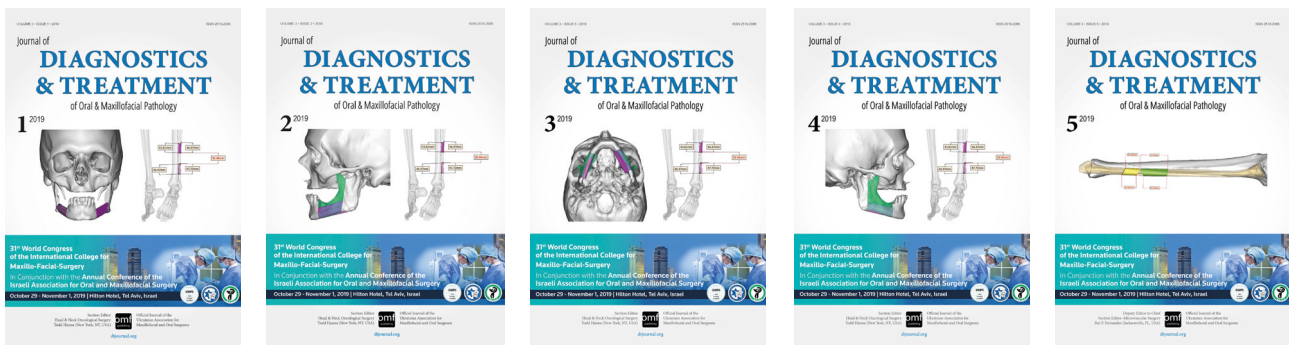

No. UA/3920/01/01



# Subscription in Ukraine

A *Journal of Diagnostics & Treatment of Oral & Maxillofacial Pathology* is published monthly. A subscription for individuals and institutions to the print version of the *Journal* is performed both in any state post offices of Ukrposhta at the territory of Ukraine and online via website [www.presa.ua](http://www.presa.ua)

SUBSCRIPTION INDEX IS: 60077



From a January 2019 the *Journal* became a monthly publication. Taking into account that individuals or institutions who have already subscribed 4 Issues (in 2019) or will subscribe the *Journal* in 2019 will receive additional 8 Issues free of charge.

From the end of 2019 it will be possible to subscribe all 12 of 2020-year Issues.

ANOUNCMENT: At the end of the 2019 it will be possible subscribe the *Journal* from any corner of the globe via *Journal*'s website.

Number of Issues (Numbers)	Cost
4 issues in 2019 (March, June, September, December)	US \$ 27.68 (UAH 782.00)
12 issues in 2020	US \$ 83.95 (UAH 2 325.12)

# Content

of the Volume 3 (Issue 5) 2019

	A1	<b>Publisher and Editorial Office Information</b>
	A2	<b>Editorial Board</b>
	A7	<b>Subscription in Ukraine</b>
	A8	<b>Content and Erratum</b>
Courtesy Page	A9	<i>Cover images are courtesy of:</i> Anastasiya Quimby, Salam O. Salman, and Rui P. Fernandes
Welcome Letter	A10	<b>31st World Congress of the International College for Maxillo-Facial-Surgery (ICMFS)</b> Adi Rachmiel and Yoav Leiser
Editorial	A11	<b>Every Hashtag Matters: An Importance of That Instagram Tool in a Life of the Peer-Reviewed Journal</b> João Luiz Gomes Carneiro Monteiro and Ievgen I. Fesenko
Head Neck Oncological Surgery   Salivary Glands   Pathology: Case Report	132	<b>Mammary Analogue Secretory Carcinoma of a Minor Salivary Gland: Review of a Rare Clinical Entity</b> Harleen Kaur, Robert J. Diecidue, and Andrew Yampolsky
Ultrasound   Salivary Glands: Case Report + Video	144	<b>Effectiveness of Ultrasound in Verification of the Mucus Plugs and Sialoliths of the Wharton`s Duct</b> Olha S. Cherniak and Ievgen I. Fesenko
Dental Implants: Discussion	154	<b>Discussion: Role of Primary Stability for Successful Osseointegration of Dental Implants: Factors of Influence and Evaluation</b> Ivan V. Nagorniak
	A12	<b>Future Events</b>
	A13	<b>Submission of Articles</b>
	A16	<b>Association Information</b>
	A17	<b>Disclaimer</b>
Forthcoming Articles	A18	<b>How Useful Is Ultrasound in Case of Traumatic Myositis Ossificans of the Masseter Muscle?</b> <i>and</i> <b>“Wait and See” Strategy: Can It Be an Advantageous Management in Case of Retention Cyst of the Maxillary Sinus with Size More Than 2.0 × 2.0 cm?</b>



# 31<sup>st</sup> World Congress of the International College for Maxillo-Facial-Surgery

In Conjunction with the Annual Conference of the  
Israeli Association for Oral and Maxillofacial Surgery

October 29 - November 1, 2019 | Hilton Hotel, Tel Aviv, Israel



## WELCOME LETTER

Dear Colleagues,

### Tradition and progress coming together.

Maxillofacial surgery is one of the most diverse and challenging professions. We operate while influencing on a person's facial appearance, some of the times unintentionally while at other times in order to improve appearance. We treat bony tissue and soft tissue, functional structures and aesthetic structures, healthy people and sick ones, children and adults. Our field includes numerous procedures; from minor oral surgery and implantology up to major head & neck surgery and reconstruction.

Due to the diversity of our field, an increased number of technological developments are introduced constantly, starting from minimal invasive endoscopic instrumentation up to virtual 3D pre planning of operations and personalized surgical guides and implants.

Research is an important part of our field and completes the clinical activity.

All of the above require us to exchange experiences and developments in our field in order to allow the best possible care for our patients.

In light of the importance of these scientific meetings it is my pleasure to invite you to the 31<sup>st</sup> World Congress of the International College for Maxillo-Facial-Surgery (ICMFS), which will be held in Tel Aviv, Israel between the 29<sup>th</sup> of October and the 1<sup>st</sup> of November 2019 ([www.icmfs2019.com](http://www.icmfs2019.com)).

This congress will include keynote lectures from some of the most experienced and well known surgeons of our field.

In addition, we want this congress to act as a platform for all of you to exhibit your experience as well as your research accomplishments while conducting discussions to improve you as a clinician and researcher.

In this congress you will be exposed to keynote lectures, oral presentations, poster presentations, masterclasses, panel discussions, evening receptions and more. You will get the chance to meet new people in your field and form collaborations.

You will have the opportunity to see Israel with all of its historical past and numerous beaches and cultural experience as well as great food and great weather.

We are looking forward to meet you all in the congress and have a wonderful time together in Israel.

Adi Rachmiel, Professor  
President, 31<sup>st</sup> ICMFS World  
Congress 2019

Dr. Yoav Leiser  
President Elect, Israeli Association for  
Oral and Maxillofacial Surgery



Editorial

# Every Hashtag Matters: An Importance of That Instagram Tool in a Life of the Peer-Reviewed Journal

João Luiz Gomes Carneiro Monteiro<sup>a</sup> and Ievgen I. Fesenko<sup>b</sup>

*Every person matters.*  
—Tom Hanks as James Donovan  
in movie “Bridge of Spies”

Hashtag (ie, the # symbol)<sup>1</sup> is a type of metadata tag used in the different social media, such as Instagram, Twitter, YouTube, etc. It was invented by Chris Messina in 2007, when he proposed to use hashtag in Twitter with a purpose to group and easily find posts with a specific content/theme. Scientific journals from different specialties with high Impact Factor are also paying a great attention to the role of hashtags in their journals' media accounts lives.<sup>1,2</sup>

The *DTJournal's* first Instagram-related international collaboration started in 2017, during the 23<sup>rd</sup> International Conference on Oral and Maxillofacial Surgery in Hong Kong. Using in *DTJournal's* account the hashtag #icoms2017 (which included 164 posts) two participants of the event Dr. Monteiro and Dr. Fesenko began a productive conversation dedicated to submission of a case report article.<sup>3</sup> Which was successfully published (Fig) in the nearest issue.

So, an Editorial's message to the colleagues is very

<sup>a</sup> Maxillofacial Surgeon, PhD Student, University of Pernambuco, Recife, Pernambuco, Brazil.  
Web & Social Media Editor, *DTJournal*.

<sup>b</sup> Managing Editor, *DTJournal*.

E-mails: [joaoluizgcm2@gmail.com](mailto:joaoluizgcm2@gmail.com) (João Luiz Monteiro)  
[i.i.fesenko@dtjournal.org](mailto:i.i.fesenko@dtjournal.org) (Ievgen Fesenko)  
Instagram: [joaoluizmonteiro](https://www.instagram.com/joaoluizmonteiro)  
[dr\\_eugenfesenko](https://www.instagram.com/dr_eugenfesenko)

<http://dx.doi.org/10.23999/j.dtopm.2019.5.1>.  
© 2019 OMF Publishing, LLC. This is an open access article under the CC BY licence (<http://creativecommons.org/licenses/by-nc/4.0/>).

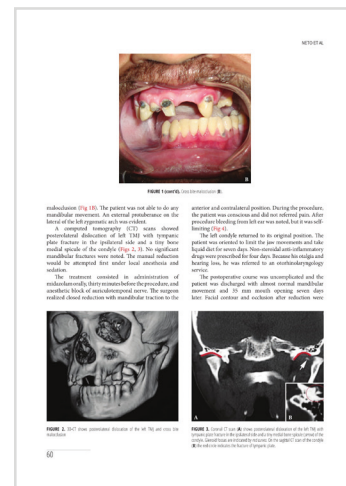
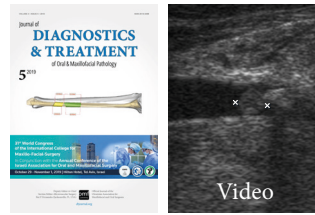
FIGURE. Second page of the article of Neto et al.<sup>3</sup>

clear: Do not regret the time to use hashtags in all kind of scientific, communicative or marketing purposes.

## REFERENCES

1. Rauschnabel, PA, Sheldon, P, Herzfeldt, E. What motivates users to hashtag on social media? *Psychol Mark* **2019**;36:473–88. <https://doi.org/10.1002/mar.21191>.
2. Dorfman RG, Vaca EE, Mahmood E, Fine NA, Schierle CF. Plastic surgery-related Hashtag utilization on Instagram: implications for education and marketing. *Aesthet Surg J* **2018**;38:332–8. <https://doi.org/10.1093/asj/sjx120>.
3. Neto AMR, Monteiro JL, Borba PM, Melo AR, Barbosa LM, Vasconcelos BC. TMJ's posterolateral dislocation with tympanic plate fracture – case report. *J Diagn Treat Oral Maxillofac Pathol* **2017**;1:59–64. <https://doi.org/10.23999/j.dtopm.2017.2.2>.



Ultrasound | Salivary Glands: Case Report + Video

## Effectiveness of Ultrasound in Verification of the Mucus Plugs and Sialoliths of the Wharton`s Duct

Olha S. Cherniak<sup>a</sup> and Ievgen I. Fesenko<sup>b, \*</sup>

### SUMMARY/INTRODUCTION

*The pathological changes in 467 submandibular glands were identified both endoscopically and radiographically, and endoscopic findings showed three types: calculus (91 percent), mucus plug (3 percent), and stenosis (6 percent).<sup>1</sup>*

—Yu Chuangqi et al, 2013  
China

Mucus plugs<sup>1, 2</sup> (*synonyms*: mucous plugs<sup>3</sup>, mucin plugs<sup>4</sup>, fibromucinous plugs<sup>5, 6</sup> and mucosal plugs<sup>7</sup>) and sialoliths (*synonyms*: salivary stones, salivary calculi<sup>1</sup>, and concrements<sup>8, 9</sup>) belong to the one of the common causes of the obstructive salivary gland disease (*synonyms*: obstructive sialadenitis<sup>10</sup> and obstructive sialadenopathy<sup>8</sup>). Among other etiologies of obstructive sialadenitis are: foreign bodies, inflammation, kinks, strictures, anatomic malformations, polyps or even tumors.<sup>11</sup> Those causes are found in different percentages. The radiographic investigation e.g. X-ray and computed tomography (CT) are very useful in detection of the salivary stones. Nevertheless, as approximately 80-90 percent of the sialoliths are opaque on a standard review X-ray and CT, and in 10-20% radiolucent.<sup>12, 13</sup> But these methods are not useful in the detection of mucus plugs due to the non-contrast features of the last. There are a lot of studies which described ultrasound features of the sialoliths.<sup>14, 15</sup> Also, there are some studies that demonstrate endoscopic view of the mucosal plugs in a ductal system<sup>1, 7, 16</sup> and in some cases the authors during sialendoscopy noted the floating mucous plugs.<sup>17</sup> But we cannot find articles in PubMed which demonstrate ultrasound and clinical appearance of the obstructive salivary gland disease caused by sialoliths with mucus plugs simultaneously.

The purpose of our article is to describe a first and precise description of ultrasound pattern of the mucus plugs comparing with sialolith and their clinical presentation after removal. We report the consecutive gray scale and color Doppler sonograms with a supplemental video.

<sup>a</sup> Head, Department of Ultrasound, Regional Diagnostic Center, Kyiv Regional Clinical Hospital, Kyiv, Ukraine.

<sup>b</sup> Oral Surgeon, Center of Maxillofacial Surgery, Kyiv Regional Clinical Hospital, Kyiv, Ukraine (place of work at moment of article preparing). PhD, Assistant Professor. Department of Oral & Maxillofacial Surgery, Private Higher Educational Establishment "Kyiv Medical University", Kyiv, Ukraine.

\* Corresponding author address: 7 Antona Tsedika Street, Kyiv 02000, Ukraine.  
Department of Oral & Maxillofacial Surgery, Private Higher Educational Establishment "Kyiv Medical University"

E-mail: [i.i.fesenko@dtjournal.org](mailto:i.i.fesenko@dtjournal.org) (Ievgen Fesenko)  
Instagram: [dr\\_eugenfesenko](https://www.instagram.com/dr_eugenfesenko)

E-mail of the co-author:  
[cherniak.os@gmail.com](mailto:cherniak.os@gmail.com) (Olha Cherniak)

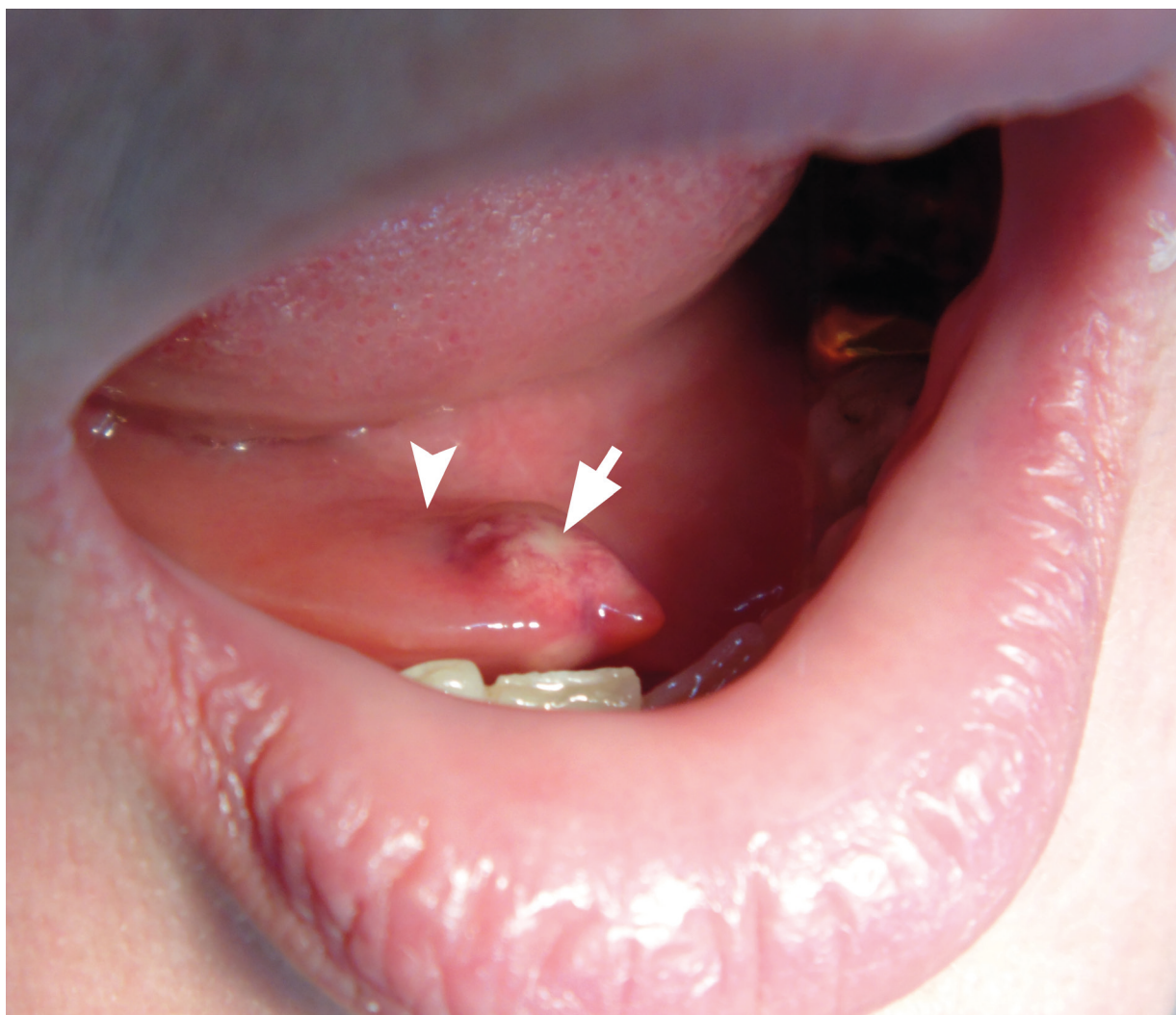
Paper received 10 March 2019  
Accepted 17 April 2019  
Available online 31 May 2019

<https://dx.doi.org/10.23999/j.dtopm.2019.5.3>.  
© 2019 OMF Publishing, LLC. This is an open access article under the CC BY license (<http://creativecommons.org/licenses/by-nc/4.0/>).

## CASE

A 32-year-old woman was seen in Maxillofacial Surgery Center of the Kyiv Regional Clinical Hospital because of swelling in right submandibular and sublingual area during last days. The salivary colic (*synonyms*: postprandial salivary colic<sup>18</sup>, spasmodic pain during eating<sup>19</sup> and meal time syndrome<sup>6</sup>) began to disturb the patient at the same time as the

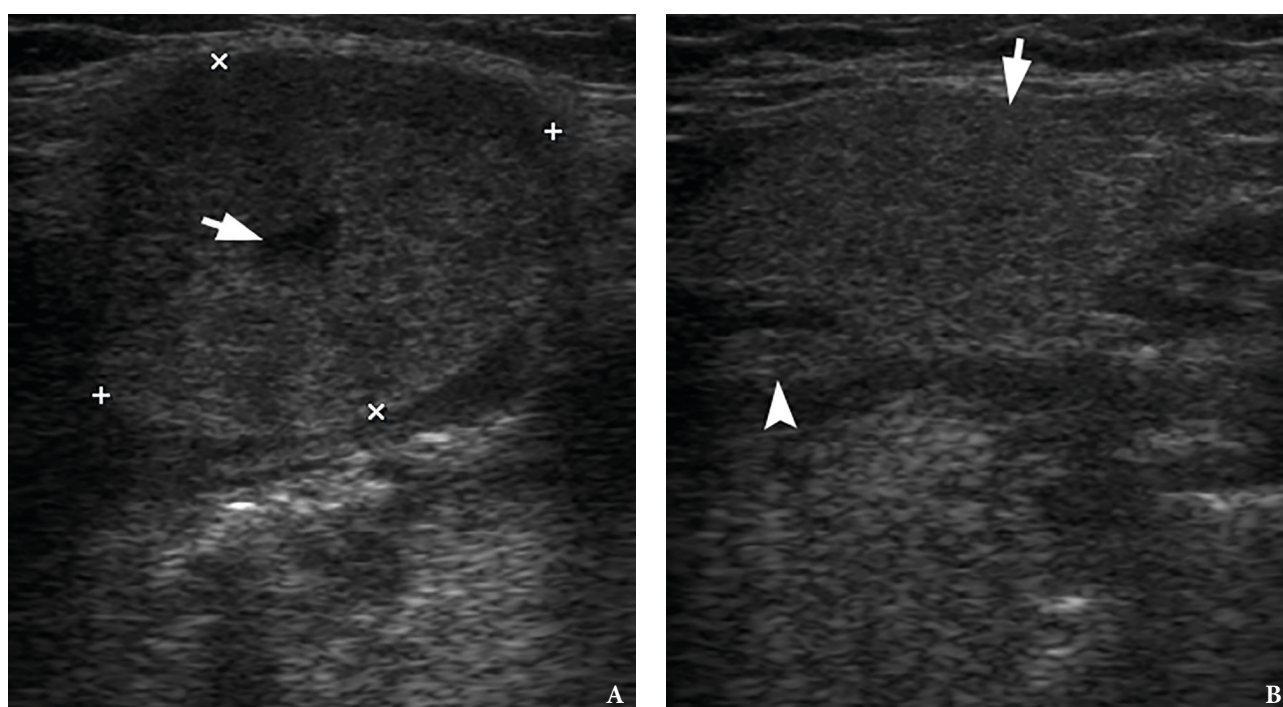
appearance of edema. An intraoral examination showed severe swelling of the mucosa in the right sublingual area with its significant erythema and a local necrosis (Fig 1). During massage of the right submandibular gland no milking exudate or saliva was present from the duct's orifice. Bimanual palpation of the right submandibular gland was painful to the patient and also indicated us the enlargement of the gland.



**FIGURE 1.** Intraoral view before ultrasound and treatment. Note an erythema and swelling (*arrowhead*) in the right sublingual area. Necrosis of the mucosa is indicated by *arrow*.

Ultrasound (US) investigation was performed with 12-3 MHz linear transducer (*synonym*: linear probe<sup>14</sup>) (model HD11 XE, Philips). US in the right

submandibular position showed the two-times enlarged right submandibular gland comparing with a contralateral organ (Fig 2).



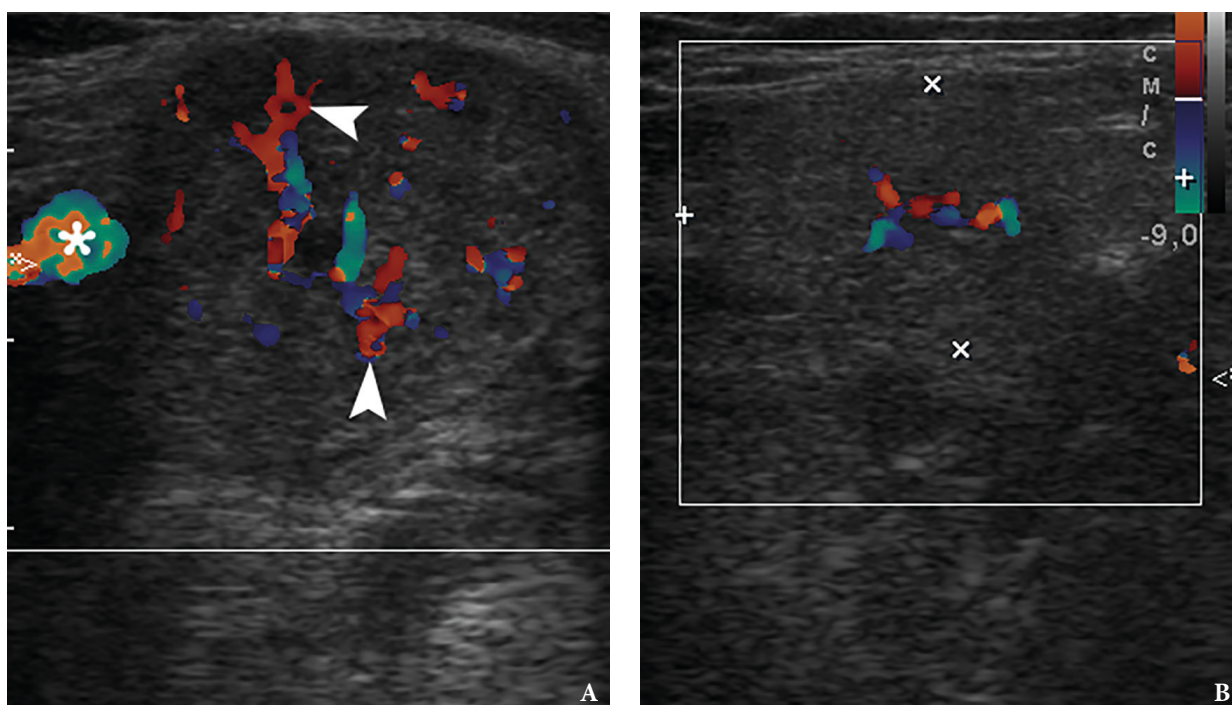
**FIGURE 2.** Comparison of the longitudinal gray scale sonograms of a right obstructed and inflamed submandibular gland (**A**) with a left nonsymptomatic gland (**B**). At image **A**, the gland is indicated by '+' and 'x' calipers. The gland is enlarged in size almost twice and has a rounded form. Note a dilatation of the intraglandular duct (*arrow*). At image **B**, the superficial (larger) lobe of the left nonsymptomatic gland is lying within the digastric triangle<sup>19</sup> and is indicated by *arrow*, the deep (smaller) lobe – by *arrowhead*.

In a longitudinal transducer's position the color Doppler US showed a striking increase of intraparenchymal vascularity (**Fig 3**) of the right obstructed gland. Gray scale ultrasound in the middle portion of the right Wharton's duct showed a hyperechogenic (*synonym*: hyperechoic) semilunar formation 0.43 cm in longitudinal size with artifact of 'clean' acoustic shadowing behind (**Fig 4B**). Posteriorly to the hyperechoic semilunar body in the duct, the US shows an isoechoic, round shape formation without acoustic shadowing. Its size reached 0.42 cm (**Fig 4C**). The **Video** (Supplemental Video Content) clearly demonstrates how significantly the whole Wharton's duct is dilated and its maximum width reached 0.5 cm at the posterior part. Video is available in the page of the full-text article on [dtjournal.org](http://dtjournal.org) and in the YouTube channel 'Videos DTJournal', available at <https://youtu.be/NF5MY6OW3BQ>. Total video's duration: 10 sec. The duct was filled with anechoic fluid (supposedly suppurated saliva) (**Fig 5**).

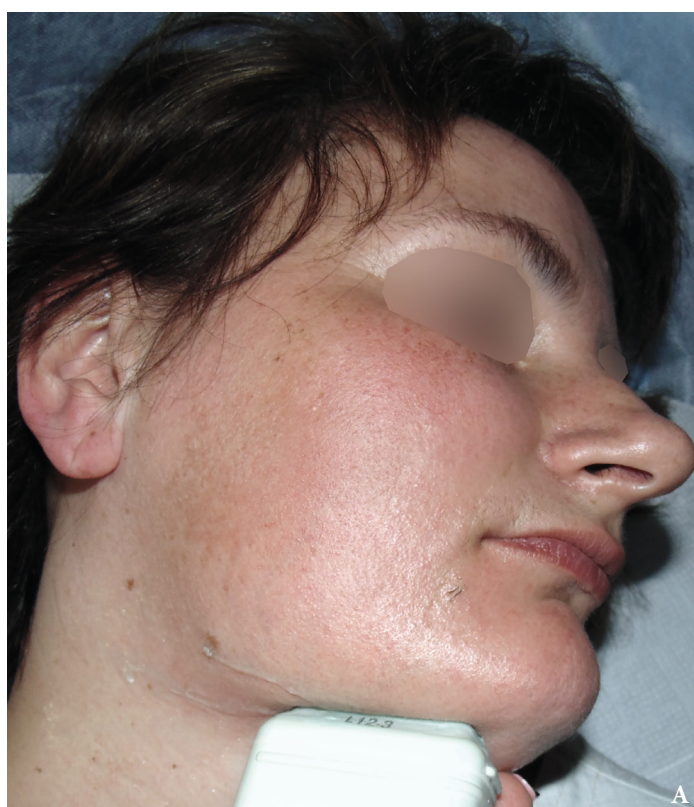A surgery was performed under local anesthesia (right inferior alveolar nerve block using 1.4 ml Ultracain D-S forte, Frankfurt, Aventis Pharma Deutschland GmbH) after suturing of the proximal part of the duct (to prevent displacement of the sialoliths and plugs posteriorly during surgery). A 1.0 cm incision was made above the swelled duct in the right sublingual area. The operation resulted in evacuation of the suppurated saliva in amount of approximately 5.0 ml (**Fig 6**) with spontaneous emergence of the sialolith with several mucus plugs. An oval yellow sialolith was measured to be 0.5 × 0.3 cm (**Fig 7**), what proved its preoperative measurement with ultrasound. Three pinky mucus plugs were 0.4 × 0.4 cm, 0.15 × 2.5 cm, and 0.2 × 0.25 cm in size. Special feature of the mucus plugs was its buttery consistency. That was proved by palpation (they are easily crushed) and even upon the contact with some surface (the plugs leave smudged trace).

The patient immediately felt relief after surgery. No postoperative complications were noted.

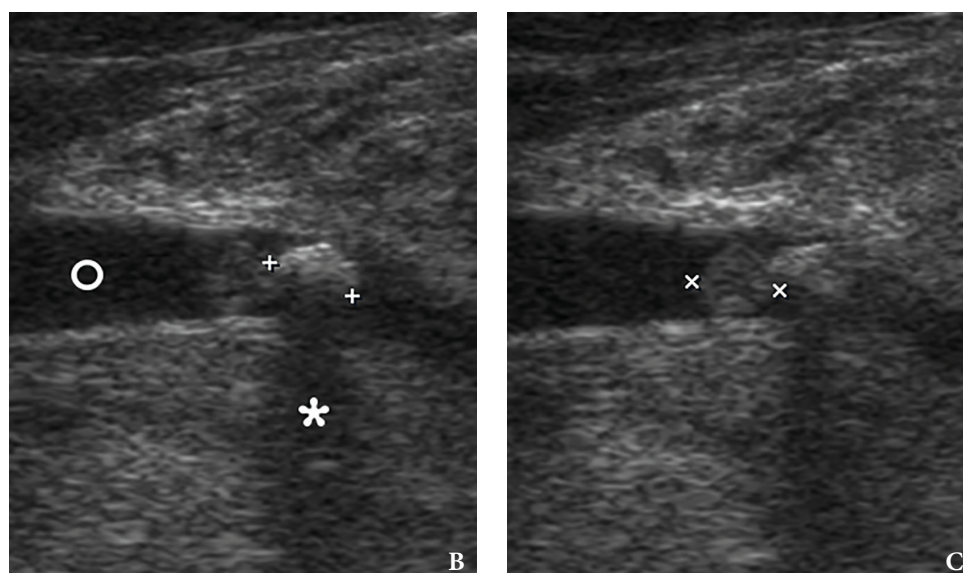




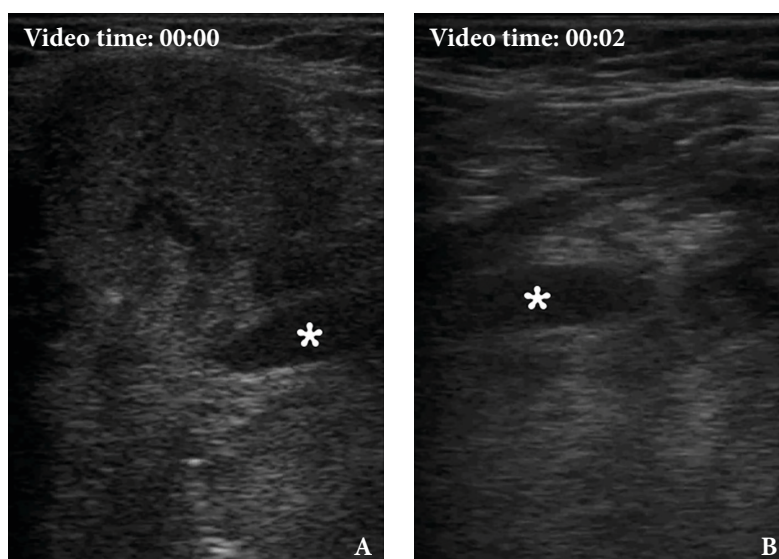
**FIGURE 3.** Longitudinal color Doppler ultrasound: Right inflamed submandibular gland (A) and left healthy submandibular gland (B). Comparing with a nonsymptomatic gland (B) (is indicated by '+' and 'x' calipers), the obstructed gland (A) is enlarged in two times. A striking increase of intraparenchymal vascularity (*arrowheads*) of the right gland is noted. Facial vessel is indicated by *asterisk* at image A.



**FIGURE 4.** Position of the linear transducer is seen at image A. (Fig 4 continued on next page.)



**FIGURE 4 (cont'd).** Gray scale ultrasound images (**B, C**) have been obtained in that position (in the projection of the middle part of the right Wharton`s duct). At image **B**, a sialolith is indicated by '+' calipers and its longitudinal size is 0.43 cm. A stone has a hyperechoic semilunar form with artifact of acoustic shadowing behind (*asterisk*). Circle indicates a lumen of dilated duct filled with anechoic fluid. At image **C**, a mucus plug is indicated by 'x' calipers and its longitudinal size reached 0.42 cm. A plug is isoechoic, round shape formation without acoustic shadowing.

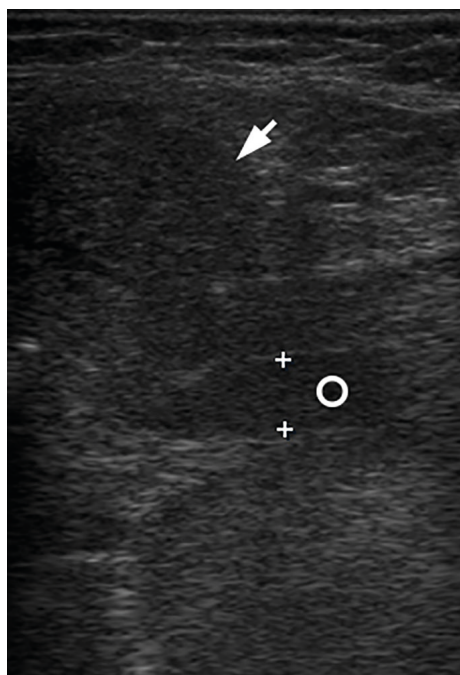


**VIDEO.** Supplemental Video Content (**A, B**) demonstrates the gray scale ultrasound examination of the right inflamed submandibular gland with a sialolith and mucus plug in its dilated Wharton`s duct filled with anechoic fluid (ie, suppurated saliva) (*asterisk*). Video is available in the page of the full-text article on [dtjournal.org](http://dtjournal.org) and in the YouTube channel 'Videos DTJournal', available at <https://youtu.be/NF5MY6OW3BQ>.

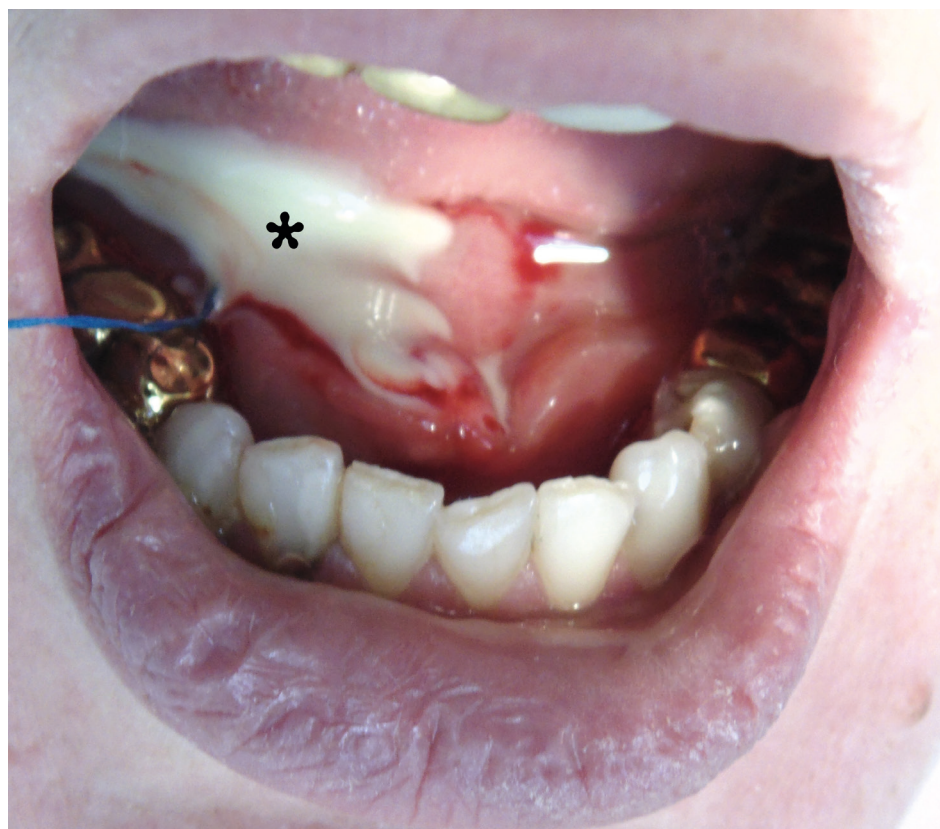
Total video`s duration: 10 sec.



QR code leads to that video at  
DTJournal`s YouTube channel  
[Videos DTJournal](https://youtu.be/NF5MY6OW3BQ)



**FIGURE 5.** Gray scale ultrasonogram shows a right submandibular gland (*arrow*) and a posterior (proximal) part of the Wharton`s duct (*circle*) filled with anechoic content (suppurated saliva). A significant dilatation of the duct is noted. Distance between '+' calipers (width of the dilated duct) is 0.51 cm.



**FIGURE 6.** Intraoral view immediately after lancing of the Wharton`s duct. After the duct lancing a significant amount of suppurated saliva (*asterisk*) was obtained.



**FIGURE 7.** Sialolith (*arrow*) and three mucus plugs (*arrowheads*), which were received with suppurated saliva from the Wharton`s duct after its lancing. Special feature of the mucus plugs was a buttery consistency of the last. That was proved by palpation (they are easily crushed) and even upon the contact with some surface (the plugs leave smeared trace). A smeared trace from a plug is indicated by *curved arrow*.

## DISCUSSION

Terraz et al indicated that secondary infection, due to obstruction of salivary flow by a sialoliths, is leading to progressive parenchymal inflammation, atrophy, and fibrosis of the gland.<sup>14</sup> The obstructive salivary gland disease with a changes in a gland tissue due to sialoliths in Ukraine is also termed as chronic sialolithic disease of the submandibular gland (*synonyms*: chronic calculous submaxillitis and chronic concrementous submaxillitis).<sup>9</sup> Thomas et al found in sixty-eight patients that sensitivity and specificity of ultrasound in detection of salivary stones were 65 and 80%. That was lower than sensitivity (98 percent) and specificity (88 percent) for CT.<sup>20</sup>

One of the main ultrasound features of the sialoliths is an artifact of acoustic shadowing (*synonym*: posterior acoustic shadowing<sup>21</sup>). Generally, this artifact may appear behind bones, stones, metal inclusions, gas, etc. as 1) clean (*synonyms*: complete<sup>22</sup> and total), 2) partial, or 3) dirty shadowing, what we can see at Table 2.<sup>23,24</sup> But in case of sialolithiasis the shadowing is typically presented as clean or partial, depending on the calcification`s size.

## LOCATIONS OF THE STONES AND PLUGS

Erkul and Gillespie used the useful location`s classification for the salivary duct scar location.<sup>25</sup> We used that location`s classification for describing the precise place of the intraductal bodies of the

submandibular gland, such as stones and plugs:

1. Ostium (orifice of the duct is opened in area of sublingual caruncle).
2. Distal part of the main duct—part of the Wharton's duct close to the duct's ostium (a synonym according to Thomas et al is 'anterior Wharton's duct'<sup>20</sup>).
3. Proximal part of the main duct—part of the Wharton's duct close to the gland (a synonym according to Turner is 'posterior duct'<sup>26</sup>).
4. Hilum—part of the Wharton's duct which enters the submandibular gland.
5. Intraglandular duct.

**SUBMANDIBULAR GLAND: ULTRASOUND FEATURES**

According to Ching and Ahuja the nonsymptomatic submandibular gland is a well-capsulated structure which has a uniform homogenous parenchymal echo pattern.<sup>22</sup> Also, the authors stated that the swollen gland due to sialoliths or other obstructive reason may become heterogeneously hypoechoic and may show dilatation of the intraglandular ductal system.<sup>22</sup>

**WHARTON'S DUCT: ULTRASOUND FEATURES**

The length of the Wharton's duct according to Ching and Ahuja varies but is approximately one and a half times the axial length of the submandibular

gland.<sup>22</sup> Carlson and Ord have noticed in their textbook "Salivary Gland Pathology: Diagnosis and Management" that submandibular duct is about 5 cm long in the adult.<sup>19</sup>

In normal (nonsymptomatic) cases the Wharton's duct can be seen only occasionally.<sup>27</sup> It will be seen as a hypoechoic linear structure with a thin echogenic wall.<sup>21,22</sup> In case of obstructive salivary gland disease or sialodochitis<sup>28</sup> the duct will be dilated and filled with anechoic fluid.

**SALIVARY STONES: ULTRASOUND FEATURES**

Gritzmann and Katz et al described a sialolith at sonogram as a bright curvilinear echo complex with posterior shadowing.<sup>29,28</sup> Ching and Ahuja reported that calculus at sonograms has an echogenic rim with complete posterior acoustic shadowing.<sup>22</sup> Goncalves et al clearly noted the salivary stones on ultrasound shows as hyperechoic reflexes with distal signal loss.<sup>8</sup> Aiyekomogbon et al stated that sialolith is usually visualized as a brightly echogenic mass casting posterior acoustic shadow.<sup>15</sup> But some authors insist that in sialoliths smaller than 2 mm, this shadow may be missing.<sup>28</sup>

**MUCUS PLUGS: ULTRASOUND FEATURES**

According to our case the plug has an isoechoic pattern with no acoustic shadowing behind.

Taking into account the fact that during the

**TABLE 1.** Comparison of Ultrasound Features of the Sialolith and Mucus Plug Located in the Wharton's Duct According to Presented Case.

Ultrasound Features	Sialolith	Mucus Plug
Echogenicity	Hyperechoic	Isoechoic
Artifact of acoustic shadowing	Present	Absent

**TABLE 2.** Types of Acoustic Shadowing Artifact According to Hindi and Colleagues.<sup>23</sup>

Characteristics	Clean (Total) Shadowing	Partial Shadowing	Dirty Shadowing
Appearance of the acoustic shadowing artifact	Uniformly anechoic signal behind a structure.	Hypoechoic signal behind a structure.	Low-level echoes in the shadow deep to gas.
In what cases occurs	Behind stones/calcifications >0.5 mm, and bones.	1. Behind calcifications and stones <0.5 mm. 2. Behind fat containing structures when surrounded by other soft tissues.	Behind gas collections.

surgery and evacuation of the duct's content we received three plugs, all 8 sonograms and three videos were retrospectively evaluated and confirmed that two other mucus plugs were located exactly in the ostium area. After all, this was indicated by the following:

1. In addition to one plug in Wharton's duct, there were no other plugs posteriorly to the calculus.
2. Concrement and concomitant posterior plug were located in the middle part of the duct, which created a place for possible localization of the two other plugs in the anterior duct.
3. The presence of two unclear objects in the anterior duct close to ostium.

And a thesis of Ching and Ahuja, that "stone impacted at the ductal ostium (30 percent) may not be well depicted on sonography, but many cases (65%) have associated main duct dilatation"<sup>22</sup> can explain why we cannot precisely detect other two mucus plugs, as they were located close to the ductal ostium.

## CONCLUSIONS

Thus, a first report of the precise ultrasound and clinical appearance of the mucus plugs and sialolith is presented. Also, a 10 seconds supplemental video is added. Comparison of the gray scale and color Doppler ultrasound images of the obstructed submandibular gland with nonsymptomatic contralateral organ is showed.

In addition, to our humble opinion, the mucus plugs which were presented at the ultrasound and post op images can clearly support the arguments of one of the theories, that sialolith's formation is happened by deposition of calcium salts around a nidus of organic material-mucus plug.<sup>7, 30</sup> So, in that case, mucus plugs can be clearly considered as a stage in the formation of salivary stones. And in that case the usage of ultrasonography can be helpful both in the detection of stones and plugs.

## TERM OF CONSENT

Written patient consent was obtained from a lady to publish the clinical photographs.

## CONFLICT OF INTEREST

The authors declare no conflict of interest.

## ROLE OF THE AUTHORS

The authors are equally contributed to that paper.

## FUNDINGS

No funding was received for this study.

## ACKNOWLEDGMENTS

None.

## REFERENCES

1. Chuangqi Y, Chi Y, Lingyan Z. Sialendoscopic findings in patients with obstructive sialadenitis: long-term experience. *Br J Oral Maxillofac Surg* **2013**;51:337–41. <https://doi.org/10.1016/j.bjoms.2012.07.013>.
2. Scully C. Oral and maxillofacial medicine: the basis of diagnosis and treatment. 3rd ed. London: Churchill Livingstone; **2013**.
3. Fernandes RP, Salman S, Quimby A. Minimally invasive techniques for management of salivary gland pathology. *J Diagn Treat Oral Maxillofac Pathol* **2017**;1:11–4. <https://dx.doi.org/10.23999/jdtomp.2017.1.2>.
4. Sharav Y, Benoliel R. Orofacial pain and headache. 1st ed. Maryland Heights: Mosby; **2008**.
5. Capaccio P, Torretta S, Ottaviani F, Sambataro G, Pignataro L. Modern management of obstructive salivary diseases. *Acta Otorhinolaryngol Ital* **2007**;27:161–72.
6. Rana SS, Arya S. Sialolithiasis of the Wharton's duct – report of 3 cases. *J Adv Med Dent Scie Res* **2017**;5:108–11. <https://doi.org/10.21276/jamdsr.2017.5.11.27>.
7. Al-Abri R, Marchal F. New era of endoscopic approach for sialolithiasis: sialendoscopy. *Sultan Qaboos Univ Med J* **2010**;10:382–7.
8. Goncalves M, Schapher M, Iro H, Wuest W, Mantsopoulos K, Koch M. Value of sonography in the diagnosis of sialolithiasis: comparison with the reference standard of direct stone identification. *J Ultrasound Med* **2017**;36:2227–35. <https://doi.org/10.1002/jum.14255>.
9. Tymofiev OO. Manual of maxillofacial and oral surgery [Russian]. 5th ed. Kyiv: Chervona Ruta-Turs; **2012**.

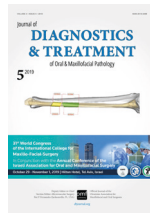
10. Carta F, Farneti P, Cantore S, Macrì G, Chuchueva N, Cuffaro L, Pasquini E, Puxeddu R. Sialendoscopy for salivary stones: principles, technical skills and therapeutic experience. *Acta Otorhinolaryngol Ital* **2017**;37(2):102–12. <https://dx.doi.org/10.14639/0392-100X-1599>.
11. Pace CG, Hwang K-G, Papadaki M, Troulis MJ. J Oral Maxillofac Surg **2014**;72:2157–66. <https://doi.org/10.1016/j.joms.2014.06.438>.
12. Larheim TA, Westesson P-L. Maxillofacial imaging. 1st ed. Berlin: Springer-Verlag, **2006**.
13. Rzymyska-Grala I, Stopa Z, Grala B, Gołębiowski M, Wanyura H, Zuchowska A, Sawicka M, Zmorzyński M. Salivary gland calculi – contemporary methods of imaging. *Pol J Radiol* **2010**;75:25–37.
14. Terraz S, Poletti PA, Dulguerov P, Dfouni N, Becker CD, Marchal F, Becker M. How reliable is sonography in the assessment of sialolithiasis? *AJR Am J Roentgenol* **2013**;201:W104–9. <https://doi.org/10.2214/AJR.12.9383>.
15. Aiyekomogbon JO, Babatunde LB, Salam AJ. Submandibular sialolithiasis: the roles of radiology in its diagnosis and treatment. *Ann Afr Med* **2018**;17:221–4. [https://doi.org/10.4103/aam.aam\\_64\\_17](https://doi.org/10.4103/aam.aam_64_17).
16. Prendes BL, Orloff LA, Eisele DW. Therapeutic sialendoscopy for the management of radioiodine sialadenitis. *Arch Otolaryngol Head Neck Surg* **2012**;138:15–9. <https://doi.org/10.1001/archoto.2011.215>.
17. Marchal F, Kurt AM, Dulguerov P, Lehmann W. Retrograde theory in sialolithiasis formation. *Arch Otolaryngol Head Neck Surg* **2001**;127(1):66–8.
18. Buckenham T. Salivary duct intervention. *Semin Intervent Radiol* **2004**;21:143–8. <https://doi.org/10.1055/s-2004-860872>.
19. Carlson ER, Ord RA. Salivary gland pathology: diagnosis and management 2nd ed. Hoboken: Wiley-Blackwell; **2016**.
20. Thomas WW, Douglas JE, Rassekh CH. Accuracy of ultrasonography and computed tomography in the evaluation of patients undergoing sialendoscopy for sialolithiasis. *Otolaryngol Head Neck Surg* **2017**;156:834–9. <https://doi.org/10.1177/0194599817696308>.
21. Huang F, Caton R, Colla J. Point-of-care ultrasound diagnosis of acute sialolithiasis with sialadenitis. *Clin Pract Cases Emerg Med* **2017**;1:437–8. <https://doi.org/10.5811/cpcem.2017.7.34907>.
22. Ching AS, Ahuja AT. High-resolution sonography of the submandibular space: anatomy and abnormalities. *AJR Am J Roentgenol* **2002**;179:703–8. <https://doi.org/10.2214/ajr.179.3.1790703>.
23. Hindi A, Peterson C, Barr RG. Artifacts in diagnostic ultrasound. *Rep Med Imag* **2013**;Volume 2013:29–48. <https://doi.org/10.2147/RMI.S33464>.
24. Baad M, Lu ZF, Reiser I, Paushter D. Clinical Significance of US artifacts. *Radiographics* **2017**;37:1408–23. <https://doi.org/10.1148/rg.2017160175>.
25. Erkul E, Gillespie MB. Sialendoscopy for non-stone disorders: the current evidence. *Laryngoscope Investig Otolaryngol* **2016**;1:140–5. <https://doi.org/10.1002/lio2.33>.
26. Turner MD. Combined surgical approaches for the removal of submandibular gland sialoliths. *Atlas Oral Maxillofac Surg Clin North Am* **2018**;26:145–51. <https://doi.org/10.1016/j.cxom.2018.05.005>.
27. Ahuja AT, Evans RM. Practical head and neck ultrasound. 1st ed. London: Greenwich Media Medical Limited. **2000**.
28. Katz P, Hartl DM, Guerre A. Clinical ultrasound of the salivary glands. *Otolaryngol Clin North Am* **2009**;42:973–1000. <https://doi.org/10.1016/j.otc.2009.08.009>.
29. Gritzmann N. Sonography of the salivary glands. *Am J Roentgenol* **1989**;153:161–6.
30. Ashby RA. The chemistry of sialoliths: stones and their homes. In: Norman JED, McGurk M, editors. *Color Atlas and Text of the Salivary Glands. Diseases, Disorders, and Surgery*. London: Mosby-Wolfe, **1995**:243-251.

Cherniak OS, Fesenko II.

Effectiveness of ultrasound in verification of the mucus plugs and sialoliths of the Wharton's duct.

*J Diagn Treat Oral Maxillofac Pathol* **2019**;3:144–53.

<http://dx.doi.org/10.23999/j.dtomp.2019.5.3>.



Dental Implants: Discussion

## Discussion: Role of Primary Stability for Successful Osseointegration of Dental Implants: Factors of Influence and Evaluation

Ivan V. Nagorniak

The authors should be honored for such a well-written and much-needed publication.<sup>1</sup> In the work by Javed et al,<sup>1</sup> a role of different factors in achieving of a primary stability (Fig) is raised and analysed. In their paper “Role of Primary Stability for Successful Osseointegration of Dental Implants: Factors of Influence and Evaluation”, are precisely described: Pre-requisites for a fortunate primary stability, density and quality of the bone tissue, design of the implants, methods of evaluation of the primary stability, and how micromotions can effect the primary stability.<sup>1</sup>

The partial/complete edentulous patient embodies the convergence of three extremely common, very challenging, and highly expensive conditions: lack of bone, poor quality of bone tissue, and high costs for the dental implants placement/bone augmentation procedures.<sup>2-8</sup>

So, factors affecting primary and secondary stability of the dental implants were beautifully outlined by Javed et al:<sup>1</sup>

### 1. Factors influencing primary stability:

- Bone quantity.
- Bone quality.
- Surgical technique.
- Implant design.

### 2. Factors influencing secondary stability:

- Primary stability.
- Bone remodeling.
- Implant surface conditions.

The bone dentistry classifications (Linkow and Chercheve, 1970; Leckholm and Zarb, 1985; Misch, 1995)<sup>1</sup> are so clearly characterized that it simplifies for the surgeons to plan and to predict the procedures using cone-beam computed tomography with Hounsfield Units measurement.<sup>3</sup> Carefully describing the “soft bones” Javed et al warn about the risks in achieving primary stability in case of soft jaw densities.<sup>1</sup> But, as pointed out by other authors,<sup>4</sup> poor primary stability is not statistically significant in the loss of dental implants. Cobo-Vázquez et al made those conclusions after analysis of 2,400 implants among which ninety-two implants were placed without primary stability.<sup>4</sup>

In summary, authors have done a great review of a hot topic of last years, analyzed 68 peer-reviewed literary sources.<sup>1</sup> This made the article<sup>1</sup> an important source for colleagues who are interested in a brief review of challenging situations in implant surgeries, especially at posterior maxilla.

DDS, PhD; Private Dental Practice, Kyiv, Ukraine.

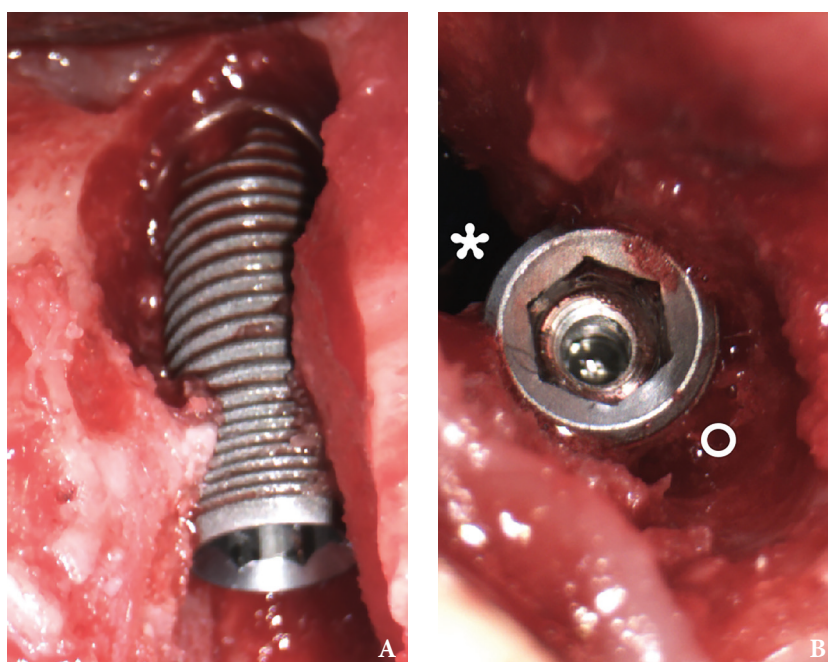
Corresponding author. *Private Dental Practice, 6-G Andruschenka Street, Office 6, Kyiv 01135, Ukraine.*  
Phone: +380674088131  
E-mail: [ivan.nagorniak@gmail.com](mailto:ivan.nagorniak@gmail.com) (Ivan Nagorniak)

Paper received 07 May 2019  
Accepted 20 May 2019  
Available online 31 May 2019

<http://dx.doi.org/10.23999/j.dcomp.2019.5.4>.  
© 2019 OMF Publishing, LLC. This is an open access article under the CC BY license (<http://creativecommons.org/licenses/by-nc/4.0/>).

[dtjournal.org](http://dtjournal.org)





**FIGURE.** Case (A, B) of the author (Nagorniak IV) demonstrates an example of primary stability of implant at the maxilla (place of a tooth 1.4). Image B: Large buccal wall defect\* (asterisk) and palatal bone gap (circle) were treated by bone grafting with guided bone regeneration using titanium mesh.

**REFERENCES**

1. Javed F, Ahmed HB, Crespi R, Romanos GE. Role of primary stability for successful osseointegration of dental implants: factors of influence and evaluation. *Interv Med Appl Sci* **2013**;5:162–7. <https://doi.org/10.1556/IMAS.5.2013.4.3>.
2. Le BT, Borzabadi-Farahani A. Simultaneous implant placement and bone grafting with particulate mineralized allograft in sites with buccal wall defects, a three-year follow-up and review of literature. *J Craniomaxillofac Surg* **2014**;42:552–9. <https://doi.org/10.1016/j.jcms.2013.07.026>.
3. Marquezan M, Osório A, Sant'Anna E, Souza MM, Maia L. Does bone mineral density influence the primary stability of dental implants? A systematic review. *Clin. Oral Impl. Res* **2012**;23:767–74. <https://doi.org/10.1111/j.1600-0501.2011.02228.x>.
4. Cobo-Vázquez C, Reininger D, Molinero-Mourelle P, González-Serrano J, Guisado-Moya B, López-Quiles J. Effect of the lack of primary stability in the survival of dental implants. *J Clin Exp Dent* **2018**;10:e14–e19. <https://doi.org/10.4317/jced.54441>.
5. Gómez-Polo M, Ortega R, Gómez-Polo C, Martín C, Celemín A, Del Río J. Does length, diameter, or bone quality affect primary and secondary stability in self-tapping dental implants? *J Oral Maxillofac Surg* **2016**;74:1344–53. <https://doi.org/10.1016/j.joms.2016.03.011>.
6. Falisi G, Severino M, Rastelli C, Bernardi S, Caruso S, Galli M. The effects of surgical preparation techniques and implant macro-geometry on primary stability: An in vitro study. *Med Oral Patol Oral Cir Bucal* **2017**;22:e201–e206.
7. Turkyilmaz I, Aksoy U, McGlumphy EA. Two alternative surgical techniques for enhancing primary implant stability in the posterior maxilla: a clinical study including bone density, insertion torque, and resonance frequency analysis data. *Clin Implant Dent Relat Res* **2008**;10(4):231–7. <https://doi.org/10.1111/j.1708-8208.2008.00084.x>.
8. Tanaka K, Sailer I, Iwama R, Yamauchi K, Nogami S, Yoda N, Takahashi T. Relationship between cortical bone thickness and implant stability at the time of surgery and secondary stability after osseointegration measured using resonance frequency analysis. *J Periodontal Implant Sci* **2018**;48:360–72. <https://doi.org/10.5051/jpis.2018.48.6.360>.

Nagorniak IV.  
 Discussion: role of primary stability for successful osseointegration of dental implants: factors of influence and evaluation.  
*J Diagn Treat Oral Maxillofac Pathol* **2019**;3:154–5.  
<https://dx.doi.org/10.23999/j.dtomp.2019.5.4>

# Future Events

for 2019-2021

## 2019

### 18th Meeting of the International Society of Craniofacial Surgery

September 16 – 19, 2019  
Paris, France

[www.iscfs.org](http://www.iscfs.org)

### American Association of Oral and Maxillofacial Surgeons: 101st Annual Meeting, Scientific Sessions and Exhibition (Fig)

September 16 – 21, 2019  
Boston, Massachusetts, USA

[www.aaoms.org](http://www.aaoms.org)

### 31st World Congress of the International College for Maxillo-Facial-Surgery (ICMFS)

October 29 – November 01, 2019  
Tel Aviv, Israel

[www.icmfs2019.com](http://www.icmfs2019.com)

### 21st International Congress of the Latin American Association of Bucomaxillofacial Surgery and the Mexican Association of Oral and Maxillofacial Surgery

December 01 – December 04, 2019  
Cancun, Mexico

[www.cialacibu2019.com/en/welcome/](http://www.cialacibu2019.com/en/welcome/)

## 2020

### 25th Congress of the European Association for Cranio-Maxillo-Facial Surgery

September 15 – 18, 2020  
Paris, France

[www.eacmfs.org](http://www.eacmfs.org)

## 2021

### 14th Quadrennial International Facial Nerve Symposium

August, 2021  
South Korea

[www.internationalfacialnerve.org](http://www.internationalfacialnerve.org)



FIGURE. Screenshot from a website [www.aaoms.org](http://www.aaoms.org).

# Submission of Articles

## Papers for the Publication

- original papers
- clinical cases (case reports)
- surgical notes
- radiological notes
- reports of new equipment, instruments or technical innovations
- journal or book reviews
- reviews of other journals articles
- letters to the Editor

## Article and Abstracts

Article must be written in English.

The authors from the Russian-speaking countries must send an abstract of the article in Russian. The authors from Ukraine must send an abstract of the article in Ukrainian and Russian.

One co-author is denominated as the corresponding author with all contact details:

- Postal address (ZIP code of a country, City, Street, phone and fax number)
- E-mail address

The abstract should include full title of the article, full names and surnames of the co-authors, affiliation, scientific degree, specialty. Also the abstract should include short information about article content: purpose, material and methods, results, conclusions. Example how the Abstract should be looked like the authors can get from the published articles in current issue.

## Figures and Tables

Photographs, CT and MRI images, sonograms should be submitted in original with resolution of at least 300 dpi and saved in JPEG or TIFF file format.

## Fundings

The authors should indicate the sources of funding that were allocated for the preparation of the article, if such were the case.

## Conflicts of Interest

At the end of the article the authors should specify about conflicts of interest (e.g., no conflict of interest).

## Role of Co-authors in Writing

After specifying conflicts of interest the role of co-authors in writing of the article (concept and design of the study; material collection, material processing, statistical data processing, writing text, editing, etc.) should be designated.

## Patient Consent

Written patient consent should be obtained to publish the clinical images of the patients.

## Acknowledgments

The authors can acknowledge the persons or institutions which they helped or useful in writing an article.

The Journal is recommended to use that internet source for the articles preparing according to *Vancouver References Style*: <http://libguides.murdoch.edu.au/Vancouver/journal>

## Examples How to Form a Reference List

List all references in numerical order in the text.

Making a list of references from articles, books, internet links, etc.:

*Example for the articles:*

Fernandes RP, Quimby A, Salman S. Comprehensive reconstruction of mandibular defects with free fibula flaps and endosseous implants. *J Diagn Treat Oral Maxillofac Pathol* **2017**;1(1):6–10.

*Example for the articles with more than three authors:*

Neto AMR, Monteiro JL, Borba PM, et al. TMJ's posterolateral dislocation with tympanic plate fracture – case report. *J Diagn Treat Oral Maxillofac Pathol* **2017**;1:59–64.

*Example for the articles from the Journal Supplement:*

Hammerle CH, Chen ST, Wilson Jr TG. Consensus statements and recommended clinical procedures regarding the placement of implants in extraction sockets. *Int J Oral Maxillofac Implants* **2004**;19(Suppl):26–8.

or

Hammerle CH, Chen ST, Wilson Jr TG. Consensus statements and recommended clinical procedures regarding the placement of implants in extraction sockets. *Int J Oral Maxillofac Implants* **2004**;19:S26–8.

*Examples for the book chapters:*

Yuen HY, Ahuja AT. Benign clinical conditions in the adjacent neck. In: Sofferman RA, Ahuja AT, editors. *Ultrasound of the thyroid and parathyroid glands*. Springer, **2012**:229–33.

*Example for the books:*

Baskin J, Duick D, Levine R. *Thyroid ultrasound and ultrasound guided FNA*. 2nd ed. New York: Springer; **2008**.

*Example for the PhD/ScD work (dissertation for candidate/doctor of science):*

Borkowski MM. *Infant sleep and feeding: a telephone survey of Hispanic Americans*. PhD [dissertation]. Mount Pleasant (MI): Central Michigan University; **2002**.

Kopchak AV. *Clinico-biological and biomechanical study of methods for surgical treatment of mandibular fractures*. ScD [dissertation]. Kyiv: Bogomolets National Medical University; **2014**.

*Example for references in Cyrillic:*

Please indicate the language of writing in square brackets [Ukrainian] or [Russian].

Tymofieiev OO. *Manual of maxillofacial and oral surgery* [Russian]. 5th ed. Kyiv: Chervona Ruta-Turs; **2012**.

Tymofieiev OO. *Diseases of the salivary glands* [Ukrainian]. 1st ed. Lviv: VNLT-Klasyka; **2007**.

*Examples for the internet links:*

Seave A. Elsevier CEO using unique data sets and analytic processes to maintain competitive edge. *The Forbes*. February 25, 2016. Available at: <https://www.forbes.com/sites/avaseave/2016/02/25/elsevier-ceo-using-unique-data-sets-and-analytic-processes-to-maintain-competitive-edge/#1d9e4b3979c2/>. Accessed February 25, 2016.

Adult improving access to psychological therapies programme. NHS England. Available from URL:

<https://www.england.nhs.uk/mental-health/adults/iapt/> (last accessed 3 March **2017**).

McManus S, Meltzer H, Brugha T, et al., editors. *Adult psychiatric morbidity in England, 2007: results of a household survey*. The NHS Information Centre for health and social care; 2017. Available from URL: <http://www.hscic.gov.uk/catalogue/PUB02931/adul-psyc-morb-reshou-sur-eng-2007-rep.pdf> (last accessed 3 March **2017**).

*Example for conference paper in print proceedings:*

Christensen S, Oppacher F. An analysis of Koza's computational effort statistic for genetic programming. In: Foster JA, Lutton E, Miller J, Ryan C, Tettamanzi AG, editors. *Genetic programming: EuroGP 2002: Proceedings of the 5th European Conference on Genetic Programming; 2002 Apr 3-5; Kinsdale, Ireland*. Berlin: Springer; **2002**. p. 182-91.

*Example for conference paper from the internet:*

Cloherly SL, Dokos S, Lovell NH. Qualitative support for the gradient model of cardiac pacemaker heterogeneity. In: Proceedings of the 2005 IEEE Engineering in Medicine and Biology 27 Annual Conference; 2005 Sep 1-4; Shanghai, China. New York: IEEE; **2005** [cited 2010 Sep 2]. p. 133-6. Available from: IEEE Xplore.

*Example for A-V materials (DVD):*

Acland RD, presenter. Acland's DVD atlas of human anatomy [DVD]. Baltimore (MD): Lippincott Williams & Wilkins; **2004**.

*Example for A-V materials (YouTube/Vimeo video):*

NRK. Medieval helpdesk with English subtitles [video file]. **2007** Feb 26 [cited 2014 Jan 28]. Available from: <http://www.youtube.com/watch?v=pQHx-SjgQvQ>

*Example for A-V materials (Video recording):*

Hillel J, writer. Out of sight out of mind: indigenous people's health in Australia [videorecording]. Bendigo: Video Education Australasia; **2003**.

*Example for Readers/Study Guides:*

Lynch M. God's signature: DNA profiling, the new gold standard in forensic science. Endeavour. 2003;27(2):93-7. Reprinted In: Forensic Investigation (BIO373) unit reader for forensic DNA component. Murdoch (WA): Murdoch University; **2005**.

*Example for newspaper articles in print:*

Hatch, B. Smoke lingers for those who keep hospitality flowing. Australian Financial Review. **2006** Jul 13: 14.

*Example for newspaper article from the internet:*

Devlin, H. Neuron breakthrough offers hope on Alzheimer's and Parkinson's. The Times [newspaper on the Internet]. **2010** Jan 28 [cited 2010 Jan 31]. Available from: <http://www.timesonline.co.uk/tol/news/science/medicine/article7005401.ece>.

*Example for conversation citation:*

In a conversation with a colleague from the School of Population Health (Jameson LI **2002**, oral communication, 7th August)...

*Example for e-mail citation:*

Smith P. New research projects in gastroenterology [online]. E-mail to Matthew Hart (mh@hospital.wa.gov.au) **2000** Feb 5 [cited 2000 Mar 17].

## **Spelling and Grammar Check**

The article should be 'spell checked' and 'grammar checked'. You can use American or British usage, but do not use mixture of them. Authors for whom English is not their native language should add an editing certificate (the international company that can provide editing is: [www.enago.com](http://www.enago.com)).

## **Free Access for All Articles**

The journal offers the free access to all articles guiding by the main principle of the journal policy, to give a possibility to colleagues from all countries (even from low-income) to use data for the development of specialties related with Oral and Maxillofacial Area.

Editorial of the Journal independently assigns for the articles Index of the Universal Decimal Classification (UDC) according to the requirements of Higher Attestation Commission of Ukraine and Digital Object Identifier (DOI) according to the international standards.

## **Questions?**

[i.i.fesenko@dtjournal.org](mailto:i.i.fesenko@dtjournal.org)



UKRAINIAN  
ASSOCIATION  
FOR MAXILLOFACIAL  
& ORAL SURGEONS  
Founded in 1996

#### **Mission Statement of the Association**

We unite, lead, and develop the maxillofacial community to accelerate theoretical and practical movement forward and improve worldwide.

#### **Address and Contacts**

4-A Profesora Pidvysotskogo Street,  
Kyiv 01103, Ukraine  
Tel., fax: +38 (044) 528 35 17.  
E-mail: [info.uamos@gmail.com](mailto:info.uamos@gmail.com)  
[www.uamos.org](http://www.uamos.org)

**May 2019**

#### **Officers**

**Oleksii O. Tymofeiev**  
(Kyiv, Ukraine)  
*President*

**Iryna G. Lisova**  
(Kharkiv, Ukraine)  
*Vice President – Salivary Glands Diseases/Tumors*

**Andrii V. Kopchak**  
(Kyiv, Ukraine)  
*Vice President – Jaws Fractures*

**Liudmyla M. Iakovenko**  
(Kyiv, Ukraine)  
*Vice President – Pediatric Maxillofacial Surgery*

**Volodymyr S. Protsyk**  
(Kyiv, Ukraine)  
*Vice President – Head & Neck Oncological Surgery*

**Yan E. Vares**  
(Lviv, Ukraine)  
*Vice President – Orthognathic Surgery*

**Olena P. Vesova**  
(Kyiv, Ukraine)  
*Vice President – Trigemial/Facial Nerve Trauma*

**Anatolii G. Guliuk**  
(Odessa, Ukraine)  
*Vice President – Cleft Surgery*

**Natalia O. Ushko**  
(Kyiv, Ukraine)  
*Vice President – Graduate Education*

**Anatolii M. Potapchuk**  
(Uzhhorod, Ukraine)  
*Vice President – Postgraduate Education*

**Kostiantyn Ya. Peredkov**  
(Kyiv, Ukraine)  
*Vice President and Secretary-Treasurer*

**Ievgen I. Fesenko**  
(Kyiv, Ukraine)  
*Technical Director*

#### **Council**

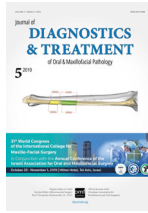**Roman O. Mamonov** (Kyiv, Ukraine)  
**Pavlo I. Tkachenko** (Poltava, Ukraine)

#### **International Council**

**Zurab Chichua** (Tbilisi, Georgia)  
**Chingiz R. Ragimov** (Baku, Azerbaijan)  
**Adnan A. Jezzini** (Beirut, Lebanon)  
**Mazen S. Tammimi** (Amman, Jordan)

### **Disclaimer**

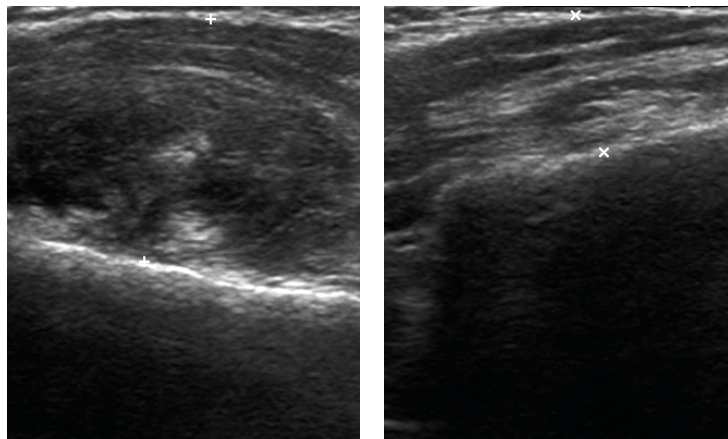
The statements and opinions expressed in publications of the *Journal* are solely those of the authors and not of the Ukrainian Association for Maxillofacial and Oral Surgeons (UAMOS). Establishing the integrity of third party resources, such as data repositories located on external websites and servers, used and cited in submissions is the responsibility of the author. All submissions are subject to external peer review as directed by the journal editors, other than UAMOS Statements, which are reviewed by the UAMOS and selected outside experts. The Editors are not permitted to engage in discussions about *Journal* content for forthcoming issues with agencies involved in soliciting advertisements, or companies purchasing advertising space. The UAMOS does not evaluate advertised products or services nor assess advertising claims. Neither the appearance of advertising in publications of the UAMOS, nor reference to a product within the same, constitutes a guarantee or endorsement of the quality or value of such product or of the claims made for it by its manufacturer. Advertisements are randomly placed, and there is no predetermined relationship between the content and the advertisement. The UAMOS reserves the right to decline or refuse advertisements.



## FORTHCOMING ARTICLES

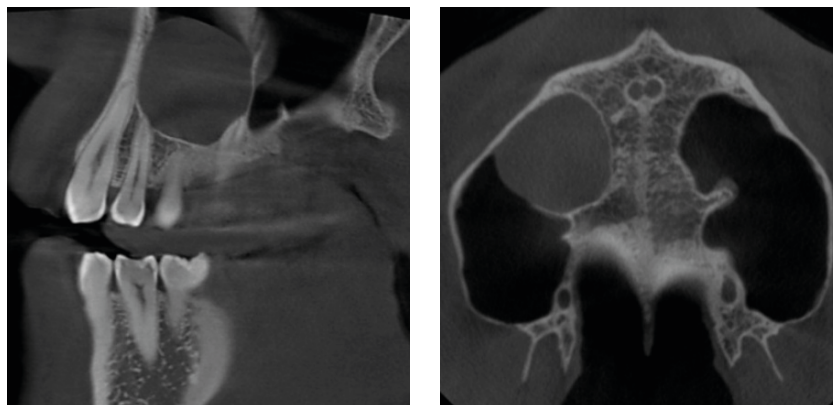
Trauma | Head Neck Ultrasound: Case Report + Video

### How Useful Is Ultrasound in Case of Traumatic Myositis Ossificans of the Masseter Muscle?



Head Neck Radiology | Benign Clinical Conditions: Case Report

### “Wait and See” Strategy: Can It Be an Advantageous Management in Case of Retention Cyst of the Maxillary Sinus with Size More Than 2.0 × 2.0 cm?



<http://dx.doi.org/10.23999/j.dtmp.2019.5.7>.

[dtjournal.org](http://dtjournal.org)



# TANTUM VERDE®

QUICK RELIEF FROM PAIN  
AND INFLAMMATION IN THE  
MOUTH AND THROAT<sup>1</sup>

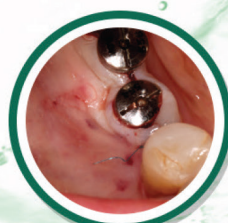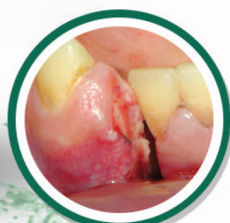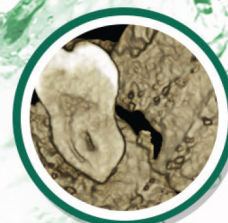
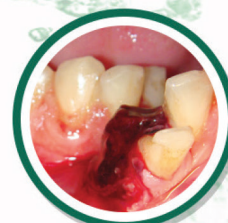**AN INTEGRAL COMPONENT OF THE TREATMENT  
OF PAIN AND INFLAMMATION IN THE ORAL CAVITY  
IN 60 COUNTRIES WORLDWIDE!<sup>2</sup>**



Reg. № UA/3920/01/01

**LOCAL ANESTHETIC  
AND ANTI-INFLAMMATORY  
EFFECT<sup>1</sup>**

- **JAWS FRACTURES<sup>3</sup>**
- **IMPLANTS PLACEMENT<sup>4</sup>**
- **WOUNDS OF ORAL CAVITY<sup>5</sup>**



#### SUMMARY OF PRODUCT CHARACTERISTICS

**NAME OF THE MEDICINAL PRODUCT.** Tantum Verde 0.15% mouthwash. **QUALITATIVE AND QUANTITATIVE COMPOSITION.** Each 100 ml contains: active ingredient: benzydamine hydrochloride 0.15 g (equivalent to 0.134 g of benzydamine). **Therapeutic indications.** Treatment of symptoms such as irritation/inflammation including those associated with pain in the oropharyngeal cavity (e.g. gingivitis, stomatitis and pharyngitis), including those resulting from conservative or extractive dental therapy. **Posology and method of administration.** Pour 15 ml of Tantum Verde mouthwash into the measuring cup, 2-3 times per day, using it either at full concentration or diluted. If diluted, add 15 ml of water to the graduated cup. Do not exceed the recommended dosage. **Contraindications.** Hypersensitivity to benzydamine or to any of the excipient. **PHARMACOLOGICAL PROPERTIES. Pharmacodynamic properties.** Pharmacotherapeutic group: Stomatologic drugs: other agents for local oral treatment, ATC code: A01AD02. Clinical studies demonstrate that benzydamine is effective in relieving suffering from localised irritation of the mouth and pharynx. In addition, benzydamine possesses a moderate local anaesthetic effect. **Pharmacokinetic properties. Absorption.** Absorption through the oropharyngeal mucosa is demonstrated by the presence of measurable quantities of benzydamine in human plasma. These levels are insufficient to produce systemic effects. **Distribution.** When applied locally, benzydamine has been shown to accumulate in inflamed tissues where it reaches effective concentrations because of its capacity to penetrate the epithelial lining.

**Information about medicines. Information for health care professionals for use in professional activities.**

1. Інструкція для медичного застосування лікарського засобу Тантум Верде®, розчин для ротової порожнини, РПН № UA/3920/01/01, затверджено Наказом Міністерства охорони здоров'я України № 636 від 01.10.2015.

2. <http://www.angelini-pharma.com/wps/wcm/connect/com/home/Angelini+Pharma+in+the+world/>

3. Тимофеев А.А. и др. "Особенности гигиены полости рта для профилактики воспалительных осложнений при переломах нижней челюсти". Современная стоматология 2015;1(75):52-8.

4, 4.5. Tymofieiev O.O. et al "Prevention of inflammatory complications upon surgeries in maxillofacial region". J Diagn Treat Oral Maxillofac Pathol. 2017;1:105-12.

Clinical and CT images are courtesy of: Ievgen Fesenko (Department of Oral & Maxillofacial Surgery, PHEI "Kyiv Medical University", Kyiv, Ukraine), Oleg Mastakov ("SCIEDECE—Scientific Center of Dentistry & Ultrasound Surgery" Kyiv, Ukraine)



04119, Kiev, Melnikova str. 83D, of. 404.  
Tel.: (044) 538-01-26  
Fax: (044) 538-01-27

