

# DT Journal

**5** 2022

**Journal of Diagnostics and  
Treatment of Oral and  
Maxillofacial Pathology**



Editors  
Oleksii Tymofieiev • Rui Fernandes  
(Kyiv, Ukraine • Jacksonville, FL, USA)



Official Journal of the  
Ukrainian Association for  
Maxillofacial and Oral Surgeons

[DTJournal.org](http://DTJournal.org)

# TANTUM VERDE®

QUICK RELIEF FROM PAIN  
AND INFLAMMATION IN THE  
MOUTH AND THROAT<sup>1</sup>

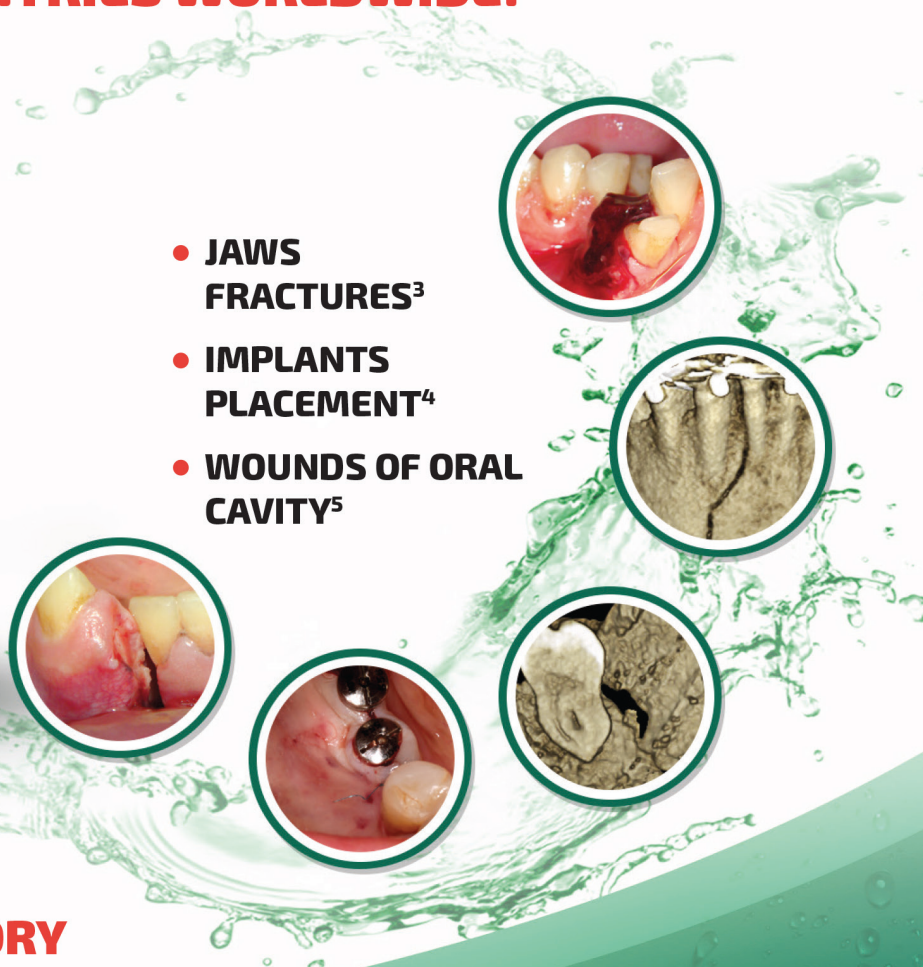**AN INTEGRAL COMPONENT OF THE TREATMENT  
OF PAIN AND INFLAMMATION IN THE ORAL CAVITY  
IN 60 COUNTRIES WORLDWIDE!<sup>2</sup>**



Reg. № UA/3920/01/01

**LOCAL ANESTHETIC  
AND ANTI-INFLAMMATORY  
EFFECT<sup>1</sup>**

- **JAWS FRACTURES<sup>3</sup>**
- **IMPLANTS PLACEMENT<sup>4</sup>**
- **WOUNDS OF ORAL CAVITY<sup>5</sup>**



#### SUMMARY OF PRODUCT CHARACTERISTICS

**NAME OF THE MEDICINAL PRODUCT.** Tantum Verde 0.15% mouthwash. **QUALITATIVE AND QUANTITATIVE COMPOSITION.** Each 100 ml contains: active ingredient: benzydamine hydrochloride 0.15 g (equivalent to 0.134 g of benzydamine). **Therapeutic indications.** Treatment of symptoms such as irritation/inflammation including those associated with pain in the oropharyngeal cavity (e.g. gingivitis, stomatitis and pharyngitis), including those resulting from conservative or extractive dental therapy. **Posology and method of administration.** Pour 15 ml of Tantum Verde mouthwash into the measuring cup, 2-3 times per day, using it either at full concentration or diluted. If diluted, add 15 ml of water to the graduated cup. Do not exceed the recommended dosage. **Contraindications.** Hypersensitivity to benzydamine or to any of the excipient. **PHARMACOLOGICAL PROPERTIES. Pharmacodynamic properties.** Pharmacotherapeutic group: Stomatologic drugs: other agents for local oral treatment, ATC code: A01AD02. Clinical studies demonstrate that benzydamine is effective in relieving suffering from localised irritation of the mouth and pharynx. In addition, benzydamine possesses a moderate local anaesthetic effect. **Pharmacokinetic properties. Absorption.** Absorption through the oropharyngeal mucosa is demonstrated by the presence of measurable quantities of benzydamine in human plasma. These levels are insufficient to produce systemic effects. **Distribution.** When applied locally, benzydamine has been shown to accumulate in inflamed tissues where it reaches effective concentrations because of its capacity to penetrate the epithelial lining.

**Information about medicines. Information for health care professionals for use in professional activities.**

1. Інструкція для медичного застосування лікарського засобу Тантум Верде®, розчин для ротової порожнини, РПН № UA/3920/01/01, затверджено Наказом Міністерства охорони здоров'я України № 636 від 01.10.2015.

2. <http://www.angelini-pharma.com/wps/wcm/connect/com/home/Angelini+Pharma+in+the+world/>

3. Тимофеев А.А. и др. "Особенности гигиены полости рта для профилактики воспалительных осложнений при переломах нижней челюсти". Современная стоматология 2015;1(75):52-8.

4, 4.5. Tymofiejew O.O. et al "Prevention of inflammatory complications upon surgeries in maxillofacial region". J Diagn Treat Oral Maxillofac Pathol. 2017;1:105-12.

Clinical and CT images are courtesy of: Ievgen Fesenko (Department of Oral & Maxillofacial Surgery, PHEI "Kyiv Medical University", Kyiv, Ukraine), Oleg Mastakov ("SCIEDECE—Scientific Center of Dentistry & Ultrasound Surgery" Kyiv, Ukraine)



04119, Kiev, Melnikova str. 83D, of. 404.  
Tel.: (044) 538-01-26  
Fax: (044) 538-01-27



# About the Journal: Aims and Scope

MAY 2022 • VOLUME 6 • ISSUE 5  
www.djournal.org

## Official Title

*Journal of Diagnostics and Treatment of Oral and Maxillofacial Pathology*

## Standard Abbreviation: ISO 4

*J. Diagn. Treat. Oral Maxillofac. Pathol.*

## Acronym

JDTOMP

## International Standard Serial Number (ISSN)

Electronic ISSN 2522-1965

## Aims & Scope

This is a monthly peer-reviewed oral and maxillofacial surgery journal focused on: microvascular and jaw reconstructive surgery, dental implants, salivary gland tumors/diseases, TMJ lesions, virtual surgical planning, implementation of ultrasonography into the practice of oral and maxillofacial surgeons.

## Editorial Board (EB) Composition

- EB shows significant geographic diversity representing 29 opinion leaders from 13 countries: Brazil, Canada, Colombia, Greece, Hong Kong (SAR, China), India, Israel, Italy, Slovak Republic, Spain, Ukraine, United Arab Emirates, and United States.
- The majority of the EB Members have a discernible publication history in Scopus, Web of Science, and journals with a high impact factor.
- The publication records of all EB members are consistent with the stated scope and published content of the journal.
- The journal has a several full-time professional editors.
- Gender distribution of the editors: 10.34% women, 89.65% men, 0% non-binary/other, and 0% prefer not to disclose.

## Frequency

12 issues a year (from January 2020)

## Publication History

2017: 4 issues a year

2018: 4 issues a year

2019: 10 issues a year

From 2020: 12 issues a year

## Publishing Model

*Journal of Diagnostics and Treatment of Oral and Maxillofacial Pathology* is a fully online-only open access and peer-reviewed publication.

## Type of Peer Review

The journal employs “double blind” reviewing.

## Article Publishing Charge (APC)

The APC in this journal is 100 USD and 50 USD (excluding taxes) depending on the article’s type. Details at website: [dtjournal.org](http://dtjournal.org).

## 13 Types of Articles Currently Published by the Journal

Editorials/Guest Editorials/Post Scriptum Editorials, Images, Case Reports/Case Series, Original Articles, Review Articles, Discussions, Paper Scans (*synonyms*: Review of Articles, Literature Scan), Book Scans (*synonym*: Book Reviews), Letters to the Editor (*synonym*: Letters), and Viewpoints.

## State Registration: Ministry of Justice of Ukraine

Registration: Jul 28, 2016 (Certificate: KB № 22251-12151 P)

Re-registration: May 21, 2019 (Certificate: KB № 23999-13839 IIP)

Re-registration: Aug 10, 2021 (Certificate: KB № 24951-14891 IIP)

## Co-Founders

1. Shupyk National Healthcare University of Ukraine (formerly known as Shupyk National Medical Academy of Postgraduate Education).
2. Private Higher Educational Establishment “Kyiv Medical University.”
3. OMF Publishing, Limited Liability Company.

## Publisher

OMF Publishing, LLC is an academic publisher focused on medical and linguistic sciences.

Address: 13-A Simferopolska Street, office 121, Kyiv 02096, Ukraine.

## Crossref Membership

OMF Publishing, LLC is a member of Publishers International Linking Association, Inc. which doing business as a Crossref. OMF Publishing’s active membership: From February 2017 to present.

## Official Journal of the Association

Ukrainian Association for Maxillofacial and Oral Surgeons

## Ukrainian Association for Maxillofacial and Oral Surgeons (UAMOS)

Address: 4-A Profesora Pidvysotskoho Street, Kyiv 01103, Ukraine.

Tel., fax: +38 044 528 35 17.

Website: [uamos.org](http://uamos.org).

© 2022 OMF PUBLISHING, LLC

# Editorial Board

MAY 2022 • VOLUME 6 • ISSUE 5  
www.djournal.org

## Editor in Chief

**Oleksii O. Tymofieiev, ScD**  
Kyiv, Ukraine

## Deputy Editor in Chief

**Rui P. Fernandes, MD, DMD, FACS, FRCS(Ed)**  
Jacksonville, Florida, United States

## Section Editors

### Bone Augmentation Techniques

**Nardy Casap, MD, DMD**  
Jerusalem, Israel

### Business

**Ivan V. Nagorniak, MSc, PhD**  
Kyiv, Ukraine

### Craniofacial Deformities

**Sunil Richardson, MDS**  
Nagercoil, Tamil Nadu, India

### Facial Feminization Surgery

**Kyle Keojampa, MD, FACS**  
Los Angeles, California, United States

### Facial Plastic Surgery

**Tirbod Fattahi, MD, DDS, FACS**  
Jacksonville, Florida, United States

### Head & Neck Oncologic Surgery

**Todd C. Hanna, MD, DDS, FACS**  
New York, New York, United States

### Head & Neck Radiology

**Anil T. Ahuja, MBBS, MD, FRCR, FHKCR, FHKAM**  
Hong Kong, SAR, China

### Images

**Camilo Mosquera, DDS**  
Bogotá, D.C., Colombia

### Orthognathic Surgery

**Mario Brinhole**  
São Paulo, São Paulo, Brazil

### Robotic Surgery

**Salam O. Salman, MD, DDS, FACS**  
Jacksonville, Florida, United States

### TMJ Lesions/Disorders

**Belmiro C. Vasconcelos, DDS, PhD**  
Recife, Pernambuco, Brazil

## Editorial Board Members

**Oleh M. Antonyshyn, MD, FRCS(C)**  
Toronto, Ontario, Canada

**Anthony M. Bunnell, MD, DMD, FACS**  
Jacksonville, Florida, United States

**Nur A. Hatab, DMD, PhD**  
Ras Al Khaimah, United Arab Emirates

**Andrey V. Kopchak, ScD**  
Kyiv, Ukraine

**Olindo Massarelli, MD, PhD, FEBOMFS**  
Sassari, Italy

**Anastasiya Quimby, DDS, MD**  
Fort Lauderdale, Florida, United States

**Daniel Robles Cantero, DDS, MSc**  
Madrid, Spain

**Peter Stanko, MD, PhD**  
Bratislava, Slovak Republic

**Rostyslav M. Stupnytskyi, ScD**  
Kyiv, Ukraine

**Olexander O. Tymofieiev, ScD**  
Kyiv, Ukraine

**Natalia O. Ushko, ScD**  
Kyiv, Ukraine

**Andrew Yampolsky, DDS, MD**  
Philadelphia, Pennsylvania, United States

## Web & Social Media Editor

**João L. Monteiro, DDS**  
Boston, Massachusetts, United States

## Director, Journal Development Department

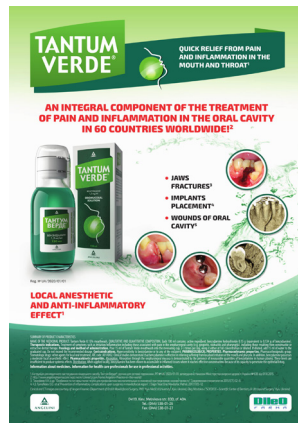**Evangelos G. Kilipiris, DMD**  
Thessaloniki, Greece | Bratislava, Slovak  
Republic

## Managing Editor

**Ievgen I. Fesenko, PhD**  
Kyiv, Ukraine

## Resident Ambassador

**John M. Le, DDS, MD**  
Birmingham, Alabama, United States



# TANTUM VERDE®

INFORMATION LEAFLET  
for the medicinal product

## **Composition:**

*active substance:* **benzydamine hydrochloride;**

100 mL of solution contain benzydamine hydrochloride 0.15 g;

*excipients:* ethanol 96%, glycerol, methyl parahydroxybenzoate (E 218), flavor (menthol), saccharin, sodium hydrocarbonate, Polysorbate 20, Quinoline Yellow (E 104), Patent Blue V (E 131), purified water.

**Dosage form.** Oromucosal solution.

*Basic physical and chemical properties:* a clear green liquid with a typical mint flavor.

**Pharmacotherapeutic group.** Dental preparations. Other agents for local oral treatment.

ATC code: A01A D02.

## **Pharmacological properties.**

### *Pharmacodynamics.*

Benzydamine is a non-steroidal anti-inflammatory drug (NSAID) with analgesic and antiexudative properties.

Clinical studies have shown that benzydamine is effective in the relief of symptoms accompanying localized irritation conditions of the oral cavity and pharynx. Moreover, benzydamine has anti-inflammatory and local analgesic properties, and also exerts a local anesthetic effect on the oral mucosa.

### *Pharmacokinetics.*

Absorption through the oral and pharyngeal mucosa has been proven by the presence of measurable quantities of benzydamine in human plasma. However, they are insufficient to produce any systemic pharmacological effect. The excretion occurs mainly in urine, mostly as inactive metabolites or conjugated compounds.

When applied locally, benzydamine has been shown to cumulate in inflamed tissues in an effective concentration

due to its ability to permeate through the mucous membrane.

## **Clinical particulars.**

### **Indications.**

Symptomatic treatment of oropharyngeal irritation and inflammation; to relieve pain caused by gingivitis, stomatitis, pharyngitis; in dentistry after tooth extraction or as a preventive measure.

### **Contraindications.**

Hypersensitivity to the active substance or to any other ingredients of the product.

### **Interaction with other medicinal products and other types of interaction.**

No drug interaction studies have been performed.

### **Warnings and precautions.**

If sensitivity develops with long-term use, the treatment should be discontinued and a doctor should be consulted to get appropriate treatment.

In some patients, buccal/pharyngeal ulceration may be caused by severe pathological processes. Therefore, the patients, whose symptoms worsen or do not improve within 3 days or who appear feverish or develop other symptoms, should seek advice of a physician or a dentist, as appropriate.

Benzydamine is not recommended for use in patients hypersensitive to acetylsalicylic acid or other non-steroidal anti-inflammatory drugs (NSAIDs).

The product can trigger bronchospasm in patients suffering from or with a history of asthma. Such patients should be warned of this.

For athletes: the use of medicinal products containing ethyl alcohol might result in positive antidoping tests considering the limits established by some sports federations.

#### *Use during pregnancy or breast-feeding*

No adequate data are currently available on the use of benzydamine in pregnant and breastfeeding women. Excretion of the product into breast milk has not been studied. The findings of animal studies are insufficient to make any conclusions about the effects of this product during pregnancy and lactation.

The potential risk for humans is unknown.

TANTUM VERDE should not be used during pregnancy or breast-feeding.

#### *Effects on reaction time when driving or using machines*

When used in recommended doses, the product does not produce any effect on the ability to drive and operate machinery.

#### **Method of administration and doses.**

Pour 15 mL of TANTUM VERDE solution from the bottle into the measuring cup and gargle with undiluted or diluted product (15 mL of the measured solution can be diluted with 15 mL of water). Gargle 2 or 3 times daily. Do not exceed the recommended dose.

#### *Children.*

The product should not be used in children under 12 years due to a possibility of ingestion of the solution when gargling.

#### **Overdosage.**

No overdose has been reported with benzydamine when used locally. However, it is known that benzydamine, when ingested in high doses (hundreds times higher than those possible with this dosage form), especially in children, can cause agitation, convulsions, tremor, nausea, increased sweating, ataxia, and vomiting. Such acute overdose requires immediate gastric lavage, treatment of fluid/salt imbalance, symptomatic treatment, and adequate hydration.

#### **Adverse reactions.**

Within each frequency group, the undesirable effects are presented in order of their decreasing seriousness.

Adverse reactions are classified according to their frequency: very common ( $\geq 1/10$ ); common ( $\geq 1/100$  to  $<1/10$ ); uncommon ( $\geq 1/1,000$  to  $<1/100$ ); rare ( $\geq 1/10,000$  to  $<1/1,000$ ); very rare ( $<1/10,000$ ); frequency unknown (cannot be estimated from the available data).

*Gastrointestinal disorders:* rare – burning mouth, dry mouth; *unknown* – oral hypesthesia, nausea, vomiting, tongue edema and discoloration, dysgeusia.

*Immune system disorders:* rare – hypersensitivity reaction, *unknown* – anaphylactic reaction.

*Respiratory, thoracic and mediastinal disorders:* very rare – laryngospasm; *unknown* – bronchospasm.

*Skin and subcutaneous tissue disorders:* uncommon – photosensitivity; very rare – angioedema; *unknown* – rash, pruritus, urticaria.

*Nervous system disorders:* *unknown* – dizziness, headache.

TANTUM VERDE contains methyl parahydroxybenzoate, which can cause allergic reactions (including delayed-type reactions).

**Shelf life.** 4 years.

#### **Storage conditions.**

Do not store above 25°C. Keep out of reach of children.

#### **Packaging.**

120 mL of solution in a bottle with a measuring cup; 1 bottle per cardboard box.

#### **Dispensing category.**

Over-the-counter medicinal product.

#### **Manufacturer.**

Aziende Chimiche Riunite Angelini Francesco A.C.R.A.F. S.p.A., Italy.

Location of the manufacturer and its business address.  
Via Vecchia del Pinocchio, 22 – 60100 Ancona (AN), Italy.

#### **Date of the last revision of the text.**

September 26, 2018.

Information leaflet is

**APPROVED** by

Order of the

**Ministry of Health of Ukraine**

No. 636 dated 01.10.2015

**Registration Certificate**

No. UA/3920/01/01

# Our Supporters

MAY 2022 • VOLUME 6 • ISSUE 5  
www.djournal.org



**FIGURE.** Evangelos G. Kilipiris, MD, DMD from the National Institute of Children’s Diseases and Faculty of Medicine at Comenius University, Bratislava, Slovak Republic. A kind support of Dr. Kilipiris during the 5 years at the position of Director, Journal Development Department helped our journal to move forward and to evolve. An honorary plaque was presented to him on behalf of the Chief Editor with words “To a Founding Director, Author of Multiple Articles and Reviews, Great Thanks and Appreciation.” Photo was taken on November 23, 2021.

# Content

of the Volume 6 • Issue 5 • May 2022

A1 **Publisher & Editorial Office Information**

A2 **Editorial Board**

A5 **Our Supporters**

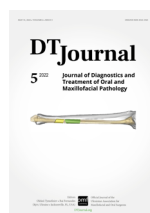
A6 **Content, Courtesy, & Erratum**

EDITORIAL

69 **The War in Europe: An Elsevier Academic Publishing Company Cordially Supports Oral and Maxillofacial Surgeons and Scientists in Ukraine**  
Ievgen I. Fesenko

CASE

71 **Surgery in the Area of Accessory Infraorbital Foramen and Nerve: Cone-Beam Computed Tomography versus Intraoperative Appearance**  
Artur V. Kuchynskyi & Ievgen I. Fesenko



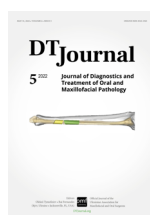COURTESY

*Journal's* cover image (virtual surgical planning for a segmental mandibular reconstruction with fibula transplant) is courtesy of Rui P. Fernandes, MD, DMD, FACS, FRCS.

Image was taken from the article: Fernandes RP, Quimby A, Salman S. Comprehensive reconstruction of mandibular defects with free fibula flaps and endosseous implants. *J Diagn Treat Oral Maxillofac Pathol* 2017;1(1):6–10.

<https://doi.org/10.23999/j.dtomp.2017.1.1>





## EDITORIAL

# The War in Europe: An Elsevier Academic Publishing Company Cordially Supports Oral and Maxillofacial Surgeons and Scientists in Ukraine

Ievgen I. Fesenko

*We are deeply saddened and outraged by the tragic events unfolding in Ukraine and the devastating impact of this war on humanity. ... Elsevier would also like to ensure Ukrainian researchers able to continue their work now, or in the near future have continued access to our research articles and books. ... We would like to extend complimentary access to ScienceDirect throughout the duration of this crisis.*

—Laura Hassink  
Managing Director, STM Journals  
(E-mail correspondence)

ScienceDirect® is a registered trademark of Elsevier B.V.—an academic publishing company headquartered in Amsterdam, Netherlands with offices worldwide.<sup>1</sup> ScienceDirect contains more than 18 million articles and chapters and >2,650 peer-reviewed journals.<sup>2</sup>

Multiple peer-reviewed journals from the subject categories “Oral Surgery,” “Surgery,” and “Otorhinolaryngology” are always in the field of view

of the Ukrainian oral and maxillofacial surgeons. Many of those journals are published by Elsevier B.V., and for the wartime period this international publishing company gave to surgeons in Ukraine a full access to all its journals (Fig 1). Such opportunity is limitless useful due to the possibility to absorb international data and surgical techniques without subscriptions or payments.

Russian terroristic invasion to Ukraine<sup>3-5</sup> increased a need for Ukrainian oral and maxillofacial surgeons, trauma and plastic surgeons to manage significant number of severe ballistic and explosive trauma cases. Implementation of modern surgical principles<sup>6-8</sup> into wartime practice is crucial for life-saving surgeries. Thus, the scientific support of Elsevier company will definitely contribute to lives` preservation and health of the Europeans.

This beautiful act of humanity and contribution from the Elsevier company to surgery, peace and prosperity on the European continent cannot be underestimated and measured, but will definitely help in a fight for the better future of human kind.

Managing Editor, *JDTOMP*, Kyiv, Ukraine

Corresponding author's address: Editorial office, *Journal of Diagnostics and Treatment of Oral and Maxillofacial Pathology (JDTOMP)*. 13-A Simferopolska Street, Kyiv 02096, Ukraine.  
E-mail: [i.i.fesenko@dtjournal.org](mailto:i.i.fesenko@dtjournal.org)

Please cite this article as: Fesenko II. The war in Europe: an Elsevier academic publishing company cordially supports oral and maxillofacial surgeons and scientists in Ukraine. *J Diagn Treat Oral Maxillofac Pathol* 2022;6(5): 69–70.

Paper received 14 May 2022  
Accepted 15 May 2022  
Available online 31 May 2022

<https://doi.org/10.23999/j.dtomp.2022.5.1>

© 2022 OMF Publishing, LLC. This is an open access article under the CC BY license (<http://creativecommons.org/licenses/by-nc/4.0/>).

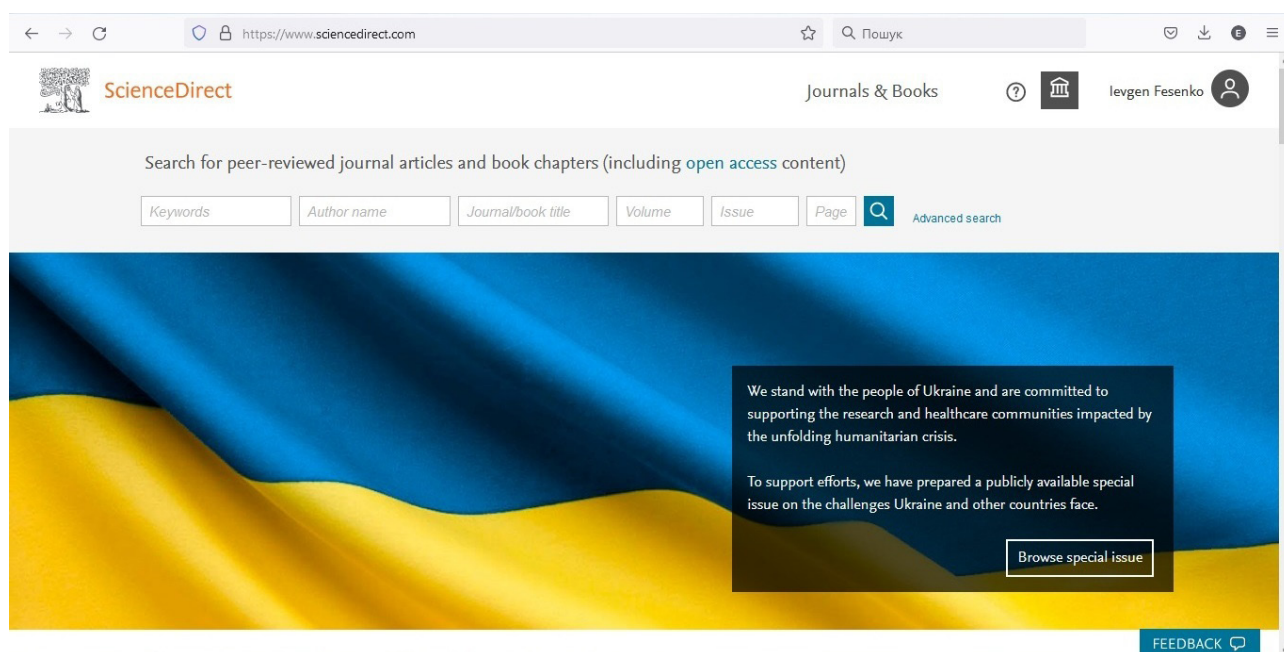


FIGURE 1. The laptop screenshot from the ScienceDirect.com platform as of May 08, 2022.

*Ukraine is literally fighting for our future.*<sup>9</sup>  
—Jaroslav Nad  
Slovakia`s defense minister

## REFERENCES (9)

1. ScienceDirect [document on the internet]; 12 Apr 2022 [cited 12 Apr 2022]. Available from: <https://www.elsevier.com/about/>
2. Elsevier: about [document on the internet]; 21 Apr 2022 [cited 21 Apr 2022]. Available from: <https://www.elsevier.com/solutions/sciencedirect>
3. Fesenko II. Stop the war! Europeans, homes, kindergartens, hospitals, universities, and global science are under the missiles. *J Diagn Treat Oral Maxillofac Pathol* 2022;6(2):32–4. <https://doi.org/10.23999/j.dtomp.2022.2.3>
4. Kilipiris EG. The heroes of the 21st century. *J Diagn Treat Oral Maxillofac Pathol* 2022;6(3):37–8. <https://doi.org/10.23999/j.dtomp.2022.3.2>
5. Guardian staff. Russia-Ukraine war: what we know on day 81 of the invasion [document on the internet]; 15 May 2022 [cited 16 May 2022]. Available from: <https://www.theguardian.com/world/2022/may/15/russia-ukraine-war-what-we-know-on-day-81-of-the-invasion>
6. Breeze J, Tong D, Gibbons A. Contemporary management of maxillofacial ballistic trauma. *Br J Oral Maxillofac Surg* 2017;55(7):661–5. <https://doi.org/10.1016/j.bjoms.2017.05.001>
7. Khatib B, Gelesko S, Amundson M, Cheng A, Patel A, Bui T, Dierks EJ, Bell RB. Updates in management of craniomaxillofacial gunshot wounds and reconstruction of the mandible. *Facial Plast Surg Clin North Am* 2017;25(4):563–76. <https://doi.org/10.1016/j.fsc.2017.06.007>
8. Tymofieiev OO. Manual of Maxillofacial and Dental Surgery [in Russian]. 5th edition. Kyiv: Chervona Ruta-Turs; 2012.
9. Higgins A. Hiding in plain sight, a Soviet-era air defense system arrives in Ukraine [document on the internet]; 15 Apr 2022 [cited 20 Apr 2022]. Available from: <https://www.nytimes.com/2022/04/14/world/europe/ukraine-russia-nato-s300.html>



## CASE

# Surgery in the Area of Accessory Infraorbital Foramen and Nerve: Cone-Beam Computed Tomography versus Intraoperative Appearance

Artur V. Kuchynskiy<sup>a</sup> & Ievgen I. Fesenko<sup>b,\*</sup>

## SUMMARY

We present a unique comparison of cone-beam computed tomography (CBCT) and intraoperative view of the accessory infraorbital foramen and nerve in a 60-year-old woman who was surgically treated due to the giant dentigerous cyst of the maxillary sinus from ectopic upper third molar. CBCT imaging demonstrates highest level of accuracy in verification of the accessory infraorbital foramina what makes this imaging technique a perfect tool for the surgery planning in the area of middle face. Avoidance of iatrogenic trauma of both infraorbital and accessory nerves will be ensured significantly in professionals who understand this topic. Oral and maxillofacial surgeons and doctors of neighboring specialties should be aware of such unusual anatomic variation as unilateral or even bilateral accessory infraorbital foramina and intraosseous nerve ramification.

Kyiv, Ukraine

<sup>a</sup> Doctor-Stomatologist-Surgeon (DSS), Department of Maxillofacial Surgery, Communal Non-Profit Enterprise "Kyiv City Clinical Hospital #12."

<sup>b</sup> Doctor-Stomatologist-Surgeon (DSS), PhD, Associate Professor, Department of Oral and Maxillofacial Surgery, Private Higher Educational Establishment "Kyiv Medical University."

\* Corresponding author's address: Department of Oral and Maxillofacial Surgery on the basis of Communal Non-Profit Enterprise "Kyiv City Clinical Hospital #12," Private Higher Educational Establishment "Kyiv Medical University," 4A Profesora Pivdysotskoho Street, Kyiv 01103, Ukraine.

E-mail: [eugenfesenko@gmail.com](mailto:eugenfesenko@gmail.com) (Ievgen Fesenko)

ORCID: <https://orcid.org/0000-0002-8901-1632>

Instagram: [@dr\\_eugenfesenko](https://www.instagram.com/dr_eugenfesenko)

Facebook: [Eugene Fesenko](#)

Please cite this article as: Kuchynskiy AV, Fesenko II. Surgery in the area of accessory infraorbital foramen and nerve: cone-beam computed tomography versus intraoperative appearance. J Diagn Treat Oral Maxillofac Pathol 2022;6(5):71–6.

Abbreviation 'CBCT' at the upper right icon means that article contains cone-beam computed tomography images.

Paper received 02 March 2022

Accepted 11 May 2022

Available online 31 May 2022

<https://doi.org/10.23999/j.dtmp.2022.5.2>

© 2022 OMF Publishing, LLC. This is an open access article under the CC BY license (<http://creativecommons.org/licenses/by-nc/4.0/>).

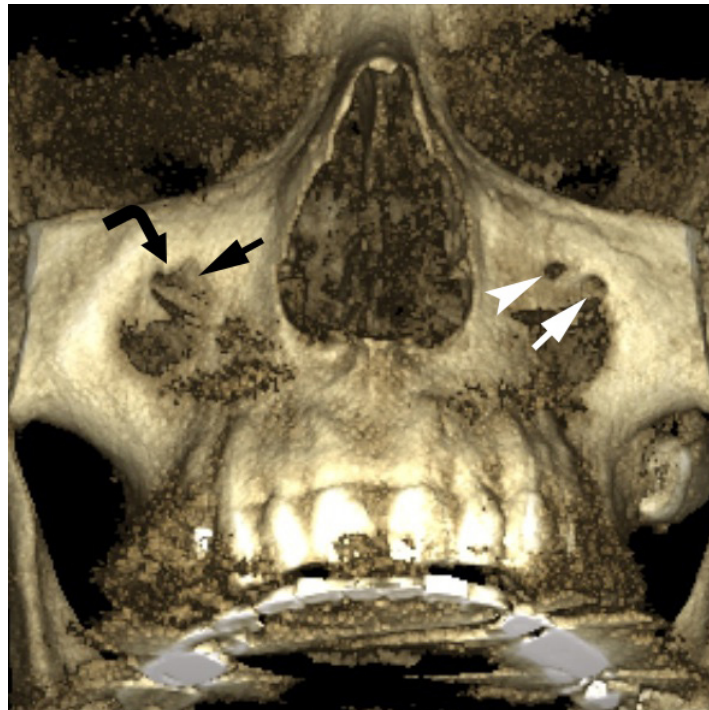
## INTRODUCTION

Direct visualization of infraorbital nerve (IN) with accessory infraorbital foramen (AIF) and nerve is not common during the maxillofacial surgery procedures. Bahrami et al (2016) presented an intraoperative view of the right duplicated IN upon the facial bones osteosynthesis.<sup>1</sup> We remember, that part of the maxillary branch of the trigeminal nerve which is going in the orbital floor terms as IN. According to the available data, IN can give an accessory branch before<sup>2</sup> and inside infraorbital canal<sup>3</sup>. Gruber in 1875 reported that number of IN foramens at every hemiface can reach even the number of 5.<sup>4</sup> Understanding the anatomy of this anatomic area is important for local anesthesia performance<sup>5</sup>, percutaneous V2 (i.e., second branch of the fifth cranial nerve [trigeminal nerve]) ablation,<sup>3</sup> nerve decompression,<sup>6</sup> osteosynthesis, etc. No English-literature data of the comparison of the cone-beam computed tomography (CBCT) and intraoperative view of accessory infraorbital nerve (AIN) have been noted during the literature search. Thus, we present a unique comparison of computed tomography imaging and intraoperative view of

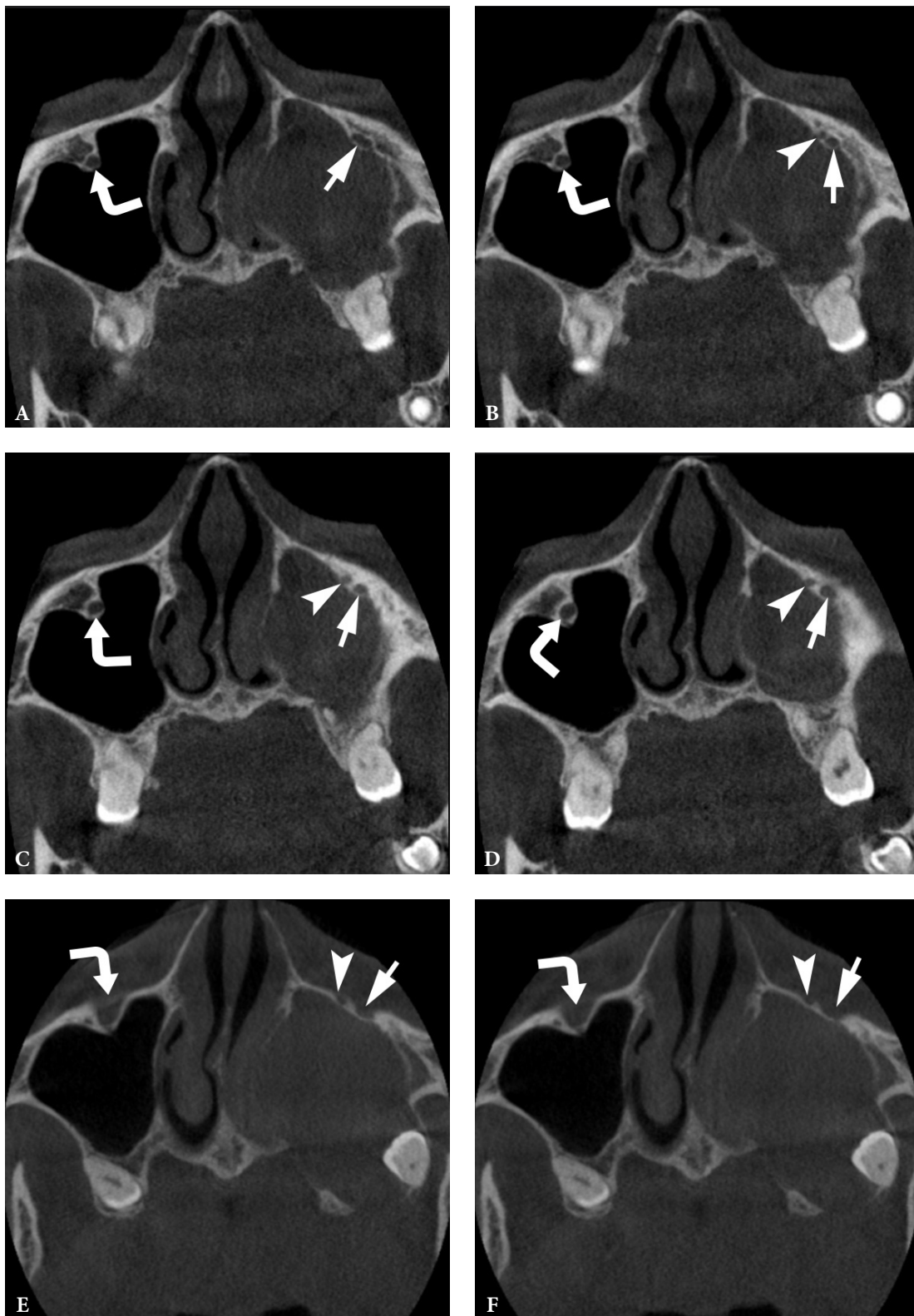
the accessory infraorbital foramen and nerve in a 60-year-old woman who was surgically treated due to the gigantic follicular cyst of the maxillary sinus.

## CASE REPORT

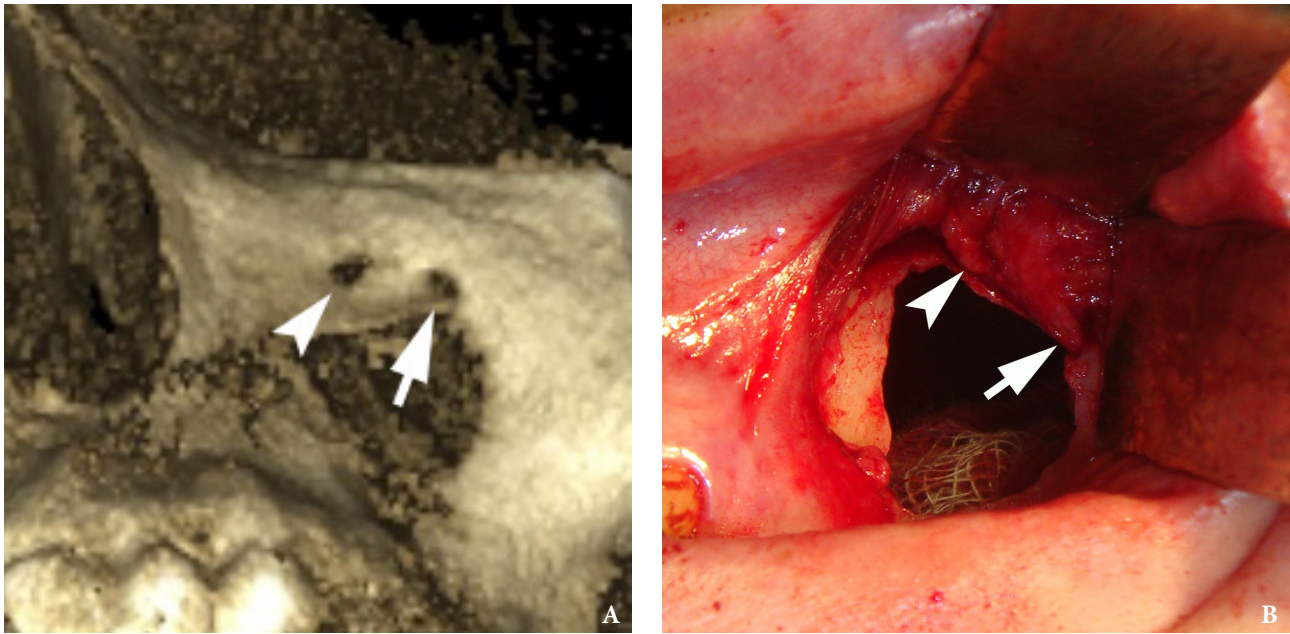
A case of 60-year-old female with a left eye tearing due to the nasolacrimal duct obstruction by gigantic follicular cyst of the left maxillary sinus from the upper left third molar was reported in the previous study.<sup>7</sup> The preoperative CBCT (Planmeca ProMax 3D Max, Planmeca, Finland) (Fig 1) showed a small bony lingula above the wide right infraorbital foramen measured  $4.62 \times 3.11$  mm. Left infraorbital foramen and accessory foramen measured  $2.60 \times 1.90$  mm and  $1.82 \times 1.79$  mm respectively. AIF was located 2.56 mm medially and slightly superiorly. The left infraorbital canal has bifurcated at the last third of its length (Fig 2). No CBCT data of accessory infraorbital canals and foramina at the right side have been noted on all scans. Two widely spaced infraorbital foramina with two thick INs were directly visualized (Fig 3B) upon the osteotomy of the anterior wall of the left maxillary sinus and cyst removal.



**FIGURE 1.** The preoperative three-dimensional CBCT image shows a small bony projection (i.e., lingula) (*black curved arrow*) above the wide right infraorbital foramen (*black arrow*) measured  $4.62 \times 3.11$  mm. Left infraorbital foramen (*white arrow*) and accessory foramen (*white arrowhead*) measured  $2.60 \times 1.90$  mm and  $1.82 \times 1.79$  mm. Printed with permission and copyrights retained by I.I.F.



**FIGURE 2.** Comparison of preoperative anteriorly rotated axial CBCT scans. Image **A** shows right infraorbital canal (*curved arrow*) and left infraorbital canal (*arrow*) prior to bifurcation. Images **B**, **C**, and **D** show the course of right (*curved arrow*), left infraorbital canal (*arrow*) and accessory canal (*arrowhead*). No CBCT data of accessory infraorbital canal and foramen at the right side have been noted on all scans. Images **E** and **F** show right (*curved arrow*) and left infraorbital foramen (*arrow*) and accessory foramen (*arrowhead*). Printed with permission and copyrights retained by I.I.F.



**FIGURE 3.** The preoperative three-dimensional CBCT image (A) shows the infraorbital foramen (*arrow*) and medially located accessory infraorbital foramen (*arrowhead*) at the left side. Two thick infraorbital neurovascular bundles were visualized intraoperatively (B): *Arrow* labels the left infraorbital nerve and *arrowhead* – the accessory infraorbital nerve. Printed with permission and copyrights retained by I.I.F.

**DISCUSSION**

Analysis of the English-language literature showed that unilateral two separate IN branches during the *cadaver dissection* of a 69-year-old male highlighted by Tubbs et al (2010) looks very similar to our *clinical case*.<sup>3</sup> The differences between case of the Bahrami et al (2016) with intraoperative AIN view and our case are presented in the Table 1.<sup>1</sup>

The analysis of 1,064 skulls by Bressan et al (2004) revealed that accessory infraorbital foramina (AIFa) were noted in 4.7 percent of skulls.<sup>8</sup> Dissection of 44 hemifaces from 25 cadavers presented in the study of Shin et al (2020) showed that AIF can be found

in 18.2 percent of cases.<sup>9</sup> It is of interest that in 2.72 percent of cases the AIF was noted bilaterally.<sup>9</sup>

Presented cadaver study with 94 hemifaces, reported by Aziz et al (2020), showed the evidence of possible quadruple ipsilateral IN what is close to the INs number in the study of Gruber.<sup>10,4</sup>

Chandra and Kennedy (2004) emphasized that IN is particularly at risk during a Caldwell-Luc antrostomy<sup>11</sup> which was done in our case. In the post-operative period, no hypoesthesia, paresthesia, or neuralgia has been noted.

A “classic location” of IN without AIN and with reference to the tissues for the nerve block performance is described by Shin et al (2020) what

**TABLE 1.** Comparison of Published Cases with Intraoperative View of the Accessory Infraorbital Foramina and Nerves.

	Age (Years)/ Sex	Diagnosis	Surgery	Imaging	Infraorbital area	Number of accessory foramina
Bahrami et al (2016) <sup>1</sup>	20/male	Mid face fracture	Open reduction and osteosynthesis	No	Right	One
Our case	60/female	Gigantic follicular cyst of the left maxillary sinus from the upper left third ectopic molar	Caldwell-Luc antrostomy with cystectomy and ectopic tooth #2.8 removal	CBCT	Left	One

is extremely useful for understanding the extraoral route of anesthesia.<sup>12</sup> Moreover, ultrasound-guided IN block is also proposed by Michalek et al (2013).<sup>13</sup> Anyway, a meticulous computed tomography analysis before the IN block and midface bone surgery will make the anesthesia and surgery performance smoother.<sup>14</sup> Recommendations of Kazkayasi et al (2003) and Iwanaga et al (2020) on the Le Fort osteotomy and AINs are also need to taken into account before surgery.<sup>15,16</sup>

One of the possible routes of pterygopalatine anesthesia (i.e., V2 nerve block) is a needle movement through the infraorbital canal (i.e., orbital route of maxillary nerve block).<sup>5</sup> It is well to bear in mind that the diameter of the canal, its curvature, and presence of possible accessory canal can contribute to anesthesia performance failure.

The data of Canan et al (1999) will be helpful for doctors in anesthesia performance.<sup>17</sup> The analysis of 229 maxilla revealed that single AIF was present in 11.5 percent of specimens and double AIF – in 1.28 percent of specimens.<sup>17</sup>

Hwang et al (2015) perfectly summarize 13 articles among the 166 PubMed searched papers with a term *infraorbital foramen*.<sup>18</sup> They concluded that in 92.2 percent of AIN cases it's located at the superomedial side of the infraorbital foramen.<sup>18</sup> That knowledge is useful during anesthetization of the infraorbital area and maxillary bone.

Rusu et al (2020) insist on a need to distinguish true, false AIFa and the infraorbital lamina cribriformis.<sup>19</sup> In their retrospective CBCT study of 200 patients, the AIFa at the sutura notha of the frontal process of maxillary bone is well illustrated.<sup>19</sup>

In summary, oral and maxillofacial surgeons and doctors of neighboring specialties should be aware of such unusual anatomic variation as unilateral or even bilateral accessory infraorbital foramina and intraosseous nerve ramification. Usage of cone-beam computed tomography proved its efficacy in verification of the accessory infraorbital foramina what make this imaging technique a perfect tool for the surgery planning in the area of middle face. Avoidance of iatrogenic trauma of infraorbital nerve and accessory nerve will be ensured significantly in professionals who understand this topic.

#### TERM OF CONSENT

No needed.

#### AUTHOR CONTRIBUTIONS

Conceptualization: Fesenko II. Data acquisition: Kuchynskyi AV, Fesenko II. Data analysis or interpretation: Kuchynskyi AV. Drafting of the manuscript: Fesenko II. Critical revision of the manuscript: Fesenko II, Kuchynskyi AV. Approval of the final version of the manuscript: all authors.

#### CONFLICT OF INTERESTS

The authors declare no conflict of interest.

#### FUNDINGS

No funding was received for this study.

#### REFERENCES (19)

1. Bahrami A, Saman M, Ducic Y. Duplicate infraorbital nerve—an uncommon anatomical variation. *JSM Oro Facial Surg* 2016;1(1):1001.
2. Jordan J. Double infraorbital nerve in man. *Folia Morphol* 1967;26:405–7.
3. Tubbs RS, Loukas M, May WR, Cohen-Gadol AA. A variation of the infraorbital nerve: its potential clinical consequence especially in the treatment of trigeminal neuralgia: case report. *Neurosurgery* 2010;67(3 Suppl Operative):onsE315; discussion onsE315. <https://doi.org/10.1227/01.NEU.0000374675.19487.FA>
4. Gruber W. Uber die infraorbitalen Kanale des Menschen und der Säugetiere [in German]. *Mem Acad Imp Sci St Petersburg* 1874;21:1–27.
5. Tymofieiev OO, Fesenko II. Anesthesia in oral and maxillofacial surgery. 1st edition. Kyiv: OMF Publishing; 2016. <https://doi.org/10.23999/b.aoms.2016.full>
6. Sosin M, De La Cruz C, Christy MR. Endoscopic-assisted infraorbital nerve release. *Case Reports Plast Surg Hand Surg* 2014;1(1):20–2. <https://doi.org/10.3109/23320885.2014.987286>
7. Babkina TM, Shekera OG, Storozhchuk YO, Telukha KI, Nozhenko OA, Fesenko II, Zaritska VI, Snisarevskyi PP. Gigantic dentigerous cysts associated with the ectopic/impacted upper third molars: computed tomography analysis of nasolacrimal duct and osteomeatal complex obstructions and review of literature. *J Diagn Treat Oral Maxillofac Pathol* 2020;4(5):79–94. <https://doi.org/10.23999/j.dtomp.2020.5.1>
8. Bressan C, Geuna S, Malerba G, Giacobini G, Giordano M, Robecchi MG, Vercellino V. Descriptive and topographic anatomy of the accessory infraorbital

- foramen. Clinical implications in maxillary surgery. *Minerva Stomatol* **2004**;53(9):495–505.
9. Shin KJ, Lee SH, Park MG, Shin HJ, Lee AG. Location of the accessory infraorbital foramen with reference to external landmarks and its clinical implications. *Sci Rep* **2020**;10(1):8566.  
<https://doi.org/10.1038/s41598-020-65330-4>
  10. Aziz SR, Marchena JM, Puran A. Anatomic characteristics of the infraorbital foramen: a cadaver study. *J Oral Maxillofac Surg* **2000**;58(9):992–6.  
<https://doi.org/10.1053/joms.2000.8742>
  11. Chandra RK, Kennedy DW. Surgical implications of an unusual anomaly of the infraorbital nerve. *Ear Nose Throat J* **2004**;83(11):766–7.
  12. Shin KJ, Shin HJ, Lee SH. Location of the infraorbital foramen with reference to soft tissue landmarks for regional nerve blocks during midface surgery. *Clin Anat* **2020**;1–5.  
<https://doi.org/10.1002/ca.23556>
  13. Michalek P, Donaldson W, McAleavey F, Johnston P, Kiska R. Ultrasound imaging of the infraorbital foramen and simulation of the ultrasound-guided infraorbital nerve block using a skull model. *Surg Radiol Anat* **2013**;35(4):319–22.  
<https://doi.org/10.1007/s00276-012-1039-3>
  14. Polo CL, Abdelkarim AZ, von Arx T, Lozanof S. The morphology of the infraorbital nerve and foramen in the presence of an accessory infraorbital foramen. *J Craniofac Surg* **2019**;30(1):244–53.  
<https://doi.org/10.1097/scs.0000000000004889>
  15. Kazkayasi M, Ergin A, Ersoy M, Tekdemir I, Elhan A. Microscopic anatomy of the infraorbital canal, nerve, and foramen. *Otolaryngol Head Neck Surg* **2003**;129(6):692–7.  
[https://doi.org/10.1016/s0194-5998\(03\)01575-4](https://doi.org/10.1016/s0194-5998(03)01575-4)
  16. Iwanaga J, Kikuta S, Kusukawa J, Tomaszewski KA, Walocha JA, Tubbs RS. Anatomic study of accessory infraorbital nerves and foramina: application for a better understanding of complications of Le Fort fractures and osteotomy. *J Oral Maxillofac Surg* **2020**;78(5):717–23.  
<https://doi.org/10.1016/j.joms.2020.01.004>
  17. Canan S, Asim OM, Okan B, Ozek C, Alper M. Anatomic variations of the infraorbital foramen. *Ann Plast Surg* **1999**;43(6):613–7.  
<https://doi.org/10.1097/0000637-199912000-00006>
  18. Hwang K, Lee SJ, Kim SY, Hwang SW. Frequency of existence, numbers, and location of the accessory infraorbital foramen. *J Craniofac Surg* **2015**;26(1):274–6.  
<https://doi.org/10.1097/SCS.0000000000001375>
  19. Rusu MC, Săndulescu M, Cârstocea L. False and true accessory infraorbital foramina, and the infraorbital lamina cribriformis. *Morphologie* **2020**;104(344):51–8.  
<https://doi.org/10.1016/j.morpho.2019.12.003>



# U-Impl<sup>®</sup>

SWITZERLAND



№ R3M 804 252 B2

Сертифікат відповідності  
технічного регламенту  
щодо медичних виробів



Switzerland Aarbergerstrasse 107A, CH-2502  
Biel, Phone/Fax +41 323230188  
info@u-impl.com  
www.u-impl.com