

# The Integral Indicator of the Evaluation of the General State Severity in Patients With Inflammatory Processes of the Mandibular Bone According to the Data of Peripheral Clinical Blood Analysis\*

Mark P. Komsyki<sup>1,\*</sup>, Olena H. Romanenko<sup>2</sup>, Oleksandr A. Buzoveria<sup>3</sup>, Mariia V. Makohon<sup>4</sup>

<sup>1</sup> Dnipro Medical Institute of Conventional and Alternative Medicine. Faculty of Dentistry. The Cycle of Surgical Dentistry. Dnipro, Ukraine (Chief, PhD, Professor).

<sup>2</sup> Dnipropetrovsk Medical Academy. Faculty of Dentistry. (PhD, Assis Prof)

<sup>3</sup> Urban Head and Neck Surgical Center of the Dnipropetrovsk City Multifield Clinical Hospital #4. Dnipro, Ukraine (Hospital Physician)

<sup>4</sup> Urban Head and Neck Surgical Center of the Dnipropetrovsk City Multifield Clinical Hospital #4. Dnipro, Ukraine (Hospital Physician)

## ABOUT ARTICLE

### Article history:

Paper received 21 November 2017

Accepted 25 November 2017

Available online 28 December 2017

### Keywords:

Osteomyelitis

Odontogenic osteomyelitis

Traumatic osteomyelitis

Mandible

Inflammatory process

Maxillofacial area

Blood analysis

## ABSTRACT

### Purpose.

To study the possibility of using a clinical blood analysis for the mathematical determination of the severity level in patients with inflammatory processes in the maxillofacial area.

### Materials and Methods.

Under our supervision were 150 patients with acute (50), subacute (50) and chronic (50) inflammatory processes in the lower jaw area. 170 blood tests were analyzed for 11 signs: Blood sedimentation rate, white blood cells (cytosis and leukopenia), myelocyte, juvenile, stub, segmented neutrophil, eosinophile, lymphocyte, monocytes, plasma cell, which are conditionally divided according to the degree of severity from 0 to 3 points in the form of a table.

### Results and Discussion.

From the archive were selected 300 case histories of patients hospitalized in the clinic for acute, subacute and chronic stages of odontogenic and traumatic osteomyelitis of the mandible (50 patients for each nosology). Laboratory analyses of peripheral blood were taken from the patient upon admission to the department. 300 blood analyses were analyzed in accordance with the scale of patients developed by us in assessing the severity of the patient's condition with the inflammatory processes of the maxillofacial area by peripheral blood analysis.

As a result, sum of points were obtained that corresponded to three degrees of severity in patients with odontogenic and traumatic osteomyelitis of the mandibular bone: mild stage from 1 to 7; medium stage from 8 to 15 and severe stage from 16 to 27 points.

### Conclusion.

The proposed methodology for the integral calculation of the evaluation of the degree of severity of general status in terms of indicators of peripheral blood in patients with inflammatory processes of the maxillofacial area allows for early diagnosis of the severity of the pyoinflammatory process of the maxillofacial area.

© 2017 OMF Publishing, LLC. This is an open access article under the CC BY licence (<http://creativecommons.org/licenses/by-nc/4.0/>).

## Introduction

Inflammatory processes in the maxillofacial area continue to occupy the main place among the causes of temporary disability in surgical dental patients [1, 2].

It is often noted the progression of the inflammatory process, the development of inflammatory complications, which significantly prolongs the duration of treatment and can lead to serious complications up to a mortality [3].

In recent years, was shown the prospects of using the method of mathematical prediction of the course of the inflammatory processes of the maxillofacial area [4-6].

To create a mathematical model, use various biochemical, immunological indicators, genetic markers, etc. However, in everyday clinical practice, the most

\*This manuscript has not been presented

\* Corresponding author. Dnipro Medical Institute of Conventional and Alternative Medicine. Faculty of Dentistry. The Cycle of Surgical Dentistry. Dnipro, 17 Sevastopolska Street, 49000, Ukraine.

Tel.: +380675628517

E-mail address: [rolex-50@yandex.ru](mailto:rolex-50@yandex.ru) (M.P. Komsyki)

## GENERAL STATE OF PATIENTS WITH MANDIBULAR OSTEOMYELITIS

common are the parameters of peripheral blood. Therefore, the further search for laboratory blood indicators that are informative and accessible to most medical institutions, which allow us to assess the severity and predict the course of the disease on the basis of mathematical modeling, is topical.

The purpose of the research is to study the possibility of using a clinical blood analysis for the mathematical determination of the severity level in patients with inflammatory processes in the maxillofacial area and to use the data obtained for the purpose of active control over the reduction in the length of stay in the hospital.

### Materials and Methods

Under our supervision, in the Clinic of the Dentistry Faculty of Dnipro Medical Institute of Conventional and Alternative Medicine on the basis of Dnipropetrovsk City

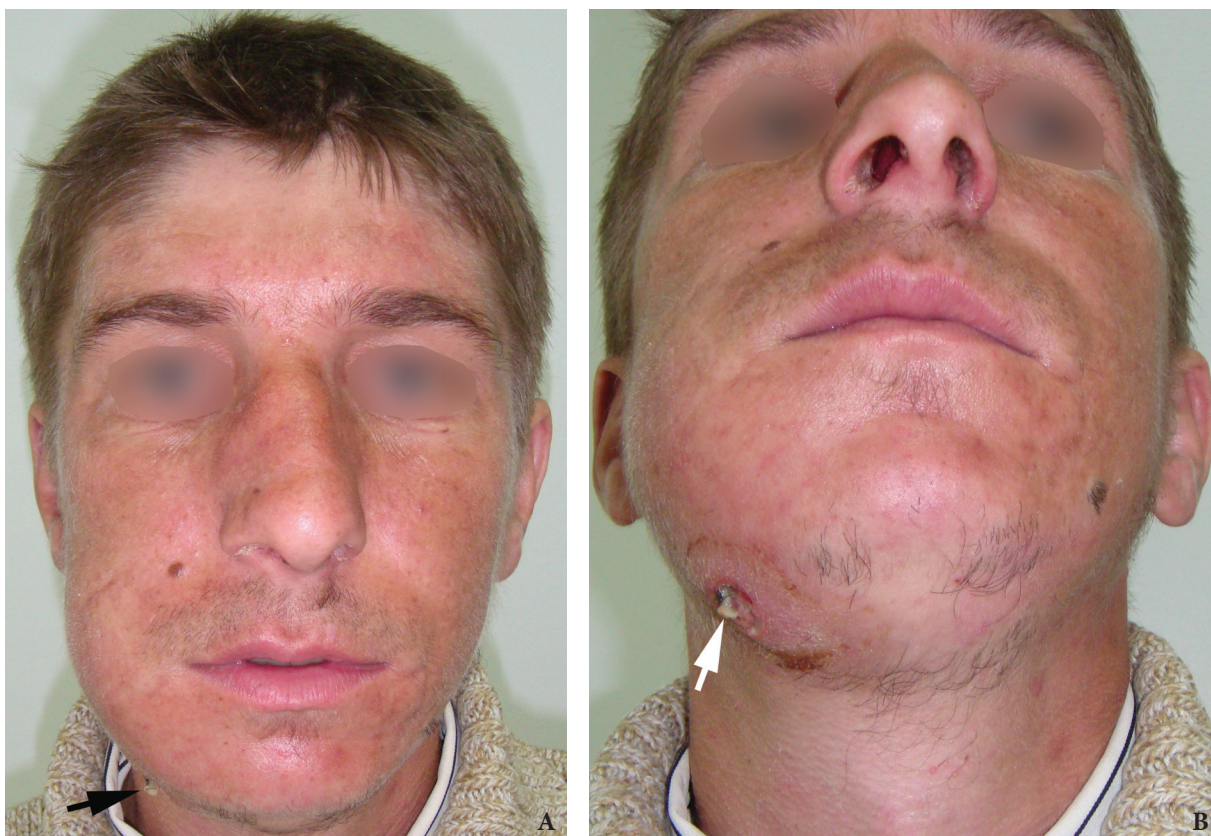Multifield Clinical Hospital #4 there were 150 patients (105 men, 45 women) with various inflammatory processes (Fig 1) in the maxillofacial area (Table 1). Age of patients from 18 to 58 years.

On presentation in the inpatient department, all patients underwent the standard complex of curative services in accordance with the nosological entity of the disease, due to the quality standard of the treatment [7].

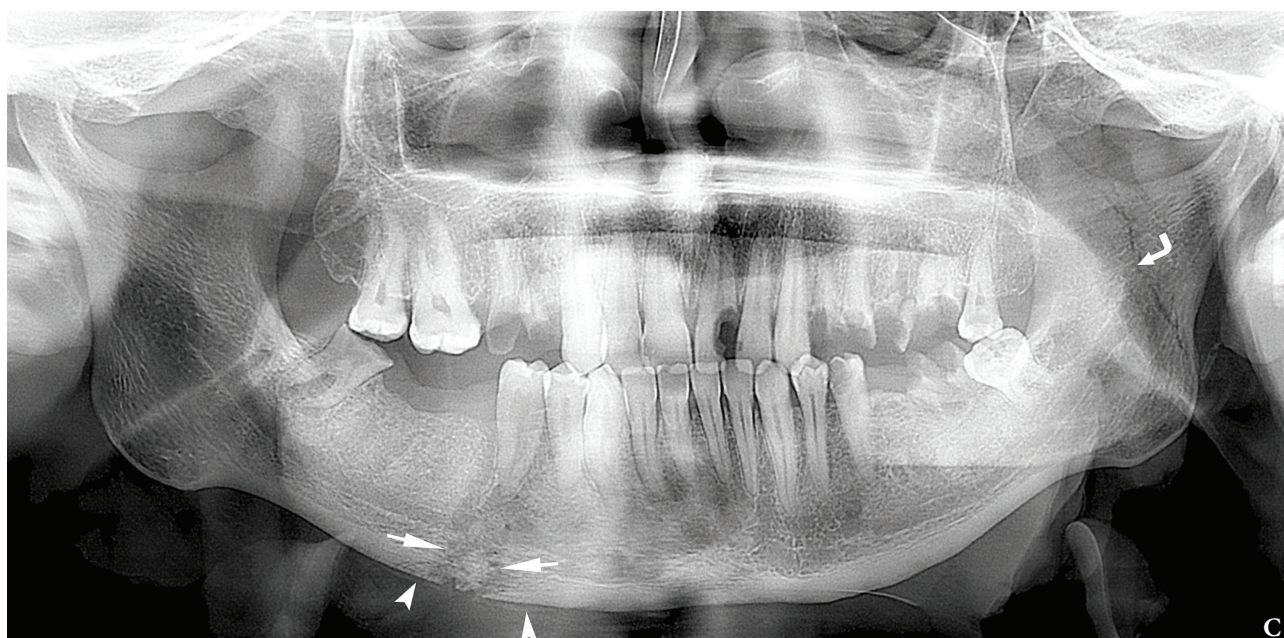
Laboratory examination of the patient was carried out on admission to the department.

Mathematical processing of data was carried out on a personal computer, it was used the standard package of mathematical statistics applications.

170 blood tests were analyzed for 11 signs, which are conditionally divided according to the severity from 0 to 3 points (Table 2), while 0 points correspond to the norm of the peripheral blood analysis for the Dnipropetrovsk region.



**FIGURE 1.** An extraoral (A, B) appearance of 27-year-old gentleman with acute posttraumatic osteomyelitis of the mandible as a result of two week trauma and bilateral fracture (right body and left subcondylar). Noted the swelling of soft tissues and cutaneous fistula (arrow) with purulent discharge. (Fig 1 continued on the next page.)



**FIGURE 1. (cont'd).** Panoramic x-ray (C) shows irregularity of bony margins in the gap of right body fracture and `doubling` sign (arrows). Left subcondylar fracture – curved arrow. Periosteal reaction at the lower border of the mandible (near the fracture gap) is indicated by arrowheads. (Images of Figure 1 are courtesy of Ievgen I. Fesenko, Assis Prof, Kyiv, Ukraine)

**TABLE 1.** 150 patients (105 men, 45 women) with various inflammatory processes in the maxillofacial area.

#	Nosological Entity	Number of Observations
1.	Practically healthy people (volunteers).	20
2.	Acute stage of odontogenic osteomyelitis of the mandible.	25
	Osteal abscess of the mandible.	25
3.	Subacute stage of odontogenic osteomyelitis of the mandibular bone.	25
	Subacute stage of traumatic osteomyelitis of the mandibular bone.	25
4.	Chronic stage of odontogenic osteomyelitis of the mandible.	25
	Chronic stage of traumatic osteomyelitis of the mandible.	25

**TABLE 2.** Scale of the points of severity of peripheral blood state in patients with odontogenic osteomyelitis of lower jaw bone.

#	Abbreviation	Designation	Points			
			Norm 0	Mild 1	Medium 2	Severe 3
1	BSR	Blood sedimentation rate	8-14	15-22	23-40	41 and above
2	Lc	White blood cells /cytosis/	4-9	10-15	16-20	21 and above
3	Lp	White blood cells / leukopenia/	9-4	3	2	1
4	Mc	Myelocyte	0	1	2	3 and above
5	J	Juvenile	0	1-3	4-10	11-20
6	St	Stab	0-5	6-8	9-15	16 and above
7	N	Segmented neutrophil	47-70	71-72	73-74	75 and above



#	Abbreviation	Designation	Points			
			Norm 0	Mild 1	Medium 2	Severe 3
8	Es	Eosinophile	0.5-5.0	0,4	0,3-0,2	0.1-0
9	Lh	Lymphocyte	19-37	18-14	13-11	10 and above
10	Mo	Monocyte	2-8	9-10	11-12	13 and above
11	Pc	Plasma cell	2-8	9-10	11-12	13 and above

When using this table, you must follow the following rules:

1. Evidence of the investigated symptoms are either present or absent.
2. The severity of the status of peripheral blood in patients is determined by summing the points of

the signs present.

### Results and Discussion

From the archives of the dental clinic for 2010-2015 years, 300 case histories were selected, hospitalized for:

TABLE 3. Nosological entity of the disease.

#	Nosological Entity	Number of Observations
1.	Acute stage: - odontogenic osteomyelitis of mandibular bone; - osteal abscess of mandibular bone.	50 50
2.	Subacute stage: - odontogenic osteomyelitis of mandibular bone; - traumatic osteomyelitis of the mandibular bone.	50 50
3.	Chronic stage: - odontogenic osteomyelitis of mandibular bone; - traumatic osteomyelitis of the mandibular bone.	50 50

Among the patients were 255 men and 45 women aged 18 to 52 years. All patients underwent the standard complex of curative services in accordance with the nosological entity of the disease, due to the quality standard of the treatment [7].

Laboratory analyses of peripheral blood were taken from the patient upon admission to the department. 300 blood analyses were analyzed in accordance with the scale of patients developed by us in assessing the severity of the patient's condition with the inflammatory processes of the maxillofacial area by peripheral blood analysis.

As a result, sum of points were obtained that corresponded to three degrees of severity in patients with odontogenic (Fig 2) and traumatic osteomyelitis of the mandibular bone (Table 4), while there was no significant difference in the odontogenic inflammatory process and an inflammatory complication of injury of the mandible [8-15].

### Conclusion

By such manners, the proposed method of integral calculation of the degree of severity of the peripheral blood state indices in patients with inflammatory processes of the maxillofacial area allows early diagnosis of the severity

of the pyoinflammatory process of the maxillofacial area of various genesis and to solve the question of rational individual treatment of the patient [15].

### Funding

None.

### Conflict of Interests

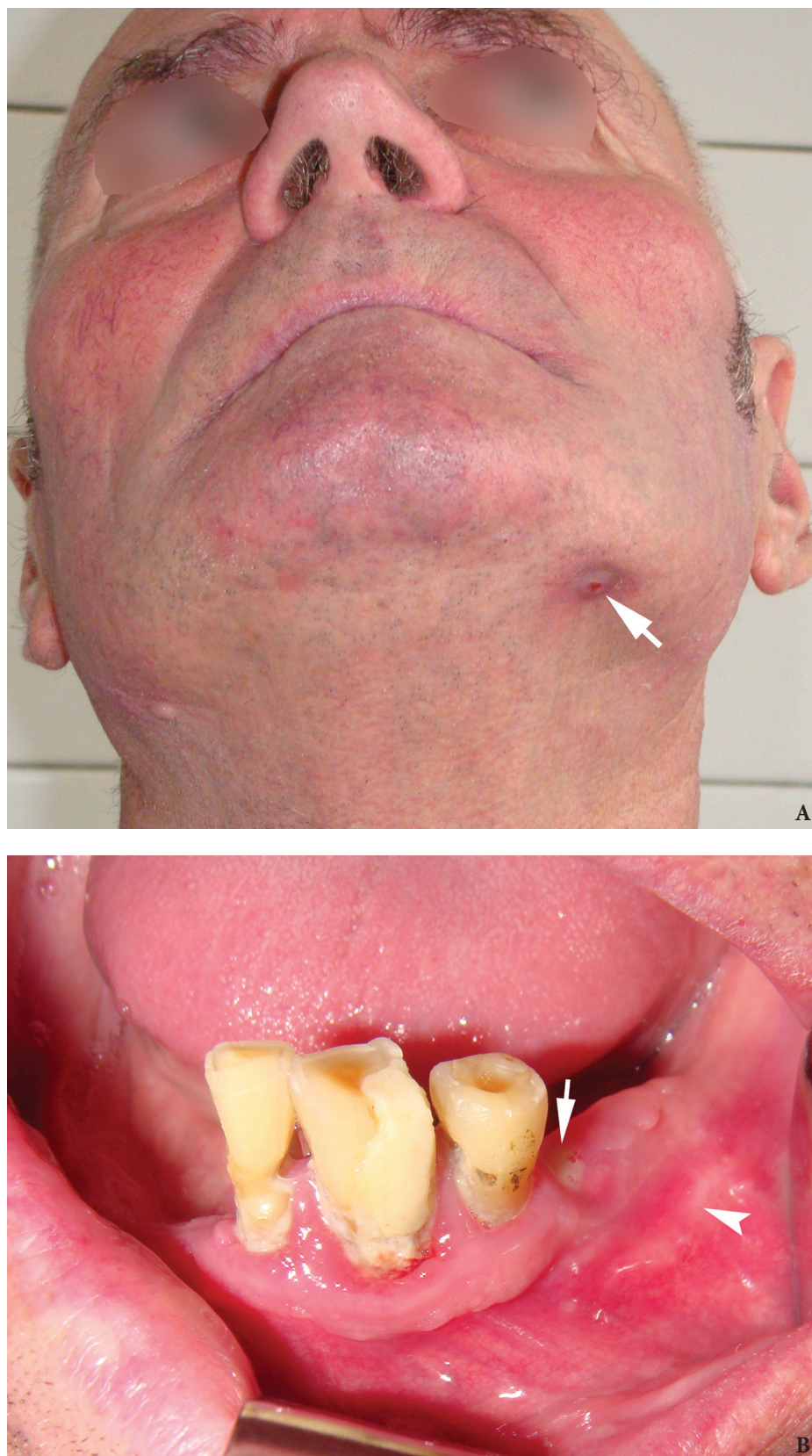The authors declare no conflict of interest.

### Role of Author and Co-authors

Mark P. Komsyki (concept of the paper and editing)  
Olena H. Romanenko (material collection and writing)  
Oleksandr A. Buzoveria (material collection and writing)  
Mariia V. Makohon (material collection and writing)

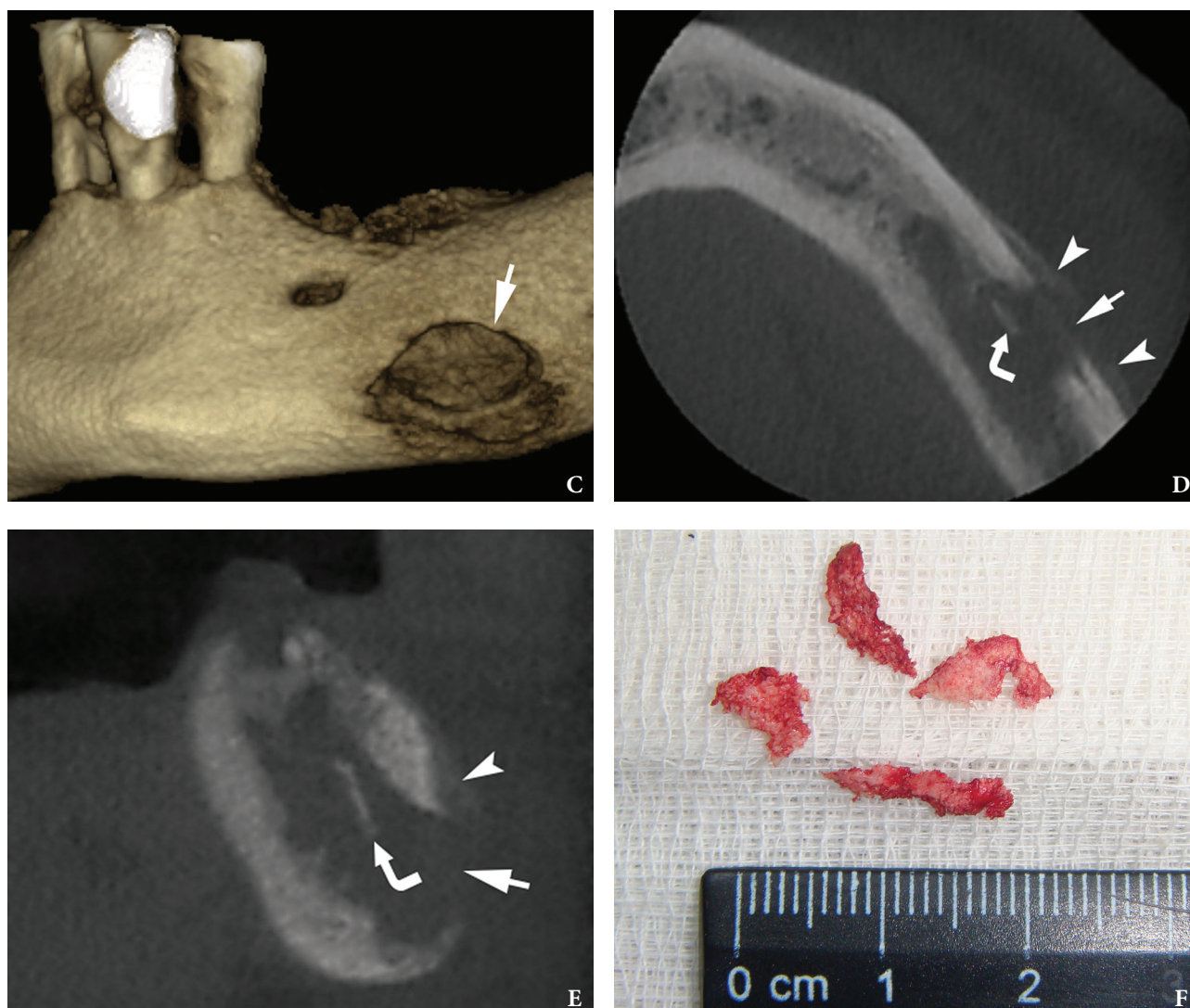
### Ethical Approval

Approval was obtained from the Medical Ethics Committee of the Dnipro Medical Institute of Conventional and Alternative Medicine.



**FIGURE 2.** An extraoral (**A**) and intraoral (**B**) appearance of 70-year-old male with chronic odontogenic osteomyelitis of the mandible as a result of alveolitis (synonym: alveolar osteitis) after extraction of teeth 35, 36. On the image **A** is noted a skin fistula (*arrow*) at lower border of mandible. On intraoral view (**B**) a purulent discharge indicated by *arrow*, scar tissue after previously performed lancing of tissues by non-experienced surgeon – by *arrowhead*. Erythema of surrounding mucosa and extremely bad hygiene are also noted. (**Fig 2 continued on the next page.**)





**FIGURE 2. (cont'd).** A 3D reconstructed (C), axial (D), and coronal (E) CBCT scans showed cortical bone defect (arrows). Sequestered bone fragment is indicated by curved arrow, periosteal reaction – by arrowheads. (F) Appearance of periosteal reaction after its removal. (Images of **Figure 2** are courtesy of Ievgen I. Fesenko, Assis Prof, Kyiv, Ukraine)

**TABLE 4.** The sum of points characterizing the degree of severity of the pathological process in patients with inflammatory diseases of the maxillofacial localization.

#	Degree of Severity of Peripheral Blood State in Patients With Osteomyelitis of the Mandible	Sum of Points
1.	Mild stage	From 1 to 7 points
2.	Medium stage	From 8 to 15 points
3.	Severe stage	From 16 to 27 points

**Patient Consent**

Written patient consent was obtained to publish the clinical photographs.

**Acknowledgements**

The authors are grateful to Sergii I. Khrulenko (*x-ray laboratory assistant*; Kyiv, Ukraine) for high quality

panoramic x-ray (**Fig 1C**).

**References**

1. Tymofieiev OO. Manual of maxillofacial and oral surgery [Russian]. 5th ed. Kyiv: Chervona Ruta-Turs; 2012.
2. Levy MM, Fink MP, Marshall JC et al. 2001 SCCV/ESICM/ACCP/ATS/SIS International Sepsis Definitions Conference. *Crit Care Med* 2003;31(4):1250–6.
3. Kabanova AA, Pokhodenko-Chudakova IO. The role of

- specific and nonspecific resistance in the development of infectious and inflammatory processes of the maxillofacial area (current state of the matter). *Dentistry* **2015**;4(19):45–9.
4. Shepel MA, Shvyrkov MB, Obiedkov RH. The use of non-traditional methods for predicting the course of fractures of the lower jaw bone: Collection of abstracts Dentistry on the eve of the third millennium; Moscow, **2001**. p. 516.
  5. Shliapnikov VV, Fedorova VV. Comparative evaluation of the results of clinical and microbiological studies for predicting the outcome of peritonitis. *Infections in Surgery* **2003**;2:40–4.
  6. Ruzin HP, Hryhorov SN, Vakulenko EN, Pokhodenko-Chudakova IO, Kabanova AA, Krainiaia VO. Data of retrospective analysis of the course and prognosis of phlegmon of maxillofacial area in various territorial conditions. *Medical Magazine* **2016**;1(55):130–6.
  7. On the approval of temporary branch unifiers of medical technology standards for the diagnostic-treatment process of inpatient care for the adult population in treatment and prophylactic institutions of Ukraine and temporary standards for the volume of diagnostic studies, treatment measures and criteria for the quality of children's treatment". Ministry of Health of Ukraine, Order #226 July 27, **1998**.
  8. Larheim TA, Westesson P-L. Maxillofacial imaging. 1st ed. Berlin Heidelberg: Springer-Verlag; **2006**.
  9. Tymofieiev OO, Ushko NO, Tymofieiev OO, Yarifa MO, Fesenko IeI. Prevention of inflammatory complications upon surgeries in maxillofacial region. *J Diagn Treat Oral Maxillofac Pathol* **2017**;1:105–12.
  10. Chattopadhyay PK, Nagori SA, Menon RP, Thanneermalai B. Osteomyelitis of the mandibular condyle: a report of 2 cases with review of the literature. *J Oral Maxillofac Surg* **2017**;75(2):322–35.
  11. Lucchesi L, Kwok J. Long term antibiotics and calcitonin in the treatment of chronic osteomyelitis of the mandible: case report. *Br J Oral Maxillofac Surg* **2008**;46:400–2.
  12. Huang Z, Huang Z, Zhang D, et al. Endoscopically-assisted operations in the treatment of odontogenic peripheral osteomyelitis of the posterior mandible. *Br J Oral Maxillofac Surg* **2016**;54(5):542–6.
  13. Chang Y-C, Shieh Y-S, Lee S-P, et al. Chronic osteomyelitis with proliferative periostitis in the lower jaw. *Journal of Dental Sciences* **2015**;10:450-5.
  14. Goda A, Maruyama F, Michi Y, et al. Analysis of the factors affecting the formation of the microbiome associated with chronic osteomyelitis of the jaw. *Clin Microbiol Infect* **2014**;20:O309–17.
  15. Marx RE, Tursun R. Suppurative osteomyelitis, bisphosphonate induced osteonecrosis, osteoradionecrosis: a blinded histopathologic comparison and its implications for the mechanism of each disease. *Int J Oral Maxillofac Surg* **2012**;41(3):283–9.

Komskiy MP, Romanenko OH, Buzoveria OA, Makohon MV.

The integral indicator of the evaluation of the general state severity in patients with inflammatory processes of the mandibular bone according to the data of peripheral clinical blood analysis.

*J Diagn Treat Oral Maxillofac Pathol* **2017**;1:168–174.

<http://dx.doi.org/10.23999/j.dtopm.2017.3-4.10>