

DT Journal

8 2022

**Journal of Diagnostics and
Treatment of Oral and
Maxillofacial Pathology**



Editors
Oleksii Tymofieiev • Rui Fernandes
(Kyiv, Ukraine • Jacksonville, FL, USA)



Official Journal of the
Ukrainian Association for
Maxillofacial and Oral Surgeons

DTJournal.org

TANTUM VERDE®

QUICK RELIEF FROM PAIN
AND INFLAMMATION IN THE
MOUTH AND THROAT¹

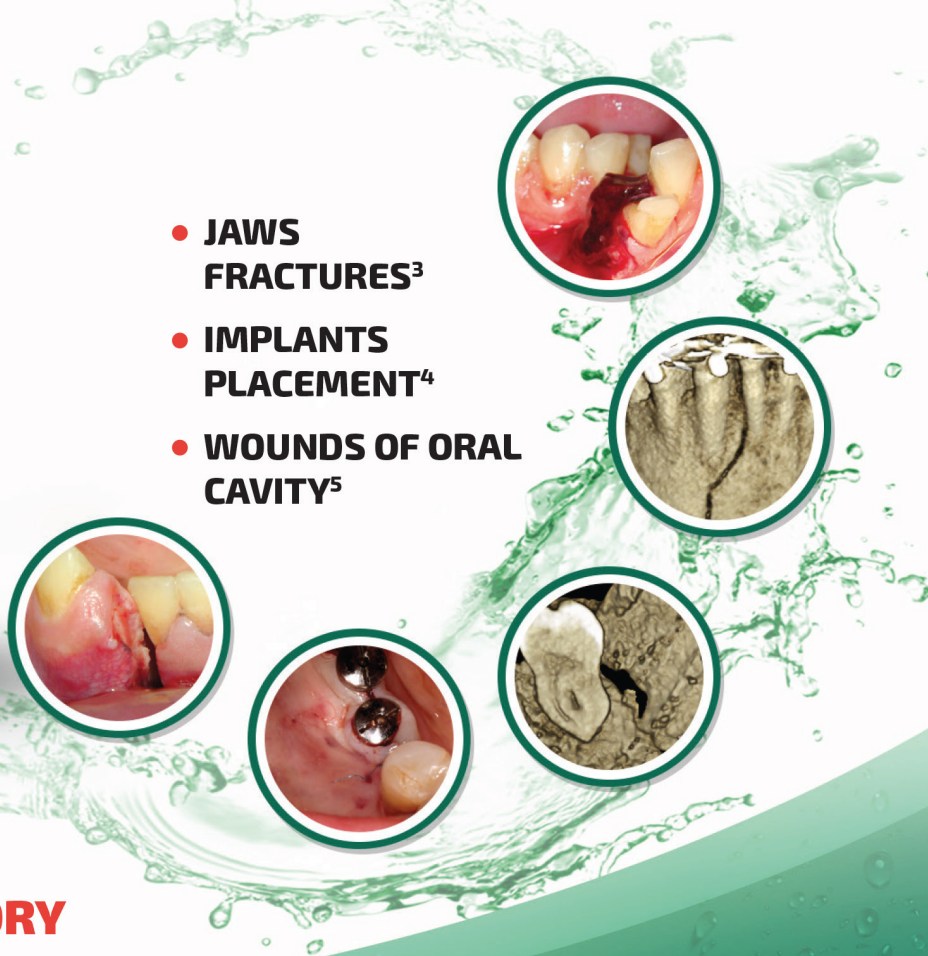
**AN INTEGRAL COMPONENT OF THE TREATMENT
OF PAIN AND INFLAMMATION IN THE ORAL CAVITY
IN 60 COUNTRIES WORLDWIDE!²**



Reg. № UA/3920/01/01

**LOCAL ANESTHETIC
AND ANTI-INFLAMMATORY
EFFECT¹**

- **JAWS FRACTURES³**
- **IMPLANTS PLACEMENT⁴**
- **WOUNDS OF ORAL CAVITY⁵**



SUMMARY OF PRODUCT CHARACTERISTICS

NAME OF THE MEDICINAL PRODUCT. Tantum Verde 0.15% mouthwash. **QUALITATIVE AND QUANTITATIVE COMPOSITION.** Each 100 ml contains: active ingredient: benzydamine hydrochloride 0.15 g (equivalent to 0.134 g of benzydamine). **Therapeutic indications.** Treatment of symptoms such as irritation/inflammation including those associated with pain in the oropharyngeal cavity (e.g. gingivitis, stomatitis and pharyngitis), including those resulting from conservative or extractive dental therapy. **Posology and method of administration.** Pour 15 ml of Tantum Verde mouthwash into the measuring cup, 2-3 times per day, using it either at full concentration or diluted. If diluted, add 15 ml of water to the graduated cup. Do not exceed the recommended dosage. **Contraindications.** Hypersensitivity to benzydamine or to any of the excipient. **PHARMACOLOGICAL PROPERTIES. Pharmacodynamic properties.** Pharmacotherapeutic group: Stomatologic drugs: other agents for local oral treatment, ATC code: A01AD02. Clinical studies demonstrate that benzydamine is effective in relieving suffering from localised irritation of the mouth and pharynx. In addition, benzydamine possesses a moderate local anaesthetic effect. **Pharmacokinetic properties. Absorption.** Absorption through the oropharyngeal mucosa is demonstrated by the presence of measurable quantities of benzydamine in human plasma. These levels are insufficient to produce systemic effects. **Distribution.** When applied locally, benzydamine has been shown to accumulate in inflamed tissues where it reaches effective concentrations because of its capacity to penetrate the epithelial lining.

Information about medicines. Information for health care professionals for use in professional activities.

1. Інструкція для медичного застосування лікарського засобу Тантум Верде®, розчин для ротової порожнини, РПН № UA/3920/01/01, затверджено Наказом Міністерства охорони здоров'я України № 636 від 01.10.2015.

2. <http://www.angelini-pharma.com/wps/wcm/connect/com/home/Angelini+Pharma+in+the+world/>

3. Тимофеев А.А. и др. "Особенности гигиены полости рта для профилактики воспалительных осложнений при переломах нижней челюсти". Современная стоматология 2015;1(75):52-8.

4, 4.5. Tymofieiev O.O. et al "Prevention of inflammatory complications upon surgeries in maxillofacial region". J Diagn Treat Oral Maxillofac Pathol. 2017;1:105-12.

Clinical and CT images are courtesy of: Ievgen Fesenko (Department of Oral & Maxillofacial Surgery, PHEI "Kyiv Medical University", Kyiv, Ukraine), Oleg Mastakov ("SCIEDECE—Scientific Center of Dentistry & Ultrasound Surgery" Kyiv, Ukraine)



04119, Kiev, Melnikova str. 83D, of. 404.
Tel.: (044) 538-01-26
Fax: (044) 538-01-27



About the Journal: Aims and Scope

AUGUST 2022 • VOLUME 6 • ISSUE 8
www.djournal.org

Official Title

Journal of Diagnostics and Treatment of Oral and Maxillofacial Pathology

Standard Abbreviation: ISO 4

J. Diagn. Treat. Oral Maxillofac. Pathol.

Acronym

JDTOMP

International Standard Serial Number (ISSN)

Electronic ISSN 2522-1965

Aims & Scope

This is a monthly peer-reviewed oral and maxillofacial surgery journal focused on: microvascular and jaw reconstructive surgery, dental implants, salivary gland tumors/diseases, TMJ lesions, virtual surgical planning, implementation of ultrasonography into the practice of oral and maxillofacial surgeons.

Editorial Board (EB) Composition

- EB shows significant geographic diversity representing 30 opinion leaders from 13 countries: Brazil, Canada, Colombia, Greece, Hong Kong (SAR, China), India, Israel, Italy, Slovak Republic, Spain, Ukraine, United Arab Emirates, and United States.
- The majority of the EB Members have a discernible publication history in Scopus, Web of Science, and journals with a high impact factor.
- The publication records of all EB members are consistent with the stated scope and published content of the journal.
- The journal has a several full-time professional editors.
- Gender distribution of the editors: 10% women, 90% men, 0% non-binary/other, and 0% prefer not to disclose.

Frequency

12 issues a year (from January 2020)

Publication History

2017: 4 issues a year

2018: 4 issues a year

2019: 10 issues a year

From 2020: 12 issues a year

Publishing Model

Journal of Diagnostics and Treatment of Oral and Maxillofacial Pathology is a fully online-only open access and peer-reviewed publication.

Type of Peer Review

The journal employs “double blind” reviewing.

Article Publishing Charge (APC)

The APC in this journal is 100 USD and 50 USD (excluding taxes) depending on the article’s type. Details at website: dtjournal.org.

13 Types of Articles Currently Published by the Journal

Editorials/Guest Editorials/Post Scriptum Editorials, Images, Case Reports/Case Series, Original Articles, Review Articles, Discussions, Paper Scans (*synonyms*: Review of Articles, Literature Scan), Book Scans (*synonym*: Book Reviews), Letters to the Editor (*synonym*: Letters), and Viewpoints.

State Registration: Ministry of Justice of Ukraine

Registration: Jul 28, 2016 (Certificate: KB № 22251-12151 P)

Re-registration: May 21, 2019 (Certificate: KB № 23999-13839 IIP)

Re-registration: Aug 10, 2021 (Certificate: KB № 24951-14891 IIP)

Co-Founders

1. Shupyk National Healthcare University of Ukraine (formerly known as Shupyk National Medical Academy of Postgraduate Education).
2. Private Higher Educational Establishment “Kyiv Medical University.”
3. OMF Publishing, Limited Liability Company.

Publisher

OMF Publishing, LLC is an academic publisher focused on medical and linguistic sciences.

Address: 13-A Simferopolska Street, office 121, Kyiv 02096, Ukraine.

Crossref Membership

OMF Publishing, LLC is a member of Publishers International Linking Association, Inc. which doing business as a Crossref. OMF Publishing’s active membership: From February 2017 to present.

Official Journal of the Association

Ukrainian Association for Maxillofacial and Oral Surgeons

Ukrainian Association for Maxillofacial and Oral Surgeons (UAMOS)

Address: 4-A Profesora Pidvysotskoho Street, Kyiv 01103, Ukraine.

Tel., fax: +38 044 528 35 17.

Website: uamos.org.

© 2022 OMF PUBLISHING, LLC

Editorial Board

AUGUST 2022 • VOLUME 6 • ISSUE 8
www.djournal.org

Editor in Chief

Oleksii O. Tymofiev, ScD
Kyiv, Ukraine

Deputy Editor in Chief

Rui P. Fernandes, MD, DMD, FACS, FRCS(Ed)
Jacksonville, Florida, United States

Section Editors

Bone Augmentation Techniques

Nardy Casap, MD, DMD
Jerusalem, Israel

Business

Ivan V. Nagorniak, MSc, PhD
Kyiv, Ukraine

Craniofacial Deformities

Sunil Richardson, MDS
Nagercoil, Tamil Nadu, India

Facial Feminization Surgery

Kyle Keojampa, MD, FACS
Los Angeles, California, United States

Facial Plastic Surgery

Tirbod Fattahi, MD, DDS, FACS
Jacksonville, Florida, United States

Head & Neck Oncologic Surgery

Todd C. Hanna, MD, DDS, FACS
New York, New York, United States

Head & Neck Radiology

Anil T. Ahuja, MBBS, MD, FRCR, FHKCR, FHKAM
Hong Kong, SAR, China

Images

Camilo Mosquera, DDS
Bogotá, D.C., Colombia

Orthognathic Surgery

Mario Brinhole
São Paulo, São Paulo, Brazil

Robotic Surgery

Salam O. Salman, MD, DDS, FACS
Jacksonville, Florida, United States

TMJ Lesions/Disorders

Belmiro C. Vasconcelos, DDS, PhD
Recife, Pernambuco, Brazil

Editorial Board Members

Oleh M. Antonyshyn, MD, FRCS(C)
Toronto, Ontario, Canada

Anthony M. Bunnell, MD, DMD, FACS
Jacksonville, Florida, United States

Nur A. Hatab, DMD, PhD
Ras Al Khaimah, United Arab Emirates

Michael T. Kase, DMD
Birmingham, Alabama, United States

Andrey V. Kopchak, ScD
Kyiv, Ukraine

Olindo Massarelli, MD, PhD, FEBOMFS
Sassari, Italy

Anastasiya Quimby, DDS, MD
Fort Lauderdale, Florida, United States

Daniel Robles Cantero, DDS, MSc
Madrid, Spain

Peter Stanko, MD, PhD
Bratislava, Slovak Republic

Rostyslav M. Stupnytskyi, ScD
Kyiv, Ukraine

Olexander O. Tymofiev, ScD
Kyiv, Ukraine

Natalia O. Ushko, ScD
Kyiv, Ukraine

Andrew Yampolsky, DDS, MD
Philadelphia, Pennsylvania, United States

Web & Social Media Editor

João L. Monteiro, DDS
Boston, Massachusetts, United States

Director, Journal Development Department

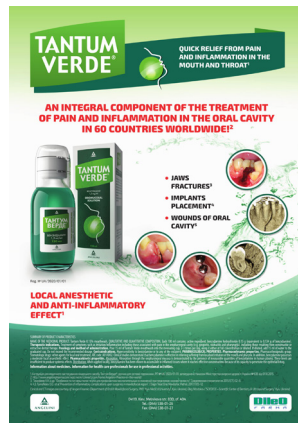Evangelos G. Kilipiris, DMD
Thessaloniki, Greece | Bratislava, Slovak Republic

Managing Editor

Ievgen I. Fesenko, PhD
Kyiv, Ukraine

Resident Ambassador

John M. Le, DDS, MD
Birmingham, Alabama, United States



TANTUM VERDE®

INFORMATION LEAFLET
for the medicinal product

Composition:

active substance: **benzydamine hydrochloride;**

100 mL of solution contain benzydamine hydrochloride 0.15 g;

excipients: ethanol 96%, glycerol, methyl parahydroxybenzoate (E 218), flavor (menthol), saccharin, sodium hydrocarbonate, Polysorbate 20, Quinoline Yellow (E 104), Patent Blue V (E 131), purified water.

Dosage form. Oromucosal solution.

Basic physical and chemical properties: a clear green liquid with a typical mint flavor.

Pharmacotherapeutic group. Dental preparations. Other agents for local oral treatment.

ATC code: A01A D02.

Pharmacological properties.

Pharmacodynamics.

Benzydamine is a non-steroidal anti-inflammatory drug (NSAID) with analgesic and antiexudative properties.

Clinical studies have shown that benzydamine is effective in the relief of symptoms accompanying localized irritation conditions of the oral cavity and pharynx. Moreover, benzydamine has anti-inflammatory and local analgesic properties, and also exerts a local anesthetic effect on the oral mucosa.

Pharmacokinetics.

Absorption through the oral and pharyngeal mucosa has been proven by the presence of measurable quantities of benzydamine in human plasma. However, they are insufficient to produce any systemic pharmacological effect. The excretion occurs mainly in urine, mostly as inactive metabolites or conjugated compounds.

When applied locally, benzydamine has been shown to cumulate in inflamed tissues in an effective concentration

due to its ability to permeate through the mucous membrane.

Clinical particulars.

Indications.

Symptomatic treatment of oropharyngeal irritation and inflammation; to relieve pain caused by gingivitis, stomatitis, pharyngitis; in dentistry after tooth extraction or as a preventive measure.

Contraindications.

Hypersensitivity to the active substance or to any other ingredients of the product.

Interaction with other medicinal products and other types of interaction.

No drug interaction studies have been performed.

Warnings and precautions.

If sensitivity develops with long-term use, the treatment should be discontinued and a doctor should be consulted to get appropriate treatment.

In some patients, buccal/pharyngeal ulceration may be caused by severe pathological processes. Therefore, the patients, whose symptoms worsen or do not improve within 3 days or who appear feverish or develop other symptoms, should seek advice of a physician or a dentist, as appropriate.

Benzydamine is not recommended for use in patients hypersensitive to acetylsalicylic acid or other non-steroidal anti-inflammatory drugs (NSAIDs).

The product can trigger bronchospasm in patients suffering from or with a history of asthma. Such patients should be warned of this.

For athletes: the use of medicinal products containing ethyl alcohol might result in positive antidoping tests considering the limits established by some sports federations.

Use during pregnancy or breast-feeding

No adequate data are currently available on the use of benzydamine in pregnant and breastfeeding women. Excretion of the product into breast milk has not been studied. The findings of animal studies are insufficient to make any conclusions about the effects of this product during pregnancy and lactation.

The potential risk for humans is unknown.

TANTUM VERDE should not be used during pregnancy or breast-feeding.

Effects on reaction time when driving or using machines

When used in recommended doses, the product does not produce any effect on the ability to drive and operate machinery.

Method of administration and doses.

Pour 15 mL of TANTUM VERDE solution from the bottle into the measuring cup and gargle with undiluted or diluted product (15 mL of the measured solution can be diluted with 15 mL of water). Gargle 2 or 3 times daily. Do not exceed the recommended dose.

Children.

The product should not be used in children under 12 years due to a possibility of ingestion of the solution when gargling.

Overdosage.

No overdose has been reported with benzydamine when used locally. However, it is known that benzydamine, when ingested in high doses (hundreds times higher than those possible with this dosage form), especially in children, can cause agitation, convulsions, tremor, nausea, increased sweating, ataxia, and vomiting. Such acute overdose requires immediate gastric lavage, treatment of fluid/salt imbalance, symptomatic treatment, and adequate hydration.

Adverse reactions.

Within each frequency group, the undesirable effects are presented in order of their decreasing seriousness.

Adverse reactions are classified according to their frequency: very common ($\geq 1/10$); common ($\geq 1/100$ to $<1/10$); uncommon ($\geq 1/1,000$ to $<1/100$); rare ($\geq 1/10,000$ to $<1/1,000$); very rare ($<1/10,000$); frequency unknown (cannot be estimated from the available data).

Gastrointestinal disorders: rare – burning mouth, dry mouth; *unknown* – oral hypesthesia, nausea, vomiting, tongue edema and discoloration, dysgeusia.

Immune system disorders: rare – hypersensitivity reaction, *unknown* – anaphylactic reaction.

Respiratory, thoracic and mediastinal disorders: very rare – laryngospasm; *unknown* – bronchospasm.

Skin and subcutaneous tissue disorders: uncommon – photosensitivity; very rare – angioedema; *unknown* – rash, pruritus, urticaria.

Nervous system disorders: *unknown* – dizziness, headache.

TANTUM VERDE contains methyl parahydroxybenzoate, which can cause allergic reactions (including delayed-type reactions).

Shelf life. 4 years.

Storage conditions.

Do not store above 25°C. Keep out of reach of children.

Packaging.

120 mL of solution in a bottle with a measuring cup; 1 bottle per cardboard box.

Dispensing category.

Over-the-counter medicinal product.

Manufacturer.

Aziende Chimiche Riunite Angelini Francesco A.C.R.A.F. S.p.A., Italy.

Location of the manufacturer and its business address.
Via Vecchia del Pinocchio, 22 – 60100 Ancona (AN), Italy.

Date of the last revision of the text.

September 26, 2018.

Information leaflet is

APPROVED by

Order of the

Ministry of Health of Ukraine

No. 636 dated 01.10.2015

Registration Certificate

No. UA/3920/01/01

Our Supporters

AUGUST 2022 • VOLUME 6 • ISSUE 8
www.djournal.org



FIGURE. Evangelos G. Kilipiris, MD, DMD from the National Institute of Children's Diseases and Faculty of Medicine at Comenius University, Bratislava, Slovak Republic. A kind support of Dr. Kilipiris during the 5 years at the position of Director, Journal Development Department helped our journal to move forward and to evolve. An honorary plaque was presented to him on behalf of the Chief Editor with words "To a Founding Director, Author of Multiple Articles and Reviews, Great Thanks and Appreciation." Photo was taken on November 23, 2021.

Content

of the Volume 6 • Issue 8 • August 2022

A1 **Publisher & Editorial Office Information**

A2 **Editorial Board**

A5 **Our Supporters**

A6 **Content, Courtesy, & Erratum**

EDITORIAL

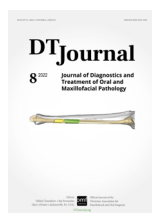111 **Making a Digital Editorial Bridge between Birmingham, Alabama and Kyiv Stronger**

Oleksii O. Tymofeiev & Ievgen I. Fesenko

IMAGES

114 **Hemolymphangioma of the Neck**

Valentyn H. Demidov & Olha S. Cherniak




COURTESY

Journal's cover image (virtual surgical planning for a segmental mandibular reconstruction with fibula transplant) is courtesy of Rui P. Fernandes, MD, DMD, FACS, FRCS.

Image was taken from the article: Fernandes RP, Quimby A, Salman S. Comprehensive reconstruction of mandibular defects with free fibula flaps and endosseous implants. *J Diagn Treat Oral Maxillofac Pathol* 2017;1(1):6–10.

<https://doi.org/10.23999/j.dtomp.2017.1.1>



EDITORIAL

Making a Digital Editorial Bridge between Birmingham, Alabama and Kyiv Stronger

Oleksii O. Tymofieiev^a & Ievgen I. Fesenko^{b,*}

*Maxillofacial Prosthetics, Dental Oncology, and things esthetically pleasing.*¹

—Michael T. Kase, DMD

Birmingham, Alabama, United States of America

Day by day, a new scholar bridge between Birmingham, Alabama and Kyiv becomes more tangible. The cornerstone of this digital bridge was laid by Dr. Le and colleagues in 2020.² Their highly productive collaboration and hard work made this transatlantic cooperation possible.^{3,4} The interplay between the players of a team of any profile is a key aspect of its success. That is why cooperation with Dr. Kase (Fig), from the same Department of Oral and Maxillofacial Surgery as Dr. Le,^{2,3,5,6} became so important for the editorial board of the *Journal of Diagnostics and Treatment of Oral and Maxillofacial Pathology*.

Despite any circumstances, like pandemic⁷ and war⁸⁻¹¹, the communication between professionals can show the tendency to grow. That is why we are so happy to feel the support of Dr. Kase in such a turbulent period as war time



FIGURE. Michael T. Kase, DMD—a new member of the editorial board.

in Europe, and so proud seeing him the editorial board member of our journal.

Kyiv, Ukraine

^a Chief Editor, *JDTOMP*.

^b Managing Editor, *JDTOMP*.

* Corresponding author's address: Editorial office, *Journal of Diagnostics and Treatment of Oral and Maxillofacial Pathology (JDTOMP)*, 13-A Simferopolska Street, Kyiv 02096, Ukraine.
E-mail: i.i.fesenko@dtjournal.org (Ievgen Fesenko)

Please cite this article as: Tymofieiev OO, Fesenko II. Making a digital editorial bridge between Birmingham, Alabama and Kyiv stronger. *J Diagn Treat Oral Maxillofac Pathol* 2022;6(8):111–3.

Available online 25 August 2022

<https://doi.org/10.23999/j.dtmp.2022.8.1>

© 2022 OMF Publishing LLC. This is an open access article under the CC BY license (<https://creativecommons.org/licenses/by-nc/4.0/>).

Dr. Kase occupies several very responsible positions in his institution:

- Associate Professor (from October 1, 2022), Department of Oral and Maxillofacial Surgery, Section of Oral Oncology, University of Alabama at Birmingham, Birmingham, Alabama, United States of America.
- Assistant and Clinical Director of the Advanced Education in Maxillofacial Prosthodontics and Dental Oncology Fellowship.

The doctor Kase's work interests cover two directions—dental oncology and maxillofacial prosthodontics.^{2,3,5,6,12–16} Thus, such a unique expertise will definitely help our journal to fulfill the gap in the direction of maxillofacial prosthetics¹⁷ as a key part of head and neck oncologic surgery.

Thank you for this opportunity!

—Michael T. Kase, DMD

Email talk between Managing Editor with Dr. Kase

Dr. Kase's email: mkase@uabmc.edu

Instagram page: [@mikito7](https://www.instagram.com/mikito7)

REFERENCES (17)

1. Instagram: [@mikito7](https://www.instagram.com/mikito7): Michael T. Kase, DMD [social media account on the internet]; 22 Aug 2022 [cited 22 Aug 2022]. Available from: <https://www.instagram.com/mikito7/>
2. Le JM, Chen PH, Seidenfaden JC, Morlandt AB, Kase MT. Zygomatic implants for restoration of complex nasal defects – a case report and outcome. *J Diagn Treat Oral Maxillofac Pathol* 2020;4(9):152–61. <https://doi.org/10.23999/j.dtomp.2020.9.2>
3. Le JM, Ying YP, Kase MT, Morlandt AB. Surgical reconstruction and rehabilitation of midface defects using osseointegrated implant-supported maxillofacial prosthetics. *J Diagn Treat Oral Maxillofac Pathol* 2022;6(1):9–25. <https://doi.org/10.23999/j.dtomp.2022.1.4>
4. Tymofieiev OO, Fesenko II. Meet the founding resident ambassador: John M. Le, DDS, MD. *J Diagn Treat Oral Maxillofac Pathol* 2022;6(1):3–5. <https://doi.org/10.23999/j.dtomp.2022.1.2>
5. Le JM, Gigliotti J, Ying Y, Kase MY, Morlandt AB. Computer-assisted microvascular free flap reconstruction and implant rehabilitation of the maxilla—treatment of a rare post-orthognathic complication. *J Maxillofac Oral Surg* 2021;21(1):82–87. <https://doi.org/10.1007/s12663-020-01492-y>
6. Le JM, Kase MT, Morlandt AB. A case of dyskeratosis congenita with squamous cell carcinoma of the maxilla: a case report and review of the literature. *Oral Maxillofac Surg Cases* 2020;6(1):100140. <https://doi.org/10.1016/j.omsc.2020.100140>
7. Maffia F, Fesenko II, Vellone V. Covid-2019 pandemic: growing wave of cancelled meetings in oral and maxillofacial surgery and its impact on specialty. *J Diagn Treat Oral Maxillofac Pathol* 2020;4(8):125–8. <https://doi.org/10.23999/j.dtomp.2020.8.1>
8. Fesenko II. Stop the war! Europeans, homes, kindergartens, hospitals, universities, and global science are under the missiles. *J Diagn Treat Oral Maxillofac Pathol* 2022;6(2):32–4. <https://doi.org/10.23999/j.dtomp.2022.2.3>
9. Fernandes R, Susarla S, Parmar S. Implications of war and healthcare. *Craniomaxillofac Trauma Reconstr* 2022;15(2):97. <https://doi.org/10.1177%2F19433875221096728>
10. van Aalst J. The costly yet valuable lessons of war. *Face* 2022;3(2):241–2. <https://doi.org/10.1177%2F27325016221104597>
11. Stefánsdóttir Á. The medical oath in the times of war [in Icelandic]. *Laeknabladid (Icel Med J)* 2022;108(4):171. <https://doi.org/10.17992/lbl.2022.04.683>
12. Chen PH, Seidenfaden JC, Kase MT, Sooudi I. Fabricating a partial nasal prosthesis with a custom nasal dilator design. *J Prosthet Dent* 2021;126(3):447–51. <https://doi.org/10.1016/j.prosdent.2020.05.029>
13. Chen PH, Seidenfaden JC, Sooudi I, Kase MT. Using digital technology to create a custom esthetic bandage for patients after rhinectomy. *J Prosthet Dent* 2021;125(2):357–60. <https://doi.org/10.1016/j.prosdent.2020.01.037>
14. Colebeck AC, Kase MT, Nichols CB, Golden M, Huryn JM. Use of orbital conformer to improve speech in patients with confluent maxillectomy and orbital defects. *J Prosthodont* 2016;25(3):241–6. <https://doi.org/10.1111%2Fjopr.12282>
15. Walma DAC, Seidenfaden JC, Mourad F, Kase MT. Prosthetic rehabilitation via silicone nasal prosthesis with internal alar support following partial rhinectomy: a short communication. *Int J Prosthodont* 2019;32(2):208–10.

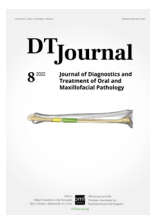<https://doi.org/10.11607/ijp.5997>

16. Gigliotti J, Ying Y, Redden D, Kase M, Morlandt AB. Fasciocutaneous flaps for refractory intermediate stage osteoradionecrosis of the mandible-is it time for a shift in management? *J Oral Maxillofac Surg*

2021;79(5):1156–67.

<https://doi.org/10.1016/j.joms.2020.11.026>

17. Lee SKY. Getting to know today's maxillofacial prosthodontist. *J Prosthet Dent* **2022**;127(3):381–2. <https://doi.org/10.1016/j.prosdent.2022.01.023>

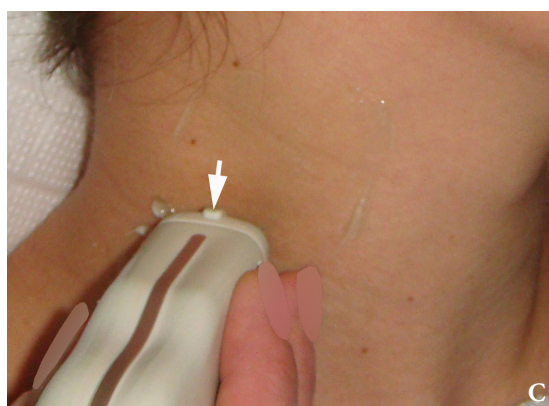
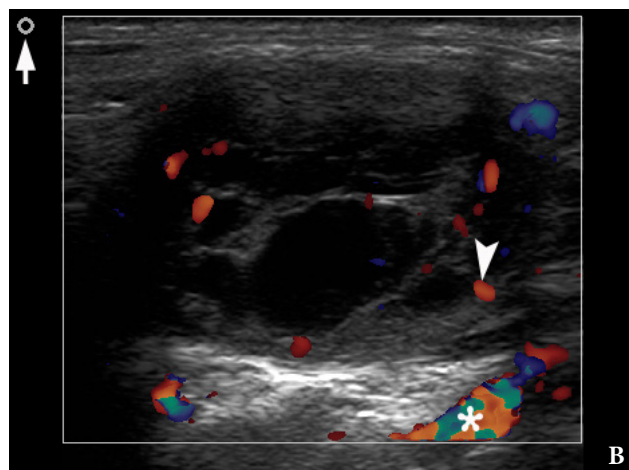
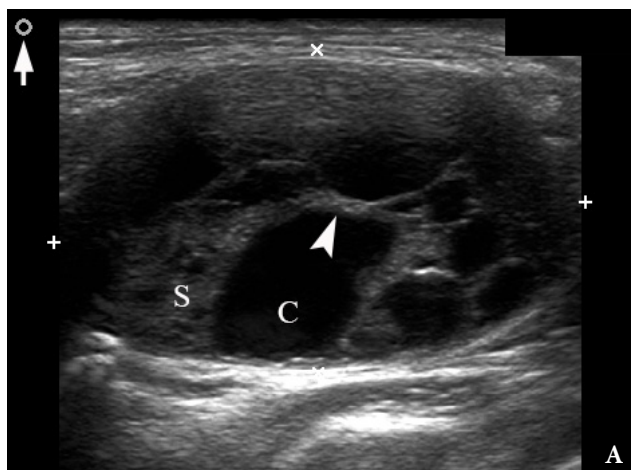


IMAGES

Camilo Mosquera, DDS, *Editor*

Hemolymphangioma of the Neck

Valentyn H. Demidov^a & Olha S. Cherniak^b



Kyiv, Ukraine

^a Doctor-Stomatologist-Surgeon (DSS), Center of Maxillofacial Surgery and Dentistry, Kyiv Regional Clinical Hospital.

^b Doctor of Ultrasound Diagnostics (DUD), Head, Department of Ultrasound, Regional Diagnostic Center, Polyclinic, Kyiv Regional Clinical Hospital.
cherniak.os@gmail.com

Please cite this article as: Demidov VH, Cherniak OS. Hemolymphangioma of the neck. *J Diagn Treat Oral Maxillofac Pathol* 2022;6(8):114–6.

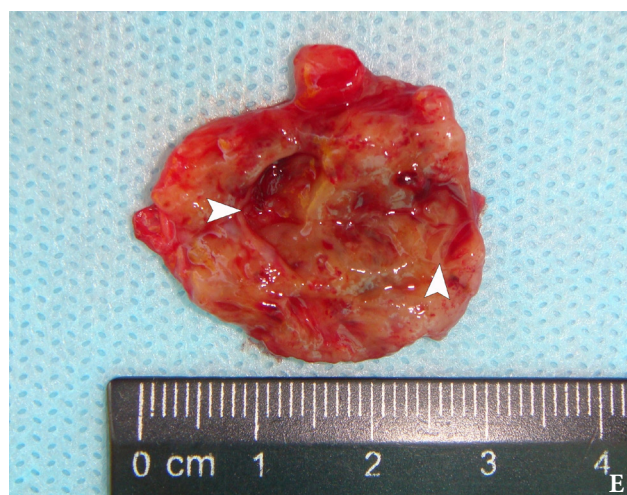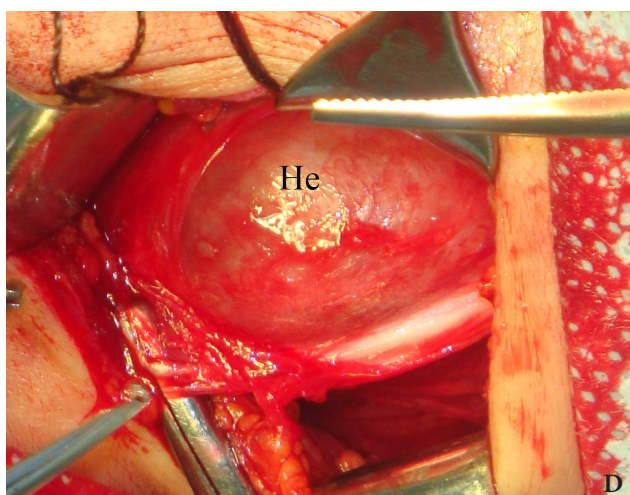
Paper received 09 August 2022

Accepted 29 August 2022

Available online 31 August 2022

<https://doi.org/10.23999/j.dtmp.2022.8.2>

© 2022 OMF Publishing, LLC. This is an open access article under the CC BY license (<https://creativecommons.org/licenses/by-nc/4.0/>).



A 26-year-old female patient presented with a painless soft tissue mass at the lower third of the right neck. The mass appearance and growth was noted during last several years. Longitudinal gray-scale ultrasound (US) showed that long-to-short diameter of this cystic lesion measured 3.51×2.12 cm (distances are indicated by even calipers '+' and 'x') (Panel A: *arrow*, position of the probe's side which corresponds to the probe bump and symbolizes the probe side [*arrow*] at Panel C; *arrowhead*, septa; C, cystic component; S, solid component). Lesion is visualized as a multicystic mass (hypoechoic with multiple anechoic areas) with septations and a prominent mixed structure (combination of macro- and microcystic cavities). A honeycomb US pattern¹ and no vascular fill of the anechoic areas (Panel B: *arrow*, position of the probe's side; *asterisk*, neck vessel; *arrowhead*, weak intratumoral blood flow), most likely represented a lymphangioma². Typically, the strong flow signal is noted from 9.30 to 59.37 percent of hemangioma cases.^{3,4} The artifact of acoustic enhancement—common for the fluid-containing structure—was noted posteriorly to the lesion. The fact that the tumor cannot be compressed using probe indicates that the cystic structure differs from the cystic structure of reported US features of cavernous lymphangiomas (sponge-like neoplasms)⁵. The capsulated lesion (Panel D: He, hemolympangioma) was surgically removed under general anesthesia applying the incision along the anterior margin of the right sternocleidomastoid muscle. During tumor removal, light-gray fluid content was partially evacuated due to the rupture

of cystic wall. Panel E shows a specimen—the decreased in volume mass—after the evacuation of its cystic content. The spaces of the intratumoral macrocysts are indicated by *arrowheads*. Histopathological examination established the diagnosis of a 'hemolympangioma' (also known as 'hemangiolympangioma'^{6,7}). The patient showed no signs of recurrence at the end of the 36-month follow-up period. Li et al (2017) emphasized that it's crucial to perform such preoperative imaging, which can help to avoid biopsy upon differential diagnostics between lymphangiomas and vascular malformations with numerous vessels (which can lead to intensive bleeding).⁸ In summary, hemolympangioma is a very rare mixed malformation of both blood and lymphatic vessels.⁹ Ohsawa et al (2018) concluded that complete excision of hemolympangiomas provides the best results with a lower recurrence rate.¹⁰ Diagnostic ultrasound and its Doppler option proved efficacy in case of such malformations. ■ DTJournal.org

REFERENCES (10)

1. Martín-Pérez E, Tejedor D, Brime R, Larrañaga E. Cystic lymphangioma of the lesser omentum in an adult. *Am J Surg* **2010**;199(2):e20–2. <https://doi.org/10.1016/j.amjsurg.2009.04.013>
2. Khaunte DDN, Kumar PS, Dhupar V, Naik M. Hemangiolympangioma of buccal cheek- a rare case report with review of literature. *J Dent Health Oral Disord Ther* **2020**;11(5):150–4. <https://doi.org/10.15406/jdhodt.2020.11.00534>
3. Keng CY, Lan HHC, Chen CCC, Gueng MK, Su YG,

- Lee SK. Soft tissue hemangiomas: high-resolution grayscale and color Doppler ultrasonographic features in 43 patients. *J Med Ultrasound* **2008**;16(3):223–30. [https://doi.org/10.1016/S0929-6441\(08\)60051-X](https://doi.org/10.1016/S0929-6441(08)60051-X)
4. Rózyło-Kalinowska I, Brodzisz A, Gałkowska E, Rózyło TK, Wieczorek AP. Application of Doppler ultrasonography in congenital vascular lesions of the head and neck. *Dentomaxillofac Radiol* **2002**;31(1):2–6. <https://doi.org/10.1038/sj/dmfr/4600650>
 5. Tymofieiev OO, Fesenko II, Cherniak OS, Zaritska VI. Features of diagnostics, clinical course and treatment of the branchial cleft cysts. *J Diagn Treat Oral Maxillofac Pathol* **2017**;1(1):15–31. <https://doi.org/10.23999/j.dtopm.2017.1.3>
 6. Agüero ME, Rojas RGA, Islas DA. Cystic hemangiolympangioma of the neck. Case report [in Spanish]. *An Med Asoc Med Hosp ABC* **2014**;59(4):299–303.
 7. Manickam S, Sasikumar P, Kishore BN, Joy S. Hemangiolympangioma of buccal mucosa: a rare case report. *J Oral Maxillofac Pathol* **2017**;21(2):282–5. https://doi.org/10.4103/jomfp.JOMFP_28_17
 8. Li Y, Zhang X, Pang X, Yang L, Peng B. Occipitocervical hemolympangioma in an adult with neck pain and stiffness: case report and literature review. *Case Rep Med* **2017**;2017:7317289. <https://doi.org/10.1155/2017/7317289>
 9. Senoh D, Hanaoka U, Tanaka Y, Tanaka H, Hayashi K, Yanagihara T, Hata T. Antenatal ultrasonographic features of fetal giant hemangiolympangioma. *Ultrasound Obstet Gynecol* **2001**;17(3):252–4. <https://doi.org/10.1046/j.1469-0705.2001.00347.x>
 10. Ohsawa M, Kohashi T, Hihara J, Mukaida H, Kaneko M, Hirabayashi N. A rare case of retroperitoneal hemolympangioma. *Int J Surg Case Rep* **2018**;51:107–11. <https://doi.org/10.1016/j.ijscr.2018.08.030>

U-Impl[®]

SWITZERLAND



№ R3M 804 252 B2

Сертифікат відповідності
технічного регламенту
щодо медичних виробів



Switzerland Aarbergerstrasse 107A, CH-2502
Biel, Phone/Fax +41 323230188
info@u-impl.com
www.u-impl.com