

# DT Journal

**10** <sup>2022</sup>

**Journal of Diagnostics and  
Treatment of Oral and  
Maxillofacial Pathology**



Editors  
Oleksii Tymofeiev • Rui Fernandes  
(Kyiv, Ukraine • Jacksonville, FL, USA)



Official Journal of the  
Ukrainian Association for  
Maxillofacial and Oral Surgeons

[DTJournal.org](http://DTJournal.org)

# TANTUM VERDE®

QUICK RELIEF FROM PAIN  
AND INFLAMMATION IN THE  
MOUTH AND THROAT<sup>1</sup>

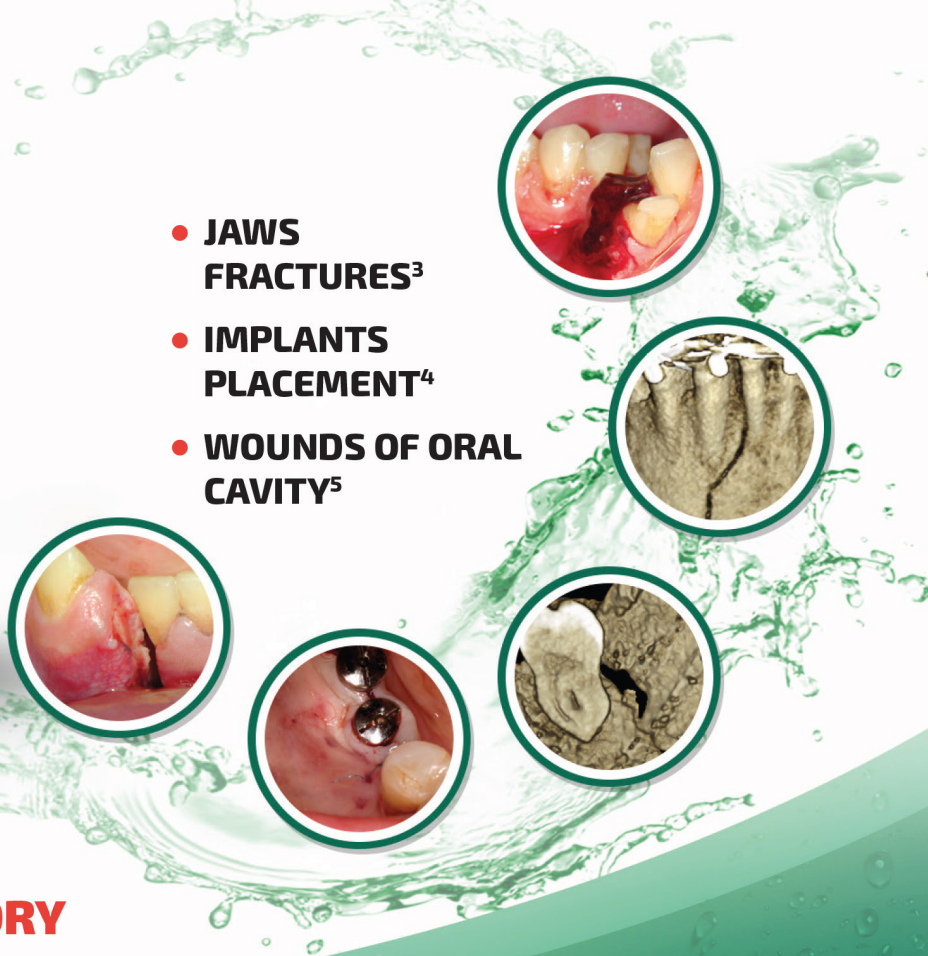
**AN INTEGRAL COMPONENT OF THE TREATMENT  
OF PAIN AND INFLAMMATION IN THE ORAL CAVITY  
IN 60 COUNTRIES WORLDWIDE!<sup>2</sup>**



Reg. № UA/3920/01/01

**LOCAL ANESTHETIC  
AND ANTI-INFLAMMATORY  
EFFECT<sup>1</sup>**

- **JAWS  
FRACTURES<sup>3</sup>**
- **IMPLANTS  
PLACEMENT<sup>4</sup>**
- **WOUNDS OF ORAL  
CAVITY<sup>5</sup>**



#### SUMMARY OF PRODUCT CHARACTERISTICS

**NAME OF THE MEDICINAL PRODUCT.** Tantum Verde 0.15% mouthwash. **QUALITATIVE AND QUANTITATIVE COMPOSITION.** Each 100 ml contains: active ingredient: benzydamine hydrochloride 0.15 g (equivalent to 0.134 g of benzydamine). **Therapeutic indications.** Treatment of symptoms such as irritation/inflammation including those associated with pain in the oropharyngeal cavity (e.g. gingivitis, stomatitis and pharyngitis), including those resulting from conservative or extractive dental therapy. **Posology and method of administration.** Pour 15 ml of Tantum Verde mouthwash into the measuring cup, 2-3 times per day, using it either at full concentration or diluted. If diluted, add 15 ml of water to the graduated cup. Do not exceed the recommended dosage. **Contraindications.** Hypersensitivity to benzydamine or to any of the excipient. **PHARMACOLOGICAL PROPERTIES. Pharmacodynamic properties.** Pharmacotherapeutic group: Stomatologic drugs: other agents for local oral treatment, ATC code: A01AD02. Clinical studies demonstrate that benzydamine is effective in relieving suffering from localised irritation of the mouth and pharynx. In addition, benzydamine possesses a moderate local anaesthetic effect. **Pharmacokinetic properties. Absorption.** Absorption through the oropharyngeal mucosa is demonstrated by the presence of measurable quantities of benzydamine in human plasma. These levels are insufficient to produce systemic effects. **Distribution.** When applied locally, benzydamine has been shown to accumulate in inflamed tissues where it reaches effective concentrations because of its capacity to penetrate the epithelial lining.

**Information about medicines. Information for health care professionals for use in professional activities.**

1. Інструкція для медичного застосування лікарського засобу Тантум Верде®, розчин для ротової порожнини, РПН № UA/3920/01/01, затверджено Наказом Міністерства охорони здоров'я України № 636 від 01.10.2015.

2. <http://www.angelini-pharma.com/wps/wcm/connect/com/home/Angelini+Pharma+in+the+world/>

3. Тимофеев А.А. и др. "Особенности гигиены полости рта для профилактики воспалительных осложнений при переломах нижней челюсти". Современная стоматология 2015;1(75):52-8.

4, 4.5. Tymofiejew O.O. et al "Prevention of inflammatory complications upon surgeries in maxillofacial region". J Diagn Treat Oral Maxillofac Pathol. 2017;1:105-12.

Clinical and CT images are courtesy of: Ievgen Fesenko (Department of Oral & Maxillofacial Surgery, PHEI "Kyiv Medical University", Kyiv, Ukraine), Oleg Mastakov ("SCIEDECE—Scientific Center of Dentistry & Ultrasound Surgery" Kyiv, Ukraine)



04119, Kiev, Melnikova str. 83D, of. 404.  
Tel.: (044) 538-01-26  
Fax: (044) 538-01-27



# About the Journal: Aims and Scope

OCTOBER 2022 • VOLUME 6 • ISSUE 10  
www.djournal.org

## Official Title

*Journal of Diagnostics and Treatment of Oral and Maxillofacial Pathology*

## Standard Abbreviation: ISO 4

*J. Diagn. Treat. Oral Maxillofac. Pathol.*

## Acronym

JDTOMP

## International Standard Serial Number (ISSN)

Electronic ISSN 2522-1965

## Aims & Scope

This is a monthly peer-reviewed oral and maxillofacial surgery journal focused on: microvascular and jaw reconstructive surgery, dental implants, salivary gland tumors/diseases, TMJ lesions, virtual surgical planning, implementation of ultrasonography into the practice of oral and maxillofacial surgeons.

## Editorial Board (EB) Composition

- EB shows significant geographic diversity representing 30 opinion leaders from 13 countries: Brazil, Canada, Colombia, Greece, Hong Kong (SAR, China), India, Israel, Italy, Slovak Republic, Spain, Ukraine, United Arab Emirates, and United States.
- The majority of the EB Members have a discernible publication history in Scopus, Web of Science, and journals with a high impact factor.
- The publication records of all EB members are consistent with the stated scope and published content of the journal.
- The journal has a several full-time professional editors.
- Gender distribution of the editors: 10% women, 90% men, 0% non-binary/other, and 0% prefer not to disclose.

## Frequency

12 issues a year (from January 2020)

## Publication History

2017: 4 issues a year

2018: 4 issues a year

2019: 10 issues a year

From 2020: 12 issues a year

## Publishing Model

*Journal of Diagnostics and Treatment of Oral and Maxillofacial Pathology* is a fully online-only open access and peer-reviewed publication.

## Type of Peer Review

The journal employs “double blind” reviewing.

## Article Publishing Charge (APC)

The APC in this journal is US \$500 and US \$250 (excluding taxes) depending on the article’s type. Details at website: [dtjournal.org](http://dtjournal.org).

## 13 Types of Articles Currently Published by the Journal

Editorials/Guest Editorials/Post Scriptum Editorials, Images, Case Reports/Case Series, Original Articles, Review Articles, Discussions, Paper Scans (*synonyms*: Review of Articles, Literature Scan), Book Scans (*synonym*: Book Reviews), Letters to the Editor (*synonym*: Letters), and Viewpoints.

## State Registration: Ministry of Justice of Ukraine

Registration: Jul 28, 2016 (Certificate: KB № 22251-12151 P)

Re-registration: May 21, 2019 (Certificate: KB № 23999-13839 IIP)

Re-registration: Aug 10, 2021 (Certificate: KB № 24951-14891 IIP)

## Co-Founders

1. Shupyk National Healthcare University of Ukraine (formerly known as Shupyk National Medical Academy of Postgraduate Education).
2. Private Higher Educational Establishment “Kyiv Medical University.”
3. OMF Publishing, Limited Liability Company.

## Publisher

OMF Publishing, LLC is an academic publisher focused on medical and linguistic sciences.

Address: 13-A Simferopolska Street, office 121, Kyiv 02096, Ukraine.

## Crossref Membership

OMF Publishing, LLC is a member of Publishers International Linking Association, Inc. which doing business as a Crossref. OMF Publishing’s active membership: From February 2017 to present.

## Official Journal of the Association

Ukrainian Association for Maxillofacial and Oral Surgeons

## Ukrainian Association for Maxillofacial and Oral Surgeons (UAMOS)

Address: 4-A Profesora Pidvysotskoho Street, Kyiv 01103, Ukraine.

Tel., fax: +38 044 528 35 17.

Website: [uamos.org](http://uamos.org).

© 2022 OMF PUBLISHING, LLC



# Editorial Board

OCTOBER 2022 • VOLUME 6 • ISSUE 10  
www.djournal.org

## Editor in Chief

**Oleksii O. Tymofiev, ScD**  
Kyiv, Ukraine

## Deputy Editor in Chief

**Rui P. Fernandes, MD, DMD, FACS, FRCS(Ed)**  
Jacksonville, Florida, United States

## Section Editors

### Bone Augmentation Techniques

**Nardy Casap, MD, DMD**  
Jerusalem, Israel

### Business

**Ivan V. Nagorniak, MSc, PhD**  
Kyiv, Ukraine

### Craniofacial Deformities

**Sunil Richardson, MDS**  
Nagercoil, Tamil Nadu, India

### Facial Feminization Surgery

**Kyle Keojampa, MD, FACS**  
Los Angeles, California, United States

### Facial Plastic Surgery

**Tirbod Fattahi, MD, DDS, FACS**  
Jacksonville, Florida, United States

### Head & Neck Oncologic Surgery

**Todd C. Hanna, MD, DDS, FACS**  
New York, New York, United States

### Head & Neck Radiology

**Anil T. Ahuja, MBBS, MD, FRCR, FHKCR, FHKAM**  
Hong Kong, SAR, China

### Images

**Camilo Mosquera, DDS**  
Bogotá, D.C., Colombia

### Orthognathic Surgery

**Mario Brinhole**  
São Paulo, São Paulo, Brazil

### Robotic Surgery

**Salam O. Salman, MD, DDS, FACS**  
Jacksonville, Florida, United States

### TMJ Lesions/Disorders

**Belmiro C. Vasconcelos, DDS, PhD**  
Recife, Pernambuco, Brazil

## Editorial Board Members

**Oleh M. Antonyshyn, MD, FRCS(C)**  
Toronto, Ontario, Canada

**Anthony M. Bunnell, MD, DMD, FACS**  
Jacksonville, Florida, United States

**Nur A. Hatab, DMD, PhD**  
Ras Al Khaimah, United Arab Emirates

**Michael T. Kase, DMD**  
Birmingham, Alabama, United States

**Andrey V. Kopchak, ScD**  
Kyiv, Ukraine

**Olindo Massarelli, MD, PhD, FEBOMFS**  
Sassari, Italy

**Anastasiya Quimby, DDS, MD**  
Fort Lauderdale, Florida, United States

**Daniel Robles Cantero, DDS, MSc**  
Madrid, Spain

**Peter Stanko, MD, PhD**  
Bratislava, Slovak Republic

**Rostyslav M. Stupnytskyi, ScD**  
Kyiv, Ukraine

**Olexander O. Tymofiev, ScD**  
Kyiv, Ukraine

**Natalia O. Ushko, ScD**  
Kyiv, Ukraine

**Andrew Yampolsky, DDS, MD**  
Philadelphia, Pennsylvania, United States

## Web & Social Media Editor

**João L. Monteiro, DDS**  
Boston, Massachusetts, United States

## Director, Journal Development Department

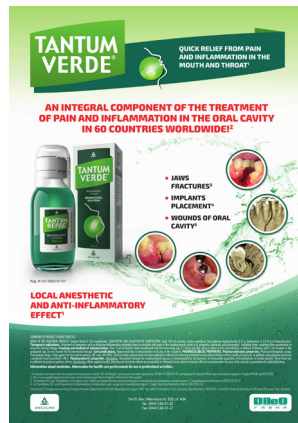**Evangelos G. Kilipiris, DMD**  
Thessaloniki, Greece | Bratislava, Slovak Republic

## Managing Editor

**Ievgen I. Fesenko, PhD**  
Kyiv, Ukraine

## Resident Ambassador

**John M. Le, DDS, MD**  
Birmingham, Alabama, United States



# TANTUM VERDE®

INFORMATION LEAFLET  
for the medicinal product

## **Composition:**

*active substance:* **benzydamine hydrochloride;**

100 mL of solution contain benzydamine hydrochloride 0.15 g;

*excipients:* ethanol 96%, glycerol, methyl parahydroxybenzoate (E 218), flavor (menthol), saccharin, sodium hydrocarbonate, Polysorbate 20, Quinoline Yellow (E 104), Patent Blue V (E 131), purified water.

**Dosage form.** Oromucosal solution.

*Basic physical and chemical properties:* a clear green liquid with a typical mint flavor.

**Pharmacotherapeutic group.** Dental preparations. Other agents for local oral treatment.

ATC code: A01A D02.

## **Pharmacological properties.**

### *Pharmacodynamics.*

Benzydamine is a non-steroidal anti-inflammatory drug (NSAID) with analgesic and antiexudative properties.

Clinical studies have shown that benzydamine is effective in the relief of symptoms accompanying localized irritation conditions of the oral cavity and pharynx. Moreover, benzydamine has anti-inflammatory and local analgesic properties, and also exerts a local anesthetic effect on the oral mucosa.

### *Pharmacokinetics.*

Absorption through the oral and pharyngeal mucosa has been proven by the presence of measurable quantities of benzydamine in human plasma. However, they are insufficient to produce any systemic pharmacological effect. The excretion occurs mainly in urine, mostly as inactive metabolites or conjugated compounds.

When applied locally, benzydamine has been shown to cumulate in inflamed tissues in an effective concentration

due to its ability to permeate through the mucous membrane.

## **Clinical particulars.**

### **Indications.**

Symptomatic treatment of oropharyngeal irritation and inflammation; to relieve pain caused by gingivitis, stomatitis, pharyngitis; in dentistry after tooth extraction or as a preventive measure.

### **Contraindications.**

Hypersensitivity to the active substance or to any other ingredients of the product.

### **Interaction with other medicinal products and other types of interaction.**

No drug interaction studies have been performed.

### **Warnings and precautions.**

If sensitivity develops with long-term use, the treatment should be discontinued and a doctor should be consulted to get appropriate treatment.

In some patients, buccal/pharyngeal ulceration may be caused by severe pathological processes. Therefore, the patients, whose symptoms worsen or do not improve within 3 days or who appear feverish or develop other symptoms, should seek advice of a physician or a dentist, as appropriate.

Benzydamine is not recommended for use in patients hypersensitive to acetylsalicylic acid or other non-steroidal anti-inflammatory drugs (NSAIDs).

The product can trigger bronchospasm in patients suffering from or with a history of asthma. Such patients should be warned of this.

For athletes: the use of medicinal products containing ethyl alcohol might result in positive antidoping tests considering the limits established by some sports federations.

#### *Use during pregnancy or breast-feeding*

No adequate data are currently available on the use of benzydamine in pregnant and breastfeeding women. Excretion of the product into breast milk has not been studied. The findings of animal studies are insufficient to make any conclusions about the effects of this product during pregnancy and lactation.

The potential risk for humans is unknown.

TANTUM VERDE should not be used during pregnancy or breast-feeding.

#### *Effects on reaction time when driving or using machines*

When used in recommended doses, the product does not produce any effect on the ability to drive and operate machinery.

#### **Method of administration and doses.**

Pour 15 mL of TANTUM VERDE solution from the bottle into the measuring cup and gargle with undiluted or diluted product (15 mL of the measured solution can be diluted with 15 mL of water). Gargle 2 or 3 times daily. Do not exceed the recommended dose.

#### *Children.*

The product should not be used in children under 12 years due to a possibility of ingestion of the solution when gargling.

#### **Overdosage.**

No overdose has been reported with benzydamine when used locally. However, it is known that benzydamine, when ingested in high doses (hundreds times higher than those possible with this dosage form), especially in children, can cause agitation, convulsions, tremor, nausea, increased sweating, ataxia, and vomiting. Such acute overdose requires immediate gastric lavage, treatment of fluid/salt imbalance, symptomatic treatment, and adequate hydration.

#### **Adverse reactions.**

Within each frequency group, the undesirable effects are presented in order of their decreasing seriousness.

Adverse reactions are classified according to their frequency: very common ( $\geq 1/10$ ); common ( $\geq 1/100$  to  $<1/10$ ); uncommon ( $\geq 1/1,000$  to  $<1/100$ ); rare ( $\geq 1/10,000$  to  $<1/1,000$ ); very rare ( $<1/10,000$ ); frequency unknown (cannot be estimated from the available data).

*Gastrointestinal disorders:* rare – burning mouth, dry mouth; *unknown* – oral hypesthesia, nausea, vomiting, tongue edema and discoloration, dysgeusia.

*Immune system disorders:* rare – hypersensitivity reaction, *unknown* – anaphylactic reaction.

*Respiratory, thoracic and mediastinal disorders:* very rare – laryngospasm; *unknown* – bronchospasm.

*Skin and subcutaneous tissue disorders:* uncommon – photosensitivity; very rare – angioedema; *unknown* – rash, pruritus, urticaria.

*Nervous system disorders:* *unknown* – dizziness, headache.

TANTUM VERDE contains methyl parahydroxybenzoate, which can cause allergic reactions (including delayed-type reactions).

**Shelf life.** 4 years.

#### **Storage conditions.**

Do not store above 25°C. Keep out of reach of children.

#### **Packaging.**

120 mL of solution in a bottle with a measuring cup; 1 bottle per cardboard box.

#### **Dispensing category.**

Over-the-counter medicinal product.

#### **Manufacturer.**

Aziende Chimiche Riunite Angelini Francesco A.C.R.A.F. S.p.A., Italy.

Location of the manufacturer and its business address. Via Vecchia del Pinocchio, 22 – 60100 Ancona (AN), Italy.

#### **Date of the last revision of the text.**

September 26, 2018.

Information leaflet is

**APPROVED** by

Order of the

**Ministry of Health of Ukraine**

No. 636 dated 01.10.2015

**Registration Certificate**

No. UA/3920/01/01

# Our Supporters

OCTOBER 2022 • VOLUME 6 • ISSUE 10  
www.djournal.org



**FIGURE.** Evangelos G. Kilipiris, MD, DMD from the National Institute of Children’s Diseases and Faculty of Medicine at Comenius University, Bratislava, Slovak Republic. A kind support of Dr. Kilipiris during the 5 years at the position of Director, Journal Development Department helped our journal to move forward and to evolve. An honorary plaque was presented to him on behalf of the Chief Editor with words “To a Founding Director, Author of Multiple Articles and Reviews, Great Thanks and Appreciation.” Photo was taken on November 23, 2021.

# Content

of the Volume 6 • Issue 10 • October 2022

A1 **Publisher & Editorial Office Information**

A2 **Editorial Board**

A5 **Our Supporters**

A6 **Content, Courtesy, & Erratum**

## BUSINESS: EDITORIAL

129 **Region of Recent Hostilities: Disruption of Chain of Work Processes in the Practice of Oral Surgeon: Opportunity for the New Generation of Stomatologists**

Ivan V. Nagorniak

## CASE

131 **Odontogenic Cutaneous Fistula and Abscess of the Superficial Peri-Zygomatic Area**

Ievgen I. Fesenko



## COURTESY

*Journal's* cover image (virtual surgical planning for a segmental mandibular reconstruction with fibula transplant) is courtesy of Rui P. Fernandes, MD, DMD, FACS, FRCS.

Image was taken from the article: Fernandes RP, Quimby A, Salman S. Comprehensive reconstruction of mandibular defects with free fibula flaps and endosseous implants. *J Diagn Treat Oral Maxillofac Pathol* 2017;1(1):6–10.

<https://doi.org/10.23999/j.dtomp.2017.1.1>





## BUSINESS: EDITORIAL

Ivan V. Nagorniak, MSc, PhD, *Section Editor*

# Region of Recent Hostilities: Disruption of Chain of Work Processes in the Practice of Oral Surgeon: Opportunity for the New Generation of Stomatologists

Ivan V. Nagorniak

... *Russia has broken the normal chains...*<sup>1</sup>

—Volodymyr Zelenskiy

President of Ukraine

Day 235 of a full-scale Russian-Ukrainian war  
(Oct 16, 2022)

Day 247 of a full-scale Russian invasion in Europe. The recent rocket attack on Kyiv during the morning commute and an attack by kamikaze drones<sup>2,3</sup> is not something that can contribute to a positive work atmosphere and a boom in job interviews. Such continuous acts of terrorism can only cause a disruption in the chains of work processes. In stomatology, such chains cannot be built overnight. Typically, it takes years of collaboration and growth of the trust.

The quality of the relationship between the members of the chain, speed of collaboration, accessibility of stomatologist for the particular patient are vital for the success of the entire chain having a positive effect on profitability and existence of the whole (Huntley, 2006; Atrek et al, 2014;

Nagorniak, 2022).<sup>4-6</sup>

On other hand, such gaps in the chains of work processes are the chances for the young, less experienced stomatologists of all specialties—orthodontists, prosthetic stomatologists, surgeons focused on dental implants, etc. A chance to take the place of more experienced and famous stomatologists.

Summarizing the 247 days of Russia's war of aggression against Ukraine, the following conclusions can be drawn regarding the disruption of work process chains in Kyiv city and options for their resolution:

- Percentage of female stomatologists and doctors from medical departments which evacuated are higher comparing to male colleagues. Maybe, upon the repair of the broken work chains for the period till victory over occupiers, oral surgeon should focus on male colleagues with reason to avoid possible future disruption of a repaired work chains. On other hand, we must avoid discrimination

MSc, PhD; Head Doctor, Individual Entrepreneur Nagorniak I.V., Kyiv, Ukraine.

Author's address: Private Practice (Certificate for management system according to ISO 9001:2015 – Private Entrepreneur Nagorniak I.V.), 6-G Andriushchenka Street, Office 6, Kyiv 01135, Ukraine.  
E-mail: [ivan.nagorniak@gmail.com](mailto:ivan.nagorniak@gmail.com)

Please cite this article as: Nagorniak IV. Region of recent hostilities: disruption of chains of work processes in the practice of oral surgeon: opportunity for the new generation of stomatologists. *J Diagn Treat Oral Maxillofac Pathol* 2022;6(10): 129–30.

Available online 28 October 2022

<https://doi.org/10.23999/j.dtmp.2022.10.1>

© 2022 OMF Publishing LLC. This is an open access article under the CC BY license (<http://creativecommons.org/licenses/by-nc/4.0/>).

based on gender.

- Young and/or less experienced stomatologist can receive their chance to start collaboration with highly experienced team or to hold a position in a clinic of their dream.
- Delay (loss of time) for the period of searching for new partners to resume the chain of work processes affects the ability to perform certain manipulations and, as a result, affects the profitability of the practice. Thus, the practice owner or practitioner should react promptly and dedicate part of their time and efforts to repair the chain as soon as possible. Moreover, those stomatological practice owners who will manage this challenge faster than others will be more successful.
- While trying to find the positive in this difficult wartime situation, we can say that such disruptions to work processes are also a way to refresh the stomatological team and find new talents.

#### REFERENCES (6)

1. Account: [@zelenskiy\\_official](#). Instagram [internet]; Oct 16, 2022 [cited 2022 Oct 16]. Available from: [https://www.instagram.com/reel/CjyTx\\_qvNud/?igshid=YmMyMTA2M2Y=](https://www.instagram.com/reel/CjyTx_qvNud/?igshid=YmMyMTA2M2Y=)
2. Bennett D, Piper I, Mirza A, Le S, Hrabchuk K. The scale of Russian attacks on Ukraine's infrastructure, visualized. The Washington Post [internet]; Oct 14, 2022 [cited 2022 Oct 16]. Available from: <https://www.washingtonpost.com/investigations/2022/10/14/ukraine-infrastructure-damage/>
3. Ismay J. The Iranian drones in Ukraine's already crowded skies. The New York Times [internet]; Oct 19, 2022 [cited 2022 Oct 23]. Available from: <https://www.nytimes.com/2022/10/19/us/politics/ukraine-drones-iran-russia.html>
4. Huntley JK. Conceptualization and measurement of relationship quality: linking relationship quality to actual sales and recommendation intention. *Ind Mark Manag* 2006;35(6):703–14. <https://doi.org/10.1016/j.indmarman.2005.05.011>
5. Atrek B, Marccone MR, Gregori GL, Temperini V, Moscatelli L. Relationship quality in supply chain management: a dyad perspective. *Ege Academic Review* 2014;14(3):371–82.
6. Nagorniak IV. Managing private practice in a war zone. *J Diagn Treat Oral Maxillofac Pathol* 2022;6(3):35–6. <https://doi.org/10.23999/j.dtomp.2022.3.1>



## CASE

# Odontogenic Cutaneous Fistula and Abscess of the Superficial Peri-Zygomatic Area

Ievgen I. Fesenko

## SUMMARY

Purulent processes of the zygomatic and peri-zygomatic area are not common. Among etiologies are: otitis media, complication of zygomatic implantation, osteomyelitis, medication-related osteonecrosis of the jaw, drug-related osteonecrosis, and odontogenic infection. This article highlights the first literature reported case of clinical presentation of odontogenic abscess and cutaneous fistula of the superficial peri-zygomatic area from the upper third molar. The preoperative and follow-up photographs of a 76-year-old Caucasian male patient are demonstrated. The uniqueness of this case is that until now the upper third molars never been published as a source of abscesses of the peri-zygomatic area.

Doctor-Stomatologist-Surgeon (DSS), PhD, Associate Professor, Department of Oral and Maxillofacial Surgery, Private Higher Educational Establishment "Kyiv Medical University," Kyiv, Ukraine.

Corresponding author's address: Department of Oral and Maxillofacial Surgery on the basis of Kyiv City Clinical Hospital #12, Private Higher Educational Establishment "Kyiv Medical University," 4A Profesora Pidvysotskoho Street, office 619, Kyiv 01103, Ukraine.  
E-mail: [eugenfesenko@gmail.com](mailto:eugenfesenko@gmail.com) (Ievgen Fesenko)  
ORCID: <https://orcid.org/0000-0002-8901-1632>

Please cite this article as: Fesenko II. Odontogenic cutaneous fistula and abscess of the superficial peri-zygomatic area. *J Diagn Treat Oral Maxillofac Pathol* 2022;6(10):131–4.

Word 'Video' at the upper right icon means that article contains supplemental video content.

Paper received 28 August 2022  
Accepted 15 September 2022  
Available online 31 October 2022

<https://doi.org/10.23999/j.dtmp.2022.10.2>

© 2022 OMF Publishing LLC. This is an open access article under the CC BY license (<https://creativecommons.org/licenses/by-nc/4.0/>).

## INTRODUCTION

Purulent processes of the zygomatic and peri-zygomatic area are not common. Among etiologies are: otitis media,<sup>1,2</sup> complication of zygomatic implants placement,<sup>3,4</sup> osteomyelitis,<sup>5</sup> medication-related osteonecrosis of the jaw (MRONJ), “Krokodil” drug-related osteonecrosis,<sup>6</sup> and odontogenic infection<sup>7,8</sup>. The last one in the peri-zygomatic area can manifest in a form of sinus tract<sup>7</sup>, abscess<sup>8</sup>, and even phlegmon<sup>8</sup>. To our literature search in English language there is no publication data which presents the clinical images of odontogenic cutaneous fistula and abscess of the peri-zygomatic area from upper third molar. That is why we are presenting the pre- and postoperative images of such rare case in a male patient.

## CASE

A 76-year-old Caucasian male patient was referred to our hospital by doctor-stomatologist-surgeon from the stomatological polyclinic in Kyiv region. The patient appeared in the Center of Maxillofacial Surgery in 2016 at 10:18 p.m. with a significant swelling, erythema, and pyorrhea from cutaneous fistula in a right peri-zygomatic area (Figs 1A and 2A). According to patient complaints the pain appeared in the tooth 1.8 (upper right third molar) a week before, and then the swelling in a right peri-zygomatic area appeared and began to increase with gradual erythema of the skin above it. Tooth 1.8 was extracted by doctor in a Kyiv region on the day of the visit to the polyclinic (i.e., out-patient clinic). Mouth opening was free. Panoramic radiography (Planmeca ProMax® 2D S3, Planmeca, Helsinki, Finland) performed in Kyiv Regional Clinical Hospital showed the empty socket of the tooth 1.8 and no radiological evidence of tooth remains.

Under the intramuscular injection of Dexalgin Inject 50 mg/2.0 ml (Laboratorios Menarini S.A., Barcelona, Spain; A. Menarini Manufacturing Logistics and Services Srl, Prato, Italy), first, applying the halsted-mosquito atraumatic hemostat (curved) the evacuation of the purulent content was performed. Then, finger revision of the purulent wound by a little finger was done. Purulent content in amount of ~6.0 ml was obtained. Irrigation of the wound with antiseptic solution was done and a sterile gauze bandage with Oflocain-Darnitsa®

(Pharmaceutical Firm Darnitsa, PRJSC, Kyiv, Ukraine) was applied (inside the wound). There was no need to drain a purulent wound using tubular perforated drainage due to the evacuation of purulent contents through an expanded fistula.

General state and condition of the local tissues improved day by day. On a day 4 of the postoperative period, the wound healed by secondary intention (Figs 1B and 2B) and its condition was acceptable. The patient was discharged that day from the hospital with postoperative recommendations—Solcoseryl® ointment (MEDA Pharmaceuticals Switzerland GmbH, Dübendorf, Switzerland) for several days and carrying out dental prosthetics.

## DISCUSSION

The term “zygomatic abscess” in English literature is commonly applied to the zygomatic root abscess—a rare extra cranial complication of acute otitis media.<sup>1,2</sup> In the East European states (e.g., Ukraine), in oral and maxillofacial surgery publications, the term “zygomatic abscess/phlegmon” is applied to the purulent infection of superficial peri-zygomatic area.<sup>8</sup> But only rare literature sources report odontogenic infection of such abscesses as the possible etiology.<sup>8</sup> Reported odontogenic source is infection from the upper premolars or first molar.<sup>8</sup>

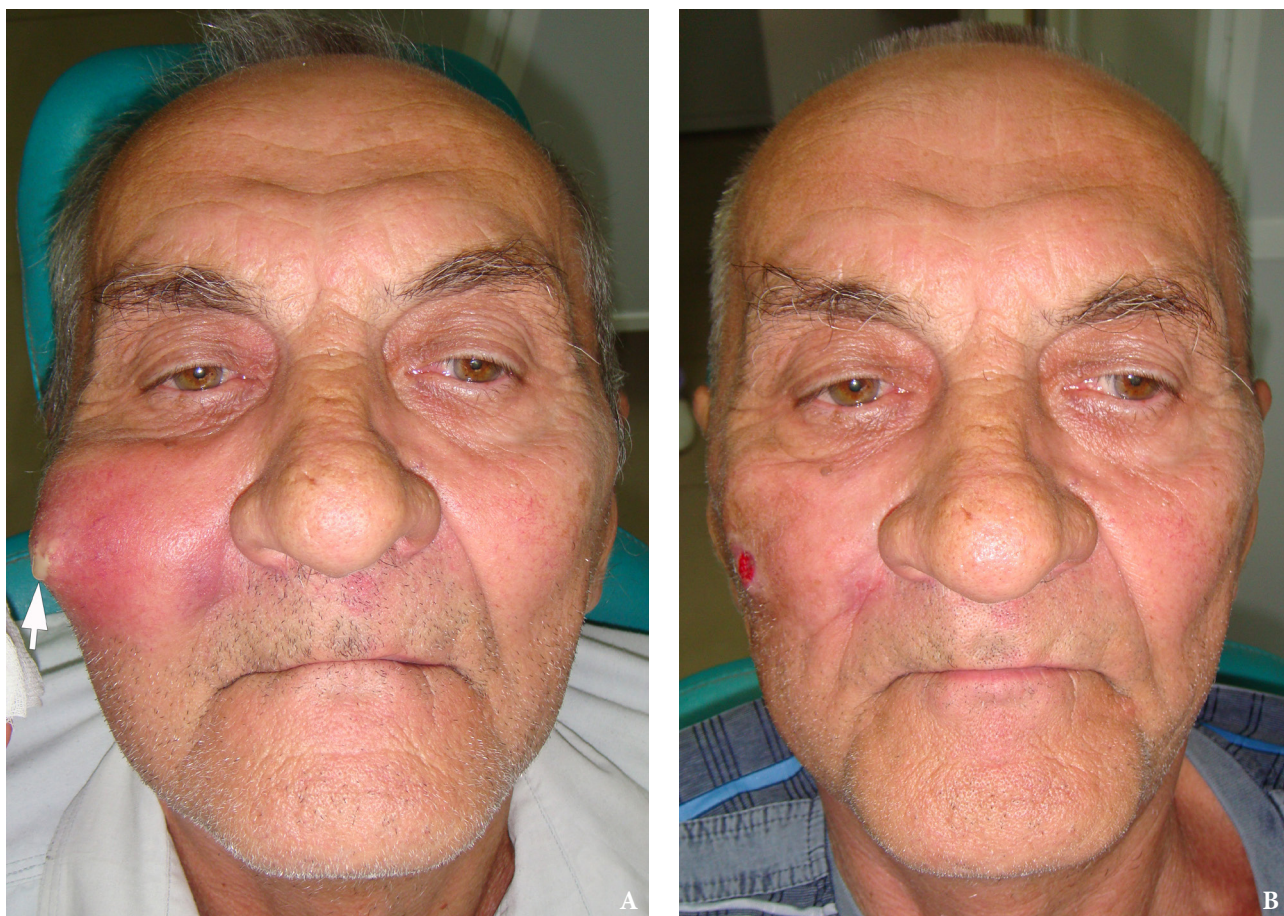Peri-zygomatic (i.e., peri-malar) area includes the soft tissues which surround the zygomatic bone outside the orbit. To be clear, it’s reasonable to distinct superficial and deep peri-zygomatic area. Mendelson et al (2012) describe in the superficial peri-zygomatic region location of the prezygomatic cellular space.<sup>9</sup>

Odontogenic cutaneous sinus tract with skin fistula as one of its manifestations in the peri-zygomatic area have been reported, but the area was termed differently. Lee et al (2016) describe it as buccal cheek area.<sup>7</sup> According to their data, in that area the odontogenic cutaneous sinus tract was manifested in 14.7 percent of odontogenic sinus tract cases (from upper first and second premolars [20 percent] and first and second molars [80 percent])<sup>7</sup>.

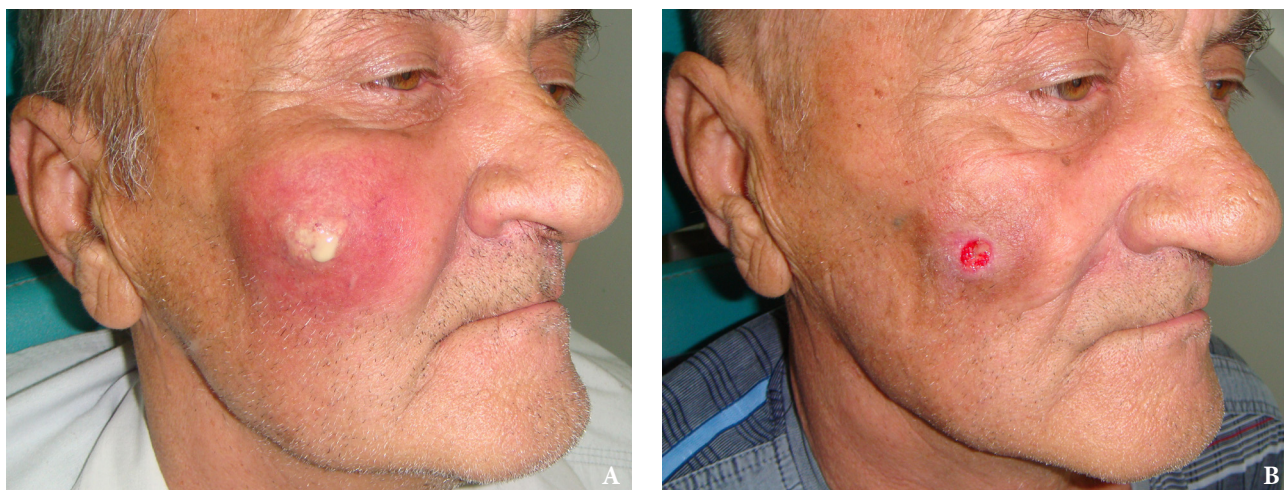Suppurated congenital cysts of the zygomatic area are also reported and should be taken into account for the differential diagnosis in similar manifestations.<sup>8</sup>

Before this inflammatory process, the patient did not notice the presence of the skin fistula or swelling





**FIGURE 1. A**, Preoperative view of a 76-year-old male patient with facial swelling in the right peri-zygomatic area. A notable purulent discharge from a skin fistula is labeled by *arrow*. **B**, Postoperative view on a day 4. The wound is healing by secondary intention.



**FIGURE 2.** Preoperative (**A**) and postoperative view on a day 4 (**B**).

in this area. This fact and the absence of firm intraoral submucosal strand upon palpation allowed us to rule out the diagnosis of the odontogenic cutaneous sinus tract manifested with cutaneous fistula (Baba et al, 2017)<sup>10</sup> or abscess. But this purulent process could be considered as one of the stages of sinus tract formation if the tooth was preserved without endodontic treatment.

Such purulent condition in that area should be managed as soon as possible to avoid zygomatic bone osteomyelitis, further spread of the inflammatory process, and long-term impairment of social life due to cosmetic problems.

### CONCLUSIONS

This paper highlights the first literature reported case of clinical presentation of odontogenic abscess and cutaneous fistula of the superficial peri-zygomatic area from the upper third molar. The preoperative and follow-up photographs are demonstrated. The uniqueness of this case is that until now the upper third molars never been published as a source of abscesses of the peri-zygomatic area.

### FUNDINGS

No funding was received for this study.

### PATIENT CONSENT

The patient provided written consent for the use of his image.

### REFERENCES (10)

1. Sathe N. Zygomatic abscess as a complication of otitis media. *Natl J Maxillofac Surg* **2011**;2(2):181–3.
2. Kuczkowski J, Narozny W, Stankiewicz C, Mikaszewski B, Izycka-Swieszewska E. Zygomatic abscess with temporal myositis - a rare extracranial complication of acute otitis media. *Int J Pediatr Otorhinolaryngol* **2005**;69(4):555–9.  
<https://doi.org/10.1016/j.ijporl.2004.10.018>
3. Tzerbos F, Bountaniotis F, Theologie-Lygidakis N, Fakitsas D, Fakitsas I. Complications of zygomatic implants: our clinical experience with 4 cases. *Acta Stomatol Croat* **2016**;50(3):251–7.  
<https://doi.org/10.15644/2Fasc50%2F3%2F8>
4. Vrielinck L, Moreno-Rabie C, Schepers S, Van Eyken P, Coucke W, Politis C. Peri-zygomatic infection associated with zygomatic implants: a retrospective longitudinal cohort study. *Clin Oral Implants Res* **2022**;33(4):405–12.  
<https://doi.org/10.1111/clr.13900>
5. Kang HJ, Lee JH, Kim YD, Byun JH, Shin SH, Kim UK, Jung IK. Osteomyelitis occurring in the zygoma caused by odontogenic maxillary sinusitis - case report [in Korean]. *J Korean Assoc Oral Maxillofac Surg* **2004**;30(3):251–4.
6. Hakobyan K, Poghosyan Y. "Krokodil" drug-related osteonecrosis of midface: a case series. *J Craniomaxillofac Surg* **2019**;47(12):1918–21.  
<https://doi.org/10.1016/j.jcms.2019.11.002>
7. Lee EY, Kang JY, Kim KW, Choi KH, Yoon TY, Lee JY. Clinical characteristics of odontogenic cutaneous fistulas. *Ann Dermatol* **2016**;28(4):417–21.
8. Tymofeiev OO. Manual of maxillofacial and dental surgery [in Russian]. 5th ed. Kyiv: Chervona Ruta-Turs; **2012**:276–318.
9. Mendelson BC, Muzaffar AR, Adams WP Jr. Surgical anatomy of the midcheek and malar mounds. *Plast Reconstr Surg* **2002**;110(3):885–96; discussion 897–911.  
<https://doi.org/10.1097/00006534-200209010-00026>
10. Baba A, Okuyama Y, Shibui T, Ojiri H. Odontogenic cutaneous fistula mimicking malignancy. *Clin Case Rep* **2017**;5(5):723–4.  
<https://doi.org/10.1002/ccr3.907>



# U-Impl<sup>®</sup>

SWITZERLAND



№ R3M 804 252 B2

Сертифікат відповідності  
технічного регламенту  
щодо медичних виробів



Switzerland Aarbergerstrasse 107A, CH-2502  
Biel, Phone/Fax +41 323230188  
info@u-impl.com  
www.u-impl.com