

Tooth Root Injury and Orthodontic Microimplant Fracture Caused by Its Incorrect Placement: Case Report*

Nataliia M. Kosiuk^{1,*}, Bohdan R. Kondratiuk²

¹ Scientific Center of Dentistry and Ultrasound Surgery (SCIEDECE), National Military Clinical Center "GVKG", Kyiv, Ukraine. Orthodontist (ScM)

² Director of the Scientific Center of Dentistry and Ultrasound Surgery (SCIEDECE), Kyiv, Ukraine. Oral surgeon.

ABOUT ARTICLE

Article history:

Paper received 01 December 2017

Accepted 03 February 2018

Available online 30 March 2018

Keywords:

Microimplants

Mini-implants

Miniscrews

Temporary anchorage device

Mesiobuccal (MB) canal of the tooth

Microimplant fracture

Tooth injury

Supernumerary tooth

Upper central incisor (U1)

Frankfurt horizontal (FH) plane

ABSTRACT

The purpose of this case report was to elucidate the condition after tooth injury while drilling and orthodontic microimplant fracture caused by its incorrect positioning. Among the investigation methods were CT, pulp vitality test, and endo-ice. That case clearly demonstrates and supports opinion of other authors [6-8] that injury of periodontium and tissues of the root while drilling and placement of the microimplants can cause no significant disturbances in the future. Even in case of drilling in close proximity to root canals.

© 2018 OMF Publishing, LLC. This is an open access article under the CC BY licence (<http://creativecommons.org/licenses/by-nc/4.0/>).

Introduction

Microimplants (*synonyms*: mini-implants, miniscrew implants, temporary anchorage devices) as skeletal anchorage were implemented into clinical practice by Creekmore and Eklund in 1980s [1]. They used titanium screw below the nasal spine for intermaxillary fixation after orthognathic surgery, and intruded the maxillary incisors. Roberts *et al* [2] used implant fixture in the retromolar area. A canine was connected to the fixture with a bypass wire and used for mesialization of the mandibular molar to the edentulous area [1]. Then the specialists from the East Asia countries started to use widely microimplants and titanium plates as temporary anchorage devices [3]. The era of wide usage of microimplants lead, as any other surgical procedure, to some percentage of complications. According to Alves *et al* (2013) [4] among them: microimplant fracture, ulceration of the mucosa, periimplant mucositis, and damage of the tooth roots adjacent to the microimplant.

Case Presentation

A 26-year-old lady turned to SCIEDECE center seeking for orthodontic treatment, with main complains on crooked teeth, not satisfying smile. After proper investigations (plaster models, orthopantomogram, cephalogram/cephalometric analysis, intra- and extraoral phototography) she was diagnosed skeletal class I, low angle, light crowding on both arches (2.5 mm on upper arch, 4 mm on lower arch), upper incisors protrusion (U1/FH = 117), presence of the impacted supernumerary tooth 2.9. Treatment plan included all third molars extraction, tooth 2.9 removal within 3-6 month follow-up, full unremovable appliance placement, stripping 2 mm on upper arch, 2.5 mm on lower arch, 2 interradicular microimplants placement between upper second premolars and first molars for strong anchorage, while leveling and stripping space utilization. Upon these conditions it was essential to place microimplants maximally distal in the interradicular space as possible, to allow proper leveling. While second microimplant placement, a complication occurred – lower third of the microimplant was fractured. The cone beam computed tomography (CT) was performed. It showed impacted supernumerary tooth 2.9, that moved coronally in comparison to previous location, tip of the fractured microimplant near the mesiobuccal root of tooth 2.7 (Fig 1), and areas of drilling (Fig 2). The tooth 2.7 responded

* This manuscript has not been presented

* Corresponding author. Sciedece, Scientific Center of Dentistry and Ultrasound Surgery (SCIEDECE), 6A, Bohatyr'ska Str., Kyiv 04209, Ukraine. Tel: +380964883678 Fax: +380442908030 E-mail address: nkosiuk@gmail.com (N.M. Kosiuk) Instagram: [n.kosiuk](https://www.instagram.com/n.kosiuk); [sciedece](https://www.instagram.com/sciedece)

UDC: 1234455560607778-8-8-8-88-8-8-87

<http://dx.doi.org/10.23999/j.dtemp.2018.2.3>

to pulp vitality test (Vitality Scanner 2006, SybronEndo, Glendora, California, USA), and wasn't sensitive to endo-ice [5, 6]. We removed the fractured tip of the microimplant simultaneously with impacted tooth 2.9 (Fig 1D) under local anaesthesia (1.7 ml Ultracaine D-S forte, Sanofi-

Aventis, Frankfurt am Main, Germany). No discoloration, pulpitis, ankylose symptoms were noted during following steps of orthodontic treatment. After 14 months of orthodontic treatment, the treatment was completed and 18-month follow-up showed a successful outcome.

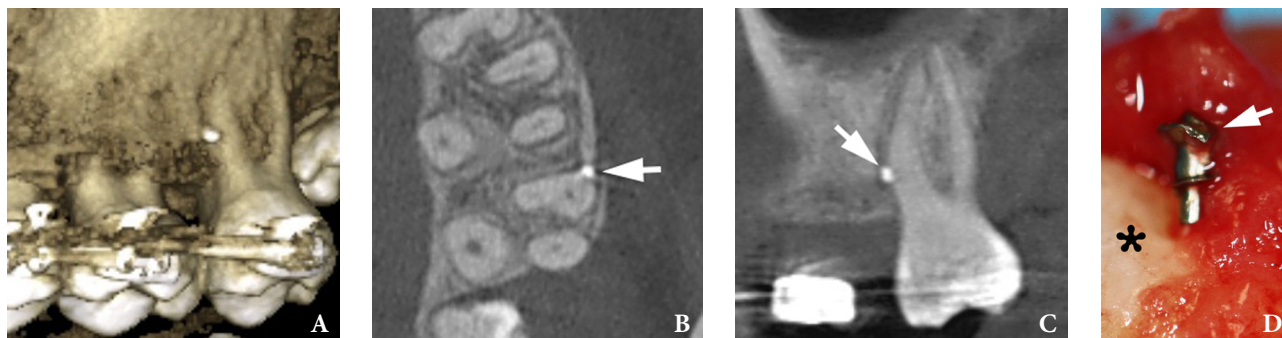


FIGURE 1. Cone beam CT scans (A: 3D reconstructed; B: axial; C: panoramic) shows fractured tip of microimplant (arrows) and its incorrect positioning into the tooth ligament. (D) Tip (arrow) of the fractured microimplant after removal (magnification, $\times 10$) simultaneously with supernumerary tooth 2.9 (asterisk: crown of the removed tooth 2.9).

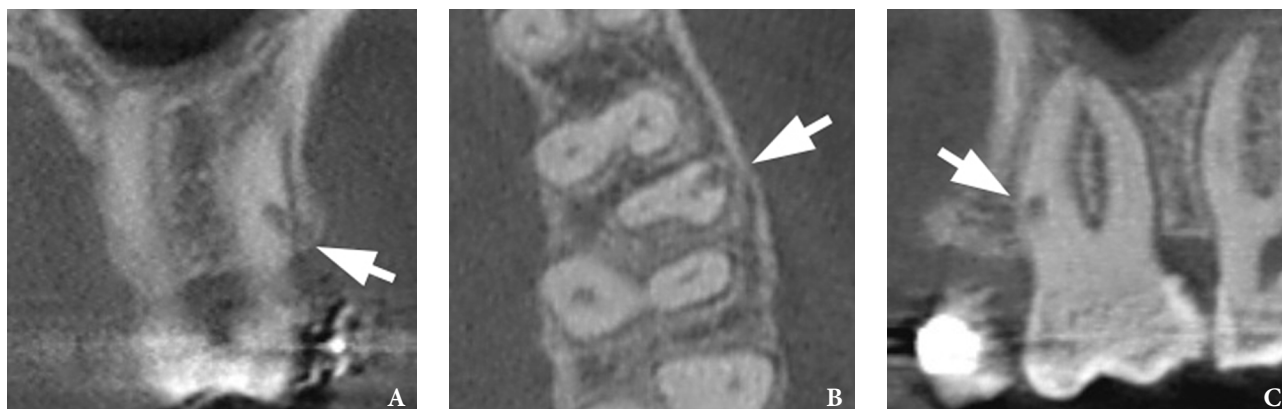


FIGURE 2. CT scans (A: coronal; B: axial; C: panoramic) shows area of drilling (arrow) causing the damage to the hard and soft tissues of the tooth root. Note proximity of the insertion hole to the first mesiobuccal (MB1) canal of the tooth 2.7.

Discussion

Orthodontic microimplants are frequently placed interradiicularly, so there is a risk of injury to the roots of the teeth. That can be a possible cause of pulpitis/periodontitis in some cases. However, iatrogenic root trauma is a rather rare complication. Animal studies have proved complete healing of insignificant damage to root tissue following implant removal, resulting in a normal periodontal structure [6-8]. In contrast, heavily injured tissue did not heal completely [7], but left a bony ankylosed area on the root surface, which can have a negative impact on orthodontic tooth movement. The defect is usually delayed by secondary cement [9, 10]. And histological examination of the roots in study of Asscherickx *et al* (2005) [10] demonstrated an almost complete repair of the periodontal structure (e.g. cementum, periodontal ligament and bone) in a period of 12 weeks, following removal of the microimplants. Few authors point out the

significant difference in primary failure rate on the left side (9.29%) vs the right (5.12%) that reflects the technical sensitivity of the procedure for operator [11].

Conclusion

Our case clearly demonstrates and supports opinion of authors [6-8] that periodontium and root injury upon drilling and placement of the microimplants can cause no significant disturbances in the future. Even in case of drilling in close proximity to root canals.

Funding

None.

Conflict of Interests

The authors declare no conflict of interests.

Role of Authors

The authors are equally contributed to that article.

Patient Consent

Written patient consent was obtained to publish the CT images.

Acknowledgements

Ievgen I. Fesenko (*PhD, Assis Prof*; Kyiv, Ukraine) for his assistance in editing of the article.

Peer Reviewed

Externally peer reviewed.

References

1. Kuroda S, Tanaka E. Risks and complications of miniscrew anchorage in clinical orthodontics. *Japanese Dental Science Review* **2014**;50(4):79–85.
2. Roberts WE, Marshall KJ, Mozsary PG. Rigid endosseous implant utilized as anchorage to protract molars and close an atrophic extraction site. *Angle Orthod* **1990**;60:135–52.
3. Kyung HM, Park HS, Bae SM, Sung JH, Kim IB. Development of orthodontic micro-implants for intraoral anchorage. *J Clin Orthod* **2003**;37:321–8.
4. Alves M, Baratieri C, Mattos CT, Tirre de Souza Araújo M, Maia LC. Root repair after contact with mini-implants: systematic review of the literature. *Eur J Orthod* **2013**;35(4):491–9.
5. Tymofieiev OO, Fesenko IeI, Tymofieiev OO. Condition of the teeth in fracture gap of the mandible. *J Diagn Treat Oral Maxillofac Pathol* **2017**;1:41–53.
6. Qin YJ, Zhang GD, Zhang Y, Ping YF, Zhao CY. Natural reversal of tooth discoloration and pulpal response to testing following removal of a miniscrew implant for orthodontic anchorage: a case report. *Int Endontic J* **2016**;49:402–9.
7. Cho UH, Yu W, Kyung HM. Root contact during drilling for microimplant placement. *Angle Orthod* **2010**;80(1):130–6.
8. Bae SM. The repair of the root and pulp tissue after intentional root injury by the orthodontic microimplant in dog [PhD thesis]. Daegu, Korea Kyungpook National University. **2005**.
9. Abraham ST, Paul MM. Micro implants for orthodontic anchorage: a review of complications and management. *J Dent Implant* **2013**;3:165–7.
10. Asscherickx K, Vannet BV, Wehrbein H, Sabzevar MM. Root repair after injury from mini-screw. *Clin Oral Implants Res* **2005**;16:575–8.
11. Chang C, Liu SS, Roberts WE. Primary failure rate for 1680 extra-alveolar mandibular buccal shelf mini-screws placed in movable mucosa or attached gingiva. *Angle Orthod* **2015**;85(6):905–10.

Kosiuk NM, Kondratiuk BR.

Tooth root injury and orthodontic microimplant fracture caused by its incorrect placement: case report.

J Diagn Treat Oral Maxillofac Pathol **2018**;2(1):57–59.

<http://dx.doi.org/10.23999/j.dcomp.2018.1.4>.