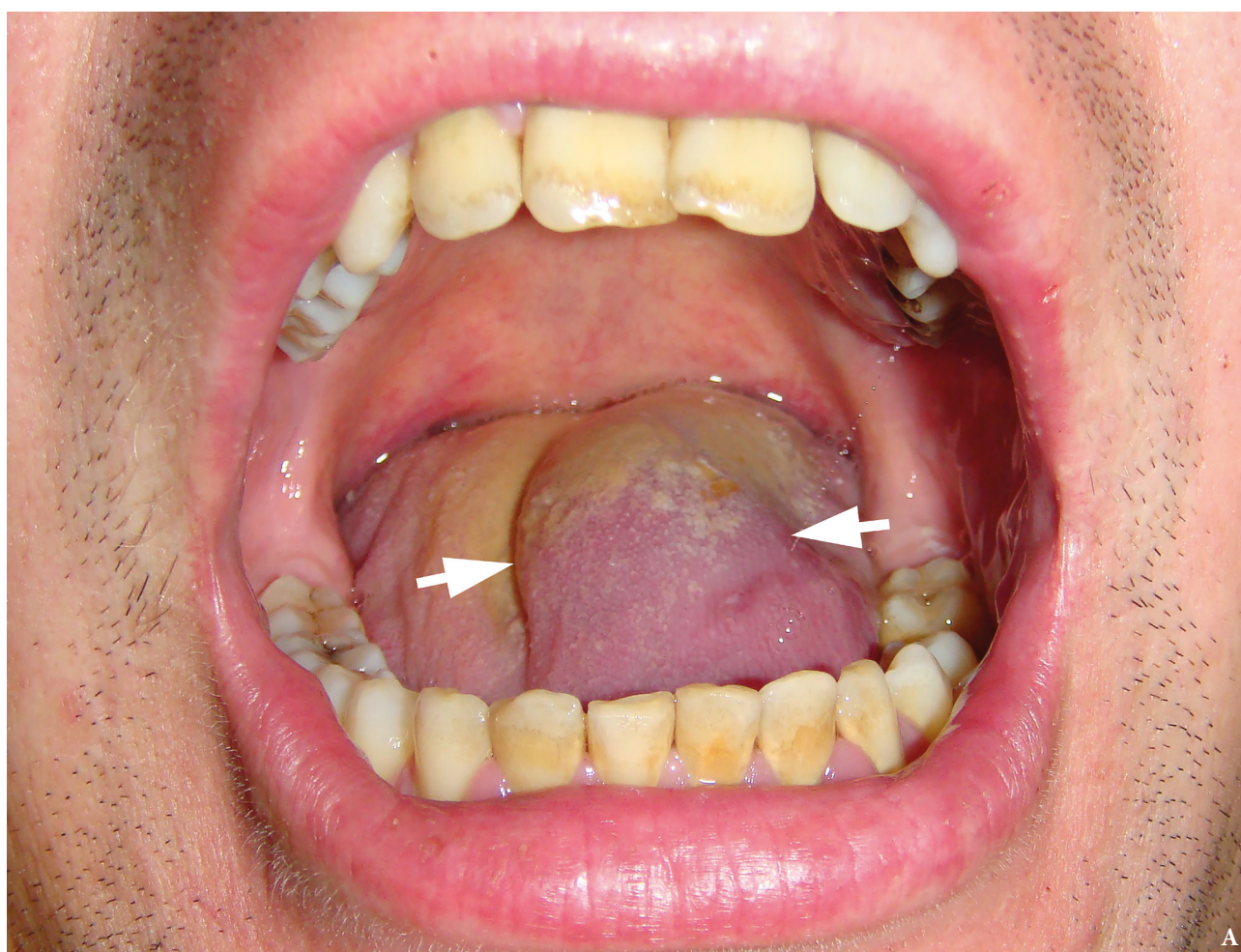




Section-Images in Oral & Maxillofacial Surgery
Camilo Mosquera, DDS, *Editor*

I Abscess of the Left Tongue

Ievgen I. Fesenko

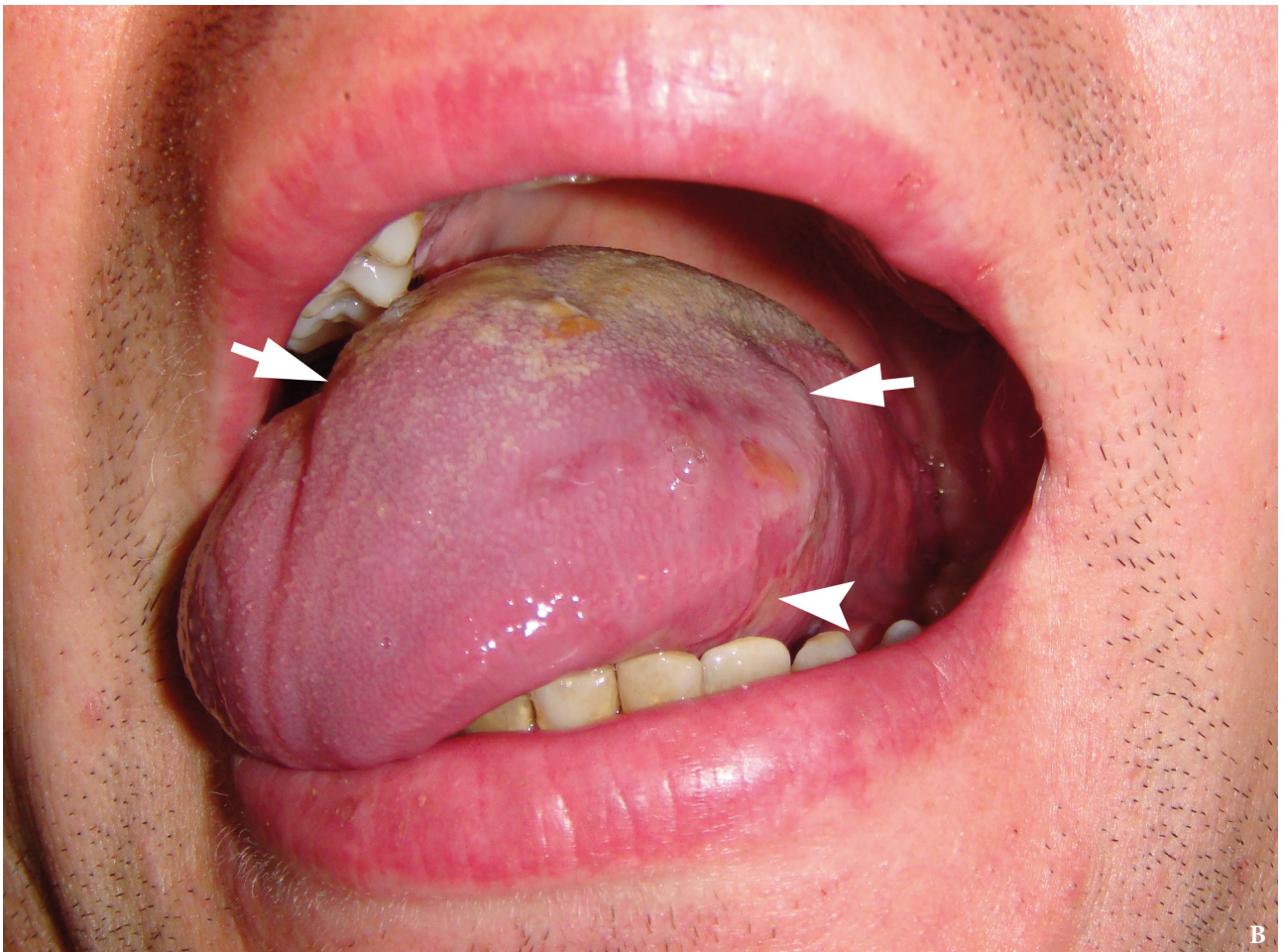


Oral Surgeon, PhD, Assistant Professor, Private Higher Educational Establishment "Kyiv Medical University," Center of Maxillofacial Surgery and Dentistry, Kyiv Regional Clinical Hospital (place of work at moment of material collection), Kyiv, Ukraine
i.i.fesenko@dtjournal.org

How to cite this article: Fesenko II. Abscess of the left tongue. *J Diagn Treat Oral Maxillofac Pathol* 2020;4(2):39-40.

Paper received 6 February 2020
Accepted 21 February 2020
Available online 28 February 2020

<https://dx.doi.org/10.23999/j.dtmp.2020.2.5>.
© 2020 OMF Publishing, LLC. This is an open access article under the CC BY license (<http://creativecommons.org/licenses/by-nc/4.0/>).



A 37-year-old Caucasian male was referred to the center of maxillofacial surgery with a painful swelling of the left tongue (Panel A, arrows: anterior tongue view), its painful movements, and fever during last several days. Patient told that 5 days before he traumatized the left surface of the tongue by a fish bone which he removed by himself. After that he did not seek any medical help, did not use rinsing with antiseptic solutions, and medications. Intraoral examination showed an extremely poor oral hygiene: dental calculi and plaque on the teeth, yellowish plaque on the tongue dorsum. Left part of the mobile tongue had a round shape, firm, and painful swelling (Panel B, arrows: left lateral tongue view). On its left lateral surface was also noticed a wound (Panel B, arrowhead) on a stage of healing with no draining pus. A diagnosis of a “fish bone-induced abscess of the left

tongue” (synonyms of tongue abscess: lingual abscess, glossal abscess) was established and the patient received surgery under local anesthesia. Abscess lancing was performed along the lateral border of the tongue by making 2.0-cm incision with blunt evacuation of 4.5 ml of purulent content and draining for 2 days by a rubber drain. 5-day antibiotic therapy, meticulous oral hygiene, and rinsing with antiseptic solution were prescribed. The patient immediately felt relief after surgery, and had no complaints after 5 days of treatment. Wound is healed by secondary intention. Tongue abscess is a rare condition which usually involves one of the anatomic parts of tongue parenchyma: left part, right part of the tongue or its base. Unlike the first two anatomic areas, lancing the abscess of the tongue base requires extraoral approach in submental area. ■ DTJournal