

DT Journal

2 2023

**Journal of Diagnostics and
Treatment of Oral and
Maxillofacial Pathology**



Editors
Oleksii Tymofieiev • Rui Fernandes
(Kyiv, Ukraine • Jacksonville, FL, USA)



Official Journal of the
Ukrainian Association for
Maxillofacial and Oral Surgeons

DTJournal.org

TANTUM VERDE®

QUICK RELIEF FROM PAIN
AND INFLAMMATION IN THE
MOUTH AND THROAT¹

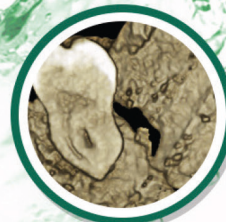
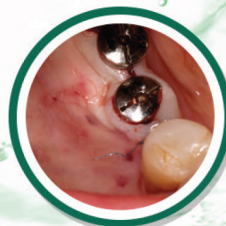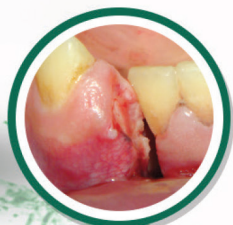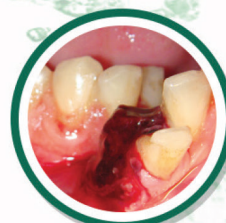**AN INTEGRAL COMPONENT OF THE TREATMENT
OF PAIN AND INFLAMMATION IN THE ORAL CAVITY
IN 60 COUNTRIES WORLDWIDE!²**



Reg. № UA/3920/01/01

**LOCAL ANESTHETIC
AND ANTI-INFLAMMATORY
EFFECT¹**

- **JAWS FRACTURES³**
- **IMPLANTS PLACEMENT⁴**
- **WOUNDS OF ORAL CAVITY⁵**



SUMMARY OF PRODUCT CHARACTERISTICS

NAME OF THE MEDICINAL PRODUCT. Tantum Verde 0.15% mouthwash. **QUALITATIVE AND QUANTITATIVE COMPOSITION.** Each 100 ml contains: active ingredient: benzydamine hydrochloride 0.15 g (equivalent to 0.134 g of benzydamine). **Therapeutic indications.** Treatment of symptoms such as irritation/inflammation including those associated with pain in the oropharyngeal cavity (e.g. gingivitis, stomatitis and pharyngitis), including those resulting from conservative or extractive dental therapy. **Posology and method of administration.** Pour 15 ml of Tantum Verde mouthwash into the measuring cup, 2-3 times per day, using it either at full concentration or diluted. If diluted, add 15 ml of water to the graduated cup. Do not exceed the recommended dosage. **Contraindications.** Hypersensitivity to benzydamine or to any of the excipient. **PHARMACOLOGICAL PROPERTIES. Pharmacodynamic properties.** Pharmacotherapeutic group: Stomatologic drugs: other agents for local oral treatment, ATC code: A01AD02. Clinical studies demonstrate that benzydamine is effective in relieving suffering from localised irritation of the mouth and pharynx. In addition, benzydamine possesses a moderate local anaesthetic effect. **Pharmacokinetic properties. Absorption.** Absorption through the oropharyngeal mucosa is demonstrated by the presence of measurable quantities of benzydamine in human plasma. These levels are insufficient to produce systemic effects. **Distribution.** When applied locally, benzydamine has been shown to accumulate in inflamed tissues where it reaches effective concentrations because of its capacity to penetrate the epithelial lining.

Information about medicines. Information for health care professionals for use in professional activities.

1. Інструкція для медичного застосування лікарського засобу Тантум Верде®, розчин для ротової порожнини, РПН № UA/3920/01/01, затверджено Наказом Міністерства охорони здоров'я України № 636 від 01.10.2015.

2. <http://www.angelini-pharma.com/wps/wcm/connect/com/home/Angelini+Pharma+in+the+world/>

3. Тимофеев А.А. и др. "Особенности гигиены полости рта для профилактики воспалительных осложнений при переломах нижней челюсти". Современная стоматология 2015;1(75):52-8.

4, 4.5. Tymofiejew O.O. et al "Prevention of inflammatory complications upon surgeries in maxillofacial region". J Diagn Treat Oral Maxillofac Pathol. 2017;1:105-12.

Clinical and CT images are courtesy of: Ievgen Fesenko (Department of Oral & Maxillofacial Surgery, PHEI "Kyiv Medical University", Kyiv, Ukraine), Oleg Mastakov ("SCIEDECE—Scientific Center of Dentistry & Ultrasound Surgery" Kyiv, Ukraine)



04119, Kiev, Melnikova str. 83D, of. 404.
Tel.: (044) 538-01-26
Fax: (044) 538-01-27



About the Journal: Aims and Scope

FEBRUARY 2023 • VOLUME 7 • ISSUE 2
www.djournal.org

Official Title

Journal of Diagnostics and Treatment of Oral and Maxillofacial Pathology

Standard Abbreviation: ISO 4

J. Diagn. Treat. Oral Maxillofac. Pathol.

Acronym

JDTOMP

International Standard Serial Number (ISSN)

Electronic ISSN 2522-1965

Aims & Scope

This is a monthly peer-reviewed oral and maxillofacial surgery journal focused on: microvascular and jaw reconstructive surgery, dental implants, salivary gland tumors/diseases, TMJ lesions, virtual surgical planning, implementation of ultrasonography into the practice of oral and maxillofacial surgeons.

Editorial Board (EB) Composition

- EB shows significant geographic diversity representing 30 opinion leaders from 13 countries: Brazil, Canada, Colombia, Greece, Hong Kong (SAR, China), India, Israel, Italy, Slovak Republic, Spain, Ukraine, United Arab Emirates, and United States.
- The majority of the EB Members have a discernible publication history in Scopus, Web of Science, and journals with a high impact factor.
- The publication records of all EB members are consistent with the stated scope and published content of the journal.
- The journal has a several full-time professional editors.
- Gender distribution of the editors: 10% women, 90% men, 0% non-binary/other, and 0% prefer not to disclose.

Frequency

12 issues a year (from January 2020)

Publication History

2017: 4 issues a year

2018: 4 issues a year

2019: 10 issues a year

From 2020: 12 issues a year

Publishing Model

Journal of Diagnostics and Treatment of Oral and Maxillofacial Pathology is a fully online-only open access and peer-reviewed publication.

Type of Peer Review

The journal employs “double blind” reviewing.

Article Publishing Charge (APC)

The APC in this journal is US \$500 and US \$250 (excluding taxes) depending on the article’s type. Details at website: dtjournal.org.

13 Types of Articles Currently Published by the Journal

Editorials/Guest Editorials/Post Scriptum Editorials, Images, Case Reports/Case Series, Original Articles, Review Articles, Discussions, Paper Scans (*synonyms*: Review of Articles, Literature Scan), Book Scans (*synonym*: Book Reviews), Letters to the Editor (*synonym*: Letters), and Viewpoints.

State Registration: Ministry of Justice of Ukraine

Registration: Jul 28, 2016 (Certificate: KB № 22251-12151 P)

Re-registration: May 21, 2019 (Certificate: KB № 23999-13839 IIP)

Re-registration: Aug 10, 2021 (Certificate: KB № 24951-14891 IIP)

Co-Founders

1. Shupyk National Healthcare University of Ukraine (formerly known as Shupyk National Medical Academy of Postgraduate Education).
2. Private Higher Educational Establishment “Kyiv Medical University.”
3. OMF Publishing, Limited Liability Company.

Publisher

OMF Publishing, LLC is an academic publisher focused on medical and linguistic sciences.

Address: 13-A Simferopolska Street, office 121, Kyiv 02096, Ukraine.

Crossref Membership

OMF Publishing, LLC is a member of Publishers International Linking Association, Inc. which doing business as a Crossref. OMF Publishing’s active membership: From February 2017 to present.

Official Journal of the Association

Ukrainian Association for Maxillofacial and Oral Surgeons

Ukrainian Association for Maxillofacial and Oral Surgeons (UAMOS)

Address: 4-A Profesora Pidvysotskoho Street, Kyiv 01103, Ukraine.

Tel., fax: +38 044 528 35 17.

Website: uamos.org.

© 2023 OMF PUBLISHING, LLC

Editorial Board

FEBRUARY 2023 • VOLUME 7 • ISSUE 2
www.djournal.org

Editor in Chief

Oleksii O. Tymofiev, ScD
Kyiv, Ukraine

Deputy Editor in Chief

Rui P. Fernandes, MD, DMD, FACS, FRCS(Ed)
Jacksonville, Florida, United States

Section Editors

Bone Augmentation Techniques

Nardy Casap, MD, DMD
Jerusalem, Israel

Business

Ivan V. Nagorniak, MSc, PhD
Kyiv, Ukraine

Craniofacial Deformities

Sunil Richardson, MDS
Nagercoil, Tamil Nadu, India

Facial Feminization Surgery

Kyle Keojampa, MD, FACS
Los Angeles, California, United States

Facial Plastic Surgery

Tirbod Fattahi, MD, DDS, FACS
Jacksonville, Florida, United States

Head & Neck Oncologic Surgery

Todd C. Hanna, MD, DDS, FACS
New York, New York, United States

Head & Neck Radiology

Anil T. Ahuja, MBBS, MD, FRCR, FHKCR, FHKAM
Hong Kong, SAR, China

Images

Camilo Mosquera, DDS
Bogotá, D.C., Colombia

Orthognathic Surgery

Mario Brinhole
São Paulo, São Paulo, Brazil

Robotic Surgery

Salam O. Salman, MD, DDS, FACS
Jacksonville, Florida, United States

TMJ Lesions/Disorders

Belmiro C. Vasconcelos, DDS, PhD
Recife, Pernambuco, Brazil

Editorial Board Members

Oleh M. Antonyshyn, MD, FRCS(C)
Toronto, Ontario, Canada

Anthony M. Bunnell, MD, DMD, FACS
Jacksonville, Florida, United States

Nur A. Hatab, DMD, PhD
Ras Al Khaimah, United Arab Emirates

Michael T. Kase, DMD
Birmingham, Alabama, United States

Andrey V. Kopchak, ScD
Kyiv, Ukraine

Olindo Massarelli, MD, PhD, FEBOMFS
Sassari, Italy

Anastasiya Quimby, DDS, MD
Fort Lauderdale, Florida, United States

Daniel Robles Cantero, DDS, MSc
Madrid, Spain

Peter Stanko, MD, PhD
Bratislava, Slovak Republic

Rostyslav M. Stupnytskyi, ScD
Kyiv, Ukraine

Olexander O. Tymofiev, ScD
Kyiv, Ukraine

Natalia O. Ushko, ScD
Kyiv, Ukraine

Andrew Yampolsky, DDS, MD
Philadelphia, Pennsylvania, United States

Web & Social Media Editor

João L. Monteiro, DDS
Boston, Massachusetts, United States

Director, Journal Development Department

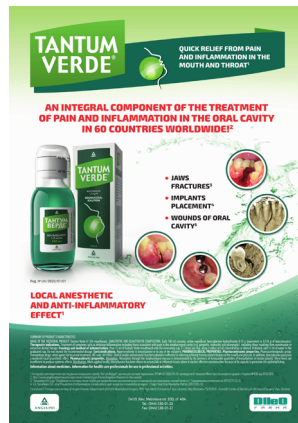Evangelos G. Kilipiris, DMD
Thessaloniki, Greece | Bratislava, Slovak Republic

Managing Editor

Ievgen I. Fesenko, PhD
Kyiv, Ukraine

Resident Ambassador

John M. Le, DDS, MD
Birmingham, Alabama, United States



TANTUM VERDE®

INFORMATION LEAFLET
for the medicinal product

Composition:

active substance: **benzydamine hydrochloride;**

100 mL of solution contain benzydamine hydrochloride 0.15 g;

excipients: ethanol 96%, glycerol, methyl parahydroxybenzoate (E 218), flavor (menthol), saccharin, sodium hydrocarbonate, Polysorbate 20, Quinoline Yellow (E 104), Patent Blue V (E 131), purified water.

Dosage form. Oromucosal solution.

Basic physical and chemical properties: a clear green liquid with a typical mint flavor.

Pharmacotherapeutic group. Dental preparations. Other agents for local oral treatment.

ATC code: A01A D02.

Pharmacological properties.

Pharmacodynamics.

Benzydamine is a non-steroidal anti-inflammatory drug (NSAID) with analgesic and antiexudative properties.

Clinical studies have shown that benzydamine is effective in the relief of symptoms accompanying localized irritation conditions of the oral cavity and pharynx. Moreover, benzydamine has anti-inflammatory and local analgesic properties, and also exerts a local anesthetic effect on the oral mucosa.

Pharmacokinetics.

Absorption through the oral and pharyngeal mucosa has been proven by the presence of measurable quantities of benzydamine in human plasma. However, they are insufficient to produce any systemic pharmacological effect. The excretion occurs mainly in urine, mostly as inactive metabolites or conjugated compounds.

When applied locally, benzydamine has been shown to cumulate in inflamed tissues in an effective concentration

due to its ability to permeate through the mucous membrane.

Clinical particulars.

Indications.

Symptomatic treatment of oropharyngeal irritation and inflammation; to relieve pain caused by gingivitis, stomatitis, pharyngitis; in dentistry after tooth extraction or as a preventive measure.

Contraindications.

Hypersensitivity to the active substance or to any other ingredients of the product.

Interaction with other medicinal products and other types of interaction.

No drug interaction studies have been performed.

Warnings and precautions.

If sensitivity develops with long-term use, the treatment should be discontinued and a doctor should be consulted to get appropriate treatment.

In some patients, buccal/pharyngeal ulceration may be caused by severe pathological processes. Therefore, the patients, whose symptoms worsen or do not improve within 3 days or who appear feverish or develop other symptoms, should seek advice of a physician or a dentist, as appropriate.

Benzydamine is not recommended for use in patients hypersensitive to acetylsalicylic acid or other non-steroidal anti-inflammatory drugs (NSAIDs).

The product can trigger bronchospasm in patients suffering from or with a history of asthma. Such patients should be warned of this.

For athletes: the use of medicinal products containing ethyl alcohol might result in positive antidoping tests considering the limits established by some sports federations.

Use during pregnancy or breast-feeding

No adequate data are currently available on the use of benzydamine in pregnant and breastfeeding women. Excretion of the product into breast milk has not been studied. The findings of animal studies are insufficient to make any conclusions about the effects of this product during pregnancy and lactation.

The potential risk for humans is unknown.

TANTUM VERDE should not be used during pregnancy or breast-feeding.

Effects on reaction time when driving or using machines

When used in recommended doses, the product does not produce any effect on the ability to drive and operate machinery.

Method of administration and doses.

Pour 15 mL of TANTUM VERDE solution from the bottle into the measuring cup and gargle with undiluted or diluted product (15 mL of the measured solution can be diluted with 15 mL of water). Gargle 2 or 3 times daily. Do not exceed the recommended dose.

Children.

The product should not be used in children under 12 years due to a possibility of ingestion of the solution when gargling.

Overdosage.

No overdose has been reported with benzydamine when used locally. However, it is known that benzydamine, when ingested in high doses (hundreds times higher than those possible with this dosage form), especially in children, can cause agitation, convulsions, tremor, nausea, increased sweating, ataxia, and vomiting. Such acute overdose requires immediate gastric lavage, treatment of fluid/salt imbalance, symptomatic treatment, and adequate hydration.

Adverse reactions.

Within each frequency group, the undesirable effects are presented in order of their decreasing seriousness.

Adverse reactions are classified according to their frequency: very common ($\geq 1/10$); common ($\geq 1/100$ to $<1/10$); uncommon ($\geq 1/1,000$ to $<1/100$); rare ($\geq 1/10,000$ to $<1/1,000$); very rare ($<1/10,000$); frequency unknown (cannot be estimated from the available data).

Gastrointestinal disorders: rare – burning mouth, dry mouth; *unknown* – oral hypesthesia, nausea, vomiting, tongue edema and discoloration, dysgeusia.

Immune system disorders: rare – hypersensitivity reaction, *unknown* – anaphylactic reaction.

Respiratory, thoracic and mediastinal disorders: very rare – laryngospasm; *unknown* – bronchospasm.

Skin and subcutaneous tissue disorders: uncommon – photosensitivity; very rare – angioedema; *unknown* – rash, pruritus, urticaria.

Nervous system disorders: *unknown* – dizziness, headache.

TANTUM VERDE contains methyl parahydroxybenzoate, which can cause allergic reactions (including delayed-type reactions).

Shelf life. 4 years.

Storage conditions.

Do not store above 25°C. Keep out of reach of children.

Packaging.

120 mL of solution in a bottle with a measuring cup; 1 bottle per cardboard box.

Dispensing category.

Over-the-counter medicinal product.

Manufacturer.

Aziende Chimiche Riunite Angelini Francesco A.C.R.A.F. S.p.A., Italy.

Location of the manufacturer and its business address. Via Vecchia del Pinocchio, 22 – 60100 Ancona (AN), Italy.

Date of the last revision of the text.

September 26, 2018.

Information leaflet is

APPROVED by

Order of the

Ministry of Health of Ukraine

No. 636 dated 01.10.2015

Registration Certificate

No. UA/3920/01/01

Our Supporters

FEBRUARY 2023 • VOLUME 7 • ISSUE 2
www.djournal.org



FIGURE. Evangelos G. Kilipiris, MD, DMD from the National Institute of Children's Diseases and Faculty of Medicine at Comenius University, Bratislava, Slovak Republic. A kind support of Dr. Kilipiris during the 5 years at the position of Director, Journal Development Department helped our journal to move forward and to evolve. An honorary plaque was presented to him on behalf of the Chief Editor with words "To a Founding Director, Author of Multiple Articles and Reviews, Great Thanks and Appreciation." Photo was taken on November 23, 2021.

Content

of the Volume 7 • Issue 2 • February 2023

A1 **Publisher & Editorial Office Information**

A2 **Editorial Board**


A5 **Our Supporters**

A6 **Content, Courtesy, & Erratum**

CASE

10 **A Rare Odontogenic Subperiosteal Abscess That Involved Entire Lateral Aspect of the Mandibular Body and Medial Aspect to the Level of Mylohyoid Ridge: Ultrasound Examination**

Olha S. Cherniak & Ievgen I. Fesenko

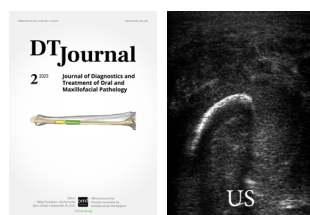

COURTESY

Journal's cover image (virtual surgical planning for a segmental mandibular reconstruction with fibula transplant) is courtesy of Rui P. Fernandes, MD, DMD, FACS, FRCS.

Image was taken from the article: Fernandes RP, Quimby A, Salman S. Comprehensive reconstruction of mandibular defects with free fibula flaps and endosseous implants. *J Diagn Treat Oral Maxillofac Pathol* 2017;1(1):6–10.

<https://doi.org/10.23999/j.dtomp.2017.1.1>



CASE

A Rare Odontogenic Subperiosteal Abscess That Involved Entire Lateral Aspect of the Mandibular Body and Medial Aspect to the Level of Mylohyoid Ridge: Ultrasound Examination

Olha S. Cherniak^a & Ievgen I. Fesenko^{b,*}

SUMMARY

Management of odontogenic subperiosteal abscess (SPA) is one of routine procedures at daily oral surgery and dental practice. Typically, SPA is manifested as a one-side-of-the-jaw collection of purulent material between bony surface and periosteum. In contrast to the data published in numerous literary sources, we present a case reported for the first time in the English-language literature. A 42-year-old male patient with odontogenic SPA that involved two surfaces (aspects) of the mandibular body—lateral and medial aspect to the level of mylohyoid ridge—and inferior margin of the mandible is highlighted. Also, this article is designed to educate oral and maxillofacial surgeons on ultrasonographic possibilities for diagnostics of perimandibular subperiosteal infection highlighting an extremely rare case in the field.

Kyiv, Ukraine

^a Doctor of Ultrasound Diagnostics (DUD); Head, Department of Ultrasound Diagnostics, Regional Diagnostic Center, Polyclinic, "Kyiv Regional Clinical Hospital" Public (Communal) Non-profit Enterprise of the Kyiv Region Council.
ORCID: <https://orcid.org/0000-0002-6372-0043>

^b Doctor-Stomatologist-Surgeon (DSS), Doctor of Ultrasound Diagnostics (DUD), PhD; Associate Professor, Department of Oral and Maxillofacial Surgery, Private Higher Educational Establishment "Kyiv Medical University"; "Kyiv Regional Clinical Hospital" Public (Communal) Non-profit Enterprise of the Kyiv Region Council (place of work at moment of material collection).
ORCID: <https://orcid.org/0000-0002-8901-1632>

* Corresponding author's address: Department of Oral and Maxillofacial Surgery on the basis of "Kyiv City Clinical Hospital #12" Public (Communal) Non-profit Enterprise, Private Higher Educational Establishment "Kyiv Medical University," 4A Profesora Pivdysotskoho Street, office 619, Kyiv 01103, Ukraine.
E-mail: eugenfesenko@gmail.com (Ievgen Fesenko)

Please cite this article as: Cherniak OS, Fesenko II. A rare odontogenic subperiosteal abscess that involved entire lateral aspect of the mandibular body and medial aspect to the level of mylohyoid ridge: ultrasound examination. *J Diagn Treat Oral Maxillofac Pathol* 2023;6(2):10–20.

Acronym 'US' at the upper right icon means that article contains ultrasound images.

Paper received 21 January 2023
Accepted 11 February 2023
Available online 28 February 2023

<https://doi.org/10.23999/j.dcomp.2023.2.1>

© 2023 OMF Publishing LLC. This is an open access article under the CC BY license (<https://creativecommons.org/licenses/by-nc/4.0/>).

INTRODUCTION

Subperiosteal abscess (SPA) is a collection of purulent material between periosteum and bone surface.¹ The odontogenic SPA is a common pathology at an oral surgeon's practice in out-patient clinics. In the East European countries, the term *acute purulent "periostitis"* is also applied for the description of SPA.² Despite the fact that the term *"periostitis"* is misnomer, it is generally accepted in some countries and is used to simplify the term of *subperiosteal abscess* and emphasize the localization of the inflammatory process in relation to the bone surface. And in the classifications of those countries the *acute purulent "periostitis"* (i.e., SPA) belongs to one of two forms of the acute *"periostitis"*—*serous* and *purulent*.² In the acute form, *"periostitis"* occurs in 94–95 percent of cases, and in the chronic form, in 5–6 percent.³ Literature sources reported that SPA is localized between periosteum and jawbone in a buccal, palatal, or lingual aspects of the jaw.⁴ Other sources detail and provide data that SPA is localized on one side of the jaw, often affecting it from the vestibular surface (in 93.4 percent of patients).³

That is why we present to your attention a unique case of an odontogenic SPA that involved two surfaces (aspects) of the mandible—lateral and medial aspect of the mandibular body to the level of mylohyoid ridge—and inferior margin of the mandibular bone. To our knowledge it is a first ever reported in the English literature case with detailed clinical, sonographic, intraoperative, and postoperative presentation.

CASE

A 42-year-old male patient presented to the Center of Maxillofacial Surgery and Dentistry in 2015 with painful, increasing swelling in the right face (Fig 1) initiated after a several days pain in lower right first molar. The patient noted a worsened general condition, weakness, headache, fever, and malaise. No comorbidities were reported by the patient.

Clinical examination revealed a swelling of soft tissues of the right cheek and submandibular area without cutaneous erythema. On palpation, a painful infiltrate was clearly noted along the periphery of the right mandibular body at lateral aspect, inferior margin, and at medial aspect. Intraorally, erythema of mucosa, painful swelling of the movable vestibular mucosa, and fluctuance were noted at the vestibular

aspect of the mandibular body along the teeth 4.7, 4.6, 4.5, and 4.4. No evidence of erythema or similar swelling at the lingual aspect was noted. Teeth 4.6 and 4.5 showed insignificant mobility. Such clinical data as classic for odontogenic SPA edema and manifestations from the vestibular side and at the same time the presence of a painful infiltrate in the right mandibular area did not fit into the generally accepted diagnosis of SPA. Simultaneous swelling and infiltrate at the submandibular area was atypical for the SPAs.

USG was performed on Philips ultrasound machine (model HD11 XE, Koninklijke Philips N.V., Eindhoven, The Netherlands) by experienced doctor of ultrasound diagnostics (O.S.C., her experience in head and neck ultrasound is 16 years) using a 12-3 MHz *linear probe* (also termed as *linear transducer*). USG of the perimandibular tissues revealed collection of significant amounts of pus between elevated periosteum and bony surface around the lateral and medial aspects of the right mandible body (Figs 2 and 3). The purulent material visualized as hypoechoic, heterogeneous area with internal debris and insignificant sign of fluid motion along the external and internal surfaces of the right mandibular body. Mandibular surfaces visualized as hyperechoic stripes with artifact of acoustic shadowing posteriorly. Collection of purulent material clearly visualized along the lateral (i.e., external) aspect the right mandibular body, inferior bony margin, and medial (i.e., internal) aspect. Worthy of attention is the fact that along the medial aspect of the mandible the pus reached the mylohyoid ridge, a place of attachment of the mylohyoid muscle. It can be said that medially the pus location was limited by subperiosteal space at the lower floor of mouth level.

Also, the extraoral examination revealed a presence of a soft, movable round-shape lesion at the left parotid area (Fig 1A). According to the patient's words, the lesion existed last several years growing slowly without painful feelings. Patient stated that a symmetrical neoplasm on the opposite side existed several years ago until its removal was done in another institution. USG of the left parotid region showed avascular well-circumscribed round-shaped lesion measured 3.96 × 1.86 cm. Lesion showed an extra-parotid location, posterior acoustic enhancement, presence of posterior wall enhancement, and heterogenic content. Its sonographic features were described in detail in our previous paper.⁵

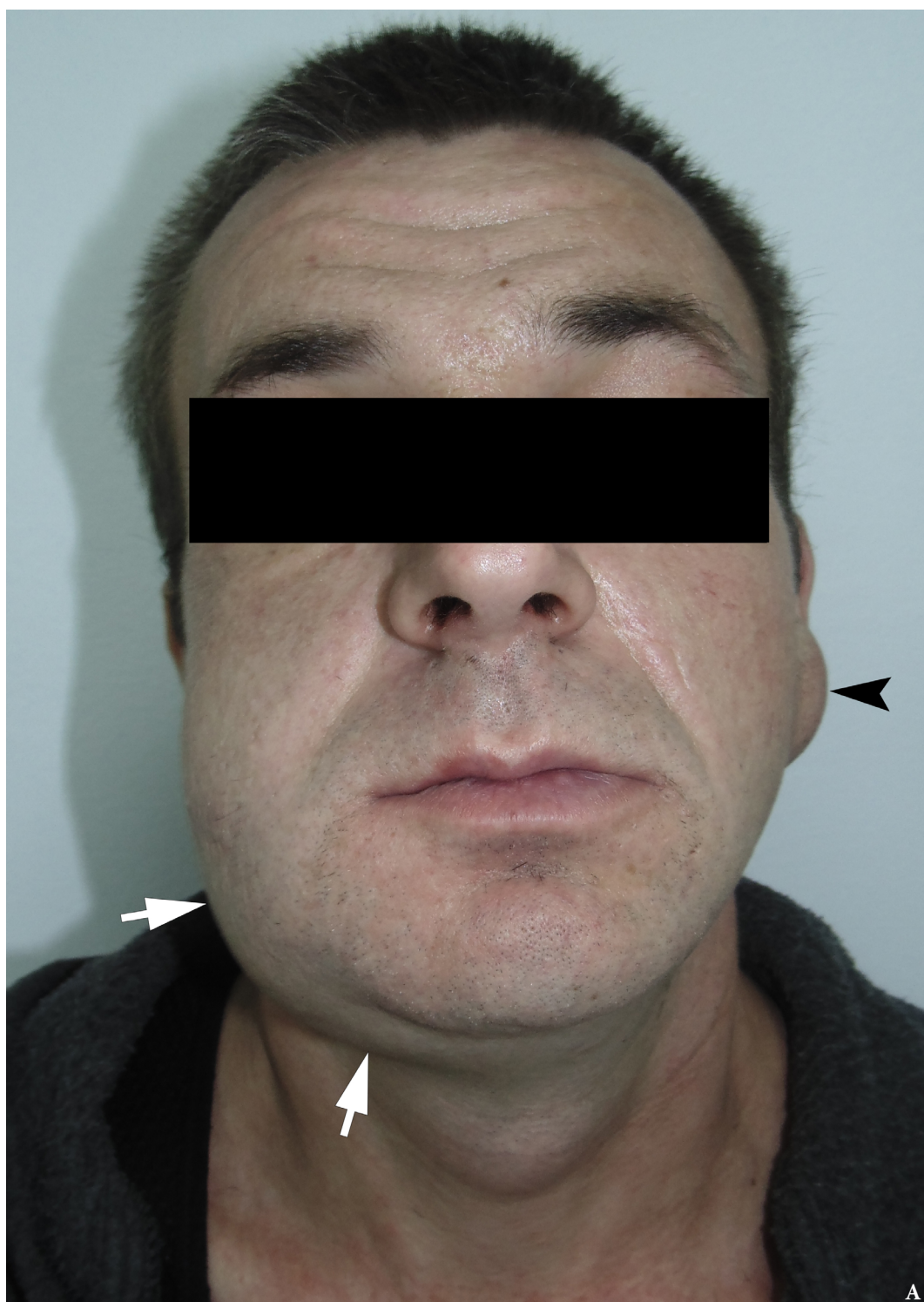


FIGURE 1. Anterior (A) and right oblique (B) photographs show significant swelling (*white arrows*) in the right cheek and submandibular regions. *Black arrowhead* labels acquired punctum-associated cyst⁵ of the left peri-parotid region. Printed with permission and copyrights retained by I.I.F. (**Figure 1 continued on next page.**)

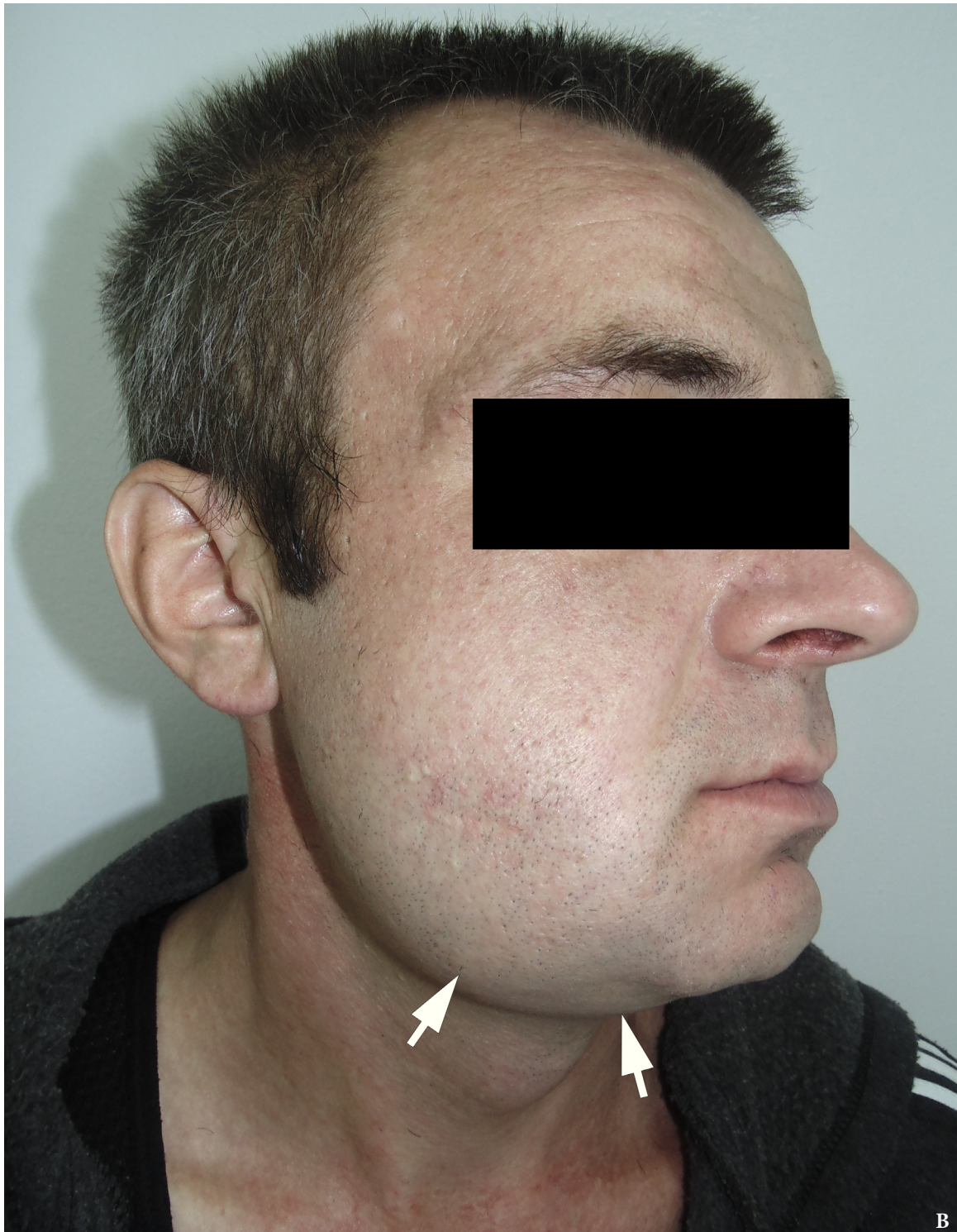

FIGURE 1 (continued). Anterior (A) and right oblique (B) photographs show significant swelling (*arrows*) in the right cheek and submandibular regions. Printed with permission and copyrights retained by I.I.F.

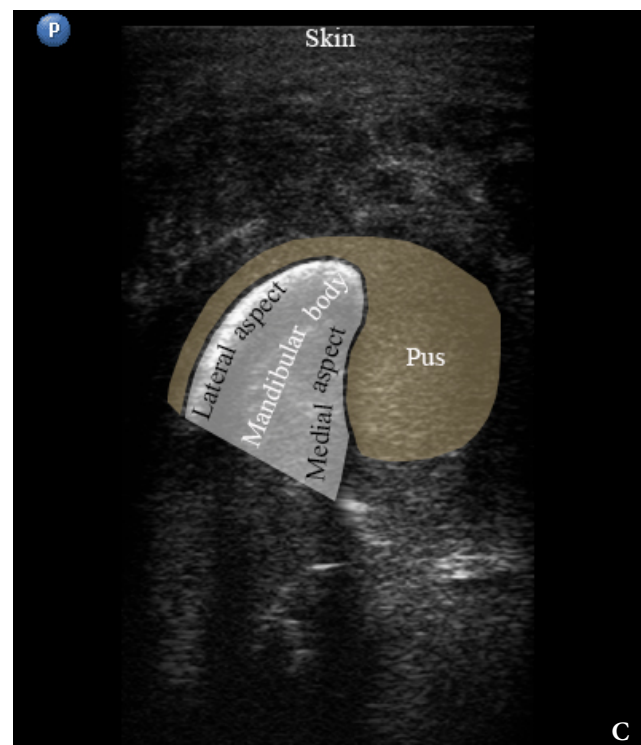
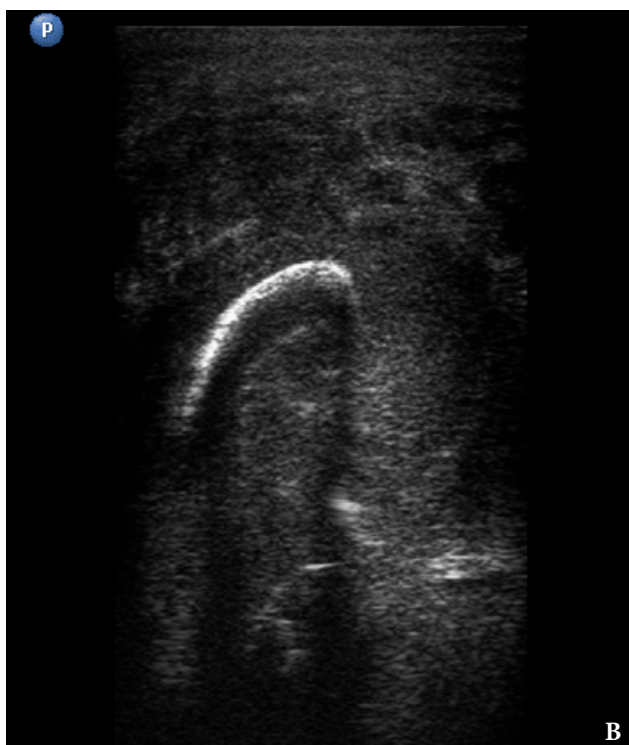
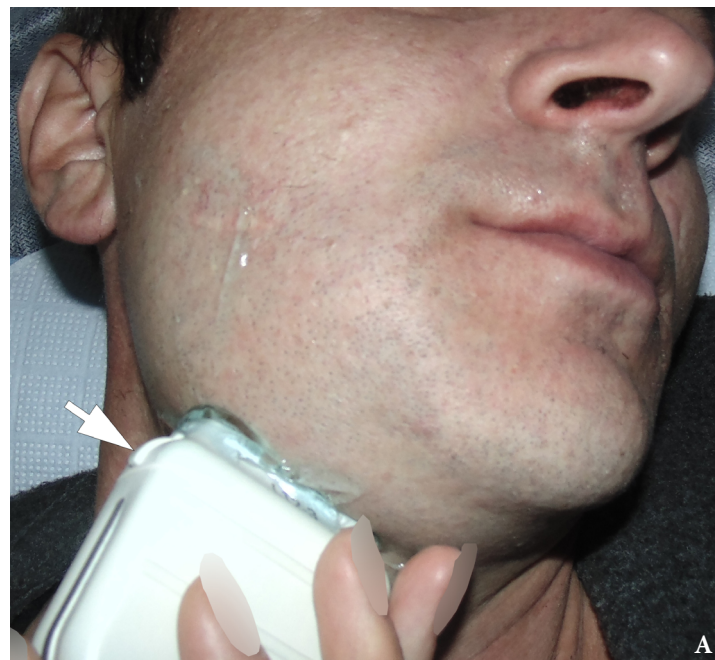
FIGURE 2. Transverse ultrasound scan of the right mandibular body (A). Arrow labels the probe's bump that corresponds to the letter "P" (i.e., position) at the upper left corner of the sonograms and indicates on the probe's side. B and C, Gray-scale sonograms. Noted collection of significant amounts of pus around the lateral and medial aspects of the mandible body. Prominent soft tissue oedema is also observed between skin and subperiosteal pus collection. The artifact of acoustic shadowing is noted posteriorly to the bony surface (hyperechoic curved stripe) of the mandible. The depth of ultrasonography is 6.0 cm. Printed with permission and copyrights retained by O.S.C. and I.I.F.

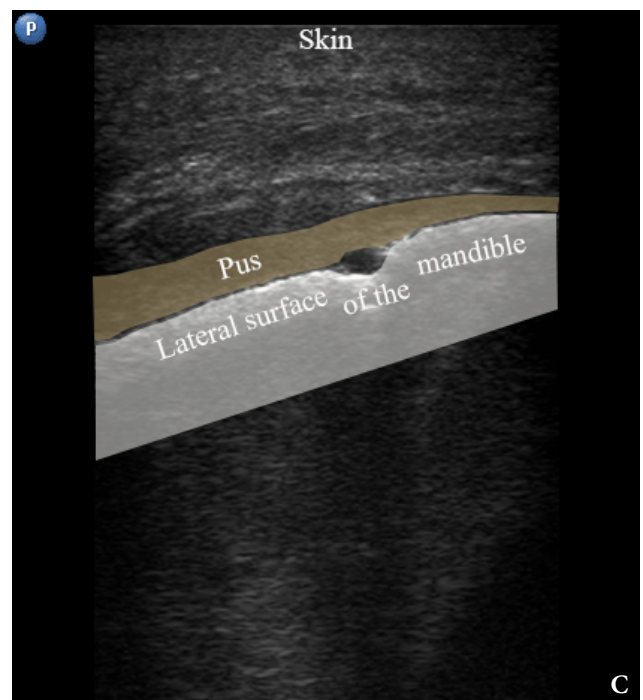
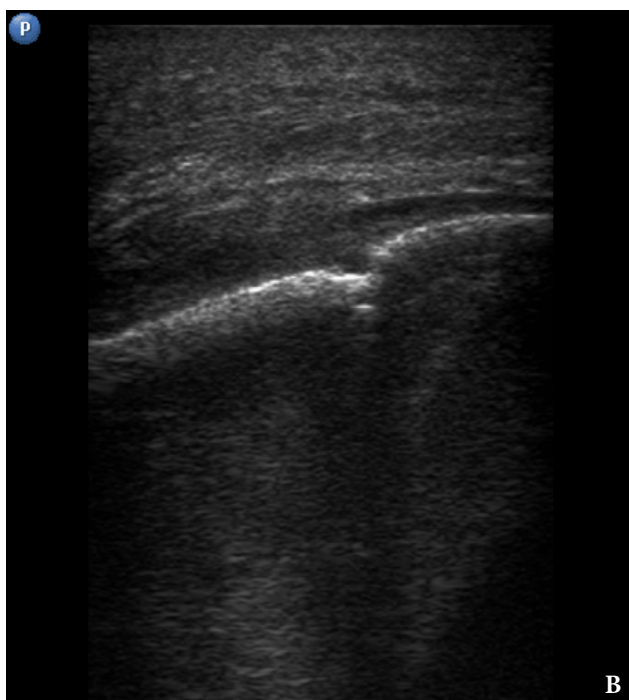
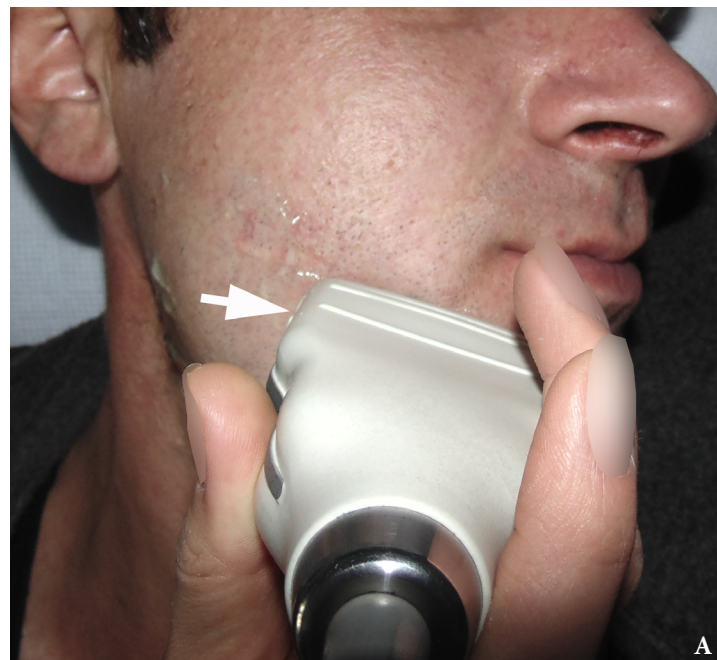FIGURE 3. Longitudinal ultrasound scan of the right mandibular body (**A**). *Arrow* labels the transducer's bump that corresponds to the letter "P" (i.e., position) at the upper left corner of the sonograms and indicates on the transducer's side. **B** and **C**, Gray-scale sonograms. Noted collection of significant amounts of pus along the lateral aspect (surface) of the mandible body. Prominent soft tissue oedema is also observed between skin and subperiosteal pus collection. The artifact of acoustic shadowing is noted posteriorly to the mandibular bone surface (hyperechoic stripe). The depth of ultrasonography presented at sonogram is 5.0 cm. Printed with permission and copyrights retained by O.S.C. and I.I.F.

The diagnosis of odontogenic SPA that covered lateral and medial aspect of the mandibular body to the level of mylohyoid ridge was established. Based on panoramic radiography, intraoral examination, and patient's words it was concluded that the causative tooth was the decayed lower right first molar. A concomitant diagnosis of acquired epidermal cyst of the left parotid area was also established.

Lancing of the SPA was done under the local potentiated anesthesia using 2.0 ml of Dexalgin® (Laboratorios Menarini SA, Barcelona, Spain) intramuscularly and 2.5 ml of Ultracaine® D-S forte (4% Articaine HCl injection with 1:100,000 epinephrine, Sanofi, Germany) intraorally.

The incision was made along the teeth 4.7, 4.6, and 4.5 with blade no. 11, cutting the movable mucosa and periosteum to the bone. Approximately 16.0 ml of purulent material was evacuated via the wound. Pus evacuation (Fig 4) was stimulated by extraoral palpation of infiltrate at inferior margin and inner surface of the mandibular body. No incision of the mucosa and periosteum at the lingual aspect of the mandible was made. After that, a double perforated tubular drainage was used, self-made from a dropper system. It was inserted into the wound and installed

slightly below the inferior margin of the mandible due to the presence of space between elevated periosteum and bony surface. Washing of the subperiosteal cavity through drainage was carried out upon the surgery and for 3 days with hospital solutions of the Furacilin and 0.02% Chlorhexidine. Then the drain was removed. Rinsing the mouth with an antiseptic solution has also been prescribed immediately after surgery. Suction of the wound was not performed. The patient refused to treat the tooth and insisted on its removal what was done at the day of SPA surgery. Postoperative recovery was smooth and uneventful. The edema decreased gradually over the next 6 days (Fig 5). A small amount of purulent content during antiseptic washing noted 3 days. No antibiotic therapy was prescribed due to good evacuation of the pus and fact that was purulent process limited by subperiosteal space only.

Removal of the cystic lesion in the left parotid area (Fig 6) was performed a week after the treatment of the SPA. The histopathological diagnosis confirmed the clinical and intraoperative diagnosis—acquired epidermal cyst (also known as *punctum-associated cyst* or formerly known as *sebaceous gland cyst* and *atheroma*).^{5,6}

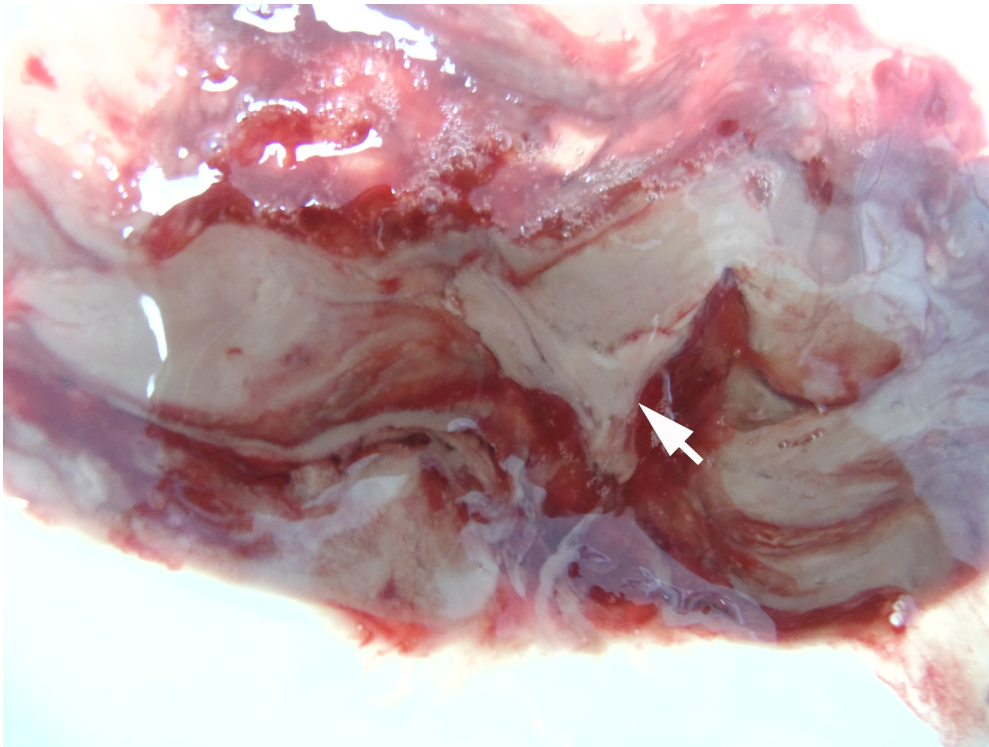


FIGURE 4. A reusable metal kidney shaped tray filled with purulent content (*arrow*) evacuated during the subperiosteal abscess lancing and drainage. Printed with permission and copyrights retained by I.I.F.

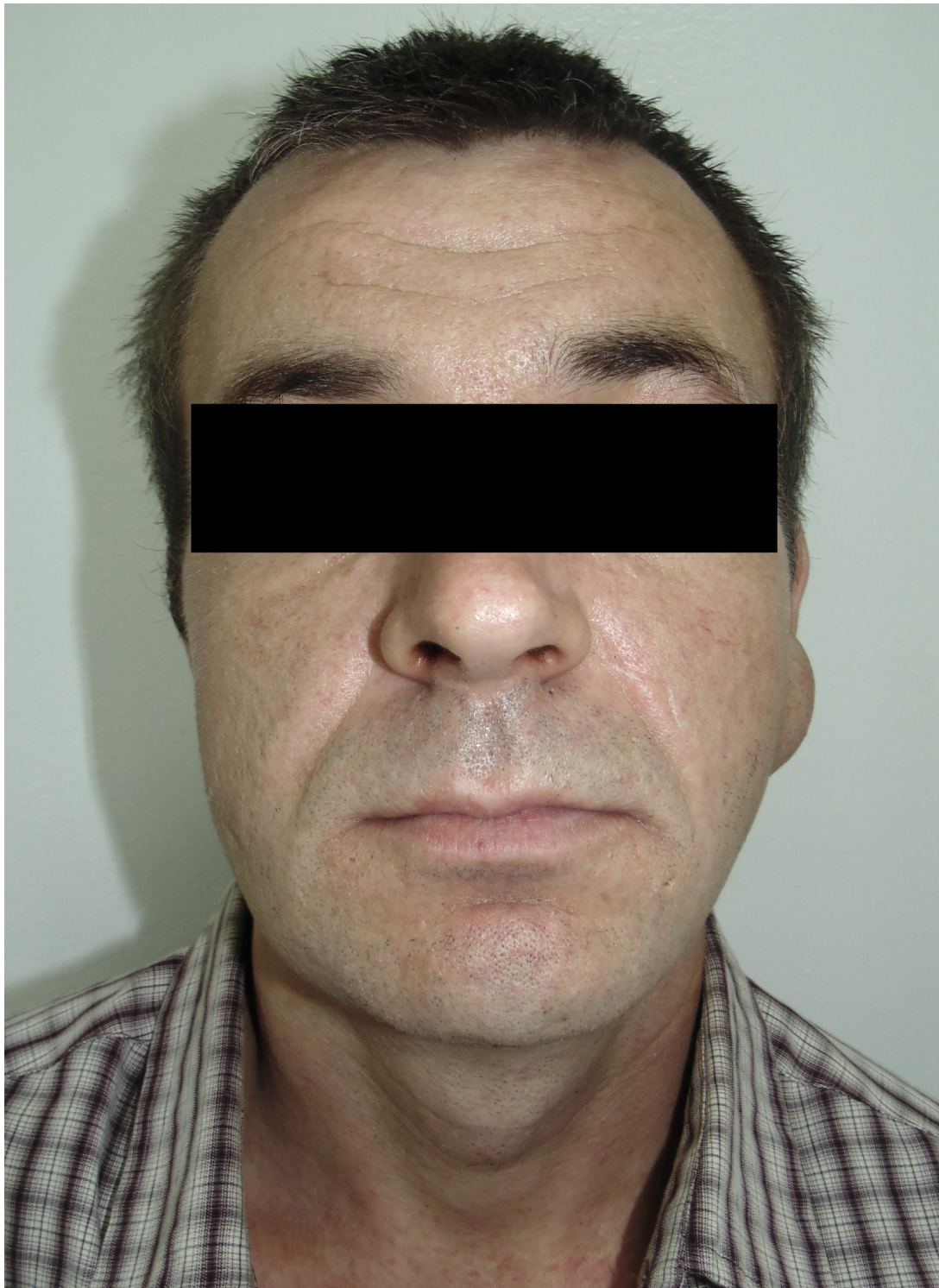

FIGURE 5. Anterior photograph on day 6 after the initiated treatment show absence of significant swelling in the right cheek and submandibular areas. The symmetry of the face in its lower third is returning. Printed with permission and copyrights retained by I.I.F.

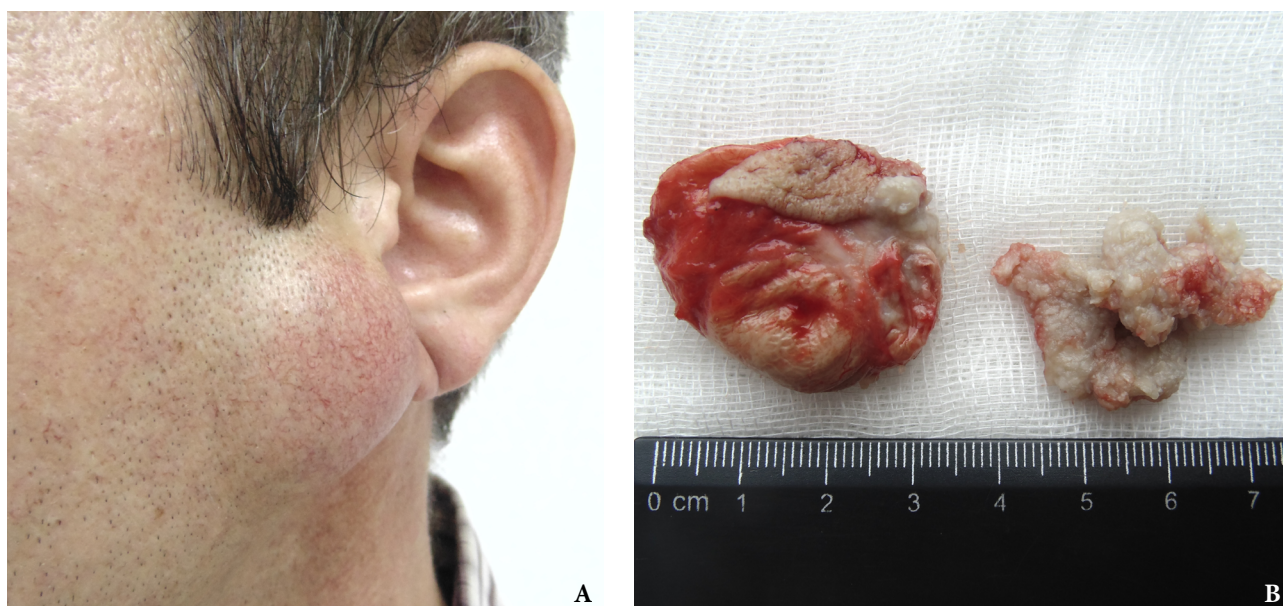

FIGURE 6. A, Oblique view before the removal of cystic lesion in the left parotid area. **B**, Specimen of the cyst after the removal. Noted the typical punctum-associated cyst appearance.⁶ The histopathological diagnosis confirmed previous clinical diagnosis—acquired epidermal cyst.⁵ Printed with permission and copyrights retained by I.I.F.

DISCUSSION

The diagnosis of SPA can be established in different anatomical locations.⁷⁻¹⁰ In case of odontogenic etiology of SPA the purulent content can be localized even in orbit.^{8,9} But the most common location of the odontogenic SPAs is a surface of the jaws.²⁻⁴ Literature reported that odontogenic SPA is typically involving one aspect (surface) of the jaw—vestibular or lingual/palatal.^{2-4,10}

According to the data presented in 2012, in acute “periostitis” (serous or purulent [i.e., SPA]), the inflammatory process develops at vestibular aspect in 93.4 percent of patients.³ “Periostitis” proceeds in an acute serous form in 41.7 percent, in an acute purulent form in 58.3% percent.³ With purulent form of acute odontogenic “periostitis” (i.e., SPA), detachment of the periosteum over one tooth is noted in 20 percent of patients, over 2 teeth – in 56 percent, and over 3-4 teeth – in 24 percent.³

The case presented in this article is unique for the following reasons: (1) the fact that pus collected around the body of the mandible on both sides (lateral and medial aspects), seizing the inferior margin of the jaw, (2) successful application of the minimally invasive technique of one surgical approach and tubular double drainage to drain the

abscess covered both body aspects, which is not typical for subperiosteal purulent processes, but such that allowed to effectively drain the wound and avoid additional incisions, and (3) according to recommendations³ the antibiotic therapy was not prescribed and the medication treatment was provided by the non-steroidal anti-inflammatory drug only. Literature emphasized that antibiotic therapy in odontogenic SPA cases is prescribed only for debilitated individuals or with concomitant diseases.³ This thesis was proved by the treatment of SPA in our case. Despite the fact that the process spread to two surfaces of mandibular body and a significant volume of purulent content, the use of correct surgical tactics and drug therapy, which included non-steroidal anti-inflammatory drugs and no antibiotics, managed to treat the patient successfully.

Location of the purulent material in the pus-created subperiosteal space was proved by high-resolution USG. Popularity of implementation of the USG into surgical practice continues to grow¹¹⁻¹⁵ proving its role as a first-line imaging for head and neck pathology. A gray-scale USG in our case also proved its efficacy allowing us to make precise diagnosis which allowed to apply minimally invasive treatment and good outcome. It is important to

emphasize that correct interpretation of USG in the floor of mouth and perimandibular areas is possible with good knowledge of anatomical structures and its interpretation on sonograms.^{16–19}

In the 13 years of the surgeon's practice (I.I.F), this is the first case of subperiosteal spread of purulent material on 3 surfaces from an odontogenic focus on the lower jaw. English literature search does not reveal the similar cases as well as its ultrasound descriptions.

Accompanying pathology in the parotid region is well described in relevant sources, both from the point of view of ultrasound diagnostics^{5,20} and surgical aspects^{2,3,6}.

CONCLUSIONS

Diagnostic ultrasound proved its efficacy as a non-radiation imaging tool even for the rare odontogenic subperiosteal abscess cases which are involving lateral and medial aspects of the mandibular body. Application of ultrasonography allows precise diagnostic, treatment planning and surgical performance. Moreover, the high level imaging and surgical control of the purulent process allow to avoid antibiotics loading on patient's body.

TERM OF CONSENT

Writing patient's consent was obtained for publication the photos.

AUTHOR CONTRIBUTIONS

Conceptualization: Fesenko II, Cherniak OS. Ultrasonographic data acquisition: Cherniak OS. Surgical images acquisition: Fesenko II. Data analysis or interpretation: Cherniak OS, Fesenko II. Drafting of the manuscript: Fesenko II. Critical revision of the manuscript: Both authors. Approval of the final version of the manuscript: Both authors.

CONFLICT OF INTERESTS

The authors declare no conflict of interest.

FUNDINGS

No funding was received for this study

REFERENCES (20)

- Chandra RK, Kennedy DW. Sinus infection. In: Miloro M, Ghali GE, Larsen PE, Waite PD, editors. *Peterson's Principles of Oral and Maxillofacial Surgery*. Hamilton: BC Decker Inc; **2004**. p. 295–312.
- Tymofieiev OO. *Maxillofacial surgery*. Kyiv: VSV "Medicine"; **2011**. (in Ukrainian)
- Tymofieiev OO. *Manual of maxillofacial and oral surgery*. Kyiv: Chervona Ruta-Turs LLC; **2012**. (in Russian)
- Fragiskos FD. Odontogenic infections. In: Fragiskos FD, editor. *Oral surgery*. Berlin Heidelberg: Springer-Verlag; **2007**. p. 205–41.
- Tymofieiev OO, Ushko NO, Fesenko II, Cherniak OS. Maxillofacial surgery specialization in Ukraine: a new order and step in the growth of the specialty: analysis of qualification categories. *J Diagn Treat Oral Maxillofac Pathol* **2021**;5(4):43–51. <https://doi.org/10.23999/j.dtomp.2021.4.3>
- Fesenko II, Snisarevskiy PP, Zaritska VI. Infected punctum-associated cyst mimicking erysipelas. *J Diagn Treat Oral Maxillofac Pathol* **2021**;5(2):15–9. <https://doi.org/10.23999/j.dtomp.2021.2.1>
- Silva ACV, Lins CM, Mendes RFA, et al. Case report: Pott's edematous tumor: complicated frontal sinusitis - an unremembered diagnosis. *Front Surg* **2022**;9:889463. <https://doi.org/10.3389/fsurg.2022.889463>
- Muñoz-Guerra MF, González-García R, Capote AL, et al. Subperiosteal abscess of the orbit: an unusual complication of the third molar surgery. *Oral Surg Oral Med Oral Pathol Oral Radiol Endod* **2006**;102(5):e9–e13. <https://doi.org/10.1016/j.tripleo.2006.03.009>
- Geusens J, Dubron K, Meeus J, Spaey Y, Politis C. Subperiosteal orbital abscess from odontogenic origin: a case report. *Int J Surg Case Rep* **2020**;73:263–7. <https://doi.org/10.1016/j.ijscr.2020.07.014>
- Foskolos PG, Hadjipetrou S, Mylanos AI, Kolomvos N. Subperiosteal abscess: a postoperative complication after surgical extraction of impacted third molars. Report of a case. *Hellenic Archives Oral Maxillofac Surg* **2020**;2:77–83.
- Mallorie CN, Jones SD, Drage NA, Shepherd J. The reliability of high resolution ultrasound in the identification of pus collections in head and neck swellings. *Int J Oral Maxillofac Surg* **2012**;41(2):252–5. <https://doi.org/10.1016/j.ijom.2011.10.012>
- Mukhi PU, Mahindra UR. The use of ultrasonography in diagnosis and management of superficial fascial space infections. *Indian J Dent Res* **2012**;23(3):313–9. <https://doi.org/10.4103/0970-9290.102211>

13. Cherniak OS, Ripolovska OV, Nozhenko OA, Fesenko II. Accuracy of ultrasound in diagnostics of odontogenic infection in layers of temporal and parotid masseter region. *J Diagn Treat Oral Maxillofac Pathol* **2019**;3(9):214–29.
<https://doi.org/10.23999/j.dtopm.2019.9.2>
14. Torres-Gaya J, Boscà-Ramón A, Marqués-Mateo M, et al. Temporomandibular joint arthrocentesis guided by ultrasonography: an anatomical study. *J Stomatol Oral Maxillofac Surg* **2021**;122(4):e27–e31.
<https://doi.org/10.1016/j.jormas.2021.03.002>
15. Tymofiev OO, Ushko NO, Fesenko II, et al. Suppurative mastoid lymphadenitis mimicking mastoiditis: a case report. *J Korean Assoc Oral Maxillofac Surg* **2021**;47(5):398–402.
<https://doi.org/10.5125/jkaoms.2021.47.5.398>
16. Madhok S, Kiruthika S, Prabhu K, et al. Mylohyoid ridge as a predictor of available bone for implant placement: a cone-beam computed tomography (CBCT) retrospective observational study. *Cureus* **2022**;14(7):e27470.
<https://doi.org/10.7759/cureus.27470>
17. Kim SD, Loukas M. Anatomy and variations of digastric muscle. *Anat Cell Biol* **2019**;52(1):1–11.
<https://doi.org/10.5115%2Facb.2019.52.1.1>
18. La'porte SJ, Juttla JK, Lingam RK. Imaging the floor of the mouth and the sublingual space. *Radiographics* **2011**;31(5):1215–30.
<https://doi.org/10.1148/rg.315105062>
19. Bell FE 3rd, Neuffer FH, Haddad TR, et al. Active learning of the floor of mouth anatomy with ultrasound. *Anat Sci Educ* **2019**;12(3):310–6.
<https://doi.org/10.1002/ase.1839>
20. Lee DH, Yoon CS, Lim BJ, et al. Ultrasound feature-based diagnostic model focusing on the “submarine sign” for epidermal cysts among superficial soft tissue lesions. *Korean J Radiol* **2019**;20(10):1409–21.
<https://doi.org/10.3348/kjr.2019.0241>

U-Impl[®]

SWITZERLAND



№ R3M 804 252 B2

Сертифікат відповідності
технічного регламенту
щодо медичних виробів



Switzerland Aarbergerstrasse 107A, CH-2502
Biel, Phone/Fax +41 323230188
info@u-impl.com
www.u-impl.com