



## ORIGINAL RESEARCH

# Potentiometric Examination of Patients with Chronic Odontogenic Maxillary Sinusitis in the Presence of Galvanic Pathology

Oleksii O. Tymofieiev<sup>a,\*</sup> & Andrii M. Cherednichenko<sup>b</sup>

## ABSTRACT

**Purpose:** To determine the values of potentiometric parameters in the oral cavity present between metal inclusions, as well as between metal inclusions and the mucous membrane of the alveolar process in patients with chronic odontogenic maxillary sinusitis with galvanic pathology.

**Methods:** 56 patients with chronic odontogenic maxillary sinusitis were divided into two observation groups, which were subjected to potentiometric and general clinical examination methods.

**Results:** In 30 patients with chronic odontogenic maxillary sinusitis with the presence of galvanism (compensated and decompensated forms) in the oral cavity, chronic inflammation in the maxillary sinus occurred without pronounced clinical symptoms, and in 26 patients with oral galvanosis (atypical and typical forms), the clinical symptoms of inflammation in the maxillary sinus were severe with an aggressive course and complications.

**Conclusions:** Based on an examination of 56 patients with chronic odontogenic maxillary sinusitis in the presence of galvanic pathology in the oral cavity, we found that in some types of this pathology, i.e., galvanosis, inflammatory disease in the maxillary sinus is aggressive, with pronounced clinical symptoms, frequent exacerbations of the inflammatory process, the presence of many postoperative inflammatory complications and recurrence of the disease.

**Keywords:** chronic odontogenic maxillary sinusitis, maxillary sinus, galvanic pathology, potentiometry, galvanism, galvanosis, metal inclusions.

<sup>a</sup> Doctor of Medical Sciences, Professor, Honored Science and Technology Figure of Ukraine, Head of the Maxillofacial Surgery Department, Shupyk National Healthcare University of Ukraine, Kyiv, Ukraine.

<sup>b</sup> PhD Researcher, Maxillofacial Surgery Department, Shupyk National Healthcare University of Ukraine, Kyiv, Ukraine.

\* **Correspondence:** Department of Maxillofacial Surgery of Shupyk National Healthcare University of Ukraine based on Kyiv City Clinical Hospital No. 12 Communal Non-profit Enterprise, 4A Profesora Pdivysotskoho Street, Kyiv 01103, Ukraine.  
E-mail: [tymofeev@gmail.com](mailto:tymofeev@gmail.com) (Oleksii Tymofieiev)  
ORCID: <https://orcid.org/0000-0002-3191-6025>

**Support:** no grants received.

**Author Contribution:** The authors confirm their contribution to the paper as follows: study conception, design, and approval of the final version of the manuscript: both authors.

**Conflict of Interests:** The author has no conflicts of interest to disclose.

**Study design:** Original research.

**Please cite this article as:** Tymofieiev OO, Cherednichenko AM. Potentiometric examination of patients with chronic odontogenic maxillary sinusitis in the presence of galvanic pathology. J Diagn Treat Oral Maxillofac Pathol 2023;7(10):120–131.

Paper received 17 October 2023

Accepted 28 October 2023

Available online 31 October 2023

<https://doi.org/10.23999/j.dtomp.2023.10.2>

© 2023 OMF Publishing LLC. This is an open access article under the CC BY license (<https://creativecommons.org/licenses/by-nc/4.0/>).

## INTRODUCTION

Replacing defects of individual teeth and tooth rows in prosthetic dentistry, non-precious metal groups and their alloys are widely used. For manufacturing fixed dental prostheses, alloys based on base of base metals are most often used: stainless steel, cobalt-chromium alloy, nickel-chromium, and cobalt chromium molybdenum alloys and others. For the adult population of Ukraine, the need for this type of dental prosthetics is more than 50%.<sup>1-7</sup> Being in the human oral cavity, dissimilar metals in contact with saliva, give positively charged ions in the solution (oral fluid). Consequently, an electric charge appears on the metal denture surrounded by saliva, and a galvanic potential difference occurs between dissimilar metals, i.e. a galvanic element is formed in the oral cavity.

It is known that in the presence of fixed metal inclusions in the mouth different types of pathological effects on the human body are observed: galvanic, toxic-chemical, allergic, etc. As a result of corrosion of metals in the mouth the bridges of dental prostheses lose their basic properties; there appear metal oxides in the oral cavity that adversely affect the mucous membrane and the patient's body. It is proved that all dissimilar metals and alloys cause galvanic currents in the oral cavity.<sup>1,2</sup> And galvanic currents arising in the oral cavity cause the appearance of so-called galvanic pathology, namely galvanism and/or galvanosis. Galvanic pathology leads to the development of local and general complications in the body, which affects the clinical course of many human diseases.<sup>1-5</sup>

The aim of this study is to determine the values of potentiometric parameters in the oral cavity (potential difference, current strength and electrical conductivity of oral fluid), which exist between metal inclusions, as well as between metal inclusions and the mucosa of the alveolar process in patients with chronic odontogenic maxillary sinusitis<sup>8-13</sup> and to determine the degree of their influence on the severity of the clinical course of the inflammatory process in the maxillary sinus and postoperative outcome.

## MATERIAL AND METHODS

We examined 56 patients with chronic odontogenic maxillary sinusitis who had fixed metal dentures in the oral cavity. All fixed prostheses were

fixed on teeth (without dental implants). The subjects we categorized as having metal inclusions were those with amalgam fillings, metal crowns, cantilever, and bridge dentures. The fixed dentures in these subjects were made of stainless steel, chromium-cobalt, chromium-nickel and other metal alloys, as well as titanium nitride metal protective coating (MPC).

The control group consisted of 27 practically healthy people (without comorbidities) of the same age, but without metal inclusions in the oral cavity (amalgam fillings and metal fixed dentures) with obligatory sanitized oral cavity.

Depending on the galvanic pathology detected in the patient's oral cavity, all 56 subjects with chronic odontogenic maxillary sinusitis were divided into two observational groups. The first group consisted of 30 patients with galvanic pathology in the oral cavity in the form of galvanism (compensated and decompensated form).

The compensated form of galvanism was diagnosed in 4 out of 30 patients, i.e. in 13.3% of the subjects, and the decompensated form – in 26 patients (86.7%). The second group consisted of 26 patients with chronic odontogenic maxillary sinusitis in whom galvanosis (atypical and typical forms) was detected in the oral cavity. Atypical form of galvanosis has a synonym: hidden form. Galvanosis in the second observation group occurred in the atypical form in 14 patients (53.8%) and in the typical form in 12 subjects (46.2%).

All patients underwent general clinical examination, which included examination, palpation, percussion of teeth, radiography, general blood analysis and other methods. To determine the pH of oral fluid we used a standard pH-meter. For the potentiometric method of examination, we used an automatic digital potentiometer (Pitterling Electronic GmbH  $\mu$ g-potential, München, Germany). The device automatically determines the potential difference in the range from 0 to 999 mV, current strength in the range from 0 to 99  $\mu$ A and electrical conductivity of oral fluid in the oral cavity in microsiemens ( $\mu$ Sm). All potentiometric parameters were measured in the following areas (points) of the oral cavity: between metal inclusions (M-M), as well as between metal inclusions and the mucous membrane of the alveolar processes of the jaws.

Potentiometric indices in each subject were measured twice (during their hospitalization and after surgical intervention). Repeated measurement

of potentiometric indices was justified by the fact that when galvanic pathology was detected in a patient with chronic maxillary sinusitis, it was necessary to remove metal inclusions that were the cause of the development of this pathology.

All numerical data obtained during the survey were processed by mathematical method with calculation of Student's criterion. The indicators were considered reliable at  $p < 0.05$ .

## RESULTS AND DISCUSSION

We analyzed clinical and potentiometric data in the subjects of the first observation group – 30 patients with chronic odontogenic maxillary sinusitis with the presence of galvanism (compensated and decompensated forms) in the oral cavity. In the subjects of this study group the number of metal inclusions in the oral cavity ranged from 3 to 10 orthopedic units.

Let us analyze the clinical symptoms of chronic odontogenic maxillary sinusitis<sup>8-13</sup> in the subjects of the first observation group. The patients had the following complaints: unilateral headaches were detected in 12 patients (in 40.0% of cases), nasal congestion on the side of maxillary sinusitis – in 18 patients (in 60.0%), nasal breathing disorders – in 18 patients (in 60.0%), decreased sense of smell – in 22 patients (in 73.3%), decreased sense of smell – in 22 people (73.3%), in the history of periodic (2 or more times) appearance of facial swelling, i.e. presence of exacerbations of chronic inflammatory process in the maxillary sinus – in 1 person (3.3%). When patients were hospitalized, swelling in the suborbital and cheek areas was present in 4 people (13.3%), and discharge of stinky mucus from the corresponding half of the nose – in 21 people (70.0%).

During visual examination of the patients, 8 patients (26.7% of cases) had facial asymmetry in the suborbital and cheek areas on the affected side. Skin hyperemia was absent in all subjects, the skin was collected in a fold and opening of the mouth was not difficult. Of the 30 subjects, the causative teeth had been extracted in 10 (33.3%) before their hospitalization. In 9 out of 10 (90.0%) of them, an oro-antral communication with the maxillary sinus appeared after the extraction of the causative teeth, and 1 (10.0%) had an oro-antral (primary) fistula (this patient applied for hospitalization three weeks after the extraction of the causative tooth). In the

area of the cavities of previously extracted causative teeth in 10 people (33.3%), the mucosa was gaping and there was a communication with the maxillary sinus, from which purulent contents were released. The mucous membrane of the alveolar process on the maxillary side was edematous and hyperemic in all patients (100%).

On radiographs and computed tomography scans of the nasal cavities in this group of patients there was darkening of the maxillary sinuses in all subjects, which was limited in nature with predominant lesion of its inferior and external walls. The predominant lesion of the lower and external walls is explained by the localization of odontogenic focus of infection – the source of chronic maxillary sinusitis.

Out of 30 patients with chronic odontogenic maxillary sinusitis the foci of infection, which in this group were the etiologic factor of inflammation development in the chronic inflammation in the maxillary sinus, were as follows: chronic granulomatous periodontitis in 7 patients (23.3%), chronic granulomatous periodontitis in 18 patients (60.0%), radicular cysts in 5 patients (16.7%).

Now let us examine the condition of fixed metal dentures in the first, previously mentioned observation group. Fixed metal dentures were made of stainless steel (in 7 patients, i.e. 23.3% of cases), chromium-cobalt (chromium-nickel) alloy – in 12 patients (40.0%), the presence of MPC of titanium nitride – in 11 patients (36.7%). Metal fixed dental prostheses in patients with galvanism were fabricated in different terms and the duration of their fixation on the teeth was from 5 months to 1.5 years.

During visual inspection of the surface of metal structures of dental prostheses, we found fractures in soldering points in 2 people (6.7%), fractures or breaks in ceramic or plastic parts of dental prostheses in 7 people (23.3%), uneven distribution (pathological erasability) of titanium nitride MPC on the surface of metal structures of dental prostheses (“bald areas”) in 7 people (23.3%).

Analysis of laboratory examination of patients. During the examination of oral fluid pH in the patients of the first observation group this index was  $6.7 \pm 0.2$  units (with fluctuations from 6.2 to 7.8). In the control group (22 practically healthy people) the oral fluid pH values amounted to  $7.2 \pm 0.2$  units (with fluctuations from 6.1 to 8.2). Comparing the pH changes in the subjects of the first group with

healthy people, it should be noted that in this group of observation we did not find significant changes in pH ( $p > 0.05$ ) compared to the norm.

Potentiometric indices of healthy people (without the presence of metal inclusions in the oral cavity) were as follows: potential difference –  $32.6 \pm 2.9$  mV; current strength –  $2.9 \pm 0.2$   $\mu$ A; electrical conductivity of oral fluid –  $2.7 \pm 0.2$   $\mu$ Sm.

Indices of potentiometric (galvanic) measurements in the subjects of the first observation group are presented in Figures 1–3. Analyzing the obtained potentiometric indices between metal inclusions (M-M) during hospitalization of patients we found the following values: potential difference was  $71.5 \pm 5.5$  mV; current strength –  $7.6 \pm 0.8$   $\mu$ A; electrical conductivity of oral fluid –  $9.9 \pm 1.2$   $\mu$ Sm. The analysis of potentiometric indices between metal and alveolar mucosa during hospitalization was as follows: potential difference –  $65.3 \pm 4.4$

mV; current strength –  $6.5 \pm 0.6$   $\mu$ A; electrical conductivity of oral fluid –  $8.5 \pm 0.9$   $\mu$ Sm. All these indices were significantly higher than normal ( $p < 0.001$ ) compared to healthy subjects. After the operation (sparing maxillary sinus surgery with local plasty of oro-antral communication) potentiometric parameters between metals (M-M) changed unreliably ( $p > 0.05$ ) and amounted to: potential difference –  $77.9 \pm 6.7$  mV; current strength –  $8.8 \pm 1.0$   $\mu$ A; electrical conductivity of oral fluid –  $10.5 \pm 1.3$   $\mu$ Sm. Potentiometric parameters between the metal and the mucous membrane of the alveolar outgrowth (M-SOAO) after the operation also changed unreliably ( $p_1 > 0.05$ ): potential difference was  $53.8 \pm 2.8$  mV; current strength –  $5.7 \pm 0.5$   $\mu$ A; electrical conductivity of the oral fluid –  $7.7 \pm 0.8$   $\mu$ Sm. Thus, all previously listed potentiometric parameters before and after the performed operation did not differ significantly ( $p_1 > 0.05$ ).

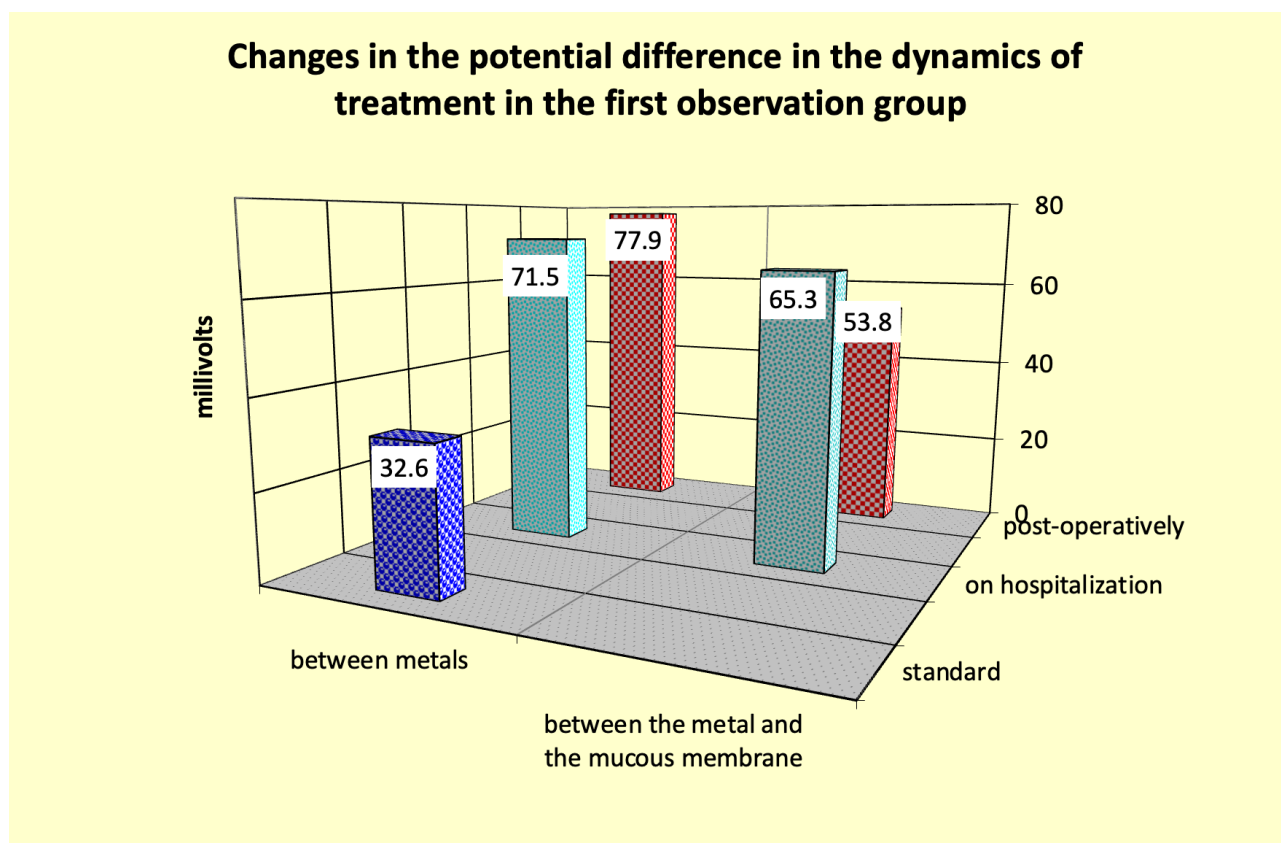
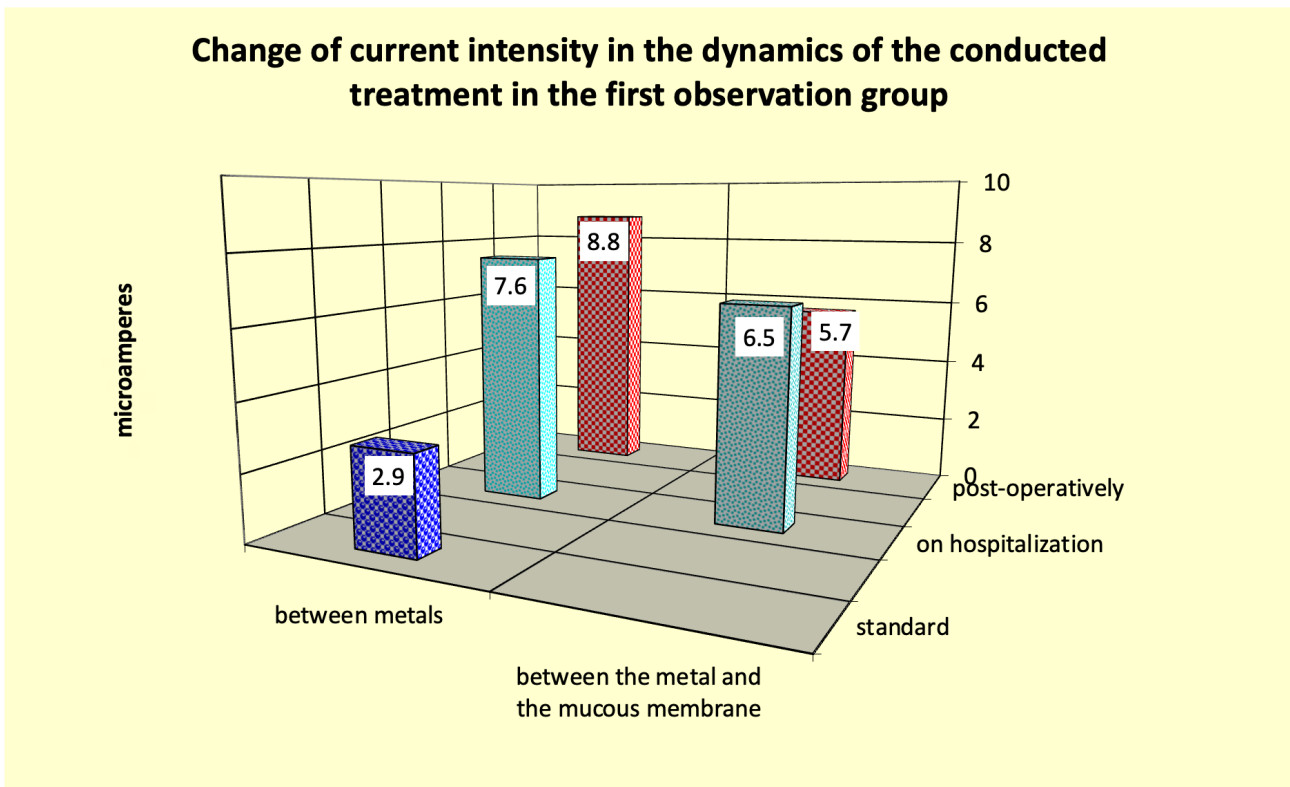
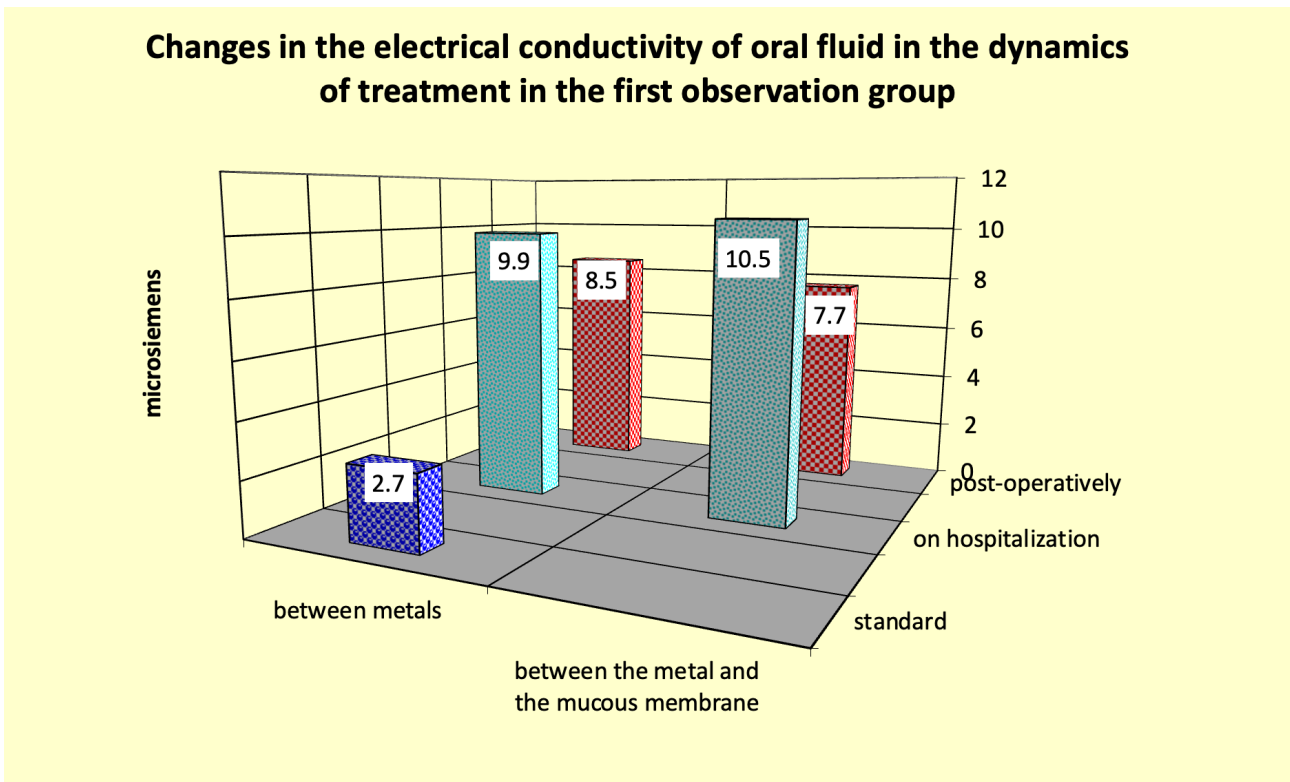


FIGURE 1. Changes in the potential difference in the dynamics of treatment in the first observation.



**FIGURE 2.** Change of current intensity in the dynamics of the conducted treatment in the first observation group.



**FIGURE 3.** Changes in the electrical conductivity of oral fluid in the dynamics of treatment in the first observation group.

According to the obtained potentiometry data, it should be noted that in patients with chronic odontogenic maxillary sinusitis, in whom galvanism (compensated and decompensated forms) was detected in the oral cavity, i.e. in the subjects of the I observation group, the clinical symptomatology of inflammation in the maxillary sinus (chronic maxillary sinusitis) was not pronounced and without aggressive course. During the first 3-4 days after the operation in 7 out of 30 patients of this group (23.3%) the postoperative period passed with high temperature (from 37.7 to 39.0°C). Clinically, postoperative edema of soft tissues (infraorbital, cheek, zygomatic areas, and upper lip) of the middle zone of the face in these terms was low expressed, which was accompanied by its insignificant asymmetry. Skin hyperemia was absent in all operated patients. In 16 out of 30 patients (53.3%) after the operation, within 5-6 days, there was pain of medium severity in the area of the maxillary bone, as well as in the area of the postoperative wound along the transitional fold and the alveolar process, as well as there was a slight discharge of blood from the corresponding half of the nose. The general condition of all patients in this group in the postoperative period was satisfactory. Three patients (10.0%) had weakness, 2 patients (6.7%) – malaise, and 3 patients (10.0%) – dizziness.

During 3-4 days after the operation, the mucosa in the area of the postoperative wound (along the transitional fold and alveolar process) was moderately edematous and slightly hyperemic in all subjects; during this period, mucosal infiltration was poorly expressed and superficial. On the 6th-7th day after the operation the hyperemia of the edges of postoperative wounds was absent and there was no infiltration of its walls. Only in 4 patients (13.3% of cases) on the 2nd-4th day after the operation the walls of the postoperative wound were slightly covered with fibrin plaque, but on the 5th-6th day the fibrin plaque on the wound walls was absent in all the patients. The sutures after the operation were fixed in all patients.

As a result, summarizing the previously conducted examination of patients with chronic odontogenic maxillary sinusitis with the presence of galvanism in the oral cavity (compensated and decompensated forms), i.e. the subjects of the first observation group, chronic inflammation in the maxillary sinus

proceeded without pronounced clinical symptoms. The exacerbation of the inflammatory process was rare – in 1 subject (3.3%). Among the inflammatory complications in the postoperative period, we found only gingivitis in the oral cavity in 19 people (63.3%), which was located in the area of existing fixed metal dentures, which in our opinion is the result of galvanic pathology - galvanism in the oral cavity of these subjects. We did not observe any other inflammatory complications in the area of peri-mandibular soft tissues of postoperative wounds and recurrences of inflammatory disease of the maxillary sinus in this observation group.

We analyzed clinical and potentiometric data in the subjects of the second observation group – 26 patients with chronic odontogenic maxillary sinusitis with the presence of galvanosis (atypical and typical forms) in their oral cavity. The number of metal inclusions in the oral cavity of these patients, as we have previously indicated, ranged from 3 to 19 orthopedic units.

Let us analyze the clinical symptomatology of chronic odontogenic maxillary sinusitis in the subjects of the second observation group. The patients had the following complaints: intense unilateral headaches were detected in 26 patients (in 100% of cases), nasal congestion on the side of maxillary sinusitis was in 24 patients (92.3%), nasal breathing disorder – in 25 patients (96.2%), decreased sense of smell – in 25 patients (96.2%), and the history of periodic exacerbation of inflammatory process in maxillary sinus (2 and more times) was noted in 17 patients (65.4%). When interviewing the patients, complaints about swelling in the infraorbital and cheek areas were present in 12 patients (46.2%), discharge of stinky mucus from the corresponding half of the nose – in 25 patients (96.2%).

When examining the patients objectively, 7 patients (26.9% of cases) had facial asymmetry in the infraorbital region on the side of maxillary sinusitis. Skin hyperemia was absent in all subjects, the skin was collected in a fold. Opening of the mouth was not difficult in all patients. Out of 26 subjects of the second observation group, the causative teeth were extracted in 8 patients (30.8%) before hospitalization. In the area of the cavities of the previously extracted teeth the mucous membrane was gaping, an oro-antral communication with the maxillary sinus was detected, from which malodorous purulent contents

were discharged. The mucous membrane of the alveolar process on the side of chronic maxillary sinus was edematous and hyperemic in all patients.

Twenty-six subjects with galvanosis had fixed metal dentures, which were made of base metals and their alloys, in 23 patients (88.5%), and 3 subjects (11.5%) had both metal-ceramic and base metal and their alloy dentures in the oral cavity at the same time. In the second observation group of patients, metal dentures were made of stainless steel (in 3 patients, i.e. in 11.5% of cases), chromium-cobalt (chromium-nickel) alloy – in 10 patients (38.5%), MPC of titanium nitride – in 13 patients (50.0%). Metal fixed dental prostheses in patients with galvanosis were fabricated at different dates and the duration of their fixation on the teeth was from 1 to 5 years.

Complaints from the general condition of the organism were revealed. When interviewing 26 patients, we found that almost all patients (100%) complained of rapid fatigability (weakness), poor sleep – 22 patients (84.6%), frequent bilateral headaches – 3 patients (11.5%), nausea – in 7 patients (26.9%). Diseases of respiratory organs (chronic bronchitis) in patients of this group we found out in 7 people (26.9%), skin diseases (eczema, dermatitis) – in 2 people (7.7%), gastrointestinal pathology (chronic gastritis, chronic cholecystitis, and pancreatitis) – in 12 people (46.2%). Allergic reactions to medications and food products were not found in the second observation group.

Then complaints from galvanic pathology (galvanosis) were identified. A metallic and/or sour taste in the mouth was noted in 11 out of 26 subjects (42.3%), “passing current” at the contact with a metal spoon while eating – in 4 people (15.4%), paresthesia of the tongue and inner surface of the lips (upper and/or lower) – in 8 people (30.8%), a feeling of bitterness – in 3 people (11.5%), burning of the mucous membrane at the place of contact with the metal part of the dental prosthesis – in 10 people (38.5%). Swelling, redness of the mucous membrane and petechial hemorrhages in the place of contact with metal parts of the denture were observed in 3 people (11.5%). Disturbance of taste sensitivity was observed in 5 patients (19.2%) and salivation (dry mouth) in 6 patients (23.1%). In addition to local symptoms of galvanosis, 4 out of 26 examined patients (15.4%) were diagnosed with general changes in the organism by family physicians (internist) and diagnosed with

increased fatigue syndrome (decreased efficiency, apathy, daytime sleepiness, anxiety, etc.) and chronic fatigue syndrome (significant decrease in physical and mental efficiency).

Visual inspection of the surface of metal structures in 26 patients with chronic odontogenic maxillary sinusitis of the second observation group revealed fractures in the soldering points of fixed dentures in 8 patients (30.8%), breaks or fractures of ceramic or plastic parts of dentures – in 3 patients (11.5%), dark oxide film at the solder location – in 7 patients (26.9%), areas of corrosive lesions – in 5 patients (19.2%), uneven distribution (pathologic abrasion) of titanium nitride metal protective coating on the surface of the metal structure of the denture (“bald areas”) – in 12 patients (46.2%). Thirteen out of 26 patients (50.0%) had a combination of detected defects (dark oxide film and fractures of the ceramic parts of the dentures, etc.).

Out of 26 patients with chronic odontogenic maxillary sinusitis, the focus of infection that were the etiologic factor of inflammation development in the maxillary sinus were as follows: granulomatous periodontitis in 8 patients (30.8%), peri-apical granuloma in 14 patients (53.8%), and radicular cysts in 4 patients (15.4%).

Radiographs and computed tomograms of the nasal cavities showed darkening of the maxillary sinuses in all subjects of a diffuse nature with predominant involvement of its lower and outer walls. In 17 patients (65.4%) of the second group the inner wall of the maxillary sinus was involved in inflammation.

Examination of oral fluid pH in 26 patients of the second group (with galvanosis) showed that this index was  $6.2 \pm 0.2$  units (with fluctuations from 5.3 to 7.6). In the control group of observation (22 practically healthy people), the oral fluid pH values were  $7.2 \pm 0.2$  units (with fluctuations from 6.1 to 8.2). Comparing changes in pH of oral fluid in patients with galvanosis with healthy people, it should be noted that in subjects with galvanosis we did not find a significant decrease in its pH ( $p > 0.05$ ) compared to the norm.

It should be noted that we could not find significant changes in the oral fluid pH values of the subjects between the first and second observation groups ( $p > 0.05$ ). The greatest deviations – decrease in pH of oral fluid were found in the subjects with

the maximum number (more than 10 prosthetic units) of fixed metal dentures in the oral cavity.

Indices of potentiometric (galvanic) measurements in the subjects of the second observation group are presented in Figures 4–6. Analyzing the obtained potentiometric indices between metal (M-M) we found the following: potential difference –  $175.9 \pm 27.5$  mV; current strength –  $17.5 \pm 2.9$   $\mu$ A; electrical conductivity of oral fluid –  $18.4 \pm 3.0$   $\mu$ Sm. Potentiometric indices between metal and mucous membrane of alveolar process at hospitalization were as follows: potential difference –  $153.8 \pm 23.0$  mV; current strength –  $14.8 \pm 2.3$   $\mu$ A; electrical conductivity of oral fluid –  $15.9 \pm 0.9$   $\mu$ Sm. When the patients were hospitalized, all the above parameters were significantly higher than normal ( $p < 0.001$ ). After the performed operation (sparing maxillary sinus surgery with local

plasty of oro-antral communication) potentiometric indices between metals (M-M) changed unreliably ( $p > 0.05$ ) and amounted to: potential difference –  $180.9 \pm 28.3$  mV; current strength –  $18.3 \pm 3.0$   $\mu$ A; electrical conductivity of oral fluid –  $19.0 \pm 3.2$   $\mu$ Sm. Potentiometric indices before and after the operation were not significantly different from each other ( $p > 0.05$ ). The indices between the metal and the mucous membrane of the alveolar process after the performed operation also did not significantly ( $p_1 > 0.05$ ) change in comparison with the previous examination (hospitalization): potential difference –  $142.9 \pm 20.8$  mV; current strength –  $14.0 \pm 2.2$   $\mu$ A; electrical conductivity of the oral fluid –  $16.7 \pm 2.7$   $\mu$ Sm. All previously studied potentiometric indices did not differ significantly ( $p_1 > 0.05$ ) from the previous measurement period, i.e. the time of hospitalization.

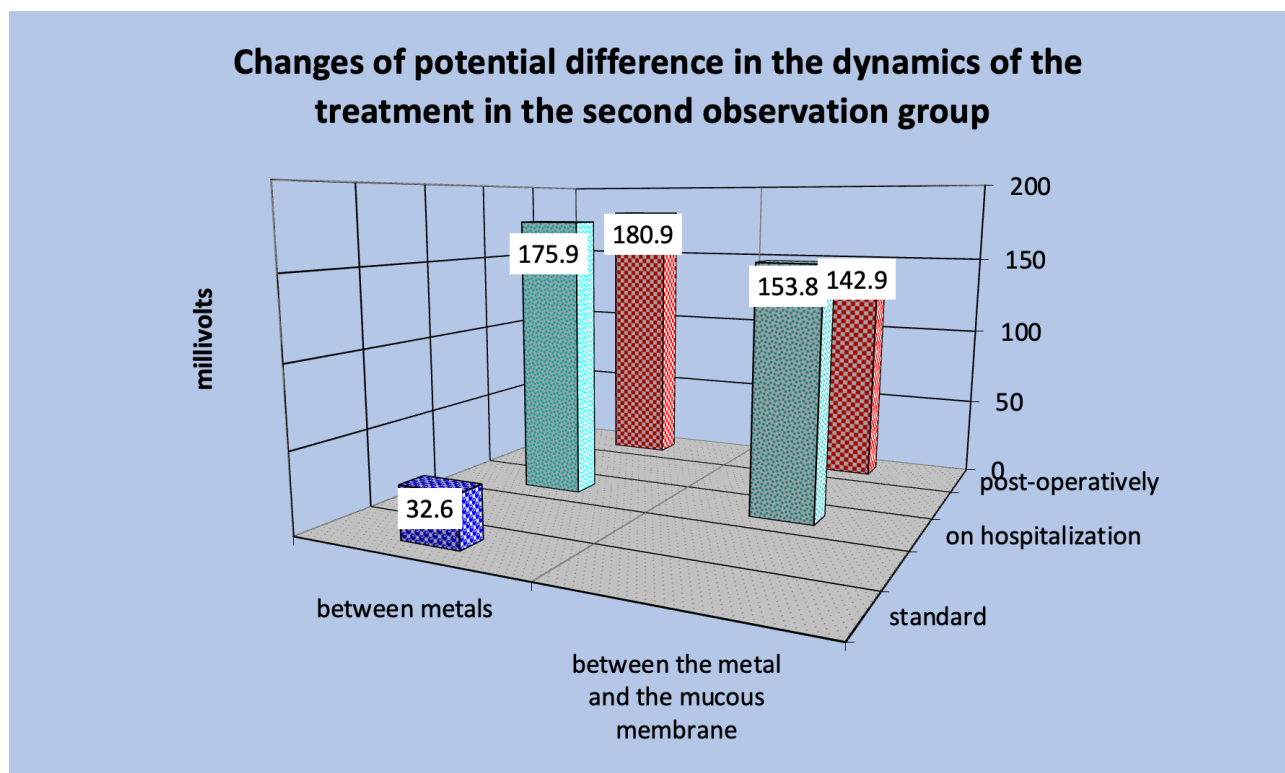
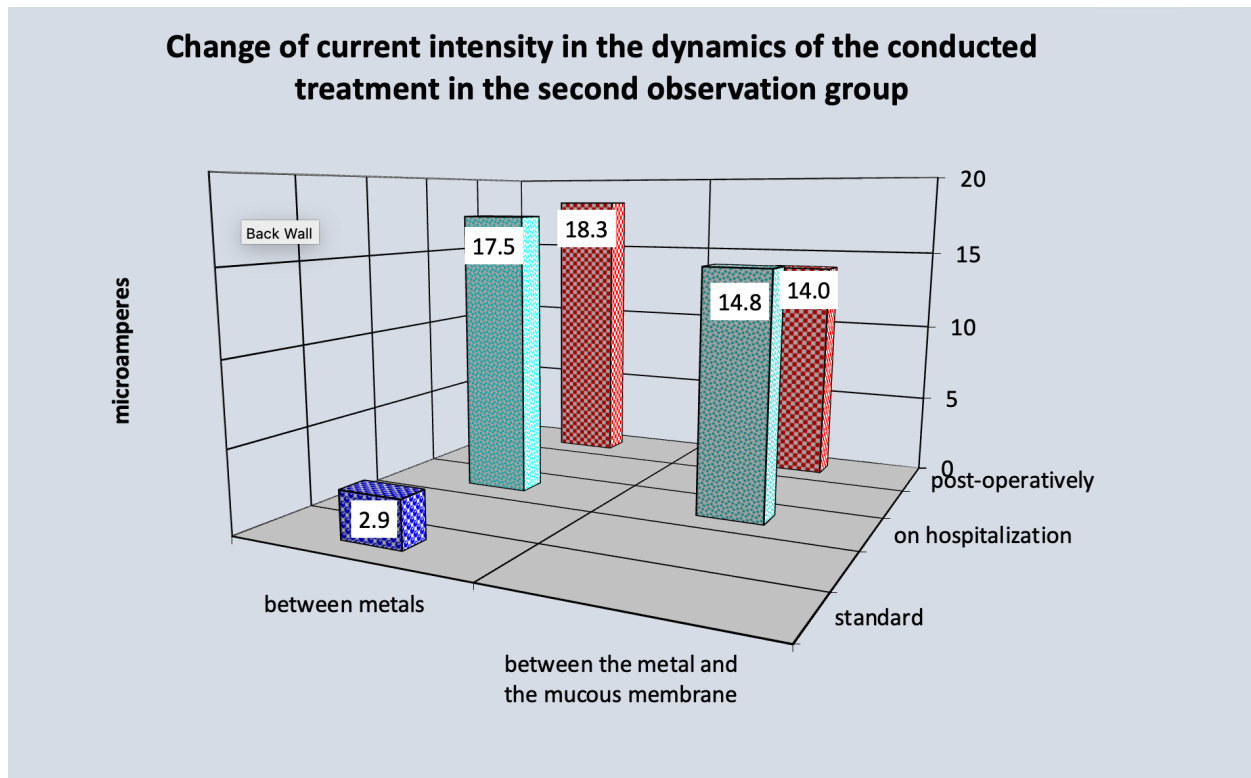
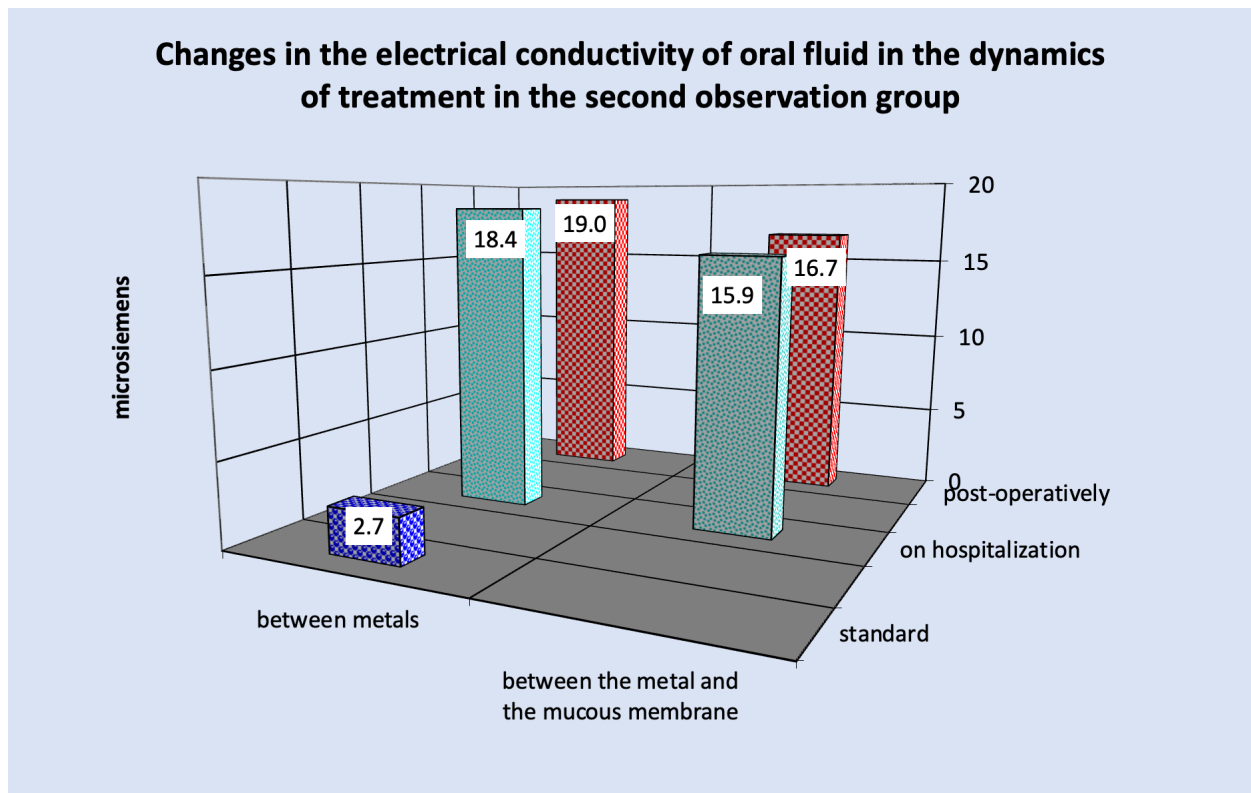


FIGURE 4. Changes of potential difference in the dynamics of the treatment in the second observation group.





**FIGURE 5.** Change of current intensity in the dynamics of the conducted treatment in the second observation group.



**FIGURE 6.** Changes in the electrical conductivity of oral fluid in the dynamics of treatment in the second observation group.

It should be noted that in patients with chronic odontogenic maxillary sinusitis in whom galvanosis (atypical and typical forms) was detected in the oral cavity, the clinical symptomatology of inflammation of the maxillary sinus was pronounced with an aggressive course. During the first 3-4 days after the operation in 23 out of 26 patients (88.5%) the postoperative period passed with high temperature (from 37.7 to 39.0°C). In 24 subjects (in 92.3% of cases) the edema of soft tissues (infraorbital, cheek, zygomatic regions, and upper lip) of the middle zone of the face was pronounced, which was accompanied by its significant asymmetry. In 13 out of 24 previously mentioned patients, i.e. in 54.2% of the examined patients, there was skin hyperemia during the first 3-4 days after the operation. All patients (in 100% of cases) had severe postoperative pain in the area of the maxillary bone, as well as in the area of the wound along the transitional fold and the alveolar process, as well as significant bloody discharge with blood streaks from the corresponding half of the nose for 5-6 days after the operation. The general condition in all patients of this group in the postoperative period was significantly disturbed. Within 6-7 days after the operation 22 patients (84.6%) had marked weakness, 20 patients (76.9%) – malaise, 15 patients (57.7%) – dizziness.

In all subjects, the wound edges of the postoperative wound on the mucosal side (along the transitional fold and alveolar process) were infiltrated, edematous and brightly hyperemic during the first 3-4 days after surgery. During this period, inflammatory infiltration of the mucosa of the postoperative wound was pronounced and deep. On 6-7 days after the operation the edges of postoperative mucosal wounds were already moderately hyperemic and superficially infiltrated. Postoperative wounds on the 2nd-4th day after the operation in 13 patients (50.0%) the walls were covered with a pronounced fibrin plaque, and on the 5th-6th day the fibrin plaque on the wound walls was found in single cases. Postoperative sutures were fixed.

In patients with chronic odontogenic maxillary sinusitis with the presence of galvanosis (atypical and typical forms) in the oral cavity, gingivitis was detected in almost all patients (in 100% of cases). Gingivitis was in the area of fixed metal dental prostheses. The most pronounced postoperative

inflammatory phenomena in the oral cavity were in the subjects who had stamped-soldered metal structures in the oral cavity, as well as in patients with chromocobalt (chromium-nickel) metal inclusions, as well as in those with defects in the metal protective coating of titanium nitride (in areas of damage and abrasion of titanium nitride of prostheses).

In all operated patients of the second observation group in the postoperative period such a complication as the presence of inflammatory infiltrate of peri-mandibular soft tissues and oral mucosa in the area of the operation was detected. In all cases after the operation, we prescribed antibacterial treatment. At repeated visits of these patients to the clinic (in 10-15 days) inflammatory infiltration of peri-mandibular soft tissues significantly decreased, but facial asymmetry remained in 12 subjects (in 46.2%), which was also observed on the side of mucous membranes in the area of the postoperative wound. In 3-4 weeks after the operation 9 patients (34.6%) of this group developed osteomyelitic process of the maxillary bone, i.e. recurrence of odontogenic inflammation of the maxillary sinus was diagnosed.

## CONCLUSIONS

Based on the examination of patients with chronic odontogenic maxillary sinusitis in the presence of galvanic pathology in the oral cavity, we found that in some types of this pathology, i.e. galvanosis, the inflammatory disease in the maxillary sinus runs aggressively, with pronounced clinical symptoms, frequent exacerbations of the inflammatory process, the presence of many postoperative inflammatory complications and recurrences of the disease.

## REFERENCES (13)

1. Tymofieiev OO. Maxillofacial surgery (Russian). 3rd ed. Kyiv: Medicine, All-Ukrainian Specialized Publishing House; 2020.
2. Tymofieiev OO. Manual of maxillofacial and dental surgery (Russian). 5th ed. Kyiv: Chervona Ruta-Turs; 2012:319–32.
3. Tymofieiev OO. Maxillofacial surgery and surgical dentistry (Russian). Volume 1. Kyiv: Medicine, All-Ukrainian Specialized Publishing House; 2020.
4. Tymofieiev OO. Maxillofacial surgery and surgical dentistry (Russian). Volume 2. Kyiv: Medicine, All-

- Ukrainian Specialized Publishing House; **2022**.
5. Tymofieiev OO, Pavlenko OO, Tymofieiev OO. Galvanic pathology in stomatology (Ukrainian). Kyiv: TOV Stal publishing house LLC; **2014**.
  6. Tymofieiev OO, Tymofieiev OO, Ushko NO, Yarifa MO. Question of the etiology of malignant neoplasms. *J Diagn Treat Oral Maxillofac Pathol* **2017**;1(3–4):175–82.  
<https://doi.org/10.23999/j.dtomp.2017.3-4.11>
  7. Tymofieiev OO, Ushko NO, Tymofieiev OO, et al. Clinical classification of galvanic manifestations, emerging in the oral cavity after the installation of metal inclusions (lecture) (Russian). *Modern Dent* **2019**;95(1):74–9.  
<https://doi.org/10.33295/1992-576X-2019-1-74-79>
  8. Yun Y, Yagi M, Sakagami T, et al. Odontogenic maxillary sinusitis: therapeutic management of cases with oroantral fistulae. *Sinusitis* **2021**; 5(1):53–8.  
<https://doi.org/10.3390/sinusitis5010006>
  9. Psillas G, Papaioannou D, Petsali S, et al. Odontogenic maxillary sinusitis: a comprehensive review. *J Dent Sci* **2021**;16(1):474–81.  
<https://doi.org/10.1016%2Fj.jds.2020.08.001>
  10. Raj G, Raj M, Pheng Loh JS. Pathophysiology and clinical presentation of odontogenic maxillary sinusitis. *Dent Rev* **2022**;2(2):100044.  
<https://doi.org/10.1016/j.dentre.2022.100044>
  11. Pokorny A, Tataryn R. Clinical and radiologic findings in a case series of maxillary sinusitis of dental origin. *Int Forum Allergy Rhinol* **2013**;3(12):973–9.  
<https://doi.org/10.1002/alr.21212>
  12. Bomeli SR, Branstetter BF 4th, Ferguson BJ. Frequency of a dental source for acute maxillary sinusitis. *Laryngoscope* **2009**;119(3):580–4.  
<https://doi.org/10.1002/lary.20095>
  13. Whyte A, Boeddinghaus R. Imaging of odontogenic sinusitis. *Clin Radiol* **2019**;74(7):503–16.  
<https://doi.org/10.1016/j.crad.2019.02.012>



ОРИГІНАЛЬНЕ ДОСЛІДЖЕННЯ

UKRAINIAN LANGUAGE

## Потенціометричне обстеження хворих із хронічним одонтогенним верхньощелепним синуситом за наявності гальванічної патології

Олексій Тимофєєв<sup>a,\*</sup> та Андрій Чередніченко<sup>b</sup>

### АНОТАЦІЯ

**Мета.** Метою дослідження було визначення величини потенціометричних показників у порожнині рота, що наявні між металевими включеннями, а також між металевими включеннями та слизовою оболонкою альвеолярного відростка у хворих на хронічний одонтогенний верхньощелепний синусит (гайморит) з гальванічною патологією.

**Методи.** 56 обстежених із хронічним одонтогенним верхньощелепним синуситом було розділено на дві обстежувані групи спостереження, яким проводилися потенціометричні та загальноклінічні обстеження.

**Результати.** У 30 хворих на хронічний одонтогенний верхньощелепний синусит із наявністю у них у порожнині рота гальванізму (компенсованої та декомпенсованої форм) хронічне запалення у верхньощелепній пазусі протікало без яскраво вираженої клінічної симптоматики, а у 26 хворих, у яких у порожнині рота виявлено гальваноз (атипової та типової форми), клінічна симптоматика прояву запалення у верхньощелепній пазусі була вираженою з агресивним перебігом та при наявності ускладнень.

**Висновки.** На підставі проведеного обстеження 56 хворих на хронічний одонтогенний верхньощелепний синусит за наявності в порожнині рота гальванічної патології нами встановлено, що при деяких видах цієї патології, тобто при гальванозі, запальне захворювання у верхньощелепній пазусі протікає агресивно, з яскраво вираженою клінічною симптоматикою, частими загостреннями запального процесу, наявністю великої кількості післяопераційних запальних ускладнень і рецидивами захворювання.

**Ключові слова:** хронічний одонтогенний верхньощелепний синусит, гайморит, верхньощелепна пазуха, гальванічна патологія, потенціометрія, гальванізм, гальваноз, металеві включення.

<sup>a</sup> Тимофєєв Олексій Олександрович – д. мед. н., професор, заслужений діяч науки і техніки України, завідувач кафедри щелепно-лицевої хірургії Національного університету охорони здоров'я України імені П. Л. Шупика.

<sup>b</sup> Чередніченко Андрій Миколайович – аспірант кафедри щелепно-лицевої хірургії Національного університету охорони здоров'я України імені П. Л. Шупика.

\* **Кореспонденція:** Department of Maxillofacial Surgery of Shupyk National Healthcare University of Ukraine based on Kyiv City Clinical Hospital No. 12 Communal Non-profit Enterprise, 4A Profesora Pidvysotskoho Street, Kyiv 01103, Ukraine.  
E-mail: [tymofeev@gmail.com](mailto:tymofeev@gmail.com) (Oleksii Tymofieiev)  
ORCID: <https://orcid.org/0000-0002-3191-6025>

**Підтримка.** Гранти не отримано.

**Внесок автора.** Автори підтверджують свій внесок у статтю наступним чином: створення концепції дослідження, формуванню дизайну і затвердження остаточної версії рукопису – Олексій Тимофєєв та Андрій Чередніченко.

**Конфлікт інтересів.** Автори не мають конфлікту інтересів, про який слід розкривати.

**Дизайн дослідження:** оригінальне дослідження.

**Для цитування:** Tymofieiev OO, Cherednichenko AM. Potentiometric examination of patients with chronic odontogenic maxillary sinusitis in the presence of galvanic pathology. J Diagn Treat Oral Maxillofac Pathol 2023;7(10):120–131.

Манускрипт отриманий 17 жовтня 2023  
Прийнятий до публікації 28 жовтня 2023  
Стаття доступна онлайн 31 жовтня 2023

<https://doi.org/10.23999/j.dtomp.2023.10.2>

© 2023 ТОВ «ОМФ ПАБЛШИНГ». Це стаття відкритого доступу під ліцензією CC BY (<https://creativecommons.org/licenses/by-nc/4.0/>).