

PAPERS SCAN

Review of “A Case of Bisphosphonate-Related Osteonecrosis of the Jaw With a Particularly Unfavourable Course: A Case Report” by Viviano M, Addamo A, Cocca S in *J Korean Assoc Oral Maxillofac Surg* 2017;43:272–5

Bisphosphonate-related osteonecrosis of the jaw (BRONJ) is side-effects of Bisphosphonates (BP) used to prevent and treat osteoporosis, to treat Paget’s disease, multiple myeloma, bone metastases, and associated malignant hypercalcemia. Nowadays the American Association of Oral and Maxillofacial Surgeons is renamed BRONJ into MRONJ (medication-related osteonecrosis of the jaw) according to due to reports of several non-bisphosphonate drugs resulting in the loss of alveolar bone and clinically appearing similar to BRONJ. Those terms can be used as synonyms but BRONJ is more detailing the pharmaceutical etiology of the specific case of osteonecrosis. BRONJ is currently diagnosed on the basis of necrotic bone exposed in the oral cavity for at least 8 weeks in patients with no history of head or neck radiotherapy.

Viviano *et al* have described case (Fig 1) treated with zoledronic acid after breast cancer surgery diagnosed and confirmed by histological examination diagnosed and confirmed by histological examination. The patient was treated for the necrosis (mechanical debridement, washing with hydrogen peroxide, iodopovidone, and 1% chlorhexidine gel). This treatment controlled her pain, inflammation, and infectious episodes, but bone necrosis continued to spread. Patient was treated by amoxicillin

and clavulanic acid (1g 3 times a day for 10 days) and metronidazol (250mg 3 times a day for 10 days). After 15 days patient presented with temperature of 39.1°C with tachycardia, dysphagia, dyspnea, and tachypnea, extensive swelling of the face and neck, bright red extended skin, extremely painful to palpation, and incipient trismus. The patient was transferred to the intensive care unit, where antibiotic therapy was integrated with ciprofloxacin (500 mg twice a day i.v.) and imipenem (1.5 g/day) on the basis of an antibiogram. After initial clinical improvement observed about 4 days after cervicotomy, the patient’s condition deteriorated sharply. Despite systemic antibiotic treatment and repeated bronchial lavage, the patient’s general condition deteriorated, culminating in septic shock. This was followed by kidney and liver failure and death due to multiple organ dysfunction on the 10th day.

The findings of this case reveals possibility of fatal consequences after areas of necrosis permitted entry of infective agents and their spread to the oral floor and submandibular space through sublingual tissue and the mylohyoid muscle which gave rise to empyema involving the cervical fascia as necrotizing fasciitis. Therefore the use of BP should be carefully monitored in order to prevent such severe complications.

Section Editor – Medication Related Osteonecrosis of the Jaw (MRONJ)
Nur Hatab, DMD, PhD
Assistant Professor
Ras Al Khaimah, UAE
nur.hatab@rakmhsu.ac.ae



Full Article
Viviano et al

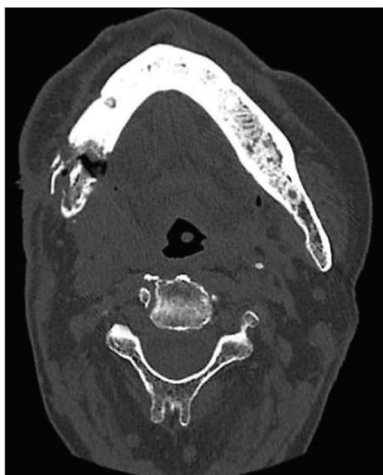

Fig. 3. Computed tomography (CT) scan of the head; transversal view. CT scan of the face, neck and chest was performed without contrast, showing pathological fracture of right jaw and periosteal reaction, besides mixed lytic and sclerotic lesion of the jaw.
Massimo Viviano et al: A case of bisphosphonate-related osteonecrosis of the jaw with a particularly unfavourable course: a case report. J Korean Assoc Oral Maxillofac Surg 2017

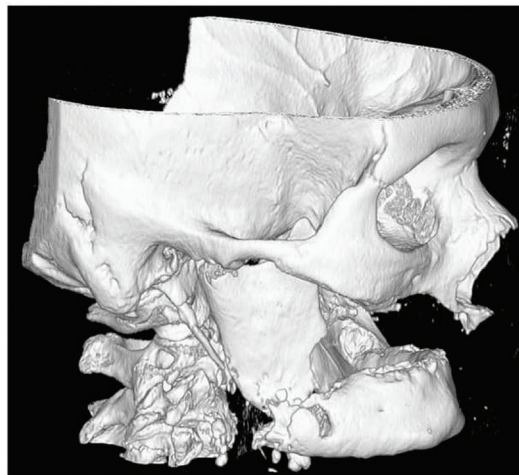


Fig. 4. Three-dimensional computed tomography reconstruction of the head. Radiological image shows a noticeable pathological fracture of right jaw in a 69-year-old woman with breast cancer history and treated with zoledronic acid.
Massimo Viviano et al: A case of bisphosphonate-related osteonecrosis of the jaw with a particularly unfavourable course: a case report. J Korean Assoc Oral Maxillofac Surg 2017

showing impaired cardiovascular function treated with calcium antagonists, beta blockers, antiplatelet agents, diuretics, electrolytes, and albumin (which is typically depleted in such conditions).

A CT scan showed an absence of empyema of the oral floor and cervical spaces due to drainage; however, the lungs showed diffuse signs of pneumonia with massive involvement on the left side. Despite systemic antibiotic treatment and repeated bronchial lavage, the patient’s general condition deteriorated, culminating in septic shock. This was followed by kidney and liver failure and death due to multiple organ dysfunction on the 10th day.

III. Discussion

Bone necrosis is a complication of therapy with BP and is related to the strength of the drug administered, duration of therapy⁶, and concomitance of trauma exposing bone of the jaws. Extraction of a tooth is often the triggering event. If dental treatment is necessary, BP should only be suspended when the risk of complications is high⁷.

Our patient has previously undergone surgery for breast cancer and was immediately treated with zoledronic acid. After seven months of BP therapy, she developed BRONJ. No dental events can explain the osteonecrosis. In the present case, progression of areas of necrosis led to jaw fracture,

permitting entry of infective agents (usually *Staphylococcus aureus* and *P. aeruginosa*^{8,9}) and their spread to the oral floor and submandibular space through sublingual tissue and the mylohyoid muscle. This gave rise to empyema involving the cervical fascia as necrotizing fasciitis¹⁰. The first therapies indicated were high doses of broad-spectrum antibiotics. The flora that generally cause this type of infection consist of resistant anaerobic and aerobic bacteria. The most suitable drugs for appropriate initial antibiotic therapy include penicillinase-resistant penicillin for streptococci and staphylococci, clindamycin or metronidazole for anaerobic gram-negative flora, and fluoroquinolones for *Pseudomonas* and aerobic and anaerobic bacteria¹¹.

Other systemic diseases, conditions, and pharmacological therapies that contribute to poor general condition (diabetes, positivity for hepatitis B virus, hepatitis C virus, human immunodeficiency virus, smoking, alcohol abuse, obesity, cardiovascular disease, and immunosuppressant therapy) are fundamental factors in the evolution of BRONJ, infection, and fasciitis, as in the present case, and predispose the patient to a negative outcome. A good prognosis is often aided by early diagnosis, specific pharmacological therapy, and prompt surgical debridement¹². In the present case, the poor general condition of the patient made it impossible to limit spread of the infection.

Like other pathologies of odontogenic origin that can lead

FIGURE 1. Cropped screenshot from the article Viviano M, Addamo A, Cocca. A case of bisphosphonate-related osteonecrosis of the jaw with a particularly unfavourable course: a case report. *SJ Korean Assoc Oral Maxillofac Surg* 2017;43:272–5. <https://doi.org/10.5125/jkaoms.2017.43.4.272>. This is an open-access article distributed under the terms of the Creative Commons Attribution Non-Commercial License (<http://creativecommons.org/licenses/by-nc/4.0/>).