

# Osteoradionecrosis of the Jaws: A Report of Nineteen Consecutive Cases\*

Oleksii O. Tymofieiev<sup>1,\*</sup>, Oleksandr O. Tymofieiev<sup>2</sup>

<sup>1</sup> Chair of the Department of Maxillofacial Surgery, Shupyk National Medical Academy of Postgraduate Education, Kyiv, Ukraine (Prof, ScD)

<sup>2</sup> Associate Professor of the Dentistry Department of Shupyk National Medical Academy of Postgraduate Education (Assoc Prof, ScD)

## ABOUT ARTICLE

### Article history:

Paper received 16 January 2018

Accepted 03 February 2018

Available online 30 March 2018

### Keywords:

Malignant tumors

Osteoradionecrosis (ORN)

Osteonecrosis

Post-radiation necrosis

Jaws

Sequestrectomy

Radiation-induced oral mucositis (RIOM)

Xerostomia after radiation therapy

Retabolil

## ABSTRACT

### Purpose.

To study the clinical-radiological symptoms in post-radiological osteonecrosis of the jaws.

### Methods.

The survey is based on the clinical study of 19 patients with osteoradionecrosis of the jaws that appeared after the radiation impact on the soft tissues what surrounds jaws, which was performed after the removal of malignant tumors of the soft tissues of the maxillofacial area.

### Results.

Based on the examination of patients, clinical and radiological symptoms were studied in cases of osteoradionecrosis of the jaws, described methods of treatment and prevention of this disease.

### Conclusions.

In osteoradionecrosis of the jaws there is a significant destruction of bone tissue, which is accompanied by the rejection of sequestrs. After X-ray influence on the soft tissues that surrounds jaws, changes in tissues and organs of the oral cavity are observed.

© 2018 OMF Publishing, LLC. This is an open access article under the CC BY licence (<http://creativecommons.org/licenses/by-nc/4.0/>).

## Introduction

Radiation damage to organs and tissues occurs as a result of exposure to ionizing radiation. The use of ionizing radiation in the treatment of malignant tumors of various organs and systems is associated with the risk of post-radiation complications. Osteoradionecrosis (ORN) (synonyms: post-radiation necrosis of the jaws, post-radiation osteomyelitis) of the jaw bones occurs after exposure to ionizing radiation, which can be associated with the treatment of malignant tumors, blood diseases and other organs and systems. ORN develops in 5-10% of patients who received large doses of radiation in the jaw region [1-4].

## Material and Methods

This examination is based on the clinical examination and treatment of 19 patients with ORN of the jaws, which appeared after radiation exposure of the soft tissue that surrounds jaws, carried out after the removal of malignant tumors of the soft tissues of the maxillofacial region. We

have observed patients and surgical interventions both in the Maxillofacial Surgery Department of Shupyk National Medical Academy of Postgraduate Education and in other surgical departments of Kyiv and other cities of Ukraine.

The purpose of the survey is to study clinical and radiological symptoms in post-radiation osteonecrosis of the jaws.

## Results

There are early (acute) and late (chronic) manifestations of radiation exposure. The development of necrotic foci in tissues (skin, soft tissues, and jaws) after radiation depends on the size of the dose, the volume of the irradiated zone, etc. They manifest themselves in skin burns resembling thermal burns and are characterized by the fact that radiation burns of the skin do not develop immediately after exposure, and after a while, i.e. through a latent period. The duration of the latter is shortened with an increase in the dose of ionizing radiation. Late radiation damage most often occurs as a consequence of radiation therapy of malignant tumors.

Many authors believe that the following factors most often contribute to the appearance of ORN of the jaw: the failure of the irradiation technique (exceeding the permissible dose of irradiation), underestimation of concomitant local (presence of carious teeth, chronic periodontitis or complicated forms of periodontitis) or general (diabetes mellitus or another chronic pathology)

\* This manuscript has not been presented

\* Corresponding author. Department of Maxillofacial Surgery, Shupyk NMAPE, 4-a Pidvysotskogo Street, Kyiv 01103, Ukraine. Tel., fax: +38 (044) 528 35 17.

E-mail address: [tymofeev@gmail.com](mailto:tymofeev@gmail.com) (O.O. Tymofieiev)

Instagram: [oleksii.tymofieiev](https://www.instagram.com/oleksii.tymofieiev/); [dt\\_journal](https://www.instagram.com/dt_journal/)

UDC: 616.31:616.716.4-001.28-002.4-089

<http://dx.doi.org/10.23999/j.dtemp.2018.1.5>

diseases. It should be noted that osteoradionecrosis appears more often in people who abuse alcohol or smokers.

In the radiation zone in the postoperative radiation exposure, in addition to the affected tissues, healthy tissues also enter, including the mucous membrane of the oral cavity and alveolar processes, teeth and jaw bones.

It should be noted that the clinical signs of ORN, teeth and tissues of the oral cavity are quite typical. In all patients in the beginning there is a radiation-induced oral mucositis (RIOM) (synonym: radiomucositis) of mucous membranes of lips, cheeks, and tongue [5]. The clinical picture of radiation damage to the mucous membrane develops gradually. First there is hyperemia and swelling of the mucous membranes, in the future – erosion. The post-radiation reaction has its own peculiarities of manifestation in various parts of the mucous membrane. The first clinical signs on the mucosa, which do not have a keratinized layer in the epithelium, i.e. cheeks, the bottom of the oral cavity and the soft palate, are manifested by slight hyperemia and swelling, which gradually increase. Owing to an intense keratinization, the mucous membrane becomes turbid, loses its luster, thickens, folding appears, and the surface layer is not removed during scraping. Modified areas of the mucosa may resemble leukoplakia or oral lichen planus. As the dose of irradiation increases, the keratinized epithelium is rejected in some areas and erosions appear, covered with a sticky necrotic coating – focal radiation-induced oral mucositis, then the epithelium is rejected in large areas, the erosions merge and the focal radiomucositis is transformed into a large (diffused) radiation-induced oral mucositis. With post-radiation effects in the oral cavity the tropism of the mucous membrane changes, burning, dryness, blanching of the mucous membrane is observed. Often post-radiation stomatitis is developed, as well as the phenomenon of hemorrhagic syndrome, the presence of infection provoke the formation of ulcers and necrosis. Necrosis developing in the oral cavity, is always more intense in the area of adherence to the mucous membrane of metal prostheses and seals, in such places where there are usually accumulations of microbes. There are signs of damage to the edges of the gums and tonsils, followed by the damage of the lateral surfaces of the tongue and palate, increased swelling of the membranes of the mouth, lips and face.

The pathological process that occurs in the mucosa of the oral cavity is complicated by the damage of the salivary glands. Initially, there is increased salivation (within a few days), which quickly gives way to dry mouth before complete xerostomia [6-10] is developed. As a result of the death of taste buds of the tongue there is a taste disorder. Initially, sensations in the tongue can manifest as a glossalgia, then there is a perversion of taste, and later its loss. It is known that radiation changes in the oral cavity are largely reversible. After cessation of irradiation or during a break in treatment, the mucous

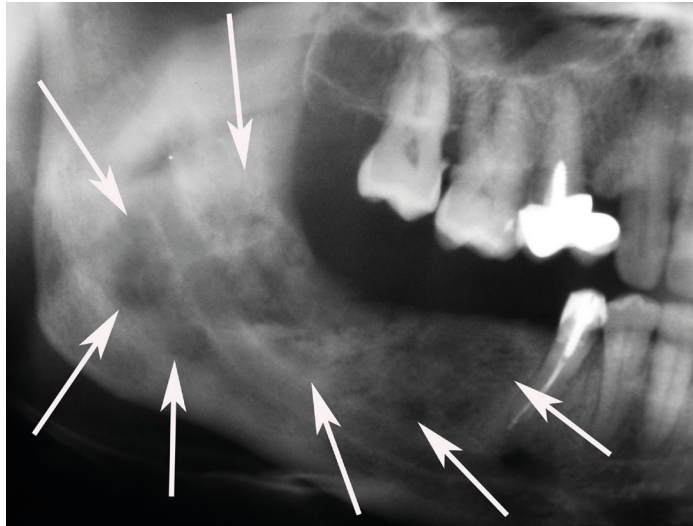
membrane returns fairly quickly (within 2-3 weeks) to normal. Long-term radiation exposure can lead to irreversible changes in the salivary glands and mucous membrane (edema, hyperemia, telangiectasia, atrophy, radiation ulcers).

Post-radiation pathologic process of the jaws (osteoradionecrosis) is develop in the long term after irradiation and is most often manifested in the form of aseptic necrosis of the bone. Post-radiation damage to jaw bones and teeth can be both isolated and combined with radiation damage to the skin and soft tissues. The causes of osteoradionecrosis are vascular, morphological, degenerative changes in tissues and in the organs of the oral cavity (salivary glands), as well as the immunosuppressive effect of ionizing radiation on tissues. It is believed that the post-radiation osteonecrosis of the lower and upper jaws arises when the oral cavity dryness (xerostomia) affects the teeth. Predisposing factors for infection of the jaw injured by ionizing radiation are untreated dental diseases (periodontitis, etc.) [11-14]. As a result of this infection, post-radiation osteomyelitis develops, characterized by the presence of purulent inflammation in addition to the typical changes in bone structure for radiation injuries.

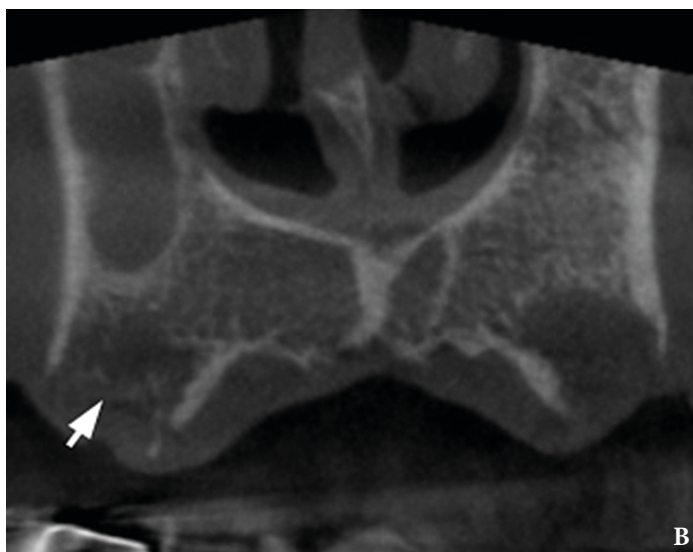
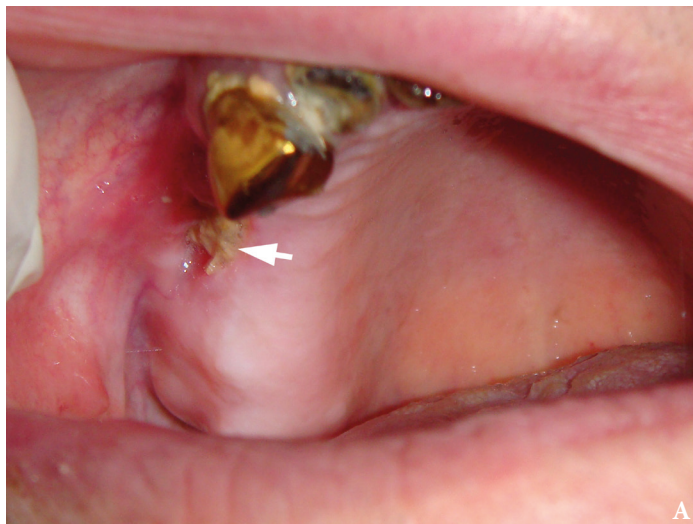Most often ORN develops within the first or second year after the end of radiation therapy. In rare cases, they can appear at an earlier time – in a few weeks or at a later date – after 3 years or more. One of the first clinical signs of the development of post-radiation osteonecrosis is the emergence of osteoporosis foci, which can be detected by radiography. Clinical symptoms are often pains localized in the lower and less frequently in the upper jaw. When infected, areas of ulceration or even necrosis of the mucous membranes of the alveolar process may appear. Radiological features (X-ray, CT, MRI): foci of rarefaction (destruction) of bone tissue (osteolytic foci), in some cases it is possible to detect sequestrs (Figs 1, 2). Sequestrs can be easily detected upon clinical examination of patients (Fig 3).

## Discussion

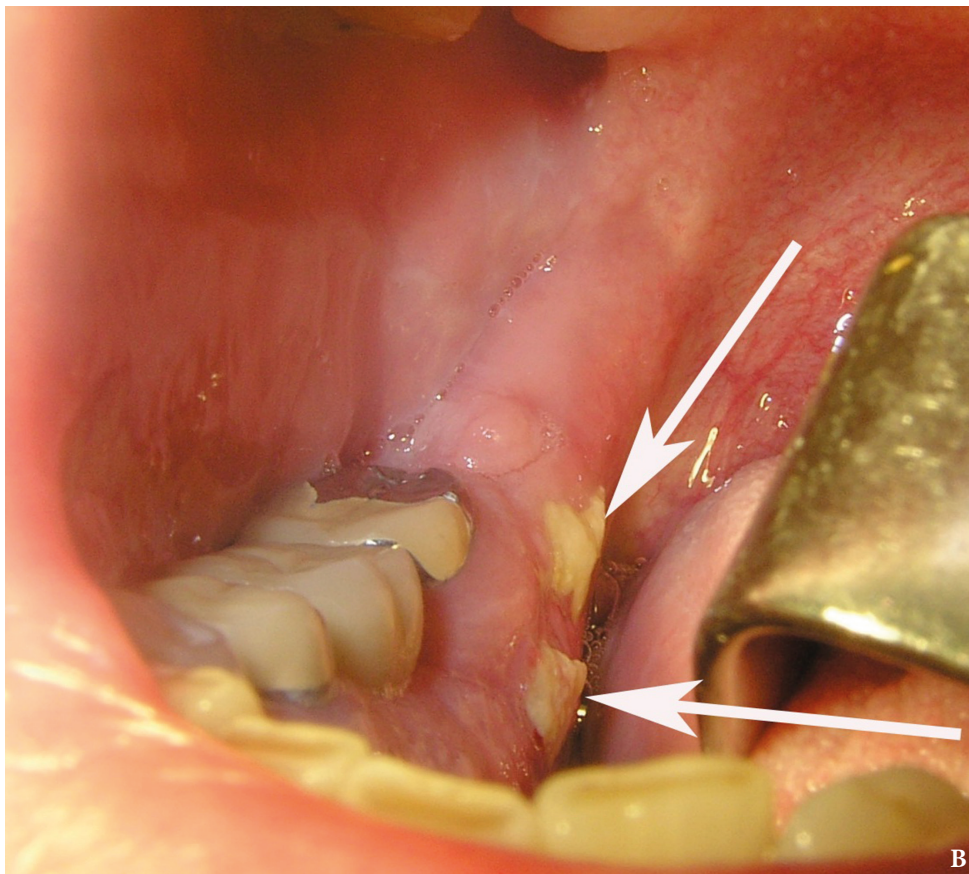
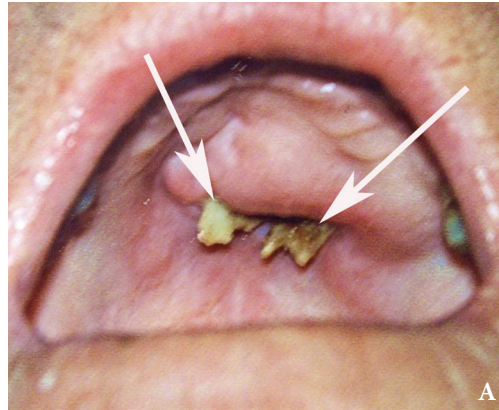
The essence of pathological changes in the bone is a violation (deterioration) of its blood supply and mineral composition. In some cases, post-radiation lesions of the upper and lower jaw can occur in the absence of clinical symptoms, i.e. aseptic necrosis of the bone develops. Therefore, the term “dead-jaw syndrome” is often found in the literature. In some cases, as a result of the presence of chronic odontogenic foci in the patients, infection of pathological foci develops (hyperemia and edema of the alveolar processes, soreness, fistulas with other clinical signs of inflammation) [15-18]. In very sharp cases ORN of the mandible is complicated by abscesses and phlegmons of the soft tissues of the maxillofacial region and neck, as well as sepsis, thrombophlebitis of facial veins and other severe purulent-inflammatory processes.



**FIGURE 1.** Radiograph shows destruction foci at the right mandible (arrows) in a 52-year-old gentleman with osteoradionecrosis.



**FIGURE 2.** Osteoradionecrosis on the right maxilla in a 64-year-old man after radiotherapy. Sequester is indicated by arrows (**A**: clinical view; **B**: coronal cone beam CT scan). Images of **Figure 2** are courtesy of Ievgen I. Fesenko, PhD, Assis Prof; Kyiv, Ukraine.



**FIGURE 3.** Sequestration (*arrows*) on the maxilla (**A**) and mandible (**B**) with osteoradionecrosis in patients of different age groups.

#### TREATMENT OF OSTEORADIONECROSIS

Treatment of osteoradionecrosis of the jaws in the early stages of its detection can be conservative and consists in prescribing, according to indications, anabolic steroids (Retabolil; Gedeon Rihter, Budepest, Hungary) in combination with calcium preparations. Retabolil enhances protein synthesis in patients with asthenia, cachexia, during radiation therapy, osteoporosis and other pathologies. Under the influence of the active substance, which is part of retabolil, the growth of damaged bone tissue is accelerated [19-22].

Treatment of post-radiation osteomyelitis is always

operative and consists of carrying out sequestrectomy (with the removal of existing sequestrers) or resection of the involved bone tissue also using microvascular free flaps [23-25]. But the flap surgeries have their own rate of complications [26]. General (antibiotic therapy) and local (antiseptic rinsing of the oral cavity) anti-inflammatory treatment is performed. General treatment of post-radiation lesions should always be combined with therapeutic measures that are aimed at increasing immunological resistance and normalizing the disturbed functions of the body.

There may be difficulties in the treatment of such patients. One of such difficulties in the treatment

of osteonecrosis may be that it is often difficult to determine radiography the difference between the healthy and affected bone tissue which determines the size of the sequestrectomy (necrectomy). Another difficulty is that it can be difficult to differentiate between post-ray bone necrosis and the recurrence of a malignant bone tumor. To solve this problem, the experience of the operating surgeon and carrying out pathomorphological studies of the material to be removed is necessary.

#### PREVENTION OF OSTEORADIONECROSIS

Prevention of osteoradionecrosis of the jaws consists in the sanitation of the oral cavity before radiotherapy, hygiene of the oral cavity. The teeth should not be extracted during radiotherapy and 2-3 months after [27, 28]. It is necessary to reduce the indirect effect of penetrating radiation by preliminary (preferably before irradiation) a month course of general and local remineralizing therapy in combination with a complex of antioxidants. In such cases, the use of antioxidants in tablets becomes necessary.

For remineralizing therapy, preparations containing calcium, phosphate and other trace elements are used: 10% calcium gluconate solution, 5-10% solution of acidified calcium phosphate, 3% remodent solution (fluoride is not included in its composition), calcium phosphate-containing gels, 5-10% calcium lactate solution, 2.5-10% calcium glycerophosphate solution.

The role of antioxidants is performed by vitamins and minerals contained in various products. The latter activate the human enzyme system. The best antioxidant products are natural products: blueberries, blackberries, grapes, eggplants, beets, grapefruits, persimmons, tomatoes, pumpkin, carrots, etc. Antioxidants must also be taken in the form of medicinal multivitamin preparations: vitrum antioxidant, vitrum-fort Q10, quercetin, selenium-forte, lipin, trofosan, coenzyme Q10, and others.

In the event that preventive measures before irradiation were not carried out, then after radiotherapy it is necessary to conduct the entire course of complex treatment for 5-6 months, combining it with dental interventions (sanitation of the oral cavity).

#### Funding

None.

#### Conflict of Interests

The authors declare no conflict of interests.

#### Role of Authors

The authors are equally contribute to that article.

#### Ethical Approval

Approval was obtained from the Medical Ethics Committee of the Shupyk National Medical Academy of Postgraduate Education, Kyiv, Ukraine.

#### Patient Consent

Written patient consent was obtained to publish the clinical images.

#### Acknowledgements

None.

#### Peer Reviewed

Externally peer reviewed.

#### References

1. Tymofieiev OO. Manual of maxillofacial and oral surgery [Russian]. 5th ed. Kyiv: Chervona Ruta-Turs; **2012**.
2. Tymofieiev OO. Maxillofacial surgery [Ukrainian]. 2nd ed. Kyiv: Medytsyna; **2017**.
3. Rathy Ravindran, Sunil S, Nivia M. Osteoradionecrosis of mandible: case report with review of literature. *Contemp Clin Dent* **2013**;4(2):251–3.
4. Chronopoulos A, Zarra T, Tröltzsch M, Mahaini S, Ehrenfeld M, Otto S. Osteoradionecrosis of the mandible: a ten year single-center retrospective study. *J Craniomaxillofac Surg* **2015**;43(6):837–46.
5. Maria OM, Eliopoulos N, Muanza T. Radiation-induced oral mucositis. *Front Oncol* **2017**;7:89.
6. Pinna R, Campus G, Cumbo E, Mura I, Milia E. Xerostomia induced by radiotherapy: an overview of the physiopathology, clinical evidence, and management of the oral damage. *Ther Clin Risk Manag* **2015**;11:171–88.
7. Sugimoto K, Tsuchiya S, Hara K, Matsushita Y, Masahito Fujio, Hideharu Hibi. Osteoradionecrosis of the jaw caused by periapical periodontitis: A case report. *J Oral Maxillofac Surg Med Pathol* **2017**;29(4):328–33.
8. Fan H, Kim SM, Cho YJ, Eo MY, Lee SK, Woo KM. New approach for the treatment of osteoradionecrosis with pentoxifylline and tocopherol. *Biomaterials Research* **2014**;18:13.
9. Lyons A, Ghazali N. Osteoradionecrosis of the jaws: current understanding of its pathophysiology and treatment. *Br J Oral Maxillofac Surg* **2008**;46:653–60.
10. He Y, Liu Z, Tian Z, Dai T, Qiu W, Zhang Z. Retrospective analysis of osteoradionecrosis of the mandible: proposing a novel clinical classification and staging system. *Int J Oral Maxillofac Surg* **2015**;44(12):1547–57.
11. Robard L, Louis M-Y, Blanchard D, Babin E, Delanian S. Medical treatment of osteoradionecrosis of the mandible by PENTOCLO: preliminary results. *Eur Ann Otorhinolaryngol Head Neck Dis* **2014**;131(6):333–8.
12. Zhang W, Zhang X, Yang P, Blanchard P, Garden AS, Gunn B, Fuller CD, Chambers M, Hutcheson KA, Ye R, Lai SY, Radwan MAS, Zhu XR, Frank SJ. Intensity-modulated proton therapy and osteoradionecrosis in oropharyngeal cancer. *Radiother Oncol* **2017**;123(3):401–5.

13. Kraeima J, Steenbakkers RJHM, Spijkervet FKL, Roodenburg JLN, Witjes MJH. Secondary surgical management of osteoradionecrosis using three-dimensional isodose curve visualization: a report of three cases. *Int J Oral Maxillofac Surg* **2018**;47(2):214–9.
14. Lyons AJ, Brennan PA. Pentoxifylline – a review of its use in osteoradionecrosis. *Br J Oral Maxillofac Surg* **2017**;55(3):230–4.
15. Dhanda J, Pasquier D, Newman L, Shaw R. Current concepts in osteoradionecrosis after head and neck radiotherapy. *Clin Oncol* **2016**;28(7):459–66.
16. Rhet Tucker J, Xu L, Sturgis EM, Mohamed ASR, Hofstede TM, Chambers MS, Lai SY, Fuller CD, Beadle B, Gunn GB, Hutcheson KA. Osteoradionecrosis in patients with salivary gland malignancies. *Oral Oncol* **2016**;57:1–5.
17. Nabil S, Ramli R. The use of buccal fat pad flap in the treatment of osteoradionecrosis. *Int J Oral Maxillofac Surg* **2012**; 41(11):1422–6.
18. Madrid C, Abarca M, Bouferrache K. Osteoradionecrosis: an update. *Oral Oncol* **2010**;46(6):471–4.
19. Antonio Rivero J, Shamji O, Kolokythas A. Osteoradionecrosis: a review of pathophysiology, prevention and pharmacologic management using pentoxifylline,  $\alpha$ -tocopherol, and clodronate. *Oral Surg Oral Med Oral Pathol Oral Radiol Endod* **2017**;124(5):464–71.
20. Zhang D, Yang Z, Zhuang P, Wang Y, Chen W, Zhang B. Role of negative-pressure wound therapy in the management of submandibular fistula after reconstruction for osteoradionecrosis. *J Oral Maxillofac Surg* **2016**;74(2):401–5.
21. McCaul JA. Pharmacologic modalities in the treatment of osteoradionecrosis of the jaw. *Oral Maxillofac Surg Clin North Am* **2014**;26(2):247–52.
22. Yoshimura H, Ohba S, Aiki M, Nagase J, Kimura T, Kobayashi J, Ishimaru K, Matsuda S, Sano K. Piezosurgery-assisted transposition of the inferior alveolar nerve in a patient with osteoradionecrosis: a case report with a neurosensory assessment and a review of the literature. *J Oral Maxillofac Surg Med Pathol* **2014**;26(4):472–6.
23. Fernandes RP, Quimby A, Salman S. Comprehensive reconstruction of mandibular defects with free fibula flaps and endosseous implants. *J Diagn Treat Oral Maxillofac Pathol* **2017**;1(1):6–10.
24. Baron S, Salvan D, Cloutier L, Gharzouli I, Le Clerc N. Fibula free flap in the treatment of mandibular osteoradionecrosis. *Eur Ann Otorhinolaryngol Head Neck Dis* **2016**;133(1):7–11.
25. Lee M, Chin RY, Eslick GD, Sritharan N, Paramaesvaran S. Outcomes of microvascular free flap reconstruction for mandibular osteoradionecrosis: a systematic review. *J Craniomaxillofac Surg* **2015**;43(10):2026–33.
26. Powell HRE, Jaafar M, Bisase B, Kerawala CJ. Resorption of fibula bone following mandibular reconstruction for osteoradionecrosis. *Br J Oral Maxillofac Surg* **2014**;52(4):375–8.
27. Tymofieiev OO, Ushko NO, Tymofieiev OO, Yarifa MO, Fesenko IeI. Prevention of inflammatory complications upon surgeries in maxillofacial region. *J Diagn Treat Oral Maxillofac Pathol* **2017**;1:105–12.
28. Nabil S, Samman N. Incidence and prevention of osteoradionecrosis after dental extraction in irradiated patients: a systematic review. *Int J Oral Maxillofac Surg* **2011**;40:229–43.

Tymofieiev OO, Tymofieiev OO.  
Osteoradionecrosis of the jaws: a report of nineteen consecutive cases.  
*J Diagn Treat Oral Maxillofac Pathol* **2018**;2(1):51–56.  
<http://dx.doi.org/10.23999/j.dcomp.2018.2.5>