

DT Journal

1 2021

**Journal of Diagnostics and
Treatment of Oral and
Maxillofacial Pathology**



Editors
Oleksii Tymofieiev • Rui Fernandes
(Kyiv, Ukraine • Jacksonville, FL, USA)



Official Journal of the
Ukrainian Association for
Maxillofacial and Oral Surgeons

DTJournal.org

U-Impl[®]

SWITZERLAND



№ R3M 804 252 B2

Сертифікат відповідності
технічного регламенту
щодо медичних виробів



Switzerland Aarbergerstrasse 107A, CH-2502
Biel, Phone/Fax +41 323230188
info@u-impl.com
www.u-impl.com

About the Journal: Aims and Scope

JANUARY 2021 • VOLUME 5 • ISSUE 1
www.djournal.org

Official Title

Journal of Diagnostics and Treatment of Oral and Maxillofacial Pathology

Standard Abbreviation: ISO 4

J. Diagn. Treat. Oral Maxillofac. Pathol.

International Standard Serial Number (ISSN)

Print ISSN 2519-2086 | Online ISSN 2522-1965

Aims & Scope

This is a monthly peer-reviewed oral and maxillofacial surgery journal focused on: Microvascular and jaw reconstructive surgery, dental implants, salivary gland tumors/diseases, TMJ lesions, virtual surgical planning, implementation of ultrasonography into the practice of oral and maxillofacial surgeons.

Editorial Board (EB) Composition

- EB shows significant geographic diversity representing 26 opinion leaders from 13 countries: Brazil, Canada, Colombia, Greece, Hong Kong (SAR, China), India, Israel, Italy, Slovak Republic, Spain, Ukraine, United Arab Emirates, and United States.
- The majority of the EB Members have a discernible publication history in Scopus, Web of Science, and journals with a high impact factor.
- The publication records of all EB members are consistent with the stated scope and published content of the journal.
- The journal has a several full-time professional editors.
- Gender distribution of the editors: 11.53% women, 88.47% men, 0% non-binary/other, and 0% prefer not to disclose.

Frequency

12 print/online issues a year (from January 2020)

Publication History

2017: 4 issues a year

2018: 4 issues a year

2019: 10 issues a year

From 2020: 12 issues a year

Publishing Model

Journal combines a *hybrid* and *delayed open access* publishing models. The articles of all types, except Editorials, are immediately in open access. Editorials became an open access publication too after 3-month embargo period.

Article Processing Charge (APC)

During hard times of Covid-19 pandemic our journal trying to support authors by reducing the APC by 50%. And by the end of March 2021 the APC will be 100 USD and 50 USD (excluding taxes) depending on the article's type. Details at website: dtjournal.org.

13 Types of Articles Currently Published by the Journal

Editorials/Guest Editorials/Post Scriptum Editorials, Images, Case Reports/Case Series, Original Articles, Review Articles, Discussions, Paper Scans (*synonyms*: Review of Articles, Literature Scan), Book Scans (*synonym*: Book Reviews), Letters to the Editor (*synonym*: Letters), and Viewpoints.

Registration: Ministry of Justice of Ukraine

Registration: July 28, 2016

Re-Registration: May 21, 2019 (Certificate: KB # 23999-13839IIP)

Co-Founders

1. Shupyk National Medical Academy of Postgraduate Education (from January-February 2021, the Academy receives a new name: Shupyk National University of Healthcare of Ukraine).
2. Private Higher Educational Establishment "Kyiv Medical University."
3. OMF Publishing, Limited Liability Company.

Publisher

OMF Publishing, LLC is an academic publisher focused on medical and linguistic sciences.

Address: 13-A Simferopolska Street, Office 121, Kyiv 02096, Ukraine.

Crossref Membership

OMF Publishing, LLC is a member of Publishers International Linking Association, Inc. which doing business as a Crossref. OMF Publishing's active membership: From February 2017 to present.

Official Journal of

Ukrainian Association for Maxillofacial and Oral Surgeons

Ukrainian Association for Maxillofacial and Oral Surgeons (UAMOS)

Address: 4-A Profesora Pidvysotskoho Street, Kyiv 01103, Ukraine.
Tel., fax: +38 044 528 35 17.

Website: uamos.org.

Subscription Index

In Ukraine: 60077 | In Donetsk/Luhansk Regions: 88263.

See page A5.

© 2021 OMF PUBLISHING, LLC

Editorial Board

JANUARY 2021 • VOLUME 5 • ISSUE 1
www.djournal.org

Editor in Chief

Oleksii O. Tymofieiev, ScD
(Kyiv, Ukraine)

Deputy Editor in Chief

Rui P. Fernandes, MD, DMD, FACS, FRCS(Ed)
(Jacksonville, Florida, United States)

Section Editors

Bone Augmentation Techniques

Nardy Casap, MD, DMD
(Jerusalem, Israel)

Head & Neck Radiology

Anil T. Ahuja, MBBS, MD, FRCR, FHKCR, FHKAM
(Hong Kong, SAR, China)

Craniofacial Deformities

Sunil Richardson, MDS
(Nagercoil, Tamil Nadu, India)

Images

Camilo Mosquera, DDS
(Bogotá, D.C., Colombia)

Facial Feminization Surgery

Kyle Keojampa, MD, FACS
(Los Angeles, California, United States)

Orthognathic Surgery

Mario Brinhole
(São Paulo, São Paulo, Brazil)

Facial Plastic Surgery

Tirbod Fattahi, MD, DDS, FACS
(Jacksonville, Florida, United States)

Robotic Surgery

Salam O. Salman, MD, DDS, FACS
(Jacksonville, Florida, United States)

Head & Neck Oncologic Surgery

Todd C. Hanna, MD, DDS, FACS
(New York, New York, United States)

TMJ Lesions/Disorders

Belmiro C. Vasconcelos, DDS, PhD
(Recife, Pernambuco, Brazil)

Editorial Board Members

Oleh M. Antonyshyn, MD, FRCS(C)
(Toronto, Ontario, Canada)

Anastasiya Quimby, DDS, MD
(Fort Lauderdale, Florida, United States)

Anthony M. Bunnell, MD, DMD, FACS
(Jacksonville, Florida, United States)

Daniel Robles Cantero, DDS, MSc
(Madrid, Spain)

Nur A. Hatab, DMD, PhD
(Ras Al Khaimah, United Arab Emirates)

Peter Stanko, MD, PhD
(Bratislava, Slovak Republic)

Andrey V. Kopchak, ScD
(Kyiv, Ukraine)

Olexander O. Tymofieiev, ScD
(Kyiv, Ukraine)

Olindo Massarelli, MD, PhD, FEBOMFS
(Sassari, Italy)

Natalia O. Ushko, ScD
(Kyiv, Ukraine)

Andrew Yampolsky, DDS, MD
Philadelphia, Pennsylvania, United States

Web & Social Media Editor

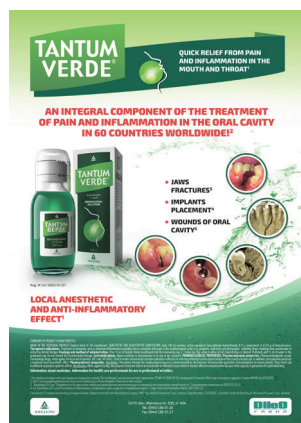João L. Monteiro, DDS
(Boston, Massachusetts, United States)

Director, Journal Development Department

Evangelos G. Kilipiris, DMD
(Thessaloniki, Greece | Bratislava, Slovak
Republic)

Managing Editor

Ievgen I. Fesenko, PhD
(Kyiv, Ukraine)



TANTUM VERDE®

INFORMATION LEAFLET
for the medicinal product

Composition:

active substance: benzydamine hydrochloride;
100 mL of solution contain benzydamine hydrochloride 0.15 g;

excipients: ethanol 96%, glycerol, methyl parahydroxybenzoate (E 218), flavor (menthol), saccharin, sodium hydrocarbonate, Polysorbate 20, Quinoline Yellow (E 104), Patent Blue V (E 131), purified water.

Dosage form. Oromucosal solution.

Basic physical and chemical properties: a clear green liquid with a typical mint flavor.

Pharmacotherapeutic group. Dental preparations. Other agents for local oral treatment.
ATC code: A01A D02.

Pharmacological properties.

Pharmacodynamics.

Benzydamine is a non-steroidal anti-inflammatory drug (NSAID) with analgesic and antiexudative properties.

Clinical studies have shown that benzydamine is effective in the relief of symptoms accompanying localized irritation conditions of the oral cavity and pharynx. Moreover, benzydamine has anti-inflammatory and local analgesic properties, and also exerts a local anesthetic effect on the oral mucosa.

Pharmacokinetics.

Absorption through the oral and pharyngeal mucosa has been proven by the presence of measurable quantities of benzydamine in human plasma. However, they are insufficient to produce any systemic pharmacological effect. The excretion occurs mainly in urine, mostly as inactive metabolites or conjugated compounds.

When applied locally, benzydamine has been shown to cumulate in inflamed tissues in an effective concentration

due to its ability to permeate through the mucous membrane.

Clinical particulars.

Indications.

Symptomatic treatment of oropharyngeal irritation and inflammation; to relieve pain caused by gingivitis, stomatitis, pharyngitis; in dentistry after tooth extraction or as a preventive measure.

Contraindications.

Hypersensitivity to the active substance or to any other ingredients of the product.

Interaction with other medicinal products and other types of interaction.

No drug interaction studies have been performed.

Warnings and precautions.

If sensitivity develops with long-term use, the treatment should be discontinued and a doctor should be consulted to get appropriate treatment.

In some patients, buccal/pharyngeal ulceration may be caused by severe pathological processes. Therefore, the patients, whose symptoms worsen or do not improve within 3 days or who appear feverish or develop other symptoms, should seek advice of a physician or a dentist, as appropriate.

Benzydamine is not recommended for use in patients hypersensitive to acetylsalicylic acid or other non-steroidal anti-inflammatory drugs (NSAIDs).

The product can trigger bronchospasm in patients suffering from or with a history of asthma. Such patients should be warned of this.

For athletes: the use of medicinal products containing ethyl alcohol might result in positive antidoping tests considering the limits established by some sports federations.

Use during pregnancy or breast-feeding

No adequate data are currently available on the use of benzydamine in pregnant and breastfeeding women. Excretion of the product into breast milk has not been studied. The findings of animal studies are insufficient to make any conclusions about the effects of this product during pregnancy and lactation.

The potential risk for humans is unknown.

TANTUM VERDE should not be used during pregnancy or breast-feeding.

Effects on reaction time when driving or using machines

When used in recommended doses, the product does not produce any effect on the ability to drive and operate machinery.

Method of administration and doses.

Pour 15 mL of TANTUM VERDE solution from the bottle into the measuring cup and gargle with undiluted or diluted product (15 mL of the measured solution can be diluted with 15 mL of water). Gargle 2 or 3 times daily. Do not exceed the recommended dose.

Children.

The product should not be used in children under 12 years due to a possibility of ingestion of the solution when gargling.

Overdosage.

No overdose has been reported with benzydamine when used locally. However, it is known that benzydamine, when ingested in high doses (hundreds times higher than those possible with this dosage form), especially in children, can cause agitation, convulsions, tremor, nausea, increased sweating, ataxia, and vomiting. Such acute overdose requires immediate gastric lavage, treatment of fluid/salt imbalance, symptomatic treatment, and adequate hydration.

Adverse reactions.

Within each frequency group, the undesirable effects are presented in order of their decreasing seriousness.

Adverse reactions are classified according to their frequency: very common ($\geq 1/10$); common ($\geq 1/100$ to $<1/10$); uncommon ($\geq 1/1,000$ to $<1/100$); rare ($\geq 1/10,000$ to $<1/1,000$); very rare ($<1/10,000$); frequency unknown (cannot be estimated from the available data).

Gastrointestinal disorders: rare – burning mouth, dry mouth; *unknown* – oral hypesthesia, nausea, vomiting, tongue edema and discoloration, dysgeusia.

Immune system disorders: rare – hypersensitivity reaction, *unknown* – anaphylactic reaction.

Respiratory, thoracic and mediastinal disorders: very rare – laryngospasm; *unknown* – bronchospasm.

Skin and subcutaneous tissue disorders: uncommon – photosensitivity; very rare – angioedema; *unknown* – rash, pruritus, urticaria.

Nervous system disorders: *unknown* – dizziness, headache.

TANTUM VERDE contains methyl parahydroxybenzoate, which can cause allergic reactions (including delayed-type reactions).

Shelf life. 4 years.

Storage conditions.

Do not store above 25°C. Keep out of reach of children.

Packaging.

120 mL of solution in a bottle with a measuring cup; 1 bottle per cardboard box.

Dispensing category.

Over-the-counter medicinal product.

Manufacturer.

Aziende Chimiche Riunite Angelini Francesco A.C.R.A.F. S.p.A., Italy.

Location of the manufacturer and its business address.
Via Vecchia del Pinocchio, 22 – 60100 Ancona (AN), Italy.

Date of the last revision of the text.

September 26, 2018.

Information leaflet is

APPROVED by

Order of the

Ministry of Health of Ukraine

No. 636 dated 01.10.2015

Registration Certificate

No. UA/3920/01/01

Subscription in Ukraine

JANUARY 2021 • VOLUME 5 • ISSUE 1
www.dtjournal.org

Frequency of the *Journal of Diagnostics and Treatment of Oral and Maxillofacial Pathology*:
12 issues (synonym: numbers) a year.

Subscription index in Ukraine: 60077.

Subscription index for Donetsk and Luhansk Regions: 88263.



Three ways of individual/institutional subscription of print version of the *Journal*:

1. At Ukrposhta post offices.
2. At the website www.presa.ua.
3. At the website www.dtjournal.org

| Issues | Fee in 2021 |
|-----------|----------------------|
| 1 Issue | \$1.35 (37.88 UAH) |
| 3 Issues | \$3.95 (110.64 UAH) |
| 6 Issues | \$7.65 (214.28 UAH) |
| 12 Issues | \$15.11 (423.36 UAH) |

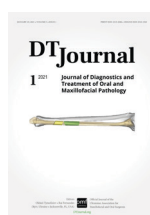

QR code leads to
Journal subscription

Content

of the Volume 5 • Issue 1 • January 2021

| | | |
|-----------|----|--|
| | A1 | Publisher & Editorial Office Information |
| | A2 | Editorial Board |
| | A5 | Subscription in Ukraine |
| | A6 | Content, Courtesy, & Erratum |
| EDITORIAL | 1 | Global Board in a Global World Oleksii O. Tymofeiev, Ievgen I. Fesenko, & Victoria P. Blinova |
| NOTE | 3 | Laser CO2 to Decrease the Risk of the Recurrence in Odontogenic Myxoma When an Extensive Resection Is Not Possible Andrés Pauwels-Tumiñan, Constanza Lozano-Morales, Juan Pablo López, & María Paula Orjuela |
| GUEST | 10 | Private Practice, Implantology, and Continuing Professional Development Ivan V. Nagorniak |
| IMAGES | 13 | Periorbital Abscessing Furuncle Olha S. Cherniak & Ievgen I. Fesenko |



COURTESY

Journal's cover image (virtual surgical planning for a segmental mandibular reconstruction with fibula transplant) is courtesy of Rui P. Fernandes, MD, DMD, FACS, FRCS.

Image was taken from the article: Fernandes RP, Quimby A, Salman S. Comprehensive reconstruction of mandibular defects with free fibula flaps and endosseous implants. *J Diagn Treat Oral Maxillofac Pathol* 2017;1(1):6–10.



EDITORIAL

Global Board in a Global World

Oleksii O. Tymofieiev^a, Ievgen I. Fesenko^b, & Victoria P. Blinova^c

Think globally, act locally.
—Paul McCartney
English singer-songwriter

Nice to see OMS flourishing in my motherland.
—Andrew Yampolsky, DDS, MD
(personal communication, 2019)
Philadelphia, Pennsylvania, United States

Global composition of the Editorial Board (EB) is a beautiful core feature of the *Journal of Diagnostics and Treatment of Oral and Maxillofacial Pathology*. International diversity of the EB in 2020 became represented by 26 opinion leaders from 13 countries (Table 1).

The biggest number of EB editors and members from United States (8 persons) and the second highest number from Ukraine (5 persons) tells us how strong the editorial bridge between two countries was built during the five years of journal's existence. Moreover, the fact that two United States surgeons^{1,2} and one Canadian have Ukrainian roots symbolized that our journal is not only a new English-language flourishing publication in Ukraine and Eastern Europe but also a new one that unites surgeons with Ukrainian ancestors from all around the world.

Congratulations on the launching of a new journal. I wish you success. Thank you as well for your invitation to participate on the Editorial Board I would be delighted to do so.

—Oleh Antonyshyn, MD, FRCSC
(personal communication, 2016)
Toronto, Ontario, Canada

It's a special honor for me to be invited and I am beyond grateful for the opportunity to make my motherland proud!
—Anastasiya Quimby, DDS, MD
(personal communication, 2020)
Fort Lauderdale, Florida, United States

Simultaneously with geographical diversity, EB faced 2021 with a next gender distribution: 11.53 percent women, 88.47 percent men, 0 percent non-binary/other, and 0 percent prefer not to disclose. Furthermore, taking into account a steady increase in the proportion of Oral and Maxillofacial Surgery trainees and specialists who are females³ we can predict that number of females in the EB can grow.

In November's editorial⁴ we talked about journal's evolution with a help of technologies (like high-tech website), and this issue's analysis highlights another aspect of growth with a help of global editorial collaboration. So, we are happy to make those two steps in progress with our international editors because *website functionality* and *editorial board composition* are two of 24 quality criteria of the Web

Kyiv, Ukraine

^a Editor in Chief
E-mail: tymofeev@gmail.com (Oleksii Tymofieiev)

^b Managing Editor
E-mail: i.i.fesenko@dtjournal.org (Ievgen Fesenko)
Instagram: [@dr_eugenfesenko](https://www.instagram.com/dr_eugenfesenko)

^c Dentist; Assistant Professor, Department of Oral and Maxillofacial Surgery, Private Higher Educational Establishment "Kyiv Medical University"

Please cite this article as: Tymofieiev OO, Fesenko II, Blinova VP. Global board in a global world. *J Diagn Treat Oral Maxillofac Pathol* 2021;5(1):1–2.

<https://dx.doi.org/10.23999/j.dtemp.2021.1.1>

© 2021 OMF Publishing, LLC. This is an open access article under the CC BY license (<http://creativecommons.org/licenses/by-nc/4.0/>).

TABLE 1. Geographical Distribution of DTJournal.org`s Editors and EB Members.

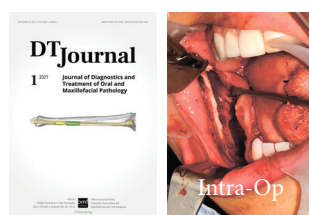| Country | Persons (n) |
|--|-------------|
| Brazil | 3 |
| Canada | 1 |
| Colombia | 1 |
| Greece | 1 |
| Hong Kong (special administrative region, China) | 1 |
| India | 1 |
| Israel | 1 |
| Italy | 1 |
| Slovak Republic | 1 |
| Spain | 1 |
| Ukraine | 5 |
| The United Arab Emirates | 1 |
| The United States | 8 |
| Total | 26 |

of Science journal evaluation process and selection criteria.⁵ Criteria which can help us to reach a goal each journal`s staff is very proud of-getting the first

Impact Factor.

REFERENCES

1. Tymofieiev OO, Fesenko II, Quimby A. Introducing the editorial board member from Philadelphia, Pennsylvania: Andrew Yampolsky, DDS, MD. *J Diagn Treat Oral Maxillofac Pathol* **2020**;4(9):151. <https://dx.doi.org/10.23999/j.dtomp.2020.9.1>
2. Tymofieiev OO, Fesenko II, Kilipiris EG. Introducing a new editorial board member: Anastasiya Quimby, DDS, MD. *J Diagn Treat Oral Maxillofac Pathol* **2020**;4(7):111. <https://dx.doi.org/10.23999/j.dtomp.2020.7.1>
3. Magennis P, Begley A. Gender in oral and maxillofacial surgery (OMFS) – trends and comparisons. *Br J Oral Maxillofac Surg* **2016**;54(10):e127–e128. <https://dx.doi.org/10.1016/j.bjoms.2016.11.175>
4. Tymofieiev OO, Ushko NO, Kilipiris EG. Dtjournal.org: growing with technologies. *J Diagn Treat Oral Maxillofac Pathol* **2020**;4(11):195–6. <https://dx.doi.org/10.23999/j.dtomp.2020.11.1>
5. Web of Science journal evaluation process and selection criteria [document on the internet]; February 29, **2019** [cited 2021 Jan 20]. Available from: <https://clarivate.com/webofsciencgroup/journal-evaluation-process-and-selection-criteria/>



NOTE

Laser CO2 to Decrease the Risk of the Recurrence in Odontogenic Myxoma When an Extensive Resection Is Not Possible

Andrés Pauwels-Tumiñan^a, Constanza Lozano-Morales^b, Juan Pablo López^{c,*}, & María Paula Orjuela^d

SUMMARY

Within the head and neck neoplasms, odontogenic myxoma is considered as a benign neoplasm that can present an aggressive behavior. It is frequently associated with an important recurrence rate that is possibly related to incomplete resection. Among the most common surgical behaviors that can be followed to treat this lesion, we can find curettage or curettage with a peripheral osteotomy to reduce its recurrence rate. The use of a laser has been increasing, presenting good results in different procedures in the oral and maxillofacial region. The aim of this study is to propose an alternative treatment combining the use of the CO2 laser with the conventional curettage technique in order to reduce the risk of recurrence of the odontogenic myxoma and avoid invasive procedures that will affect the quality of life of the patient.

Bogotá, Colombia

^a DDS, OMFS; Oral and Maxillofacial Surgeon, Head, Department of Oral Health Service, Hospital Universitario Fundación Santa Fe de Bogotá. Professor, Universidad El Bosque.

^b DDS, OMFS; Oral and Maxillofacial Surgeon, Chief, Division Oral and Maxillofacial Surgery, Hospital Universitario Fundación Santa Fe de Bogotá. Professor, Universidad El Bosque.

^c DDS, Private Practice.

^d DDS, Resident of Oral and Maxillofacial Surgery Program, Universidad El Bosque.

* Corresponding author's address: Private Practice, Bogotá, Colombia. Postal addresses 110111. Work telephone number: +57 (1) 6030303 – ext. 5818, 5814, 5833. E-mail: jplopez2304@gmail.com (Juan Pablo López)

E-mails of the co-authors:

ahapauwels@yahoo.ar (Andrés Pauwels-Tumiñan)
lozanoconstanza@yahoo.com (Constanza Lozano-Morales)
mapaula9413@gmail.com (María Paula Orjuela)

Please cite this article as: Pauwels-Tumiñan A, Lozano-Morales C, López JP, Orjuela MP. Laser CO2 to decrease the risk of the recurrence in odontogenic myxoma when an extensive resection is not possible. *J Diagn Treat Oral Maxillofac Pathol* 2021;5(1):3–9.

The abbreviation 'Intra-Op' at the upper right icon means that article contains intraoperative photographs.

Paper received 19 July 2020
Accepted 16 November 2020
Available online 29 January 2021

<https://dx.doi.org/10.23999/j.dtomp.2021.1.2>

© 2021 OMF Publishing, LLC. This is an open access article under the CC BY license (<http://creativecommons.org/licenses/by-nc/4.0/>).

INTRODUCTION

Odontogenic myxoma was first described by Thoma and Goldman in 1947.¹ They reported eleven cases in the maxillary and jaw area, similar to those seen in long bones. In the oral cavity it may occur as a peripheral or central tumor with persistent pain.¹ It is characterized by stellate and spindle-shaped cells dispersed in an abundant myxoid extracellular matrix.² Its origin from ectomesenchymal cells and its frequency of appearance is 3 to 6 percent within all odontogenic tumors.³ The treatments reported for its management vary from curettage to block resection with safety margins.⁴ The latter mentioned is indicated because although this lesion is considered a benign neoplasm, it usually has an aggressive behavior due to its infiltrative capacity.² However, block resection treatments with wide margins can cause mutilation in the patient, which results in a decrease in self-esteem and quality of life and has a significant impact on the development of one person's healthy life. Therefore, the use of conservative techniques as an alternative to resection is discussed and defended, in order to mitigate the adverse results of these extensive procedures. Likewise, knowing the recurrence rate of these tumors makes it possible to consider complementing these conventional techniques with adjuvant therapies such as the use of CO2 lasers.

Laser therapy has been frequently used in oral cavity in recent decades due to the simplicity of its technique, limitation in bleeding, minimal pain and short surgical time. All these mentioned characteristics make it a tool with great advantages over other techniques. Therefore, its use has also increased in the field of oral surgery and some of the procedures where it is used include vascular lesions of the mucosa, over inserted oral structures, mucoceles and even in gingivitis, among others.⁵

Therefore, the objective of this article is to suggest a combination of surgical techniques in the management of myxomas, including a conservative treatment and the additional use of the CO2 laser as an adjuvant therapy in order to reduce the likelihood of recurrence to the maximum.

SURGICAL TECHNIQUE

Having the patient under general anesthesia in a supine position, an incision and elevation of the flap is made according to what is indicated for

the location of the myxoma. Then, an osteotomy is performed to expose the tumor with a piezoelectric device, removing the entire roof of the lesion. This maneuver is performed to avoid any remains of the tumor attached to the bone ceiling. Afterwards, a mechanical curettage of the lesion is developed (Fig 1), trying to maintain the integrity of the lesion so that it can be sent in one piece for histopathological analysis.

With previous osteoplasty with piezoelectric, a CO2 laser scan of the entire bone cavity and surrounding soft tissue is performed where friable debris of the tumor remain, which are difficult to remove due to their size and consistency. This debris can generate reappearance of the lesion, so vaporization is carried out with the laser configured in a continuous pulse at 5 watts (Fig 2). It is essential to protect the tissues that are not involved and follow all precautionary measures for the use of lasers in vital tissues. Finally, primary closure of the lesion is made and the follow-up visits for the patient are scheduled for the next eight days, one month, six months, one year, two years, three years and five years (Fig 3). Although a few cases have been made following this protocol, nowadays we have 4 cases of patients with a mean radiographic follow-up of five years. These cases have been successfully treated, with the absence of symptoms and radiographic changes that can suggest the recurrence of the lesion.

DISCUSSION

The odontogenic myxoma frequently presents multilocular characteristics with a bone expansion that invades it infiltrative. These characteristics make it aggressive and probably associated with the recurrence rate of the injury. Mechanical curettage, as the only treatment option, has a high recurrence rate. The recurrence rate varies within different studies, averaging 25 percent, but the prognosis remains good. Occasionally, extensive peripheral osteotomies are performed that may reduce the risk of recurrence, but this treatment tends to be mutilating. Additionally, this may be limited in large lesions and association with critical anatomical structures.² The CO2 laser appears as an alternative to a block resection treatment for different benign or malignant lesions in different parts of the body. This laser was invented at Bell laboratories by Kumal Patel in 1964,⁶ and since the '70s, it has been widely

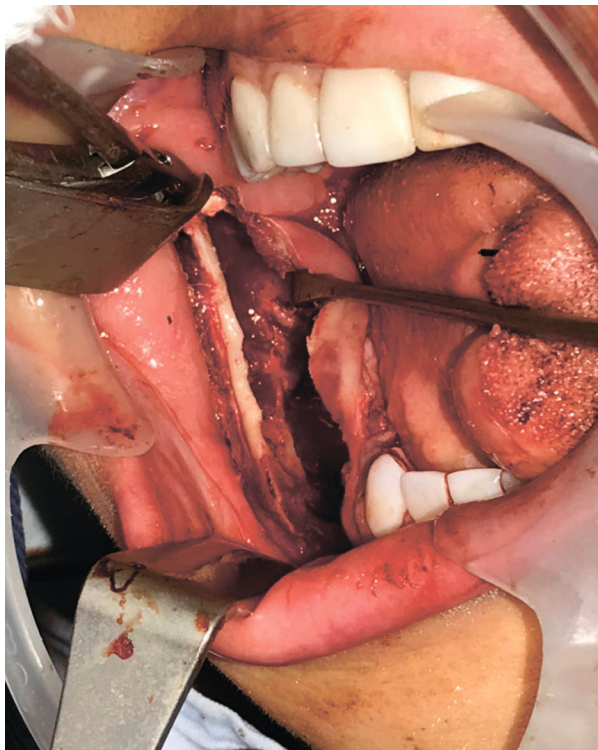

FIGURE 1. A bone cavity after mechanical curettage.

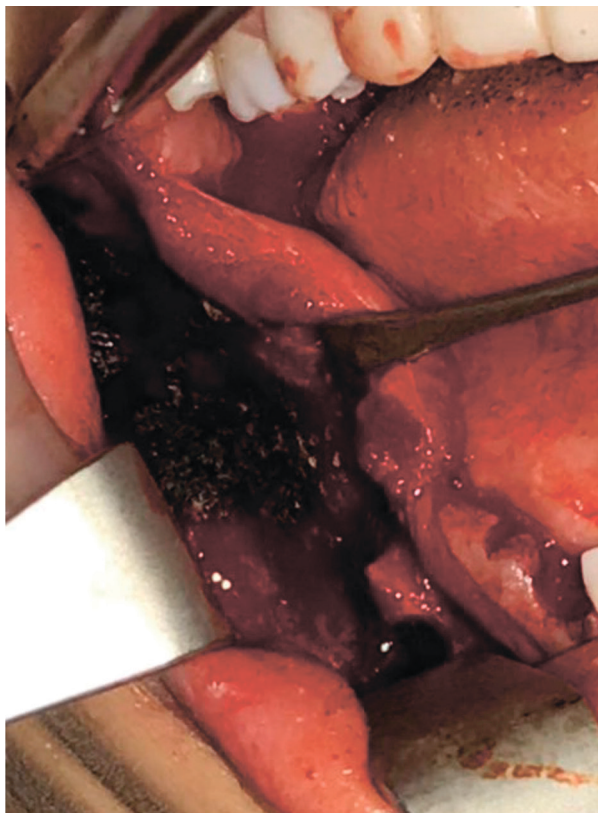

FIGURE 2. A bone cavity after the use of CO2 laser.

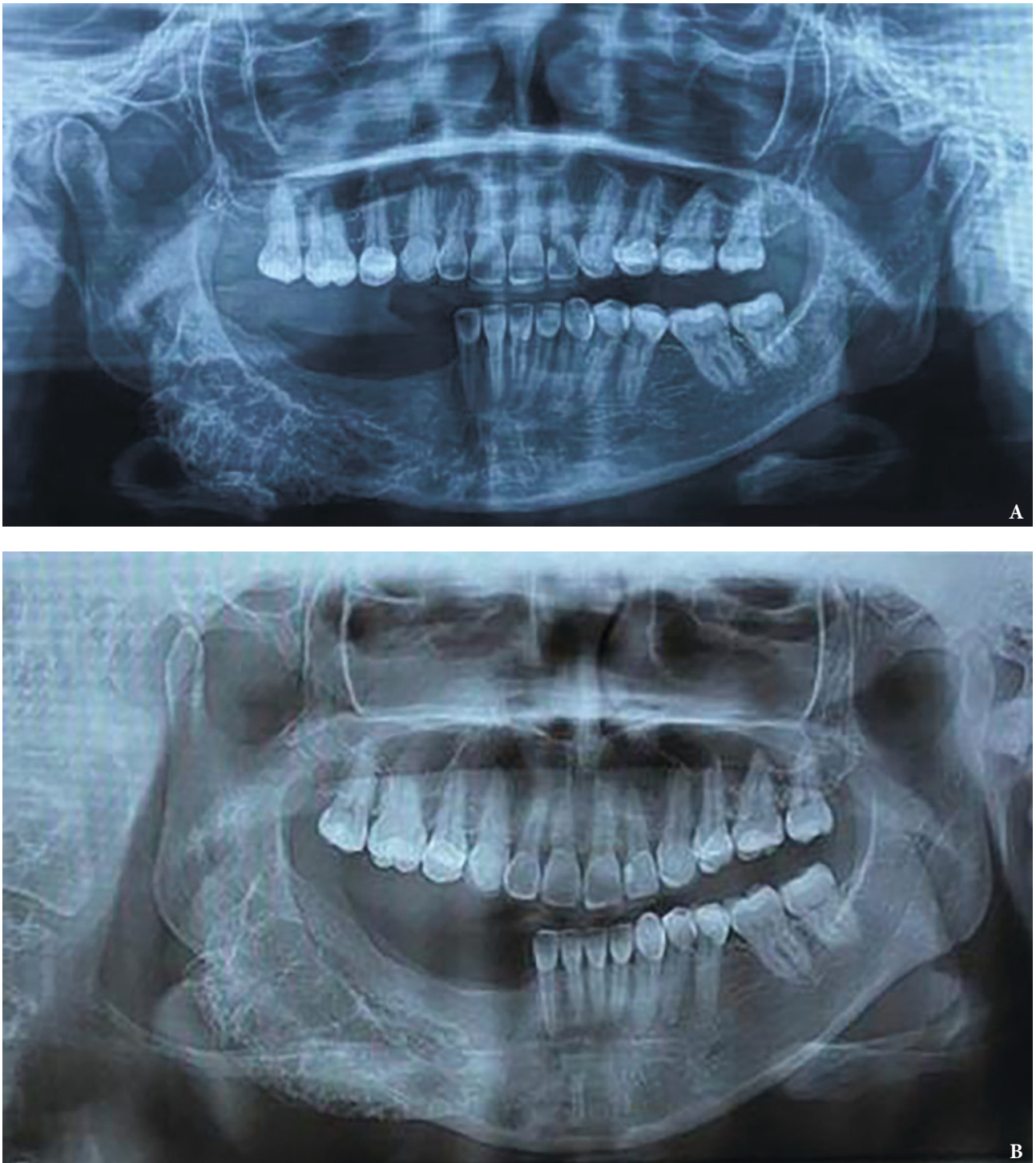


FIGURE 3. Orthopantomograms before (A) and after (B) surgery (five-year follow-up).

used in the field of maxillofacial surgery, as well as in surgical procedures carried out in the oral cavity.⁷ This type of laser is part of the group of invisible rays included in the infrared wavelength (10,600 nm) and is classified within Low-Level Therapy (LLT) due to its therapeutic effect without the use of high temperatures.⁸ Its use in oral surgery is attributed to its great affinity for high water content tissues and many other advantages that make it stand out compared to the use of the cold scalpel.⁹ Its mechanism of action is based on the soft tissues absorbing energy in the form of heat produced by the laser, which causes evaporation of intra and extracellular fluid. This, in turn, causes cell disruption and loss of 75 to 95 percent of the cell volume represented in steam. All these effects occur at a temperature of 100°C, but using higher temperatures, evaporation of the residual organic matrix can be achieved, resulting in total ablation of the soft tissue.¹⁰ This effect has been called photothermal effect and its consequences related to the collateral damage caused to cells on the periphery of the lesion, and the conservation of tissue that will be subjected to histopathological study have been extensively studied. Tuncer et al,¹¹ in their study, show that the damages caused by the CO2 laser on the margins of the removed tissue, do not represent any inconvenience for the pathologist's diagnosis. However, this mentioned disadvantage does not affect the performance of the procedure that we propose in this article. In the technique that is developed, the removal of the tissue is performed initially with curettage, trying to preserve the intact specimen for analysis. On the contrary, this gives us an advantage because what we need is this evaporation of the possible debris of the lesion that may remain in the tissue after curettage.

Among the advantages related to its use mentioned in the literature, morphological and functional recovery in the postoperative period, pain control, minimization of surgical times, and reduction of the use of sutures or flaps can be highlighted. Besides, other high relevance qualities are reported, such as minimal damage to adjacent tissue and preservation of unaffected oral tissues, which in turn prevents the compromise of essential functions such as speech and swallowing.¹² This last advantage plays a crucial role in surgical pathology, since, as previously mentioned, the procedures related to the treatment of benign lesions with aggressive behavior (such as myxoma) and malignant lesions, are usually extremely

invasive. Also, the use of the CO2 laser allows the combination of other conventional techniques for tumor resection, such as curettage.

Regarding the reported disadvantages of laser methods in general, a delay in tissue healing is mentioned, mainly justified by the fact that, when intervening with these instruments, a rupture occurs in both blood vessels and lymphatic vessels, which leads to more time being consumed in the neovascularization process.¹⁰ However, this disadvantage is widely disputed because healing times have been well studied, and in some studies, a faster healing rate is suggested. In others, the results show a delayed healing rate, while in others, it is not found statistically significant differences.¹³ Lately, the laser has been recommended to treat benign oral lesions, such as fibromas, vascular anomalies, mucoceles, ranulae, gingival hyperplasias with different causes (idiopathic or due to side effects of medications), aphthous ulcers, mucosal frenula, or tongue ties (ankyloglossia), as well as premalignant lesions such as oral leukoplakia, erythroplakia, papillomas, and lichen planus.⁹ Furthermore, various authors have reported using this instrument for the resection of malignant tumors of the oral cavity. Wang et al¹⁴ in 2001 show favorable results, with a 5-year survival rate of 88 percent in patients with cancerous lesions of the anterior two-thirds of the tongue treated with a CO2 laser. In 2002, Ishii et al¹⁵ compared the use of CO2 laser with radiotherapy, showing statistically significant differences in metastasis in favor of patients treated with laser. Luna-Ortiz et al¹⁶ in 2019 studied the behavior of cancerous lesions in the oral cavity after their resection with CO2 laser, showing a survival rate of 60 percent with different follow-up times in each patient included in the study.

So far, no cases have been reported where the use of CO2 laser has been implemented for the treatment of oral myxoma. Therefore, a possible protocol is proposed, which can serve as a conservative therapeutic option in the future but without leaving aside the risk of recurrence. Hence, it is recommended to use CO2 laser vaporization in the surgical bed after the mechanical resection of lesions that, due to their consistency, can cause incomplete removal, increasing the risk of reappearance of these lesions, as in the case of myxomas. In any case, it is recommended to conduct further research with long-term follow-ups, hoping to obtain good results. On the other hand, it is essential to emphasize that with the use of any

technique, it is crucial to carry out a periodic follow-up of the patient and even more in these cases that the use of conventional techniques is performed. Therefore, each patient's conditions must be taken into account, including their commitment to their general health, socioeconomic conditions, and ease and consistency in attending control appointments.

These aspects will play a vital role in choosing the best surgical technique that adapts to each patient's situation. Thus, in a patient with little commitment or whose conditions do not allow him to attend his controls regularly, the more invasive surgical procedures would be more indicated, since it is difficult to carry out an exhaustive control of the lesion's recurrence in this type of patient.

The age of the patient and other aspects must be considered, such as the relevance that the patient gives to his aesthetic condition. These aspects could lead us to take more conservative procedures into account with a higher priority. In this way, the treatment for each patient is individualized, and the best surgical technique is chosen according to their specific conditions.

On the other hand, although our experience has been limited and patient follow-up and data collection has been difficult, the results 5 years after the surgical procedure are very encouraging. These suggest that it may be a viable alternative for specific cases, making it clear that it is not the ideal treatment for odontogenic myxomas. The main limitation we had when it came to demonstrate the results was the limited information and the quality of the photos. However, we still believe that this alternative should be taken into account in the decision panel. It is also of great importance to continue monitoring patients and to consider other future publications that support or contradict the results.

ROLE OF CO-AUTHORS

Pauwels-Tumiñan A. (material processing).
Lozano-Morales C. (concept and design).
López J.P. (writing text, editing).
Orjuela M.P. (writing text, editing).

FUNDING

This research was funded through Hospital Universitario Fundación Santa Fe de Bogotá, Bogotá, Colombia.

CONFLICT OF INTEREST

The authors have expressed none conflict of interests.

ETHICAL APPROVAL

Not necessary.

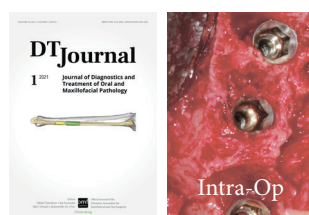INFORMED CONSENT

Informed consent was obtained from the patient.

REFERENCES

1. Thoma KH, Goldman HM. Central myxoma of the jaw. *Oral Surg Oral Med Oral Pathol* **1947**;33(7):B532–40. [https://doi.org/10.1016/0096-6347\(47\)90315-3](https://doi.org/10.1016/0096-6347(47)90315-3)
2. Naggar AK, Chan JKC, Grandis JR, Takata T, Sloatweg PJ. World Health Organization classification of head and neck tumours. 4th ed. Lyon: IARC Press. **2017**.
3. Noffke CE, Raubenheimer EJ, Chabikuli NJ, Bouckaert MM. Odontogenic myxoma: review of the literature and report of 30 cases from South Africa. *Oral Surg Oral Med Oral Pathol Oral Radiol Endod* **2007**;104(1):101–9. <https://doi.org/10.1016/j.tripleo.2007.01.026>
4. Boffano P, Gallezio C, Barreca A, Bianchi FA, Garzino-Demo P, Roccia F. Surgical treatment of odontogenic myxoma. *J Craniofac Surg* **2011**;22(3):982–7. <https://doi.org/10.1097/SCS.0b013e3182101400>
5. Khosraviani F, Ehsani S, Fathi M, Saberi-Demneh A. Therapeutic effect of laser on pediatric oral soft tissue problems: a systematic literature review. *Lasers Med Sci* **2019**;34(9):1735–46. <https://doi.org/10.1007/s10103-019-02834-0>
6. Patel CKN. Continuous-wave laser action on vibrational-rotational transitions of CO₂. *Phys Rev A* **1964**;136(5A):1187–93. <https://doi.org/10.1103/PhysRev.136.A1187>
7. Jerjes W, Hamdoon Z, Hopper C. CO₂ lasers in the management of potentially malignant and malignant oral disorders. *Head Neck Oncol* **2012**;4:17. <https://doi.org/10.1186/1758-3284-4-17>
8. Asnaashari M, Zadsirjan S. Application of laser in oral surgery. *J Lasers Med Sci* **2014**;5(3):97–107.
9. Saibene AM, Rosso C, Castellarin P, Vultaggio F, Pipolo C, Maccari A, Ferrari D, Abati S, Felisati G. Managing benign and malignant oral lesions with carbon dioxide laser: indications, techniques, and outcomes for outpatient surgery. *Surg J (N Y)* **2019**;5(3):e69–e75. <https://doi.org/10.1055/s-0039-1694735>

10. Strauss RA, Fallon SD. Lasers in contemporary oral and maxillofacial surgery. *Dent Clin North Am* **2004**;48(4):861–88. <https://doi.org/10.1016/j.cden.2004.06.005>
11. Tuncer I, Ozçakir-Tomruk C, Sencift K, Cöloğlu S. Comparison of conventional surgery and CO2 laser on intraoral soft tissue pathologies and evaluation of the collateral thermal damage. *Photomed Laser Surg* **2010**;28:75–9. <https://doi.org/10.1089/pho.2008.2353>
12. Roodenburg JLN, Witjes MJ, de Veld DC, Tan IB, Nauta JM. Lasers in dentistry 8. Use of lasers in oral and maxillofacial surgery (in Dutch). *Ned Tijdschr Tandheelkd* **2002**;109(12):470–4.
13. Garg N, Verma S, Chadha M, Rastogi P. Use of carbon dioxide laser in oral soft tissue procedures. *Natl J Maxillofac Surg* **2015**;6(1):84–8. <https://doi.org/10.4103/0975-5950.168218>
14. Wang CP, Chang SY, Wu JD, Tai SK. Carbon dioxide laser microsurgery for tongue cancer: surgical techniques and long-term results. *J Otolaryngol* **2001**;30(1):19–23. <https://doi.org/10.2310/7070.2001.20897>
15. Ishii J, Fujita K, Komori T. Clinical assessment of laser monotherapy for squamous cell carcinoma of the mobile tongue. *J Clin Laser Med Surg* **2002**;20(2):57–61. <https://doi.org/10.1089/104454702753768025>
16. Luna-Ortiz K, Hidalgo-Bahena SC, Muñoz-Gutiérrez TL, Mosqueda-Taylor A. Tumors of the oral cavity: CO2 laser management. *Med Oral Patol Oral Cir Bucal* **2019**;24(1):e84–e88. <https://doi.org/10.4317/medoral.22811>



GUEST

Private Practice, Implantology, and Continuing Professional Development

Ivan V. Nagorniak

Strength and growth come only through continuous effort and struggle.

—Napoleon Hill

American self-help author

Continuing professional development (CPD) (synonym: *continuing education* [CE])¹ in Ukrainian stomatology reached a new level in 2019 by the Order (# 446, dated February 22) entitled “Some issues of CPD of doctors” was officially published.² According to new Order of Ministry of Healthcare of Ukraine,³ every physician-stomatologist must score:

1. 50 CPD points obtained in 2020 or 2021 for certification in 2021.
2. 100 CPD points obtained in 2020 and 2021 for certification in 2022.
3. 150 CPD points obtained in 2020, 2021, and 2022 for certification in 2023.

The CPD points can be scored for a wide variety of activities, like: 1) participation in scientific and practical conference, congress or symposium, 2) distance (digital) learning using electronic learning resources, 3) thematic training (professional schools,

seminars, workshops, etc.), 4) study or internship at a university or health care institution – in Ukraine or abroad, 5) publication of an article in a peer-review journal, etc.³

Attestation is needed 1) to continue (or to obtain a right) practicing in a certain specialty, 2) to confirm the assigned qualification category or a new higher one assignment.⁴

The Procedure for attestation of doctors notes that it is aimed to improve the activities of health care institutions of all forms of ownership.⁴ Physician-stomatologist-surgeon (ie, oral surgeon) who moves own private surgical practice forward is more than interested in obtaining the *Second, First and Highest qualification category*. Special motivation of the surgeon to obtain the categories is usually driven by the wish to perform dental implantation (Fig 1) and bone grafting procedures. For example, according to the instructions (approved by the order of the Ministry of Health of Ukraine) the *physician-stomatologist-surgeon of the Second qualification category* among other surgical procedures must be able to perform dental implantation and related manipulations within the alveolar process without additional bone grafting.⁵ Also, the instructions

Oral Surgeon (Physician-Stomatologist-Surgeon), PhD
Private Practice, 6-G Andruschenka Street, Office 6
Kyiv 01135, Ukraine
E-mail: ivan.nagorniak@gmail.com

Please cite this article as: Nagorniak IV. Private practice, implantology, and continuing professional development. *J Diagn Treat Oral Maxillofac Pathol* 2021;5(1):10–2.

The abbreviation 'Intra-Op' at the upper right icon means that article contains intraoperative photographs.

Paper received 21 January 2021
Accepted 23 January 2021
Available online 29 January 2021

<https://dx.doi.org/10.23999/j.dtomp.2021.1.3>

© 2021 OMF Publishing, LLC. This is an open access article under the CC BY license (<http://creativecommons.org/licenses/by-nc/4.0/>).

for the *physician-stomatologist-surgeon of the First qualification category* note that among other surgical procedures the surgeon must be able to perform dental implantation and related manipulations using bone grafting materials and intraoral blocks.⁶ *Physician-*

stomatologist-surgeon of the Higher qualification category must be able to perform all types of dental implantation and related manipulations within and outside the alveolar process using extraoral blocks and fixation of exoprostheses.⁷

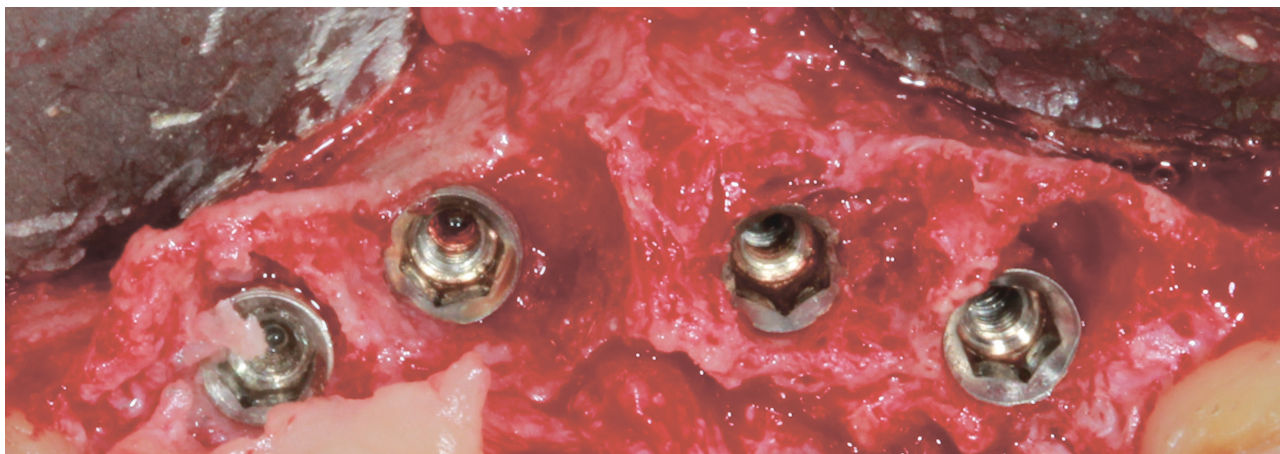


FIGURE 1. Dental implantation at the anterior maxilla.

Publication of the scientific paper (case report,⁸ case series, images' article,⁹ viewpoint,¹⁰ etc.) is a great option for every stomatologist in Ukraine as it will bring 20 or 30 CPD points depending it's a publication in Ukrainian or English language peer-reviewed journal (Table 1).³

TABLE 1. Number of Scored CPD Points for the Published Article.

| Ukrainian Language Peer-reviewed Journal | English Language Peer-reviewed Journal |
|--|--|
| 20 CPD points | 30 CPD points |

Analyzing CPD in other countries and CPD's relation with journals it's worth to notice that, for example, *Australian Dental Journal* (Impact Factor: 1.401; 2019 Journal Citation Reports (Clarivate Analytics): 66/91 (Dentistry, Oral Surgery & Medicine)¹¹ which has an oral and maxillofacial surgery section, also publishes CPD Quiz with scoring the points for the readers.¹²

Moreover, some journals, like *Oral Diseases* journal (Impact Factor: 2.613; 2019 Journal Citation Reports (Clarivate Analytics): 19/91 (Dentistry, Oral Surgery & Medicine),¹³ even score points for the review of the articles.

In summary, it's become more and more popular worldwide to score CPD points for the physicians who read, review the articles or who publish the peer-reviewed papers, like in Ukraine from 2019. In my opinion, this way of rewarding readers, reviewers and authors has an extremely positive effect on the growth of doctors as professionals, their domestic/international cooperation and the development of specialties and journals.

REFERENCES

1. Sambrook P, Goss A. Continuing education for oral and maxillofacial surgeons--new expectations. *Ann R Australas Coll Dent Surg* **1996**;13:193–7.
2. Order of the Ministry of Health of Ukraine dated 22.02.2019 # 446 "Some issues of continuous professional development of doctors" [document on the internet]; February 22, **2019** [cited 2021 Jan 21]. Available from: <https://moz.gov.ua/article/ministry-mandates/nakaz-moz-ukraini-vid-22022019--446-dejaki-pitannja-bezperernogo-profesijnogo-rozvitku-likariv>
3. How are the points of continuing professional development for doctors scored: examples [document on the internet]; February 22, **2019** [cited 2021 Jan 21]. Available from: <https://moz.gov.ua/article/for-medical-staff/jak-narahovujutsja-bali-bezperernogo-profesijnogo-rozvitku-likarjam>

- prikladi
4. Procedure for attestation of doctors [document on the internet]; February 29, **2019** [cited 2021 Jan 21]. Available from: https://moz.gov.ua/uploads/2/11598-dn_20190222_446_dod_por.pdf
 5. Job instruction: physician-stomatologist-surgeon of the second qualification category [document on the internet]; September 15, **2019** [cited 2021 Jan 21]. Available from: https://www.borovik.com/index_instruction.php?Gins=wcmn&lang_i=1
 6. Job instruction: physician-stomatologist-surgeon of the first qualification category [document on the internet]; September 15, **2019** [cited 2021 Jan 21]. Available from: https://www.borovik.com/index_instruction.php?Gins=wcm1&lang_i=1
 7. Job instruction: physician-stomatologist-surgeon of the higher qualification category [document on the internet]; September 15, **2019** [cited 2021 Jan 21]. Available from: https://www.borovik.com/index_instruction.php?Gins=wcmq&lang_i=1
 8. Nagorniak KY, Nagorniak IV. Buccal plate preservation at anterior maxilla using immediate implant placement with a 2.0-mm gap technique based on spontaneous bone healing: case report. *J Diagn Treat Oral Maxillofac Pathol* **2018**;2(4):151–4. <https://doi.org/10.23999/j.dtomp.2018.4.2>
 9. Nagorniak IV. Clinical appearance of lateral incisive canal. *J Diagn Treat Oral Maxillofac Pathol* **2019**;3(8):200. <https://doi.org/10.23999/j.dtomp.2019.8.4>
 10. Nagorniak IV. Sinus lift: analysis of Schneiderian membrane perforations. *J Diagn Treat Oral Maxillofac Pathol* **2020**;4(10):191–3. <https://doi.org/10.23999/j.dtomp.2020.10.2>
 11. Australian Dental Journal [document on the internet]; January 21, **2020** [cited 2021 Jan 21]. Available from: <https://onlinelibrary.wiley.com/journal/18347819>
 12. CPD Quiz: multiple choice questions [document on the internet]; December 22, **2020** [cited 2021 Jan 21]. Available from: <https://onlinelibrary.wiley.com/doi/10.1111/adj.12805>
 13. Oral Diseases [document on the internet]; January 21, **2020** [cited 2021 Jan 21]. Available from: <https://onlinelibrary.wiley.com/journal/16010825>



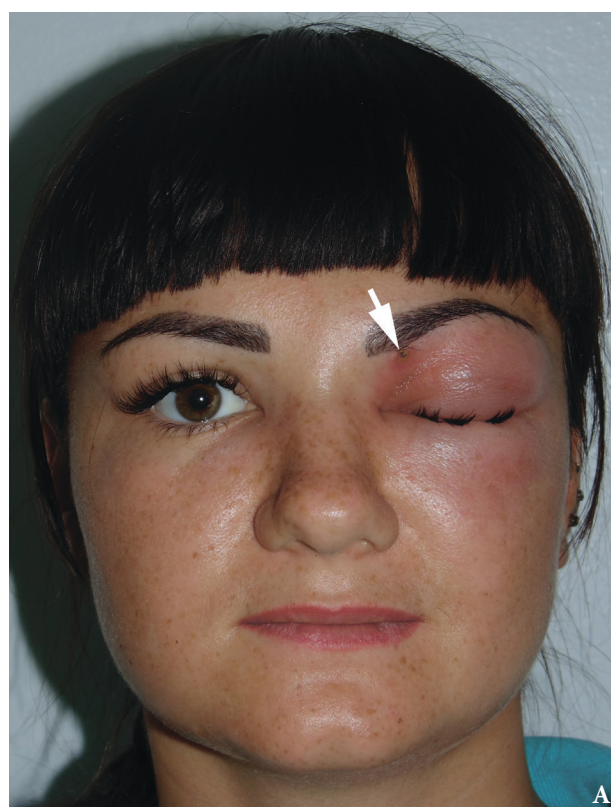IMAGES

Camilo Mosquera, DDS, *Editor*

Periorbital Abscessing Furuncle

Olha S. Cherniak^a & Ievgen I. Fesenko^{b,c}

After plucking eyebrows a 27-year-old female patient noted left eyelids swelling, redness, increasing of pain and body temperature with no visual deficits. The examination showed the presence of crust (Panel A: arrow) just below the medial part of the left eyebrow. Ultrasonography (model HD11 XE, Philips) was performed using linear transducer (frequency range: 12-3 MHz) in the supine position of the patient. Firstly, a comparative gray scale ocular ultrasound (US) of the right (Panel B) and left eye (Panel C) showed only a soft tissue hypoechoic swelling anteriorly to the left eye. Increased distance (due to edema) between skin surface and cornea is labeled by *vertical line*. But placing the transducer in the projection of the crust and parallel to the left eyebrow (Panel D) the gray scale US (Panel E) showed fluctuated nearly anechoic heterogenic area with ill-defined margins (indicated by '+' and 'x' calipers) measured 1.21 × 1.06 cm. Such data suggested presence of limited purulent content. *Furuncle* (also known as *boil*) is a single hair follicle-associated bacterial infection (in 96 to 98 percent caused by *Staphylococci* [in 88–90 percent – by *Staphylococcus aureus* and in 6–10 percent – by *Staphylococcus epidermidis*])² of the perifollicular



Kyiv, Ukraine

^a Physician of Ultrasound Diagnostics; Head, Department of Ultrasound, Regional Diagnostic Center, Kyiv Regional Clinical Hospital.
cherniak.os@gmail.com

^b Physician-Stomatologist-Surgeon, Physician of Ultrasound Diagnostics, Center of Maxillofacial Surgery and Dentistry, Kyiv Regional Clinical Hospital (place of work at moment of material collection).
i.i.fesenko@dtjournal.org

^c PhD, Associate Professor, Department of Oral and Maxillofacial Surgery, Private Higher Educational Establishment "Kyiv Medical University."

Please cite this article as: Cherniak OS, Fesenko II. Periorbital abscessing furuncle. *J Diagn Treat Oral Maxillofac Pathol* 2021;5(1):13–4.

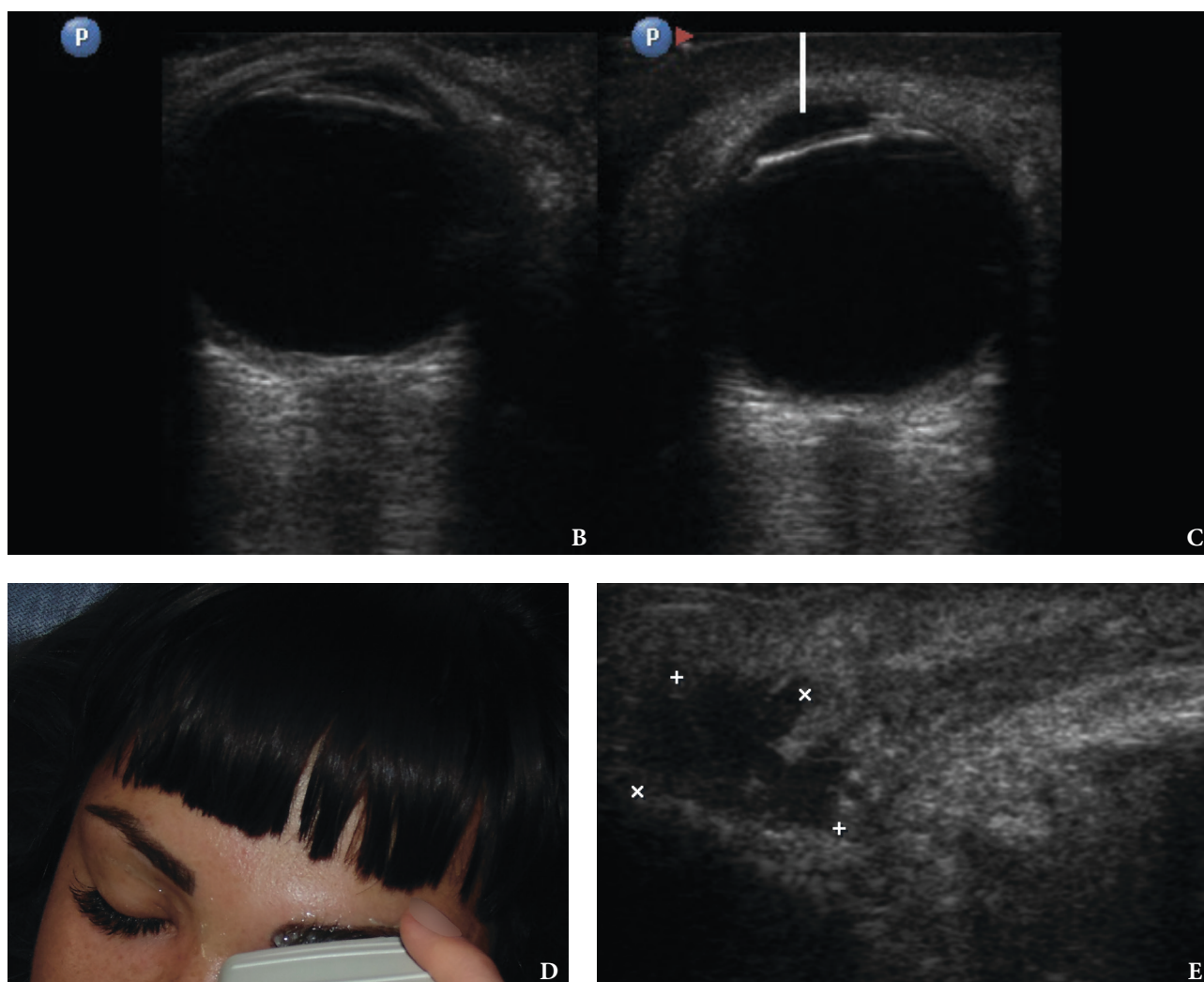
Paper received 5 January 2021

Accepted 14 January 2021

Available online 29 January 2021

<https://dx.doi.org/10.23999/j.dtmp.2021.1.4>

© 2021 OMF Publishing, LLC. This is an open access article under the CC BY license (<http://creativecommons.org/licenses/by-nc/4.0/>).



tissue.^{1,3} Also, *furuncle* is named in the literature as acute purulent-necrotic inflammation of the single hair follicle and surrounding tissue.² Abscessing (ie, fluctuating) furuncles require its drainage what was done in our case under the local anesthesia with a several days rubber drainage placement.^{1,2} Intramuscular ceftriaxone was prescribed (2.0 g daily) and complete recovery was noted at 7-day follow-up. Summarizing, orbital US continues to prove its efficacy in the wide variety of orbital inflammatory cases^{4,5} becoming a viable tool during the different stages of treatment. ■ DTJournal

REFERENCES

1. Lin HS, Lin PT, Tsai YS, Wang SH, Chi CC. Interventions for bacterial folliculitis and boils (furuncles and carbuncles). *Cochrane Database Syst Rev* **2018**;2018(8):CD013099. <https://doi.org/10.1002/14651858.CD013099>
2. Tymofieiev OO. Maxillofacial surgery and surgical dentistry [Russian]. Kyiv, Ukraine: Medicine; **2020**.
3. Lopez FA, Lartchenko S. Skin and soft tissue infections. *Infect Dis Clin N Am* **2006**;20(4):759–72. <https://doi.org/10.1016/j.idc.2006.09.006>
4. Mair MH, Geley T, Judmaier W, Gassner I. Using orbital sonography to diagnose and monitor treatment of acute swelling of the eyelids in pediatric patients. *AJR Am J Roentgenol* **2002**;179(6):1529–34. <https://doi.org/10.2214/ajr.179.6.1791529>
5. McIlrath ST, Blaivas M, Lyon M. Diagnosis of periorbital gas on ocular ultrasound after facial trauma. *Am J Emerg Med* **2005**;23(4):517–20. <https://doi.org/10.1016/j.ajem.2004.10.001>

TANTUM VERDE®

QUICK RELIEF FROM PAIN
AND INFLAMMATION IN THE
MOUTH AND THROAT¹

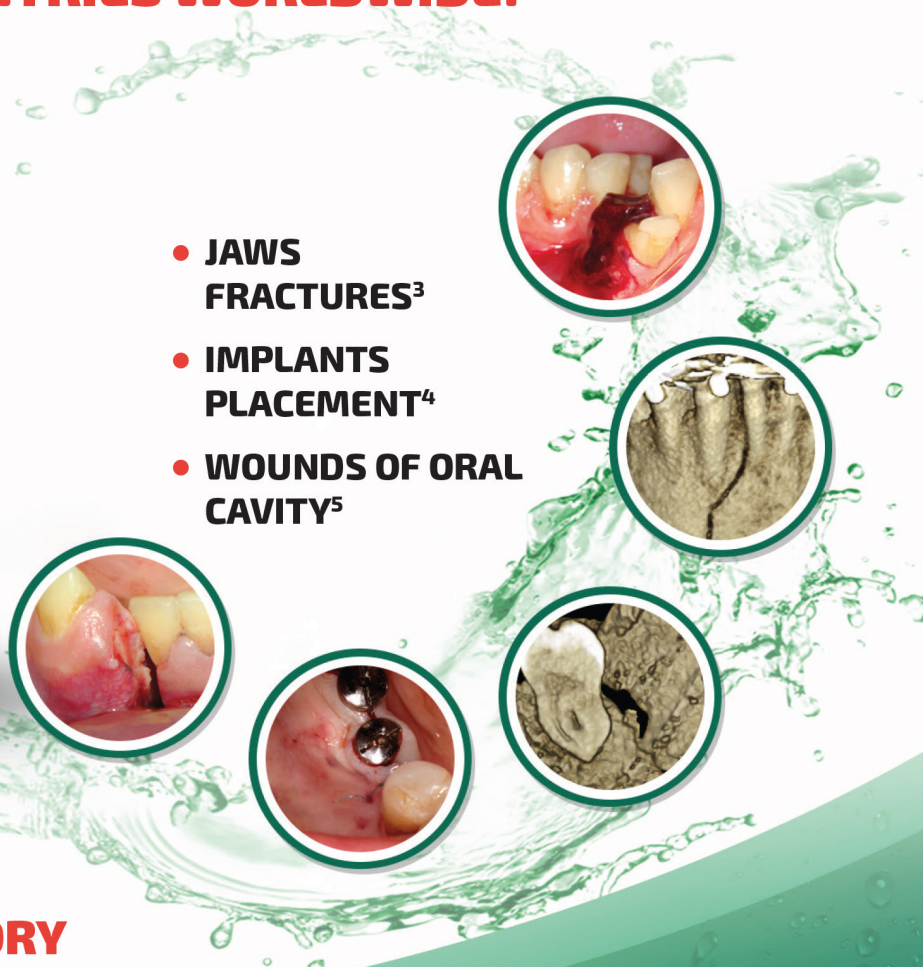**AN INTEGRAL COMPONENT OF THE TREATMENT
OF PAIN AND INFLAMMATION IN THE ORAL CAVITY
IN 60 COUNTRIES WORLDWIDE!²**



Reg. № UA/3920/01/01

**LOCAL ANESTHETIC
AND ANTI-INFLAMMATORY
EFFECT¹**

- **JAWS FRACTURES³**
- **IMPLANTS PLACEMENT⁴**
- **WOUNDS OF ORAL CAVITY⁵**



SUMMARY OF PRODUCT CHARACTERISTICS

NAME OF THE MEDICINAL PRODUCT. Tantum Verde 0.15% mouthwash. **QUALITATIVE AND QUANTITATIVE COMPOSITION.** Each 100 ml contains: active ingredient: benzydamine hydrochloride 0.15 g (equivalent to 0.134 g of benzydamine). **Therapeutic indications.** Treatment of symptoms such as irritation/inflammation including those associated with pain in the oropharyngeal cavity (e.g. gingivitis, stomatitis and pharyngitis), including those resulting from conservative or extractive dental therapy. **Posology and method of administration.** Pour 15 ml of Tantum Verde mouthwash into the measuring cup, 2-3 times per day, using it either at full concentration or diluted. If diluted, add 15 ml of water to the graduated cup. Do not exceed the recommended dosage. **Contraindications.** Hypersensitivity to benzydamine or to any of the excipient. **PHARMACOLOGICAL PROPERTIES. Pharmacodynamic properties.** Pharmacotherapeutic group: Stomatologic drugs: other agents for local oral treatment, ATC code: A01AD02. Clinical studies demonstrate that benzydamine is effective in relieving suffering from localised irritation of the mouth and pharynx. In addition, benzydamine possesses a moderate local anaesthetic effect. **Pharmacokinetic properties. Absorption.** Absorption through the oropharyngeal mucosa is demonstrated by the presence of measurable quantities of benzydamine in human plasma. These levels are insufficient to produce systemic effects. **Distribution.** When applied locally, benzydamine has been shown to accumulate in inflamed tissues where it reaches effective concentrations because of its capacity to penetrate the epithelial lining.

Information about medicines. Information for health care professionals for use in professional activities.

1. Інструкція для медичного застосування лікарського засобу Тантум Верде®, розчин для ротової порожнини, РПН № UA/3920/01/01, затверджено Наказом Міністерства охорони здоров'я України № 636 від 01.10.2015.

2. <http://www.angelini-pharma.com/wps/wcm/connect/com/home/Angelini+Pharma+in+the+world/>

3. Тимофеев А.А. и др. "Особенности гигиены полости рта для профилактики воспалительных осложнений при переломах нижней челюсти". Современная стоматология 2015;1(75):52-8.

4, 4.5. Tymofiejew O.O. et al "Prevention of inflammatory complications upon surgeries in maxillofacial region". J Diagn Treat Oral Maxillofac Pathol. 2017;1:105-12.

Clinical and CT images are courtesy of: Ievgen Fesenko (Department of Oral & Maxillofacial Surgery, PHEI "Kyiv Medical University", Kyiv, Ukraine), Oleg Mastakov ("SCIEDECE—Scientific Center of Dentistry & Ultrasound Surgery" Kyiv, Ukraine)



04119, Kiev, Melnikova str. 83D, of. 404.
Tel.: (044) 538-01-26
Fax: (044) 538-01-27

