

Efficacy of Cone Beam Computed Tomography (CBCT) and Periapical (PA) Radiography in Endodontic Diagnosis and Treatment Planning*

Hala Zakaria^{1,*}, Caroline L. Duarte Puerto², Hassan Al Basri³, Mohammed Fadhul⁴

RAK College of Dental Sciences, RAK Medical and Health Sciences University, Ras Al Khaimah, United Arab Emirates (UAE)

¹ PhD, Associate Professor of Oral Radiology, Diagnosis & Medicine

² Assistant Professor of Orthodontics

^{3,4} Graduate Students

ABOUT ARTICLE

Article history:

Paper received 03 June 2018

Accepted 18 June 2018

Available online 30 June 2018

Keywords:

Cone beam computed tomography (CBCT)

Periapical (PA) radiography

Bone defects

Alveolar bone loss

Periapical lesions

Vertical root fracture (VRF)

Field of view (FOV) in CBCT

ABSTRACT

Aim.

The benefits and limitations of cone beam computed tomography (CBCT) over conventional periapical (PA) radiographs have been studied by many authors since many years ago. The subtle point of negotiation is to understand to what extent the use of CBCT over periapical can have a positive influence on initial radiographic diagnosis in different dental specialties in last recent researches. This article research was achieved by identifying which modality is superior in diagnostic accuracy and outlining what can affect the efficacy of CBCT and PA radiography in the assessment of early periapical lesions, vertical root fractures and bone defects respectively.

Material and Methods.

A retrospective study was conducted with the use of two different electronic databases were search between years 2006–2017, PubMed Central® (PMC), and ProQuest, with a strict inclusion and exclusion criteria. Search was limited to English and articles that compared CBCT to PA radiography with the inclusion of the factors studied. The search strategy included a self made formula for the insertion of keywords into the search engine. Formula was to either enter one radiographic technique followed by the factor being studied, or two radiographic techniques followed by one factor being studied. Articles that appeared in more than one database were considered as duplicates and were only considered once. Two examiners (Hassan Al Basri (HAB) and Mohammed Fadhul (MF)) searched for the articles on the search engines. HAB was assigned to search in PubMed, while MF explored ProQuest. A total of 262 title/abstracts were identified through the data base search engines. Most of the articles were found on PubMed (n = 189) while the other were identified on ProQuest (n = 173). Relevant articles by title/abstract were all recorded and categorized according to the relevance to the factor being studied as shown in the results (n = 107).

Results.

The total number of articles were categorized according to the factor being studied (n = 39) to end up with (n = 15) for periapical lesions, (n = 13) for vertical root fracture and (n = 11) for bone defects. Each category had its own table for analysis and data recording as shown in tables and diagrams. The 13 out of 15 articles concluded that CBCT is superior to PA radiography in, while the rest (n = 2) concluded that no difference was seen between the two modalities in the detection of periapical lesions. 10 out of 13 articles for vertical root fracture and 5 out of 11 in bone defects also concluded that CBCT is superior to PA in the detection of each factor respectively. Pie charts were used to illustrate these differences.

Conclusion.

The main findings of this study demonstrate that with in all three factors studied, the majority of studies emphasized that CBCT was superior to periapical radiography.

Despite the limitations of the review conducted, evidence suggests that cone beam computed tomography is superior to periapical radiography in image quality and diagnostic. However, it can be concluded that the specifications like field of view and voxel size affect the quality of CBCT images and therefore can affect its ability to detect periapical lesions, vertical root fractures and bone defects when compared to periapical radiographs. However, dental clinicians should be cautious with further search regarding the radiation dose of CBCT.

© 2018 OMF Publishing, LLC. This is an open access article under the CC BY licence (<http://creativecommons.org/licenses/by-nc/4.0/>).

* This manuscript has not been presented

* Corresponding author. Department of Oral Radiology, Diagnosis & Medicine in RAK College of Dental Sciences. RAK Medical & Health Sciences University. Khuzam Road, Seih Al Burairat, Ras Al Khaimah 12973, United Arab Emirates (UAE). Tel.: +971 7 2222593 (130) Fax: +971 7 2222634 E-mail address: hala.zakaria@rakmhsu.ac.ae (Hala Zakaria)

<http://dx.doi.org/10.23999/j.djomp.2018.2.1>.

Introduction

In dentistry and oral and maxillofacial surgery, clinical examination with radiographic images is essential to end up with an accurate preoperative diagnosis. Radiography in dentistry has been for many years a building stone not

only an imaging tool, but a method that aids clinicians in accurate preoperative diagnosis. For several years clinicians have used a two dimensional periapical (PA) radiographs as it provides an acceptable imaging, due to it being cost effectiveness and exposes patients to little radiation. Recently three dimensional images were provided by cone beam computed tomography, which enhanced the level of diagnosis by providing a more accurate representation of the anatomy and enhanced image quality.

The problem with radiology is that it affects diagnosis significantly. Diagnosis in return effects the treatment plan or choice. Likewise, it's very important for radiographic modalities to provide accurate information. Incorrect

image assessment can effect or even change treatment decisions. Since CBCT still exposes patient to more radiation, caution should be taken ahead of referral for these images. Only after PA imaging has been taken, CBCT can be indicated as these images will give more details. This raises the question of to what extent is it superior to PA in the diagnosis of periapical lesions, vertical root fractures and bone defects.

The purpose of this study is to identify to what extent CBCT provides more accurate diagnosis (Fig 1) when compared to periapical radiography, and what are the limitations of each modality carried out in the diagnosis of periapical lesions, vertical root fractures and bone defects.

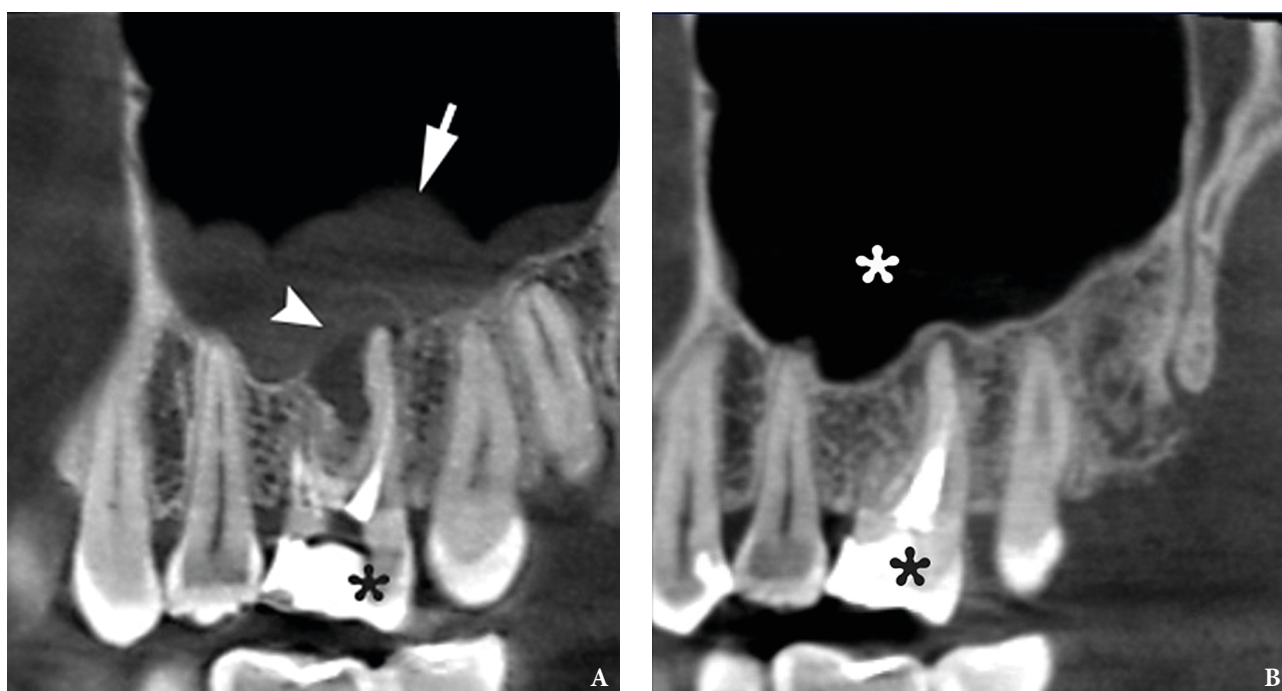


FIGURE 1. A – A sagittal CBCT scan in a 25-year-old lady before endodontic retreatment shows periapical lesion (arrowhead) around the apices of a tooth 1.6 (asterisk) and chronic maxillary sinusitis (arrow). **B** – A 8-month follow-up sagittal CBCT scan shows no signs of periapical lesion around the apices of a tooth 1.6 (black asterisk) and no chronic inflammation in the maxillary sinus (white asterisk). Images of **Figure 1** are courtesy of Dr. Mariia A. Zimina, Zimina Dental Clinic, Kyiv, Ukraine.

Background Literature

Radiographic imaging has helped many dental practitioners to envision what can't be seen clinically by the naked eye. Radiography has been used in dentistry for many years and has proved to be an imperative diagnostic tool in dental treatment planning (Shah *et al*, 2014) [1]. The dependence of radiography in surgery, endodontics, oral pathology and restorative dentistry remains essential, and in some parts of the world is mandatory by law (van der Sanden *et al*, 2016) [2]. Conventional periapical radiography has been the most commonly used image modality in many clinics, displaying two dimensional images of three dimensional structures (Butaric *et al*, 2010) [3]. However, the quality of their images is very challenging for practitioners, as minute details in these images can be hampered due to

image noise and the inability of the radiograph to take three-dimensional images (Uraba *et al*, 2016) [4]. Likewise, recently cone beam conventional computed tomography came to fruition to provide a three-dimensional image of the same structure, providing better image quality and more valuable information to the dental practitioner (Gurtu *et al*, 2014) [5]. While it remains the most commonly used radiographic method in dental practice, the limitations of periapical radiographs are very significant as they are shown to compress a three dimensional anatomy, create geometric anomalies and anatomical noise (Meena *et al*, 2014) [6]. Research has proven that a higher percentage of misdiagnosis occurs in endodontics diagnoses when using conventional periapical radiographs as compared to CBCT which is considered as the standard of care (Peters and Peters, 2012) [7]. When CBCT was first introduced,

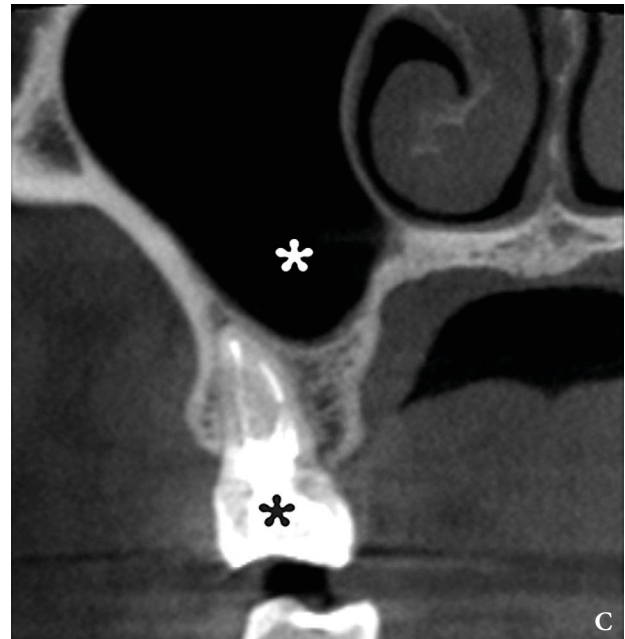
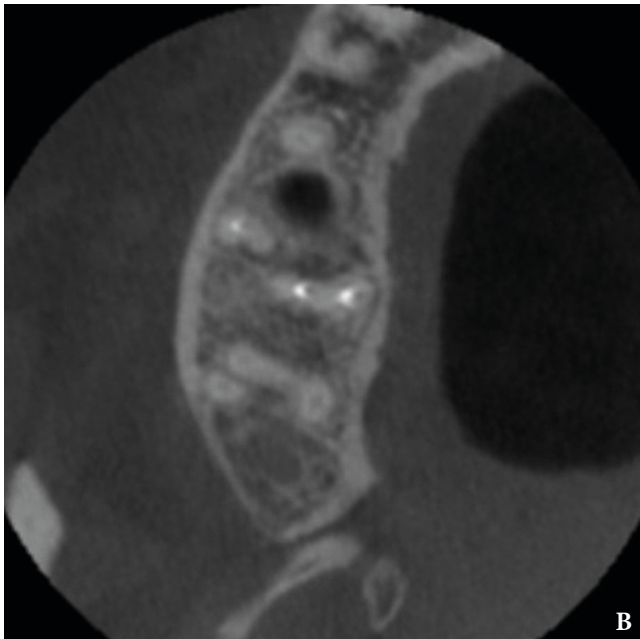
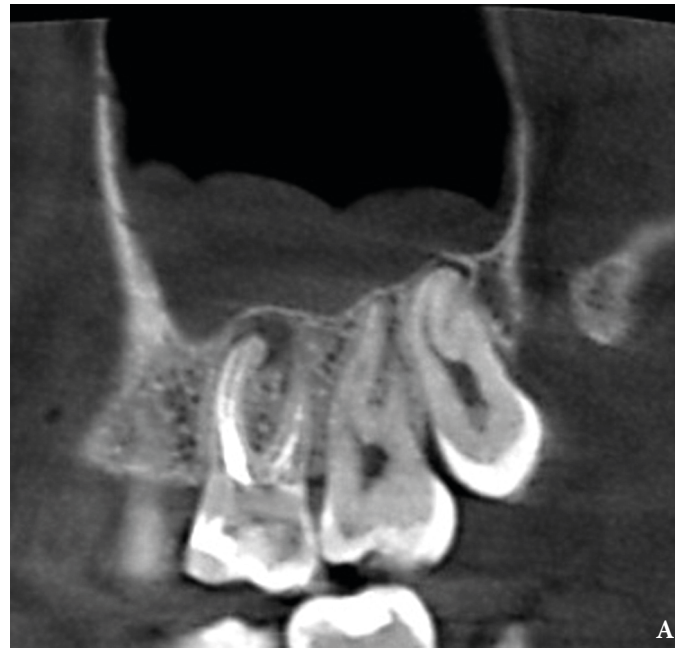

FIGURE 2. (A) Another sagittal CBCT scan of the patient from **Figure 1** before endodontic retreatment. An axial (B) and coronal (C) CBCT scans 8-month after endodontic retreatment of the tooth 1.6 (black asterisk) shows no signs of chronic inflammation in the maxilla and maxillary sinus (white asterisk). Images of **Figure 2** are courtesy of Dr. Mariia A. Zimina, Zimina Dental Clinic, Kyiv, Ukraine.

sectional images were produced, allowing better visualization by means of angles and quality. A study of Mota de Almeida *et al* (2014) [8], proved that the use CBCT has a substantial positive influence on treatment planning in endodontics. Additionally, some authors has also reported CBCT to be more effective than periapical radiographs especially in detecting root canal anatomy. However, others studies have shown that the superior abilities of CBCT were not of significant value especially in detecting the internal anatomy of mandibular incisors (Assadian *et al*, 2016) [9]. While studies have outlined the benefits of

CBCT over periapical radiography, a direct comparison to this effectiveness has not been conducted. When CBCT was first introduced, sectional images were produced, allowing better visualization by means of angles and quality. The benefits and limitations of CBCT over conventional periapical radiographs have been studied by many authors. The subtle point of negotiation is to understand to what extent the use of CBCT over periapical can have a positive influence on initial radiographic diagnosis in different dental specialties. This research aims to identify whether the use of CBCT would affect the preliminary diagnosis for

different dental cases when compared to periapical images.

Material and Methods

1. SEARCH STRATEGY

The following electronic databases were search between 2006–April 2017: PubMed and ProQuest. To find additional studies a hand selective search was done of the reference lists on the final set of retrieved articles. The search strategy included a self made formula for the insertion of keywords

into the search engine. **Diagram 1** explains this procedure. These keywords included “Cone Beam Computed Tomography” or “CBCT”, “Periapical Radiograph” or “PA”, “Digital Radiograph”, “Conventional Radiographs”, “Periapical Lesions”, “Vertical Root Fracture” or “VRF”, “Alveolar Bone Loss” and “Bone Defects”. The formula was to either enter one radiographic technique followed by the factor being studied, or two radiographic techniques followed by one factor being studied. The diagram presents the formula as such.

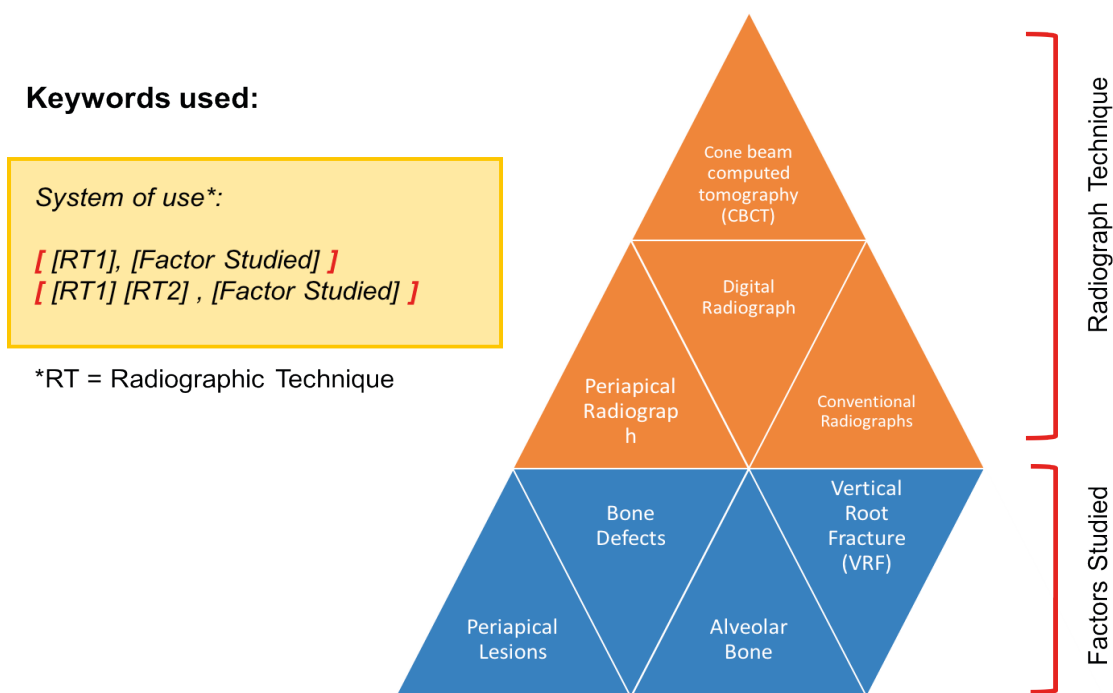


Diagram 1. The diagram above outline the formula used (yellow box) to insert the keywords (pyramid). The key words consist of two parts, the radiographic techniques (orange) and the factors studies (blue). Each word was inserted by the use of the formula into the database search engine.

Articles that appeared in more than one database were considered as duplicates and were only considered once. Two examiners (Hassan Al Basri (HAB) and Mohhamed Fadhul (MF)) searched for the articles on the search engines. HB was assigned to search in PubMed, while MF explored ProQuest.

2. INCLUSION AND EXCLUSION CRITERIA

The table bellow (Table 1) outlines the inclusion and exclusion criteria that were used to include and exclude studies as such. In vivo and in vitro studies were included with the exclusion of case reports case studies,

TABLE 1. The Criteria for Included Research

Inclusion Criteria	Exclusion Criteria
Articles from 2006 till 2017	Studies that only reviewed CBCT machines without periapical
English only	Studies outside the factors studied
Abstract that contain one or more of the keywords in the study	Case studies
Interventions: only articles that compared CBCT to periapical radiography (conventional or digital)	Case reports
Outcome measures: only studies that examined periapical lesions, vertical root fracture (VRF) and bone defects.	
Full-text articles only	

review articles, textbooks and editorials respectively. Nevertheless, only studies that compared CBCT to periapical radiography were included. Any studies that compared the modalities outside the factor being studied (periapical lesions, vertical root fracture and bone defects) were excluded. Articles only in English language and full text articles were included.

3. DATA COLLECTION AND PROCESSING

A total of 262 title/abstracts were identified through the data base search engines. Most of the articles were found

on PubMed (n = 189) while the other were identified on ProQuest (n = 173). Relevant articles by title/abstract were all recorded bellow and categorized according to the relevance to the factor being studied as shown below (n = 107).

These were then further evaluated according to the inclusion and exclusion criteria by reading the titles/abstracts. After reading some reference lists (n = 6) were added to end up with (n = 39) as the final number of articles reviewed in this study. The **Diagram 2** shows the flow process of articles and how they were recruited:

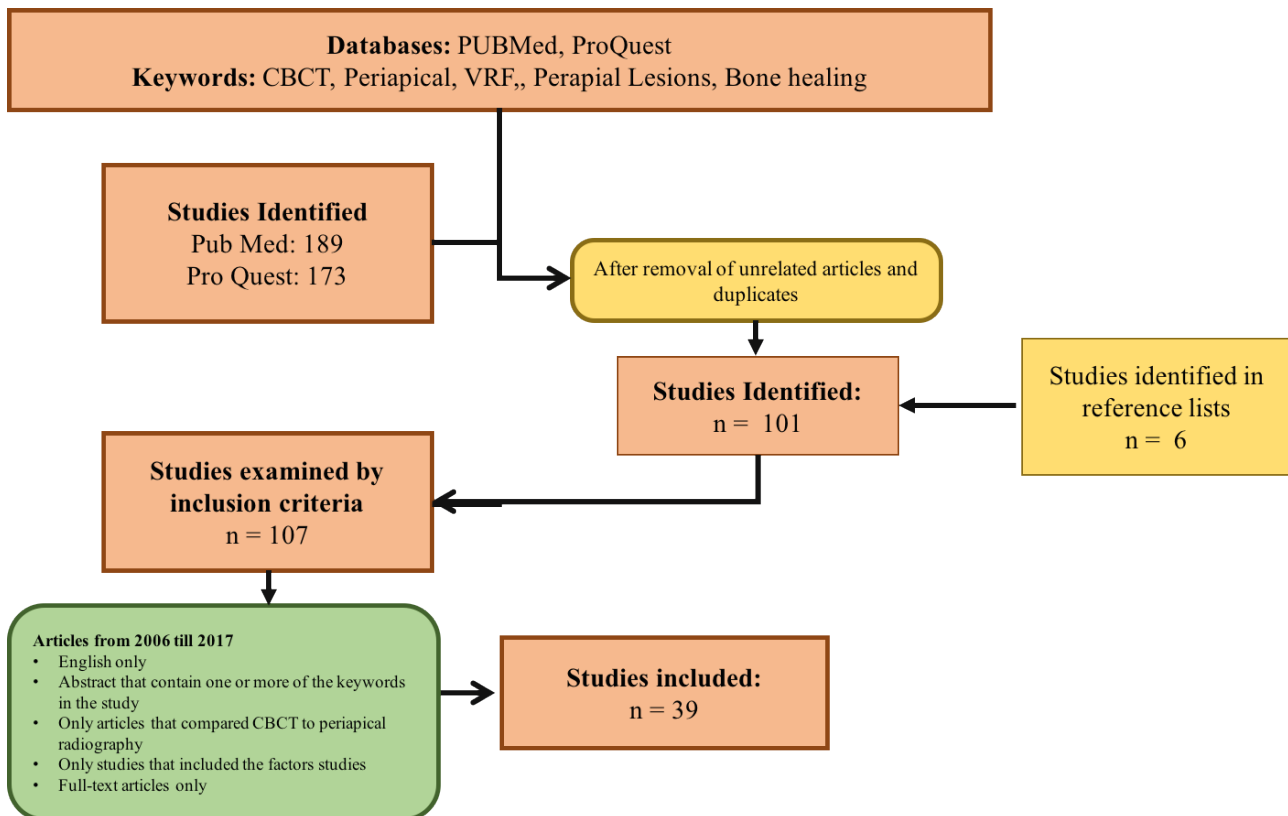


Diagram 2. The diagram is a flow diagram and represent the literature search from the initial time to the final number of articles concluded.

The total number of article (n = 39) were categorized according to the factor being studied to end up with (n = 15) for periapical lesions, (n = 13) for vertical root fracture (**Fig 3**) and (n = 11) for bone defects. Each category had its own table for analysis and data recording as shown below (**Tables 2-4**).

Results

The total amount of articles (n = 39) were categorized according to the factor being studied and were classified between *in vivo* and *in vitro* studies. In articles that investigated periapical lesions, the majority of the studied were *in vivo* (n = 11) while the remaining were *in vitro* (n = 4). This was different in the case of articles that investigated vertical root fracture and bone defects were

the majority of the studies were *in vitro* studies (n = 12) (n = 10) while the remaining were *in vivo* (n = 1) (n = 1) respectively. The **Table 5** summarizes this as outlined.

PART 1: METHODOLOGY PERIAPICAL LESIONS

The articles in this category had similar methods in data collection; the main changes included the number of sample, observers and the types of machines used. 3 articles have studied induced periapical lesions while 12 examined pathological periapical lesions in real patients. Detailed information on these differences is presented in **Table 6**.

VERTICAL ROOT FRACTURE

Since the majority if the articles in this factor were *in vitro* studies. The differences included different methods

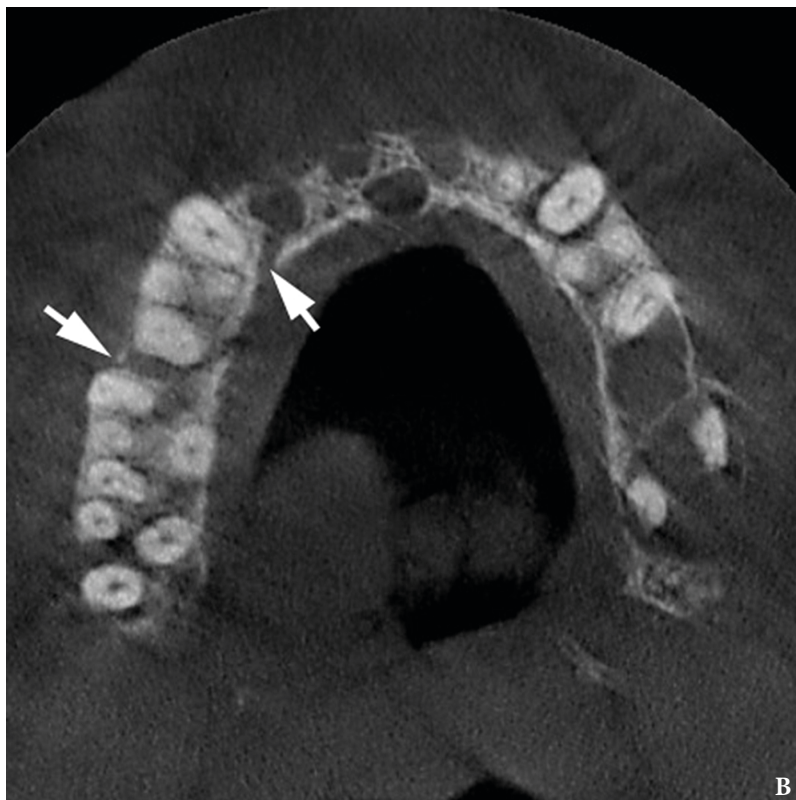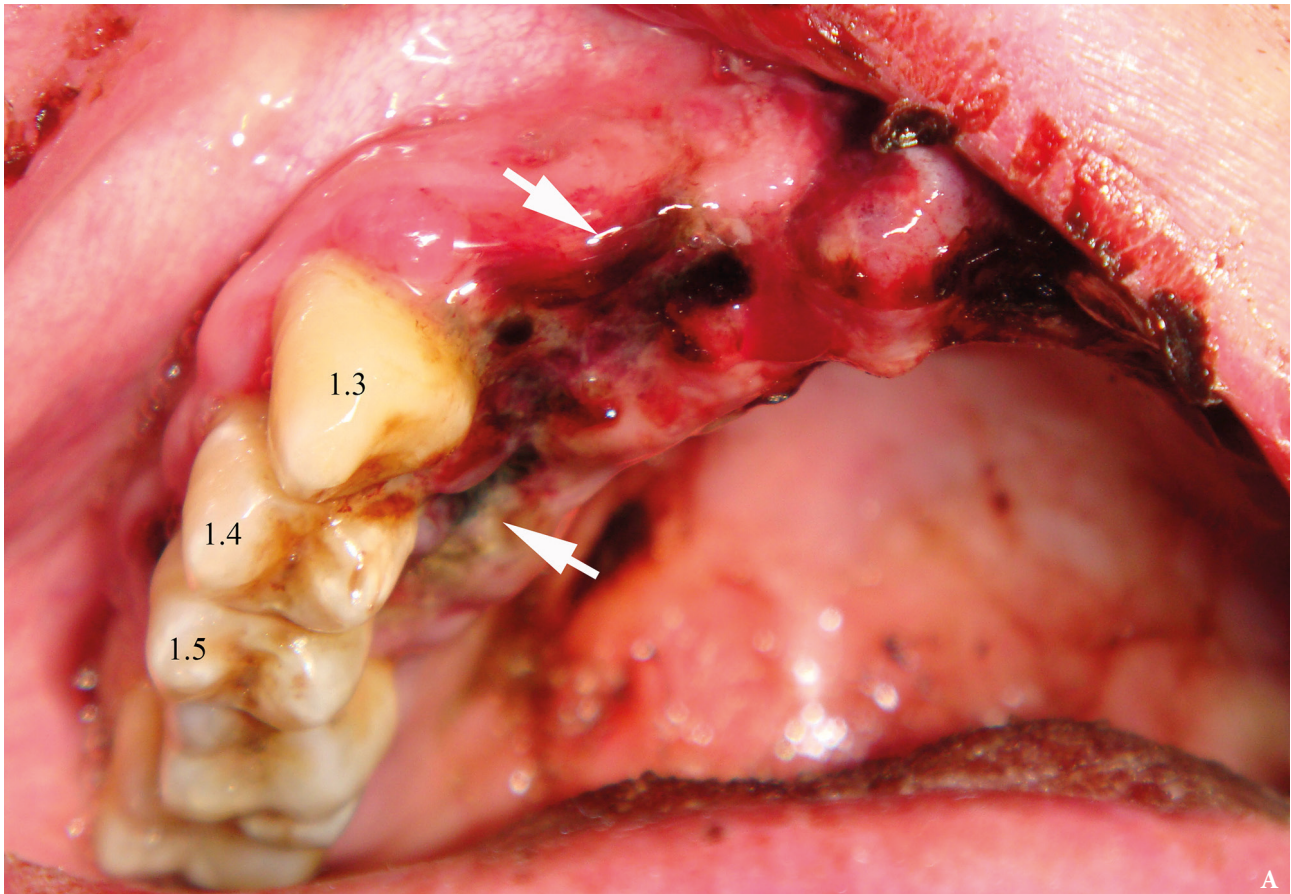


FIGURE 3. An intraoral view (A) of a 45-year-old gentleman with a trauma in anamnesis shows ruptured mucosa (arrows) from a palatal aspect of the movable teeth 1.3-1.5. That gives a suspicion for a surgeon that the maxillary fracture combines with a roots fracture of the movable teeth. The axial (B), coronal (C) CBCT scans shows no roots fracture of the teeth 1.3-1.5. The CBCT confirmed only a maxillary fracture (arrows) – segmental fracture of the alveolar process. (Fig 3 continued on next page.)

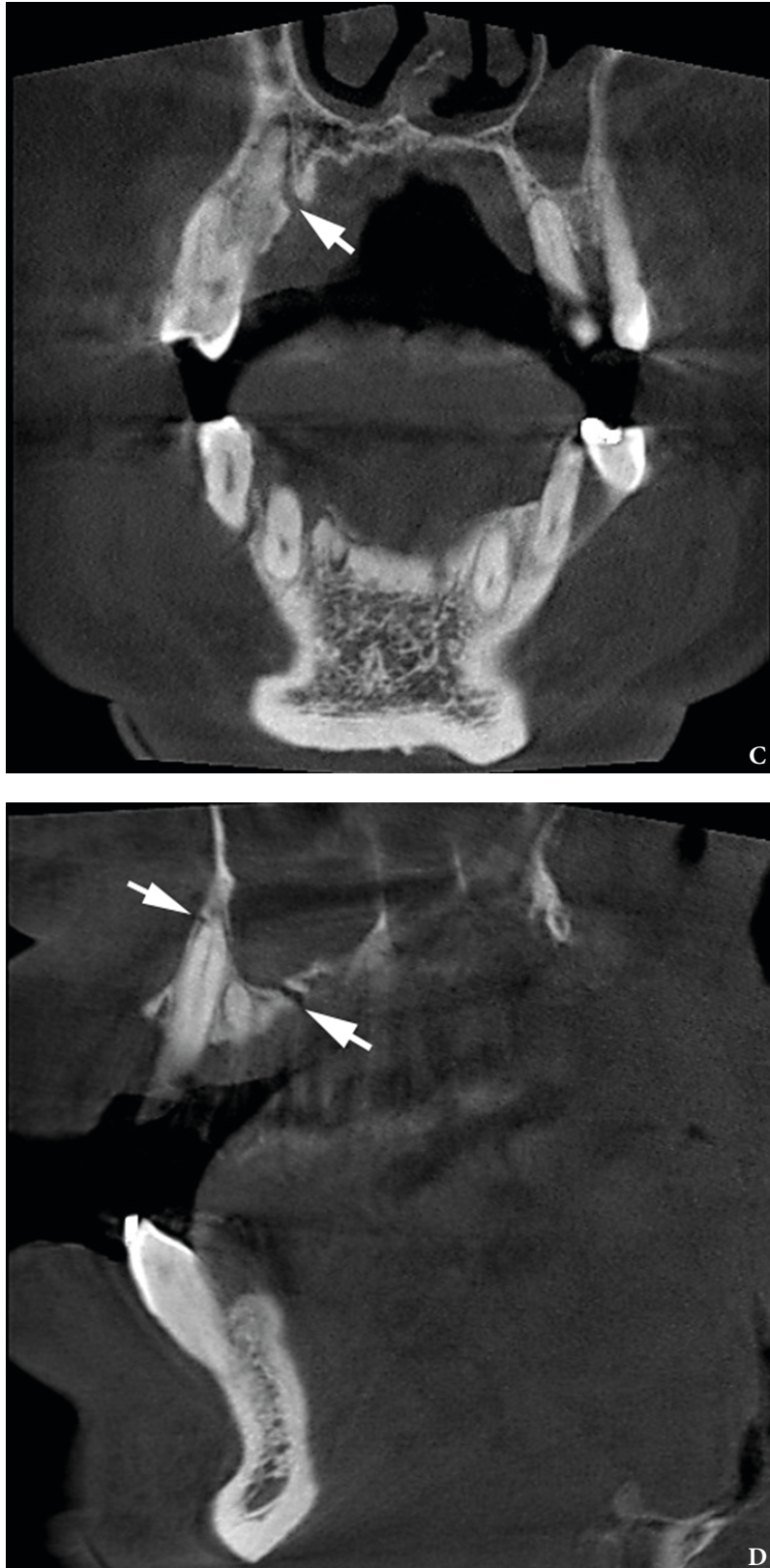


FIGURE 3. (cont'd). A coronal (C) and sagittal (D) CBCT scans shows no roots fracture of the teeth 1.3-1.5. The CBCT confirmed only a maxillary alveolar fracture (arrows). Images of **Figure 3** are courtesy of *Ievgen I. Fesenko, PhD, Assis Prof; Kyiv, Ukraine.*

TABLE 2. The Table Below is a Sample Table of How the Data Was Analyzed for Periapical Lesions Articles

Authors	Year	Study Design	Source of Sample	Type of Lesion	Patient n	Tooth n	Focus	Evaluation Time	Observers	Conclusion

TABLE 3. The Table Below is a Sample Table of How the Data Was Analyzed for Vertical Root Fractures Articles

Authors	Year	Study Design	Source of Sample	Tooth No.	Focus	Method of fractures	Tooth Status	Reference Test	CBCT Specifications	Periapical Specifications	Number of Observers	Conclusion

TABLE 4. The Table Below is a Sample Table of How the Data Was Analyzed for Bone Defects Articles

Authors	Year	Study Design	Source Sample	Number of Teeth	Number of Jaws	Focus	Periapical Specifications	Film Specifications	CBCT Specifications	Bone Status	Reference Test	Number of Observers	Conclusion

TABLE 5. Articles Included in the Study

Factors of Study	In Vivo (n)	In Vitro (n)	Total Number of Articles (n)
Periapical lesions	11	4	15
Vertical root fractures	1	12	13
Bone healing	1	10	11
Total number (n)			39

of fracture, reference tests, and types of machines as well as the sample number. The status of the tooth (filled/not filled with metallic post) also differed. Details of each respective study are outlined in [Table 7](#).

BONE DEFECTS

In this category of articles, the area of focus differed between studies were 3 articles investigated alveolar bone loss, 5 investigated the efficacy in artificially induce bone defects, 1 examined the peri-implant bone healing and 1 evaluated Regenerative periodontal bone level. The type of machines, sample number, observers’ number and bone status also differed and these are all outline in [Table 8](#).

PART 2: WHICH MODALITY IS SUPERIOR?

13 out of 15 articles concluded that CBCT is superior to PA radiography in, while the rest (n = 2) concluded that no difference was seen between the two modalities in the detection of periapical lesions. 10 out out of 13 articles for vertical root fracture and 5 out of 11 in bone defects also concluded that CBCT is superior o PA in the detection of each factor respectively. Pie charts were used to illustrate these differences as shown [Diagram 3](#).

PART 3: LIMITATIONS ADDRESSED

Several articles have mentioned the causes or limitations of CBCT and PA radiography respectively in the

identification of periapical lesions, vertical root fractures and bone defects. The numbers of articles that have addressed the limitations are shown in [Diagram 3](#). It can be seen that 9 articles mentioned limitations of PA radiography and 4 articles addressed limitation of CBCT in detection of periapical lesions. In the evaluation of vertical root fracture, 6 articles identified limitations of CBCT compared to PA and 2 articles identified the limitations of PA radiography in examination of the respective category. The limitations addressed for bone defects were less compared to the other categories with only 4 articles identify the limitations for CBCT in evaluating bone and 3 articles have shown the limitations of periapical radiography.

These addressed limitations were tabulated in [Tables 9-14](#). It can be noted that many articles agree that limitations of CBCT are due to its high radiation dose compared to PA and the fact that it require training for the use of system. Nevertheless, it was identified that the specification of CBCT during its use alters its ability to detect lesions when compared to PA radiography. Detailed explain of these differences are tabulated in [Tables 9-11](#).

More over the limitations of PA radiography in the detection of periapical lesions, vertical root fractures and bone defect was due to to the image quality affected by noise etc. furthermore, superimposition of structures in the maxillary molar area was also identified as limitation

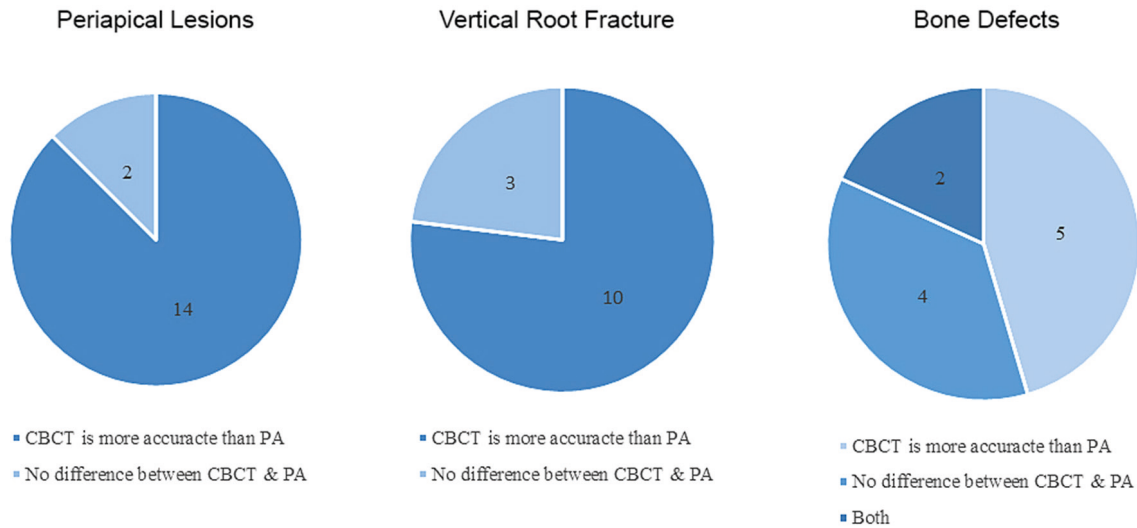


Diagram 3. The diagram illustrated the number of articles that indicated CBCT is superior to PA radiography and the articles that concluded no difference was seen between CBCT and PA radiography for each factor studied.

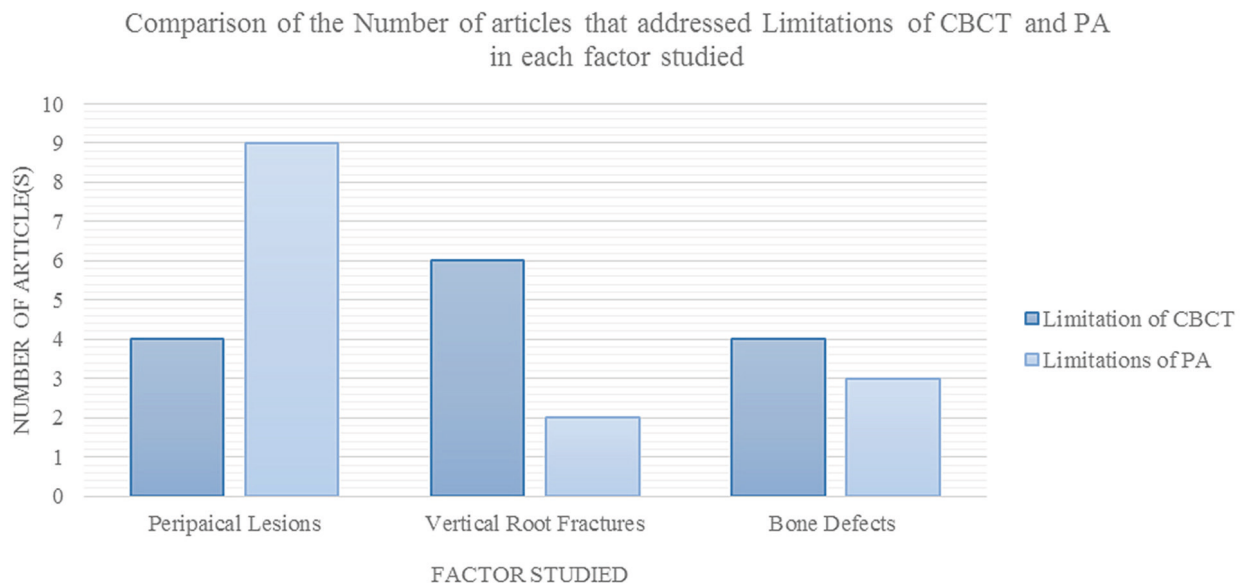


Diagram 4. The graph identifies the number of articles that addressed limitations of CBCT and PA radiography in each factor respectively. The total number of articles for periapical lesions is (n = 15), vertical root fracture (n = 13) and bone defects (n = 11).

of PA. Detailed information about these limitations is outlined in [Tables 12-14](#).

The following tables ([Tables 6-14](#)) used to analyze the data with detailed information of the difference in methodology and the limitations of CBCT and periapical radiography as such.

Discussion

This study set out to compare the differences in efficacy between periapical radiography and CBCT in diagnosis of periapical lesions, vertical root fractures and bone defects in current available literature. The main findings of this study demonstrate that with in all three factors studied,

the majority of studies emphasized that CBCT was superior to periapical radiography. Twenty-three percent (23%) of all of the studies have shown that there was no difference with regards to the diagnostic capabilities of CBCT and periapical radiography. That can be due the small sample size, the type of study conducted and the type of periapical radiographic modality used. Moreover, only a few studies showed that there was no difference between both modalities. Nevertheless, some limitations are addressed for both radiographic modalities and this may be a contributing factor to our conclusion. The most likely explanation of the negative finding is that the design of the studies can interfere with the conclusion since the studies had different sample size between each other.

TABLE 6. Summary of the Methodology and Conclusion for Articles of Periapical Lesions (Table 6 continued on next page)

Authors	Year	Study Design	Source of Sample	Type of Lesion	Patient No.	Tooth No.	Focus	Evaluation Time	Observers	Conclusions
Campello <i>et al</i> [10]	2017	<i>In vitro</i>	Artificially induced lesions with burs comparing dental radiography (DR) ^a to CBCT	Induced lesions	N/A ^b	11	Presence or absence of	Not indicated	10	CBCT allowed higher accuracy than DPR ^c in detecting simulated lesions for all simulated lesions tested. Endodontists need to be properly trained in interpreting CBCT scans to achieve higher diagnostic accuracy
Kanagasingam <i>et al</i> [11]	2017	<i>In vitro</i>	Artificially induced lesions with burs comparing DR to CBCT	Induced lesions		67	Presence or absence of	Not indicated	5	All imaging techniques had similar specificity and positive predictive values. Additional parallax views increased the diagnostic accuracy of PR. CBCT had significantly higher diagnostic accuracy in detecting AL ^d compared to PR, using human histopathological findings as a reference standard
Uraba <i>et al</i> [4]	2016	<i>In vivo</i>	Images were taken from database of the Clinic of Operative Dentistry and Endodontics at the Dental Hospital of Tokyo	Pathological	86	178	Diagnosis	Not indicated	2	1. CBCT exhibited a significantly higher AP detection compared to PR (52% vs. 31%) 2. CBCT shows more accuracy in detecting AL in maxillary molars, canines and incisors groups
Sakhadari <i>et al</i> [12]	2016	<i>In vitro</i>	Extracted teeth	Induced lesions	45 block	90	Diagnosis	Not indicated	4	1. The results showed that high-resolution CBCT scans had higher diagnostic accuracy than PSP digital radiography for detection of artificially created PA bone lesions 2. Voxel size (field of view) must be taken into account to minimize patient radiation dose
Venskutonis <i>et al</i> [13]	2014	<i>In vivo</i>	Retrieved from image database from the Department of Oral Diseases, Lithuanian University of Health Sciences from September 2008 – July 2013	Pathological	20	35	Diagnosis	Not indicated	Not indicated	1. CBCT is more accurate compared to DP in detection periapical radiolucency's in endodontically treated teeth 2. More difference is found in examining molar teeth
Saidi <i>et al</i> [14]	2014	<i>In vivo</i>	Patients were treated, at Endodontic Department of St. Joseph University	Pathological	N/A	156	Follow up healing after endo	Not indicated	2	1. CBCT was more reliable in detecting periapical lesions compared with DR in long-term evaluation of RCT success 2. Prevalence of AP was detected 34.8% with CBCT compared to 13.8%
van der Borden <i>et al</i> [15]	2013	<i>In vivo</i>	Image were taken pre operatively and at recall to check the status of the periapical lesion	Pathological	N/A	50 teeth 71 roots	Diagnosis	Not indicated	Not indicated	1. Changes in lesions size after root canal treatment determined with CBCT and PA are different 2. The outcome of RCT with PA can be untrue 3. The findings determined by PA significantly difference from CBCT

^a DR – Dental radiography
^b N/A – Not applicable
^c DPR – Dental plane radiography; PR – plane radiography
^d AL – Apical lesions

TABLE 6. (cont'd). Summary of the Methodology and Conclusion for Articles of Periapical Lesions (Table 6 continued on next page)

Authors	Year	Study Design	Source of Sample	Type of Lesion	Patient No.	Tooth No.	Focus	Evaluation Time	Observers	Conclusions
Shahbazian <i>et al</i> [16]	2013	<i>In vivo</i>	Oral Imaging Center KU Leuven	Pathological	145	537	Detecting AL in posterior maxilla	3 months interval	2	1. PA is not able to visualize pathology in maxillary molar area 2. CBCT can be used to diagnose pathology in posterior maxilla 3. Diagnosing AL with PL is underestimated with 60% missed lesions 4. Due to high radiation dose CBCT should be used only when indicated
Cheung <i>et al</i> [17]	2013	<i>In vivo</i>	Dental teaching hospital	Pathological		60		Not indicated	1 endodontist, 1 oral radiologist	1. There were substantial disagreements between PA and CBCT for assessing the periapical status of molar teeth, especially for the maxillary arch 2. The findings have implications in periapical diagnosis and for evaluating the outcome of endodontic care
Abella <i>et al</i> [18]	2012	<i>In vivo</i>	Patients referred to the Department of Endodontics at Universitat Internacional de Catalunya, Barcelona Spain from January 2011 to March 2012	Pathological	130	138 teeth	Diagnosis	Not indicated	2 examiners	1. The study concluded that 10.4 % of AP lesions were missed by PA radiographs 2. The accuracy of CBCT was significantly higher (p < 0.5)
Davies <i>et al</i> [19]	2012	<i>In vivo</i>	Refer to part 1 of the study for details	Pathological	99	123	Diagnosis	1 years	Not indicated	1. CBCT shows a lower healing rate compared to PR particularly in molar teeth 2. There was a 14 times increase in failure rate when teeth with no pre operative PA RL were assessed with CBCT compared to PR after 1 year
Balasundaram <i>et al</i> [20]	2012	<i>In vivo</i>	Patient who reported to the Endodontic Division of the University of Detroit Mercy School of Dentistry with symptoms of periapical lesions. March 2010 to December 2010	Pathological	24	24	Treatment planning	Not indicated	6	1. No difference in the treatment plan between the 2 modalities (PR and CBCT) was found 2. Even though CBCT shows more "information", it doesn't affect the treatment plan when compared to PR
Low <i>et al</i> [21]	2008	<i>In vivo</i>	The patients were referred to the Department of Oral Surgery and Stomatology in University of Bern, Switzerland	Pathological	45	74	Previously endo treated teeth with signs of AP	Not indicated	1 oral radiologist and 1 endodontist	1. 34% of lesions detected on CBCT were missed by PA in maxillary premolars and molars 2. Lesion expansion into the sinus, sinus membrane thickening, missed canals, and presence of apicomarginal defects were also more frequently seen with CBT than PA
Estrela <i>et al</i> [22]	2008	<i>In vivo</i>	Databases from the Dental and Radiological Institute of Brasilia (IORE, Brasilia, DF, Brazil). Exams were obtained between May 2004 and August 2006	Pathological	888	1508	Tooth at pre-op and recall	Not indicated	3	1. Possibility of false-negative diagnosis when using conventional radiography 2. Prevalence of AP was significantly higher with CBCT 3. AP was correctly identified with conventional methods when showed advanced status 4. CBCT was proved to be accurate to identify AP

TABLE 6. (cont'd). Summary of the Methodology and Conclusion for Articles of Periapical Lesions

Authors	Year	Study Design	Source of Sample	Type of Lesion	Patient No.	Tooth No.	Focus	Evaluation Time	Observers	Conclusions
Stavropoulos <i>et al</i> [23]	2008	<i>In vitro</i>	Pig jaws	Pathological	N/A	N/A	Visibility of a lesion	Not indicated	4	1. The diagnostic accuracy of New Tom 3G was significantly higher than that of intraoral radiographs 2. No difference between digital and conventional was seen

TABLE 7. Summary of the Methodology and Conclusion for Articles of Vertical Root Fracture (Table 7 continued on next page)

Authors	Year	Study Design	Source of Sample	Tooth No.	Method of Fractures	Tooth Status	Reference Test	CBCT Specifications	Periapical Specifications	Observers	Conclusions
Bechara <i>et al</i> [24]	2013	<i>In vitro</i>	Extracted teeth	66	Hammer and attached by methyl acrylate	Endodontically treated tooth	N/A VRF was induced	Picasso Master 3D 17 × 7 cm FOV 0.2 voxel	2 PA were taken at different angles the PSP was controlled by a putty matrix	5	1. CBCT at a small FOV showed more accuracy compared to large FOV 2. PSP and small FOV CBCT show similar results and are greater than large FOV CBCT 3. The study concludes that CBCT should be used when PSP is not enough to detect VRF
Abdian <i>et al</i> [25]	2016	<i>In vitro</i>	Extracted teeth	120	Hammer	Non-filled, filled, present with posts	Inspected with magnifier x5	Cranex 3D	3 horizontal angles	2	1. No significant difference was found between the results of CBCT compared to PR in detection of vertical root fracture 2. The study concludes that CBCT should only be used after basic radiology is done
Bechara <i>et al</i> [26]	2015	<i>In vitro</i>	Extracted teeth	66	Pin tapered with hammer into root	Endodontically treated teeth	A five point scale reviewed by the evaluators	Cranex 3D	PSP plates	5	The accuracy of RF depiction in endodontically treated teeth using 8 cm × 8 cm FOV CBCT was greater than that obtained using one or two PSP plate angulations
Ezzodini Ardakani <i>et al</i> [27]	2015	<i>In vitro</i>		80	Sharp Chisel and Hammer	RCT Filled	10 × Magnification Stereomicroscope	Planmeca Promax 3D	Conventional	3	1. This study showed that the sensitivity and accuracy of CBCT in detection of vertical root fracture are higher than periapical radiography 2. CBCT can be recommended to be used in detection of vertical root fractures

TABLE 7. (cont'd). Summary of the Methodology and Conclusion for Articles of Vertical Root Fracture (Table 7 continued on next page)

Authors	Year	Study Design	Source of Sample	Tooth No.	Method of Fractures	Tooth Status	Reference Test	CBCT Specifications	Periapical Specifications	Observers	Conclusions
Brady <i>et al</i> [28]	2014	<i>In vitro</i>	Extracted teeth	30	Software: needle inserted into canal to induce fracture	Non-endo treated	Dental Operating Microscope and OCT	2 different CBCT machines: 3D Accuitomo and i-CAT	65 kV 7mA and 0.16 s. Phosphor plate. 10 degrees mesial and distal	3 endodontics and 6 undergraduates	<ol style="list-style-type: none"> 1. CBCT is significantly more accurate in detecting incomplete VRF compared to PA 2. The width of the fracture affects the diagnostic accuracy of CBCT 3. CBCT is more accurate in detecting a fracture of >50 μm rather than <50 μm 4. The resolution is probably the reason for the poor detection
Chavda <i>et al</i> [29]	2014	<i>In vivo</i>	Unsalvageable teeth from 21 patients	22	NA	Non-endo treated	Dental Operating Microscope at 12.0 \times magnification	CBCT 3D Accuitomo F170 small volume (40 mm ³) 90 kV, 5.0 mA and 17.5 seconds	Digital Radiograph with sensor with 66 kV, 7.5 MA at 0.10 seconds	3 Endodontists and 10 undergraduates	<ol style="list-style-type: none"> 1. DR and CBCT have significant limitations in detecting VRF in vivo. 2. CBCT may be useful as an adjunct during clinical examination
Takeshita <i>et al</i> [30]	2014	<i>In vitro</i>	Extracted teeth	20	Fractured induced by testing machine	Root Canal Filled tooth	Binocular Stereomicroscope	iCAT	Conventional	3	<ol style="list-style-type: none"> 1. CBCT was more accurate than conventional periapical radiography in detecting VRF 2. MPs did not influence the diagnostic accuracy of fractures for either imaging methods 3. The present study used the smallest voxel resolution and FOV; future studies that aim to reduce radiation exposure could examine the influence of the voxel size, FOV, and different CBCT equipment
Jakobson <i>et al</i> [31]	2014	<i>In vitro</i>	Human teeth	100	Diamond coated steel discs	Tooth endo and with Metallic posts	Light microscope m900 at $\times 10$	CBCT1 (New Tom) CBCT2 (iCAT)	Film and digital Radiographs were taken and compared to CBCT1 and 2	4	<ol style="list-style-type: none"> 1. The presence of metallic posts did not influence the sensitivity of most of the examinations, excluding the CBCT1 system 2. The fracture line orientation may influence VRF detection

TABLE 7. (cont'd). Summary of the Methodology and Conclusion for Articles of Vertical Root Fracture

Authors	Year	Study Design	Source of Sample	Tooth No.	Method of Fractures	Tooth Status	Reference Test	CBCT Specifications	Periapical Specifications	Observers	Conclusions
da Silveira <i>et al</i> [32]	2013	<i>In vitro</i>	Extracted teeth	60	Stimulated	20 with GP 20 post 20 No filling	Inspected with magnification	iCAT	3 different angles with digital film	3	1. The radiographic examination with horizontal angle variation should be encouraged as the first complementary approach to assess the presence of VRFs 2. If conventional imaging is not capable to provide adequate information, CBCT can be indicated if a root fracture is strongly suspected 3. The root condition should then guide the voxel resolution choice, selecting 0.3-voxel for not root filled teeth and 0.2-voxel for teeth with filling and/or a post
Kambungton <i>et al</i> [33]	2012	<i>In vitro</i>	Extracted teeth	60	Induced by a machine system	Endodontically treated teeth	Crack line confirmed with 1% methylene blue solution	Viewspocs 3D	Digital intraoral film	3 OMF radiologists	There was no significant difference between intraoral film, high resolution metaloxide semiconductor digital image and CBCT in detecting VRF in mandibular single rooted teeth
Varshosaz <i>et al</i> [34]	2010	<i>In vitro</i>	Extracted teeth premolars single rooted	90	By a size 45 finger spreader until a sharp crack voice heard	Root canal filled tooth	Stereomicroscopy x20	3D Accuitomo 170; NewTom 3G; VistaScan PSP; CCD sensor	Conventional	2	The 3D Accuitomo 170 was significantly superior to the NewTom 3G, VistaScan PSP, CCD sensor, and conventional film images in the detection of artificially induced vertical root fractures
Tsai <i>et al</i> [35]	2012	<i>In vitro</i>	Extracted teeth	100	Pin was inserted to induce VRF	Cleaning and shaping no filling	Zackwill/Roell Z200 Universal Testing Machines	Promax 3D		6	CBCT achieves more accurate diagnosis of VRF in comparison to digital radiographs
Metska <i>et al</i> [36]	2009	<i>In vitro</i>	Extracted teeth	80	Artificially Induced	Filling roots	Stereomicroscope	iCAT	Phosphor plate films	4	1. The sensitivity of CBCT in detecting VRF was significantly higher compared to PR 2. CBCT scans overall significantly more accurate in detecting VRF 3. CBCT accuracy is 0.86 compared to 0.66 in PR 4. The presence of Root Filling did not significantly influence the sensitivity of CBCT but reduced its specificity 5. In PR presence of root filling reduced sensitivity.

TABLE 8. Summary of the Methodology and Conclusion for Articles of Bone Defects (Table 8 continued on next page)

Authors	Year	Study Design	Source of Sample	Teeth No.	Jaw No.	Focus	Periapical specifications	CBCCT Specifications	Bone Status	Reference Test	Observers	Conclusion
Bayat <i>et al</i> [37]	2016	<i>In vitro</i>	Seven sheep mandibles	84 (72 artificial defects, 8 natural defects)	7	Artificial periapical bone defects	MINIRAY Soredex Digora Soredex PSP	NewTom Vgi	Drilled bone	Photographs of created defects	3	1. CBCT was superior to digital intraoral radiography for the detection of Grade I furcation involvements, three-wall defects, dehiscence and fenestrations 2. No significant difference was noted between CBCT and digital radiography for the detection of Grades II and III furcation involvements, one-wall, two-wall and trough-like defects
Bardal <i>et al</i> [38]	2015	<i>In vitro</i>	Five dry mandibles	Edentulous	5	Artificial cancellous bone defects	de Gotzen Film: Soredex-Onion PSP and E-speed Eastman Kodak	Not mentioned	Drilled bone	Not mentioned	2	1. Defects confined to spongy bone can be identified on film and PSP radiographs and CBCT scans 2. However, interpretation of PSP images and CBCT scans needs greater expertise and skills
Bagis <i>et al</i> [39]	2015	<i>In vitro</i>	Twelve dry jaws (maxilla & mandible)	99	24	Artificial periodontal bone defects	Evolution x3000-2c Digora Soredex PSP	Planmeca Promax	Drilled bone	Periodontal Consultant	2	1. CBCT has the highest diagnostic accuracy for detecting periodontal defects 2. Further studies should be taken with different FOVs and different voxel sizes of the CBCT machines 3. CBCT not recommended if it will not improve diagnosis due to radiation
Takeshita <i>et al</i> [40]	2014	<i>In vitro</i>	Human teeth and macerated jaws	70	10	Aveolar bone loss	Carestream Health Kodak RVG 6100	iCAT Scanner	Non-induced bone loss	Digital Calliper	2	1. Conventional periapical with Han-Shin film holder was the only method that differed from the controls 2. CBCT had the closest means to the controls
de Faria Vasconcelos <i>et al</i> [41]	2012	<i>In vitro</i>	Radiographic database	39	N/A	Aveolar bone loss	Spectro 70X Selectronic Kodak Insight	iCAT Scanner	Non-induced bone loss	Dental Radiologist Specialist	3	1. CBCT was superior to digital intraoral radiography for the detection of Grade I furcation involvements, three-wall defects, dehiscence and fenestrations 2. The results showed that there was no significant difference between imaging methods in the identification of pattern of bone loss

TABLE 8. (cont'd). Summary of the Methodology and Conclusion for Articles of Bone Defects

Authors	Year	Study Design	Source of Sample	Teeth No.	Jaw No.	Focus	Periapical specifications	CBC T Specifications	Bone Status	Reference Test	Observers	Conclusion
dos Santos Corpas <i>et al</i> [42]	2011	<i>In vitro</i>	Ten minipigs	10 implants	10	Peri-implant bone healing	Planmeca Prostyle Intra VistaScan PSP	Accuitomo 3D	N/A	Histological examination	0	<ol style="list-style-type: none"> 1. Minute bone changes during a short-term period can be followed up using digital intra-oral radiography 2. Radiographic fractal analysis did not seem to match histological fractal analysis 3. CBC T was not found to be reliable for bone density measures, but might hold potential with regard to the structural analysis of trabecular bone
Patel <i>et al</i> [43]	2009	<i>In vitro</i>	Six dry mandibles	10 molars	6	Artificial periapical bone defects	Planmeca Prostyle Intra Schick CDD	Veraviewwpcos	Drilled bone	Microscope and controlled drilling	6	<ol style="list-style-type: none"> 1. With intraoral radiography, external factors such as, anatomical noise and poor irradiation geometry, hinder the detection of periapical lesions 2. CBC T removes external factors and improved detection of the of artificial periapical lesions
Grimard <i>et al</i> [44]	2009	<i>In vivo</i>	Twenty nine humans (12F, 17M)	35	29	Regenerative periodontal bone level	Air Techniques PSP	Accuitomo 3DX	Non-induced bone loss	Surgical measurements	2	<ol style="list-style-type: none"> 1. Compared to direct surgical measurements, CBVT was significantly more precise and accurate than IRs 2. If supported by further research, CBVT may obviate surgical reentry as a technique for assessing regenerative therapy outcomes
Noujeim <i>et al</i> [45]	2009	<i>In vitro</i>	Eleven dry hemi-mandible	163 sites M&D	11	Artificial bone defects	Planmeca Prostyle Intra Kodak Insight	Accuitomo 3DX	Drilled bone	Not mentioned	10	<p>Results indicate that the CBC T technique has better accuracy and diagnostic value than periapical films in the detection of interradicular periodontal bone defects</p> <ol style="list-style-type: none"> 1. CBC T allowed comparable measurements of periodontal bone levels and defects as with intraoral radiography 2. CBC T with 0.4 mm cross-sections demonstrated values closer to the gold standard indicating more accurate assessment of periodontal bone loss 3. Further research is needed to explore these results in vivo with the use of CBC T in periodontal diagnosis
Vandenbergh <i>et al</i> [46]	2008	<i>In vitro</i>	Human cadaver and dry skull (mandibles)	71	2	Alveolar bone loss	Heliodent DS Schick CDR	iCAT Scanner	Non-induced bone loss	Digital caliper	3	<ol style="list-style-type: none"> 1. CBC T allowed comparable measurements of periodontal bone levels and defects as with intraoral radiography 2. CBC T with 0.4 mm cross-sections demonstrated values closer to the gold standard indicating more accurate assessment of periodontal bone loss 3. Further research is needed to explore these results in vivo with the use of CBC T in periodontal diagnosis

LIMITATIONS OF CBCT

TABLE 9. Limitations of CBCT in Detecting Periapical Lesions Addressed by Various Research Papers

Authors	Year	Study Design	Limitation
Campello <i>et al</i> [10]	2017	<i>In vitro</i>	CBCT requires proper trained prior to use
Sakhadari <i>et al</i> [12]	2016	<i>In vitro</i>	Voxel size (field of view) must be taken into account to minimize patient radiation dose
Shahbazian <i>et al</i> [16]	2013	<i>In vivo</i>	Due to high radiation dose CBCT should be used only when indicated
Balasundaram <i>et al</i> [20]	2012	<i>In vivo</i>	Even though CBCT shows more “information”, it doesn’t affect the treatment plan when compared to PR

TABLE 10. Limitations of CBCT in Detecting Vertical Root Fracture Addressed by Various Research Papers

Authors	Year	Study Design	Limitation
Bechara <i>et al</i> [24]	2013	<i>In vitro</i>	CBCT at a small field of view (FOV) showed more accuracy compared to large FOV
Bechara <i>et al</i> [24]	2013	<i>In vitro</i>	1. PSP and small FOV CBCT show similar results and are greater than large FOV CBCT 2. The study concludes that CBCT should be used when PSP is not enough to detect VRF
Abdinian <i>et al</i> [25]	2016	<i>In vitro</i>	1. The study concludes that CBCT should only be used after basic radiology is done
Brady <i>et al</i> [28]	2014	<i>In vitro</i>	1. The width of the fracture affects the diagnostic accuracy of CBCT 2. CBCT is more accurate in detecting a fracture of >50 μm rather than <50 μm
Jakobson <i>et al</i> [31]	2013	<i>In vitro</i>	The presence of metallic posts can affect the image when using New Tom
da Silveira <i>et al</i> [32]	2013	<i>In vitro</i>	The root condition should then guide the voxel resolution choice, selecting 0.3-voxel for not root filled teeth and 0.2-voxel for teeth with filling and/or a post
Metska <i>et al</i> [36]	2009	<i>In vitro</i>	The presence of root filling did not significantly influence of the CBCT but reduced its specificity

TABLE 11. Limitations of CBCT in Detecting Bone Defects as Addressed by Various Research Papers

Authors	Year	Study Design	Limitation
Bardal <i>et al</i> [38]	2015	<i>In vitro</i>	Interpretation of CBCT scans needs greater expertise and skills
dos Santos Corpas <i>et al</i> [42]	2011	<i>In vitro</i>	CBCT was not found to be reliable for bone density measures
Grimard <i>et al</i> [44]	2009	<i>In vivo</i>	However, CBVT does not provide some of the benefits of reentry surgery such as residual probing depth following regenerative therapy

Such an example is the study by Estrela *et al* (2008) [22], which contained a sample size of 1508 compared to another study by Campello *et al* (2017) [10] only included 11 samples. The study design of the articles included can affect their conclusion, although, this review did not criticize the quality of research included to come up with conclusions. However since this review was based on conclusions of the reviewed articles, this could affect the outcome of the review. From the data collected in the results it is observed that significant key conclusions that were shared between most papers are consistent with other systematic reviews conducted in the same field of study (Bella *et al*, 2012) [47], (Kruse *et al*, 2014) [48]. Studies conducted since 2006

have shown the superiority of CBCT when compared to periapical radiography with regards to the aforementioned factors. On the other hand, while recent studies still support the fact that CBCT is superior, they also outline the technical specification which can influence the diagnostic abilities of CBCT (Bardal *et al*, 2015) [38], (Davies *et al*, 2015) [19], (Shahbazian *et al*, 2013) [16], and Kanagasingham *et al* (2017) [11] suggested that additional parallel views can increase the diagnostic accuracy of PA when comparing to CBCT in the detection of periapical lesions. However, limitations can still occur in the maxillary molar region with PA radiographs. The field of view (FOV) in CBCT had an effect with respect to the specificity and sensibility in detecting

LIMITATIONS OF PERIAPICAL RADIOGRAPHS

TABLE 12. Limitations of Periapical Radiography in Detecting Periapical Lesions Addressed by Various Research Papers

Authors	Year	Type of Study	Limitation Addressed
Uraba <i>et al</i> [4]	2016	<i>In vivo</i>	CBCT shows more accuracy in detecting AP lesions in maxillary molars, canines and incisors groups
Venskutonis <i>et al</i> [13]	2014	<i>In vivo</i>	Periapical radiography can give limited information especially in the molar teeth
van der Borden <i>et al</i> [15]	2013	<i>In vivo</i>	The outcome of RCT with pa can be untrue
Shahbazian <i>et al</i> [16]	2013	<i>In vivo</i>	PA is not able to visualize pathology in maxillary molar area
Shahbazian <i>et al</i> [16]	2013	<i>In vivo</i>	Diagnosing AP with PA is underestimated with 60% missed lesions
Cheung <i>et al</i> [17]	2013	<i>In vivo</i>	There were substantial disagreements between pa and CBCT for assessing the periapical status of molar teeth, especially for the maxillary arch
Low <i>et al</i> [21]	2008	<i>In vivo</i>	34% of lesions detected on CBCT were missed by pa in maxillary premolars and molars
Estrela <i>et al</i> [22]	2008	<i>In vivo</i>	Possibility of false-negative diagnosis when using conventional radiography
Estrela <i>et al</i> [22]	2008	<i>In vivo</i>	PA can only detect lesions at advance state compared to CBCT

TABLE 13. Limitations of Periapical Radiography in Detecting Vertical Root Fracture Addressed by Various Research Papers

Authors	Year	Type of Study	Limitation Addressed
da Silveira <i>et al</i> [32]	2013	<i>In vitro</i>	The radiographic examination with horizontal angle variation should be encouraged as the first complementary approach to assess the presence of VRF
Metska <i>et al</i> [36]	2009	<i>In vitro</i>	In PAR presence of root filling reduced sensitivity

TABLE 14. Limitations of Periapical Radiography in Detecting Bone Defects Addressed by Various Research Papers

Authors	Year	Type of Study	Limitation
Bardal <i>et al</i> [38]	2015	<i>In vitro</i>	Interpretation of PSP images needs greater expertise and skills
dos Santos Corpas <i>et al</i> [42]	2011	<i>In vitro</i>	Radiographic fractal analysis did not seem to match histological fractal analysis
Patel <i>et al</i> [43]	2009	<i>In vivo</i>	With intraoral radiography, external factors such as, anatomical noise and poor irradiation geometry, which are not in the clinician’s control, hinder the detection of periapical lesions

vertical root fractures. A smaller FOV has shown more accurate detection when compared to larger FOV (Bechara *et al*, 2013) [24]. A few more studies demonstrated that size of the FOV in CBCT alters the ability of detection of VRF in endodontically treated teeth. (Bechara *et al*, 2015) [26], (da Silveira *et al*, 2013) [32]. With regard to bone defects, it was suggested that the use film holders can alter the assessment of alveolar bone loss in PAR, in such a way that it could improve its diagnostic ability (Takeshita *et al*, 2014) [40]. Another point of discussion is the effects of external factors or variables which may influence the ability of diagnosis of the areas in question. With intraoral radiography, external factors such as, anatomical noise and poor irradiation geometry, can hinder the detection of periapical lesions. CBCT removes these external factors and further permits the clinician to select the most relevant views of the area of interest resulting in improved detection of the presence and absence of periapical lesions (Patel *et al*, 2009) [43].

Nevertheless, certain studies also shown that presence and absences of fillings can affects the image quality. Metska *et al* (2009) [36] stated that the presence of root filling has no effect on the efficacy of CBCT. Whereas, da Silveira *et al* (2013) [32] suggested that the presence or absence of fillings guides the voxel to be used. Differences between *in vivo* and *in vitro* studies have a subtle point of negotiation. Even though clinical studies results are consistent with *in vitro* results (both show CBCT is superior to PA). Several studies suggested that PR is not able to detect periapical lesions in the posterior maxilla due to superimposition of the structures where this cannot be assessed in “*in vitro*” studies. (Shahbazian *et al*, 2013) [16], (Cheung *et al*, 2013) [17], (Low *et al*, 2008) [21]. In another study, it concludes with, the orientation of the fracture and how it can influence the ability of detection in both PA and CBCT (Jakobson *et al*, 2014) [31]. Several papers addressed the ease of use and the levels of radiation among these devices.

According to Vandenberghe *et al.*, (2008) [46], the use of CBCT should only be used in complex treatment planning such as, periodontal surgeries or implant placements at lower doses and with smaller voxel sizes. Although multiple articles agree that even though CBCT can give an accurate result, clinicians still require more training to easily use and interpret these images (Campello *et al.*, 2017) [10], (Bardal *et al.*, 2015) [38]. Due to radiation difference between CBCT and PA, literature encourages the use of CBCT only when needed or after the use of PA (Shahbazian *et al.*, 2013) [16], (Abdinian *et al.*, 2016) [25]. Some authors have stated that the use of CBCT is only permissible if the diagnostic information improves the treatment results due to the extent of radiation (Bagis *et al.*, 2015) [39]. The main limitation of this study is that the focus was based on the conclusion of past studies and did not focus in depth on the variation of the design of studies conducted. Although this would not significantly alter our conclusion of the reviewed papers [49-52], it may present as a future complication in such a way that may require more precise analysis. Another major obstacle faced was that this research included a narrow assessment of search engines (only PubMed and ProQuest). With that being said, the portal provided by Ras Al Khaimah Medical and Health Sciences University was not able to retrieve several articles in full-text version, which narrowed our literary records to assess. This study reinforces the recommendation for the use of CBCT in diagnosis of periapical lesions, root fractures and bony defects and should be utilized in treatment planning in most if not all cases. The results are of direct practical relevance in which CBCT will benefit the diagnostic abilities of any dental clinician who had previous training with the use of the device.

Conclusion

Despite the limitations of the review conducted, evidence suggests that cone beam computed tomography is superior to periapical radiography in image quality and diagnostic ability with regards to periapical lesions, vertical root fractures and bone defects. However, it can be concluded that the specifications like field of view and voxel size affect the quality of CBCT images and therefore can affect its ability to detect periapical lesions, vertical root fractures and bone defects when compared to periapical radiographs. However, dental clinicians should be cautious when exposing patient to CBCT due to the higher radiation dose of CBCT. Likewise, it is proposed that the use of PA with some modifications is encouraged before the use of CBCT due to radiation dose.

Future Directions

It is recommended to research the effects of diagnosis on treatment planning by both modalities. Nevertheless, more clinical studies should be conducted when understanding the difference between CBCT and PA in detecting PA

lesions due to structures superimposition and it affects. Future studies should investigate how to achieve maximum quality at minimum radiation for the detection of the lesions discussed; Training on the use of cone beam computed tomography should be initiated at early stages of university life due to the requirements and advancements in diagnostic modalities within the dental field.

Ethical Approval

Approval was obtained from the Research and Ethics Committee of the RAK Medical Health Sciences University, Ras Al Khaima, UAE in March 3, 2017 (RAKMHSU-REC-38-2016-UG-D).

Role of Author and Co-authors

Hala Zakaria (Principle Investigator)
Caroline L. Duarte Puerto (Research Co-ordinator)
Hassan Al Basri and M. Fadhil (Investigator Researchers)

References

1. Shah N, Bansal N, Logani A. Recent advances in imaging technologies in dentistry. *World J Radiol* **2014**;6(10):794–807. <http://dx.doi.org/10.4329/wjr.v6.i10.794>.
2. van der Sanden W, Kreulen CM, Berkhout WE. Instruction in dental radiology. *Ned Tijdschr Tandheelkd* **2016**;123(04):211–218. <http://dx.doi.org/10.5177/ntvt.2016.04.15222>.
3. Butaric L, McCarthy R, Broadfield D. A preliminary 3D computed tomography study of the human maxillary sinus and nasal cavity. *Am J Phys Anthropol* **2010**;143(3):426–36. <http://dx.doi.org/10.1002/ajpa.21331>.
4. Uraba S, Ebihara A, Komatsu K, Ohbayashi N, Okiji T. Ability of cone-beam computed tomography to detect periapical lesions that were not detected by periapical radiography: a retrospective assessment according to tooth group. *J Endod* **2016**;42(8):1186–90. <http://dx.doi.org/10.1016/j.joen.2016.04.026>.
5. Gurtu A, Aggarwal A, Mohan S, Singhal A, Bansal R, Agnihotri K. CBCT: a revolutionary diagnostic aid for endodontic dilemmas. *Minerva Stomatol* **2014**;63(9):325–31.
6. Meena N, Kowsky RD. Applications of cone beam computed tomography in endodontics: a review. *Dentistry* **2014**;04(07):242. <http://dx.doi.org/10.4172/2161-1122.1000242>.
7. Peters C, Peters O. Cone beam computed tomography and other imaging techniques in the determination of periapical healing. *Endod Topics* **2012**;26(1):57–75. <http://dx.doi.org/10.1111/etp.12021>.
8. Mota de Almeida FJ, Knutsson K, Flygare L. The impact of cone beam computed tomography on the choice of endodontic diagnosis. *Int Endod J* **2015**;48:564–72. <http://dx.doi.org/10.1111/iej.12350>.
9. Assadian H, Dabbaghi A, Gooran M, Eftekhar B, Sharifi S, Shams N, Dehghani Najvani A, Tabesh H. Accuracy of CBCT, digital radiography and cross-sectioning for the evaluation of mandibular incisor root canals. *Iran Endod J* **2016**;11(2):106–10. <http://dx.doi.org/10.7508/iej.2016.02.006>.
10. Campello A, Gonçalves L, Guedes F, Marques F. Cone-beam computed tomography versus digital periapical radiography

- in the detection of artificially created periapical lesions: a pilot study of the diagnostic accuracy of endodontists using both techniques. *Imaging Sci Dent* **2017**;47(1):25–31. <http://dx.doi.org/10.5624/isd.2017.47.1.25>.
11. Kanagasigam S, Lim C, Yong C, Mannocci F, Patel S. Diagnostic accuracy of periapical radiography and cone beam computed tomography in detecting apical periodontitis using histopathological findings as a reference standard. *Int Endod J* **2016**;50(5):417–26. <http://dx.doi.org/10.1111/iej.12650>.
 12. Sakhdari S, Talaeipour AR, Talaeipour M, Pazhutan M, Tehrani SH, Kharazifard MJ. Diagnostic accuracy of CBCT with different voxel sizes and intraoral digital radiography for detection of periapical bone lesions: an ex-vivo study. *J Dent (Tehran)* **2016**;13(2):77–84.
 13. Venskutonis T, Daugela P, Strazdas M, Juodzbaly G. Accuracy of digital radiography and cone beam computed tomography on periapical radiolucency detection in endodontically treated teeth. *J Oral Maxillofac Res* **2014**;5(2):e1. <http://dx.doi.org/10.5037/jomr.2014.5201>.
 14. Saidi A, Naaman A, Zogheib C. Accuracy of cone-beam computed tomography and periapical radiography in endodontically treated teeth evaluation: a five-year retrospective study. *J Int Oral Health* **2015**;7(3):15–9.
 15. van der Borden W, Wang X, Wu M, Shemesh H. Area and 3-dimensional volumetric changes of periapical lesions after root canal treatments. *J Endod* **2013**;39(10):1245–9. <http://dx.doi.org/10.1016/j.joen.2013.07.001>.
 16. Shahbazian M, Vandewoude C, Wyatt J, Jacobs R. Comparative assessment of periapical radiography and CBCT imaging for radiodiagnosics in the posterior maxilla. *Odontology* **2013**;103(1):97–104. <http://dx.doi.org/10.1007/s10266-013-0144-z>.
 17. Cheung G, Wei W, McGrath C. Agreement between periapical radiographs and cone-beam computed tomography for assessment of periapical status of root filled molar teeth. *Int Endod J* **2013**;46(10):889–95. <http://dx.doi.org/10.1111/iej.12076>.
 18. Abella F, Patel S, Duran-Sindreu F, Mercadé M, Bueno R, Roig M. Evaluating the periapical status of teeth with irreversible pulpitis by using cone-beam computed tomography scanning and periapical radiographs. *J Endod* **2012**;38(12):1588–91. <http://dx.doi.org/10.1016/j.joen.2012.09.003>.
 19. Davies A, Patel S, Foschi F, Andiappan M, Mitchell P, Mannocci F. The detection of periapical pathoses using digital periapical radiography and cone beam computed tomography in endodontically retreated teeth – part 2: a 1 year post-treatment follow-up. *Int Endod J* **2015**;49(7):623–35. <http://dx.doi.org/10.1111/iej.12500>.
 20. Balasundaram A, Shah P, Hoen M, Wheeler M, Bringas J, Gartner A, Geist J. Comparison of cone-beam computed tomography and periapical radiography in predicting treatment decision for periapical lesions: a clinical study. *Int J Dent* **2012**;2012:920815. <http://dx.doi.org/10.1155/2012/920815>.
 21. Low K, Dula K, Bürgin W, von Arx T. Comparison of periapical radiography and limited cone-beam tomography in posterior maxillary teeth referred for apical surgery. *J Endod* **2008**;34(5):557–62. <http://dx.doi.org/10.1016/j.joen.2008.02.022>.
 22. Estrela C, Bueno M, Leles C, Azevedo B, Azevedo J. Accuracy of cone beam computed tomography and panoramic and periapical radiography for detection of apical periodontitis. *J Endod* **2008**;34(3):273–9.
 23. Stavropoulos A, Wenzel A. Accuracy of cone beam dental CT, intraoral digital and conventional film radiography for the detection of periapical lesions. An ex vivo study in pig jaws. *Clin Oral Investig* **2006**;11(1):101–6.
 24. Bechara B, McMahan C, Noujeim M, Faddoul T, Moore W, Teixeira F, Geha H. Comparison of cone beam CT scans with enhanced photostimulated phosphor plate images in the detection of root fracture of endodontically treated teeth. *Dentomaxillofac Radiol* **2013**;42(7):20120404. <http://dx.doi.org/10.1259/dmfr.20120404>.
 25. Abdinian M, Razavian H, Jenabi N. *In vitro* comparison of cone beam computed tomography with digital periapical radiography for detection of vertical root fracture in posterior teeth. *J Dent (Shiraz)* **2016**;17(2):84–90.
 26. Bechara B, Muraikhi S, McMahan A, Nasseh I, Moarbes M, Noujeim M, Sokhn S. Comparison between photostimulable phosphor plates using one or two angulations and cone beam computed tomography scans in detecting root fracture in endodontically treated teeth. *J Oral Maxillofac Radiol* **2015**;3(2):44–8. <http://dx.doi.org/10.4103/2321-3841.157522>.
 27. Ezzodini Ardakani F, Razavi SH, Tabrizizadeh M. Diagnostic value of cone-beam computed tomography and periapical radiography in detection of vertical root fracture. *Iran Endod J* **2015**;10(2):122–6.
 28. Brady E, Mannocci F, Brown J, Wilson R, Patel S. A comparison of cone beam computed tomography and periapical radiography for the detection of vertical root fractures in nonendodontically treated teeth. *Int Endodontic J* **2013**;47(8):735–46. <http://dx.doi.org/10.1111/iej.12209>.
 29. Chavda R, Mannocci F, Andiappan M, Patel S. Comparing the *in vivo* diagnostic accuracy of digital periapical radiography with cone-beam computed tomography for the detection of vertical root fracture. *J Endo* **2014**;40(10):1524–29.
 30. Takeshita W, Vessoni Iwaki L, Da Silva M, Tonin R. Evaluation of diagnostic accuracy of conventional and digital periapical radiography, panoramic radiography, and cone-beam computed tomography in the assessment of alveolar bone loss. *Contemp Clin Dent* **2014**;5(3):318–23. <http://dx.doi.org/10.4103/0976-237X.137930>.
 31. Jakobson SJM, Westphalen VPD, Silva Neto UX, Fariniuk LF, Schroeder AGD, Carneiro E. The influence of metallic posts in the detection of vertical root fractures using different imaging examinations. *Dentomaxillofac Radiol* **2014**;43(1):20130287. <http://dx.doi.org/10.1259/dmfr.20130287>.
 32. da Silveira P, Vizzotto M, Liedke G, da Silveira H, Montagner F, da Silveira H. Detection of vertical root fractures by conventional radiographic examination and cone beam computed tomography – an *in vitro* analysis. *Dent Traumatol* **2012**;29(1):41–6. <http://dx.doi.org/10.1111/j.1600-9657.2012.01126.x>.
 33. Kambungton J, Janhom A, Prapayasatok S, Pongsiriwet S. Assessment of vertical root fractures using three imaging modalities: cone beam CT, intraoral digital radiography and film. *Dentomaxillofac Radiol* **2012**;41(2):91–5. <http://dx.doi.org/10.1259/dmfr/49798768>.
 34. Varshosaz M, Tavakoli M, Mostafavi M, Baghban A. Comparison of conventional radiography with cone beam computed tomography for detection of vertical root fractures: an *in vitro* study. *J Oral Sci* **2010**;52(4):593–7.
 35. Tsai P, Torabinejad M, Rice D, Azevedo B. Accuracy of cone-beam computed tomography and periapical radiography in detecting small periapical lesions. *J Endod* **2012**;38(7):965–70. <https://doi.org/10.1016/j.joen.2012.03.001>.

36. Metska M, Aartman I, Wesselink P, Özok A. Detection of vertical root fractures *in vivo* in endodontically treated teeth by cone-beam computed tomography scans. *J Endod* **2012**;38(10):1344–7. <http://dx.doi.org/10.1016/j.joen.2012.05.003>.
37. Bayat S, Talaiepour A, Sarlati F. Detection of simulated periodontal defects using cone-beam CT and digital intraoral radiography. *Dentomaxillofac Radiol* **2016**;45(6):20160030. <http://dx.doi.org/10.1259/dmfr.20160030>.
38. Bardal R, Jahanihashemi H, Mostafavi M, Kalhor E, Tofangchiha M, Dehghani M. Accuracy of cone beam computed tomography, photostimulable phosphor plate digital radiography and conventional radiography for detection of artificial cancellous bone defects. *J Dent (Tehran)* **2015**;12(11):797–806.
39. Bagis N, Kolsuz M, Kursun S, Orhan K. Comparison of intraoral radiography and cone-beam computed tomography for the detection of periodontal defects: an *in vitro* study. *BMC Oral Health* **2015**;15:64. <http://dx.doi.org/10.1186/s12903-015-0046-2>.
40. Takeshita W, Iwaki L, da Silva M, Sabio S, Ricardo P, Albino F. Comparison of periapical radiography with cone beam computed tomography in the diagnosis of vertical root fractures in teeth with metallic post. *J Conserv Dent* **2014**;17(3):225–9. <http://dx.doi.org/10.4103/0972-0707.131781>.
41. de Faria Vasconcelos K, Evangelista K, Rodrigues C, Estrela C, de Sousa T, Silva M. Detection of periodontal bone loss using cone beam CT and intraoral radiography. *Dentomaxillofac Radiol* **2012**;41(1):64–9. <http://dx.doi.org/10.1259/dmfr/13676777>.
42. dos Santos Corpas L, Jacobs R, Quirynen M, Huang Y, Naert I, Duyck J. Peri-implant bone tissue assessment by comparing the outcome of intra-oral radiograph and cone beam computed tomography analyses to the histological standard. *Clin Oral Implants Res* **2010**;22(5):492–9. <http://dx.doi.org/10.1111/j.1600-0501.2010.02029.x>.
43. Patel S, Dawood A, Mannocci F, Wilson R, Pitt Ford T. Detection of periapical bone defects in human jaws using cone beam computed tomography and intraoral radiography. *Int Endod J* **2009**;42(6):507–15. <http://dx.doi.org/10.1111/j.1365-2591.2008.01538.x>.
44. Grimard B, Hoidal M, Mills M, Mellonig J, Nummikoski P, Mealey B. Comparison of clinical, periapical radiograph, and cone-beam volume tomography measurement techniques for assessing bone level changes following regenerative periodontal therapy. *J Periodontol* **2009**;80(1):48–55. <http://dx.doi.org/10.1902/jop.2009.080289>.
45. Noujeim M, Prihoda T, Langlais R, Nummikoski P. Evaluation of high-resolution cone beam computed tomography in the detection of simulated interradicular bone lesions. *Dentomaxillofac Radiol* **2009**;38(3):156–62. <http://dx.doi.org/10.1259/dmfr/61676894>.
46. Vandenberghe B, Jacobs R, Yang J. Detection of periodontal bone loss using digital intraoral and cone beam computed tomography images: an *in vitro* assessment of bony and/or infrabony defects. *Dentomaxillofac Radiol* **2008**;37(5):252–60. <http://dx.doi.org/10.1259/dmfr/57711133>.
47. Bella F, Patel S, Duran-Sindreu F, Mercadé M, Bueno R, Roig M. Evaluating the periapical status of teeth with irreversible pulpitis by using cone-beam computed tomography scanning and periapical radiographs. *J Endod* **2012**;38(12):1588–91. <http://dx.doi.org/10.1016/j.joen.2012.09.003>.
48. Kruse C, Spin-Neto R, Wenzel A, Kirkevang L. Cone beam computed tomography and periapical lesions: a systematic review analysing studies on diagnostic efficacy by a hierarchical model. *Int Endod J* **2014**;48(9):815–28. <http://dx.doi.org/10.1111/iej.12388>.
49. Alkan B, Aral C, Aral K, Acer N, Şişman Y. Quantification of circumferential bone level and extraction socket dimensions using different imaging and estimation methods: a comparative study. *Oral Radiol* **2015**;32(3):145–53.
50. Gupta A, Devi P, Srivastava R, Jyoti B. Intra oral periapical radiography – basics yet intrigue: a review. *Bangladesh J Dent Res Educ* **2014**;4(2):83–7.
51. Rao K. Conventional dental radiography vs. advanced dental imageology. *J Indian Acad Oral Med Radiol* **2008**;20(2):77–80.
52. Scarfe W, Farman A. What is cone-beam CT and how does it work? *Dent Clin N Am* **2008**;52(4):707–30. <https://doi.org/10.1016/j.cden.2008.05.005>.