

# DT Journal

**3** 2021

**Journal of Diagnostics and  
Treatment of Oral and  
Maxillofacial Pathology**



Editors  
Oleksii Tymofieiev • Rui Fernandes  
(Kyiv, Ukraine • Jacksonville, FL, USA)



Official Journal of the  
Ukrainian Association for  
Maxillofacial and Oral Surgeons

[DTJournal.org](http://DTJournal.org)

# U-Impl<sup>®</sup>

SWITZERLAND



№ R3M 804 252 B2

Сертифікат відповідності  
технічного регламенту  
щодо медичних виробів



Switzerland Aarbergerstrasse 107A, CH-2502  
Biel, Phone/Fax +41 323230188  
info@u-impl.com  
www.u-impl.com

# About the Journal: Aims and Scope

MARCH 2021 • VOLUME 5 • ISSUE 3  
www.djournal.org

## Official Title

*Journal of Diagnostics and Treatment of Oral and Maxillofacial Pathology*

## Standard Abbreviation: ISO 4

*J. Diagn. Treat. Oral Maxillofac. Pathol.*

## International Standard Serial Number (ISSN)

Print ISSN 2519-2086 | Online ISSN 2522-1965

## Aims & Scope

This is a monthly peer-reviewed oral and maxillofacial surgery journal focused on: Microvascular and jaw reconstructive surgery, dental implants, salivary gland tumors/diseases, TMJ lesions, virtual surgical planning, implementation of ultrasonography into the practice of oral and maxillofacial surgeons.

## Editorial Board (EB) Composition

- EB shows significant geographic diversity representing 26 opinion leaders from 13 countries: Brazil, Canada, Colombia, Greece, Hong Kong (SAR, China), India, Israel, Italy, Slovak Republic, Spain, Ukraine, United Arab Emirates, and United States.
- The majority of the EB Members have a discernible publication history in Scopus, Web of Science, and journals with a high impact factor.
- The publication records of all EB members are consistent with the stated scope and published content of the journal.
- The journal has a several full-time professional editors.
- Gender distribution of the editors: 11.53% women, 88.47% men, 0% non-binary/other, and 0% prefer not to disclose.

## Frequency

12 print/online issues a year (from January 2020)

## Publication History

2017: 4 issues a year

2018: 4 issues a year

2019: 10 issues a year

From 2020: 12 issues a year

## Publishing Model

Journal combines a *hybrid* and *delayed open access* publishing models. The articles of all types, except Editorials, are immediately in open access. Editorials became an open access publication too after 3-month embargo period.

## Article Publishing Charge (APC)

During hard times of Covid-19 pandemic our journal trying to support authors by reducing the APC by 50%. And by the end of July 2021 the APC will be 100 USD and 50 USD (excluding taxes) depending on the article's type. Details at website: [dtjournal.org](http://dtjournal.org).

## 13 Types of Articles Currently Published by the Journal

Editorials/Guest Editorials/Post Scriptum Editorials, Images, Case Reports/Case Series, Original Articles, Review Articles, Discussions, Paper Scans (*synonyms*: Review of Articles, Literature Scan), Book Scans (*synonym*: Book Reviews), Letters to the Editor (*synonym*: Letters), and Viewpoints.

## Registration: Ministry of Justice of Ukraine

Registration: July 28, 2016

Re-Registration: May 21, 2019 (Certificate: KB # 23999-13839IIP)

## Co-Founders

1. Shupyk National Medical Academy of Postgraduate Education (from January-February 2021, the Academy receives a new name: Shupyk National Healthcare University of Ukraine).
2. Private Higher Educational Establishment "Kyiv Medical University."
3. OMF Publishing, Limited Liability Company.

## Publisher

OMF Publishing, LLC is an academic publisher focused on medical and linguistic sciences.

Address: 13-A Simferopolska Street, Office 121, Kyiv 02096, Ukraine.

## Crossref Membership

OMF Publishing, LLC is a member of Publishers International Linking Association, Inc. which doing business as a Crossref. OMF Publishing's active membership: From February 2017 to present.

## Official Journal of

Ukrainian Association for Maxillofacial and Oral Surgeons

## Ukrainian Association for Maxillofacial and Oral Surgeons (UAMOS)

Address: 4-A Profesora Pidvysotskoho Street, Kyiv 01103, Ukraine. Tel., fax: +38 044 528 35 17.

Website: [uamos.org](http://uamos.org).

## Subscription Index

In Ukraine: 60077 | In Donetsk/Luhansk Regions: 88263.

See page A5.

© 2021 OMF PUBLISHING, LLC

# Editorial Board

MARCH 2021 • VOLUME 5 • ISSUE 3  
www.djournal.org

## Editor in Chief

**Oleksii O. Tymofieiev, ScD**  
Kyiv, Ukraine

## Deputy Editor in Chief

**Rui P. Fernandes, MD, DMD, FACS, FRCS(Ed)**  
Jacksonville, Florida, United States

## Section Editors

### Bone Augmentation Techniques

**Nardy Casap, MD, DMD**  
Jerusalem, Israel

### Craniofacial Deformities

**Sunil Richardson, MDS**  
Nagercoil, Tamil Nadu, India

### Facial Feminization Surgery

**Kyle Keojampa, MD, FACS**  
Los Angeles, California, United States

### Facial Plastic Surgery

**Tirbod Fattahi, MD, DDS, FACS**  
Jacksonville, Florida, United States

### Head & Neck Oncologic Surgery

**Todd C. Hanna, MD, DDS, FACS**  
New York, New York, United States

### Head & Neck Radiology

**Anil T. Ahuja, MBBS, MD, FRCR, FHKCR, FHKAM**  
Hong Kong, SAR, China

### Images

**Camilo Mosquera, DDS**  
Bogotá, D.C., Colombia

### Orthognathic Surgery

**Mario Brinhole**  
São Paulo, São Paulo, Brazil

### Robotic Surgery

**Salam O. Salman, MD, DDS, FACS**  
Jacksonville, Florida, United States

### TMJ Lesions/Disorders

**Belmiro C. Vasconcelos, DDS, PhD**  
Recife, Pernambuco, Brazil

## Editorial Board Members

**Oleh M. Antonyshyn, MD, FRCS(C)**  
Toronto, Ontario, Canada

**Anthony M. Bunnell, MD, DMD, FACS**  
Jacksonville, Florida, United States

**Nur A. Hatab, DMD, PhD**  
Ras Al Khaimah, United Arab Emirates

**Andrey V. Kopchak, ScD**  
Kyiv, Ukraine

**Olindo Massarelli, MD, PhD, FEBOMFS**  
Sassari, Italy

**Anastasiya Quimby, DDS, MD**  
Fort Lauderdale, Florida, United States

**Daniel Robles Cantero, DDS, MSc**  
Madrid, Spain

**Peter Stanko, MD, PhD**  
Bratislava, Slovak Republic

**Olexander O. Tymofieiev, ScD**  
Kyiv, Ukraine

**Natalia O. Ushko, ScD**  
Kyiv, Ukraine

**Andrew Yampolsky, DDS, MD**  
Philadelphia, Pennsylvania, United States

## Web & Social Media Editor

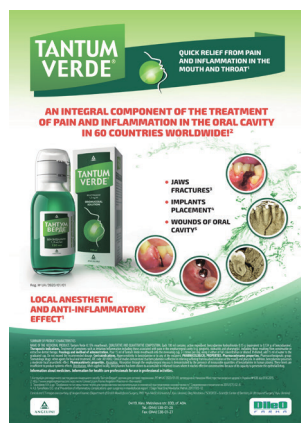**João L. Monteiro, DDS**  
Boston, Massachusetts, United States

## Director, Journal Development Department

**Evangelos G. Kilipiris, DMD**  
Thessaloniki, Greece | Bratislava, Slovak  
Republic

## Managing Editor

**Ievgen I. Fesenko, PhD**  
Kyiv, Ukraine



# TANTUM VERDE®

INFORMATION LEAFLET  
for the medicinal product

### Composition:

**active substance: benzydamine hydrochloride;**  
100 mL of solution contain benzydamine hydrochloride 0.15 g;

**excipients:** ethanol 96%, glycerol, methyl parahydroxybenzoate (E 218), flavor (menthol), saccharin, sodium hydrocarbonate, Polysorbate 20, Quinoline Yellow (E 104), Patent Blue V (E 131), purified water.

**Dosage form.** Oromucosal solution.

**Basic physical and chemical properties:** a clear green liquid with a typical mint flavor.

**Pharmacotherapeutic group.** Dental preparations. Other agents for local oral treatment.

ATC code: A01A D02.

### Pharmacological properties.

#### Pharmacodynamics.

Benzydamine is a non-steroidal anti-inflammatory drug (NSAID) with analgesic and antiexudative properties.

Clinical studies have shown that benzydamine is effective in the relief of symptoms accompanying localized irritation conditions of the oral cavity and pharynx. Moreover, benzydamine has anti-inflammatory and local analgesic properties, and also exerts a local anesthetic effect on the oral mucosa.

#### Pharmacokinetics.

Absorption through the oral and pharyngeal mucosa has been proven by the presence of measurable quantities of benzydamine in human plasma. However, they are insufficient to produce any systemic pharmacological effect. The excretion occurs mainly in urine, mostly as inactive metabolites or conjugated compounds.

When applied locally, benzydamine has been shown to cumulate in inflamed tissues in an effective concentration

due to its ability to permeate through the mucous membrane.

### Clinical particulars.

#### Indications.

Symptomatic treatment of oropharyngeal irritation and inflammation; to relieve pain caused by gingivitis, stomatitis, pharyngitis; in dentistry after tooth extraction or as a preventive measure.

#### Contraindications.

Hypersensitivity to the active substance or to any other ingredients of the product.

### Interaction with other medicinal products and other types of interaction.

No drug interaction studies have been performed.

### Warnings and precautions.

If sensitivity develops with long-term use, the treatment should be discontinued and a doctor should be consulted to get appropriate treatment.

In some patients, buccal/pharyngeal ulceration may be caused by severe pathological processes. Therefore, the patients, whose symptoms worsen or do not improve within 3 days or who appear feverish or develop other symptoms, should seek advice of a physician or a dentist, as appropriate.

Benzydamine is not recommended for use in patients hypersensitive to acetylsalicylic acid or other non-steroidal anti-inflammatory drugs (NSAIDs).

The product can trigger bronchospasm in patients suffering from or with a history of asthma. Such patients should be warned of this.

For athletes: the use of medicinal products containing ethyl alcohol might result in positive antidoping tests considering the limits established by some sports federations.

#### *Use during pregnancy or breast-feeding*

No adequate data are currently available on the use of benzydamine in pregnant and breastfeeding women. Excretion of the product into breast milk has not been studied. The findings of animal studies are insufficient to make any conclusions about the effects of this product during pregnancy and lactation.

The potential risk for humans is unknown.

TANTUM VERDE should not be used during pregnancy or breast-feeding.

#### *Effects on reaction time when driving or using machines*

When used in recommended doses, the product does not produce any effect on the ability to drive and operate machinery.

#### **Method of administration and doses.**

Pour 15 mL of TANTUM VERDE solution from the bottle into the measuring cup and gargle with undiluted or diluted product (15 mL of the measured solution can be diluted with 15 mL of water). Gargle 2 or 3 times daily. Do not exceed the recommended dose.

#### *Children.*

The product should not be used in children under 12 years due to a possibility of ingestion of the solution when gargling.

#### **Overdosage.**

No overdose has been reported with benzydamine when used locally. However, it is known that benzydamine, when ingested in high doses (hundreds times higher than those possible with this dosage form), especially in children, can cause agitation, convulsions, tremor, nausea, increased sweating, ataxia, and vomiting. Such acute overdose requires immediate gastric lavage, treatment of fluid/salt imbalance, symptomatic treatment, and adequate hydration.

#### **Adverse reactions.**

Within each frequency group, the undesirable effects are presented in order of their decreasing seriousness.

Adverse reactions are classified according to their frequency: very common ( $\geq 1/10$ ); common ( $\geq 1/100$  to  $<1/10$ ); uncommon ( $\geq 1/1,000$  to  $<1/100$ ); rare ( $\geq 1/10,000$  to  $<1/1,000$ ); very rare ( $<1/10,000$ ); frequency unknown (cannot be estimated from the available data).

*Gastrointestinal disorders:* rare – burning mouth, dry mouth; *unknown* – oral hypesthesia, nausea, vomiting, tongue edema and discoloration, dysgeusia.

*Immune system disorders:* rare – hypersensitivity reaction, *unknown* – anaphylactic reaction.

*Respiratory, thoracic and mediastinal disorders:* very rare – laryngospasm; *unknown* – bronchospasm.

*Skin and subcutaneous tissue disorders:* uncommon – photosensitivity; very rare – angioedema; *unknown* – rash, pruritus, urticaria.

*Nervous system disorders:* *unknown* – dizziness, headache.

TANTUM VERDE contains methyl parahydroxybenzoate, which can cause allergic reactions (including delayed-type reactions).

**Shelf life.** 4 years.

#### **Storage conditions.**

Do not store above 25°C. Keep out of reach of children.

#### **Packaging.**

120 mL of solution in a bottle with a measuring cup; 1 bottle per cardboard box.

#### **Dispensing category.**

Over-the-counter medicinal product.

#### **Manufacturer.**

Aziende Chimiche Riunite Angelini Francesco A.C.R.A.F. S.p.A., Italy.

Location of the manufacturer and its business address.  
Via Vecchia del Pinocchio, 22 – 60100 Ancona (AN), Italy.

#### **Date of the last revision of the text.**

September 26, 2018.

Information leaflet is

**APPROVED** by

Order of the

**Ministry of Health of Ukraine**

No. 636 dated 01.10.2015

**Registration Certificate**

No. UA/3920/01/01

# Subscription in Ukraine

MARCH 2021 • VOLUME 5 • ISSUE 3  
www.dtjournal.org

Frequency of the *Journal of Diagnostics and Treatment of Oral and Maxillofacial Pathology*:  
12 issues (synonym: numbers) a year.

Subscription index in Ukraine: 60077.

Subscription index for Donetsk and Luhansk Regions: 88263.



Three ways of individual/institutional subscription of print version of the *Journal*:

1. At Ukrposhta post offices.
2. At the website [www.presa.ua](http://www.presa.ua).
3. At the website [www.dtjournal.org](http://www.dtjournal.org)

Issues	Fee in 2021
1 Issue	\$1.35 (37.88 UAH)
3 Issues	\$3.95 (110.64 UAH)
6 Issues	\$7.65 (214.28 UAH)
12 Issues	\$15.11 (423.36 UAH)

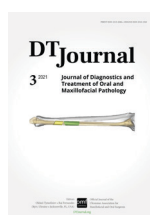

QR code leads to  
Journal subscription

# Content

of the Volume 5 • Issue 3 • March 2021

- A1 **Publisher & Editorial Office Information**
- A2 **Editorial Board**
- A5 **Subscription in Ukraine**
- A6 **Content, Courtesy, & Erratum**
- GUEST 33 **Business Articles and Section in the World Leading Jaw-Face Reconstruction Journals**  
Ivan V. Nagorniak, & Nataliia M. Koba
- GUEST 35 **Gnathology, Occlusion, Oral Surgery and Other Sections in CRANIO® Journal**  
Zinaida Y. Zhehulovych, Maryna M. Stoliarchuk, & Viktoriia M. Holodenko
- CASE 36 **Multilocular Simple Bone Cyst of the Mandible: Part 2: Histopathologic Appearance and Brief Review of the Literature**  
Oleksandr A. Nozhenko, Pavlo P. Snisarevskyi, & Valentyna I. Zaritska



## COURTESY

*Journal's* cover image (virtual surgical planning for a segmental mandibular reconstruction with fibula transplant) is courtesy of Rui P. Fernandes, MD, DMD, FACS, FRCS.

Image was taken from the article: Fernandes RP, Quimby A, Salman S. Comprehensive reconstruction of mandibular defects with free fibula flaps and endosseous implants. *J Diagn Treat Oral Maxillofac Pathol* 2017;1(1):6–10.





GUEST

## Business Articles and Section in the World Leading Jaw-Face Reconstruction Journals

Ivan V. Nagorniak<sup>a,\*</sup> & Nataliia M. Koba<sup>b</sup>

*To be successful, you have to have your heart in your business, and your business in your heart.*

—Thomas Watson, Sr., former CEO, IBM

Private practice in the recent years became not only an important part of the general dentistry<sup>1,2</sup> but also the plastic surgery,<sup>3,4</sup> facial feminization surgery<sup>5</sup>, and oral and maxillofacial surgery (OMS)<sup>6,7</sup>. So the appearance of Business and Practice Management articles<sup>3,4</sup> indicates that surgical communities start to understand the importance of business direction not only from practical appliance but also from the scholar analysis which became extremely demanded in pre-pandemic and in a current pandemic era.

In 2021, the *Plastic and Reconstructive Surgery—Global Open (PRS Global Open)* journal became a role-model publication for other journals both in plastic surgery and in an oral-maxillofacial surgery due to the launch of Business section. Cat Begovic, MD from California started to lead that new cutting-edge section in *PRS Global Open* as a founding section editor.

Moreover, such a timely and extremely demanded

section cannot be ignored by other surgical journals, especially the publications related with Oral and Maxillofacial Surgery. That is why it can be so important for the *Journal of Diagnostics and Treatment of Oral and Maxillofacial Pathology* to launch the Section Business in the nearest 2021-2022 period. The goal of which will be to review and to publish the best manuscripts dedicated to analysis of private OMS practice sector. And the articles like “Practice management in oral and maxillofacial surgery” recently presented in the *Oral and Maxillofacial Surgery Clinics of North America* journal show us how the state of the art manuscripts should be prepared for that new section.<sup>7</sup> Analysis of practice ownership forms, role of investors, accounting and tax, marketing, revenue cycle and staff management, and more others business features should be meticulously investigated in a way which will help others to follow their dream moving own private OMS practice forward.

*Play by the rules, but be ferocious.*

—Phil Knight

Co-founder of Nike

Kyiv, Ukraine

<sup>a</sup> MSc, PhD, Head Physician, Private Practice.

<sup>b</sup> MSc, Former Head Physician, Private Practice—SCIEDECE LTD.

\* Corresponding author's address: Private Practice (certificate for management system according to ISO 9001:2015 – Private Entrepreneur Nagorniak I.V.), 6-G Andruschenka Street, Office 6, Kyiv 01135, Ukraine  
E-mail: [ivan.nagorniak@gmail.com](mailto:ivan.nagorniak@gmail.com) (Ivan Nagorniak)

Please cite this article as: Nagorniak IV, Koba NM. Business articles and section in the world leading jaw-face reconstruction journals. *J Diagn Treat Oral Maxillofac Pathol* 2021;5(3):33–4.

<https://dx.doi.org/10.23999/j.dtopm.2021.3.1>

© 2021 OMF Publishing, LLC. This is an open access article under the CC BY license (<http://creativecommons.org/licenses/by-nc/4.0/>).

## REFERENCES

1. Wu, KY, Wu, DT, Nguyen, TT, Tran, SD. COVID-19's impact on private practice and academic dentistry in North America. *Oral Dis* **2021**;27( Suppl 3): 684– 7. <https://doi.org/10.1111/odi.13444>
2. Loretto C. The case for private practice. *Am J Orthod Dentofacial Orthop* **2017**;151(2):243–4. . <https://doi.org/10.1016/j.ajodo.2016.11.017>
3. Reece EM, Tanna N, Rohrich RJ. The missing link: the business of plastic surgery. *Plast Reconstr Surg* **2020**;146(4):905–12. <https://doi.org/10.1097/PRS.00000000000007182>
4. Zarrabi B, Burce KK, Seal SM, Lifchez SD, Redett RJ, Frick KD, Dorafshar AH, Cooney CM. Business education for plastic surgeons: a systematic review, development, and implementation of a business principles curriculum in a residency program. *Plast Reconstr Surg*. 2017 May;139(5):1263–71. <https://doi.org/10.1097/PRS.00000000000003290>
5. Raffaini M, Perello R, Tremolada C, Agostini T. Evolution of full facial feminization surgery: creating the gendered face with an all-in-one procedure. *J Craniofac Surg* **2019**;30(5):1419–24. <https://doi.org/10.1097/SCS.00000000000005221>
6. Zhou S. Prof. James Hupp: an academic career vs. private practice of oral and maxillofacial surgery. *Front Oral Maxillofac Med* **2019**;1:2. <https://doi.org/10.21037/fomm.2019.06.01>
7. Baker J, Leavitt A, Jundt JS. Practice management in oral and maxillofacial surgery. *Oral Maxillofac Surg Clin North Am* **2019**;31(4):601–9. <https://doi.org/10.1016/j.j.coms.2019.07.004>



GUEST

## Gnathology, Occlusion, Oral Surgery and Other Sections in CRANIO® Journal

Zinaida Y. Zhehulovych<sup>a,\*</sup>, Maryna M. Stoliarchuk<sup>b</sup>, & Viktoriia M. Holodenko<sup>c</sup>

**C**RANIO®: the Journal of Craniomandibular and Sleep Practice (further CRANIO®) is a 40-year-old multidisciplinary peer-reviewed publication devoted to temporomandibular and sleep disorders.<sup>1</sup> Formerly (from the launch in 1982 to 1985), it was named *Journal of Craniomandibular Practice*.<sup>1</sup> The 2019 impact factor of the CRANIO® became 1.173. This unique bi-monthly journal holds seventy-sixth from 141 positions in the category Dentistry (miscellaneous) and sixty-sixth from 107 positions in the category Otorhinolaryngology.<sup>2</sup>

As our team works deeply in the multidisciplinary Center which includes gnathologist, orthodontist, general dentists, and oral-maxillofacial surgeons the articles from the sections of the CRANIO® like “Gnathology,” “Occlusion,” “Craniofacial Pain,” “Sleep,” and “Oral Surgery” stick our great interest and passion.<sup>3,4</sup>

Looking through the CRANIO®'s portfolio of issues, many head and neck practitioners, academia workers and even other journals can absorb a lot of progressive developments. Moreover, the profound analysis of that beautiful publication is definitely indicated and

we will apply our efforts to highlight that research in the future issues of the *Journal of Diagnostics and Treatment of Oral and Maxillofacial Pathology*.

### REFERENCES

1. CRANIO® – The Journal of Craniomandibular and Sleep Practice [document on the internet]; February 27, 2021 [cited 2021 Feb 27]. Available from: <https://www.tandfonline.com/loi/ycra20>
2. SJR: CRANIO – The Journal of Craniomandibular and Sleep Practice [document on the internet]; February 27, 2021 [cited 2021 Feb 27]. Available from: <https://www.scimagojr.com/journalsearch.php?q=29913&tip=sid>
3. Valentino R, Cioffi I, Vollaro S, Cimino R, Baiano R, Michelotti A. Jaw muscle activity patterns in women with chronic TMD myalgia during standardized clenching and chewing tasks. *Cranio* 2021;39(2):157–63. <https://doi.org/10.1080/08869634.2019.1589703>
4. Şentürk MF, Yıldırım D, Bilgir E. Evaluation of ultrasonography guidance for single-puncture temporomandibular joint arthrocentesis: a randomized clinical study. *Cranio* 2019;37(3):181–7. <https://doi.org/10.1080/08869634.2017.1407095>

Kyiv, Ukraine

<sup>a</sup> ScD, Professor, Department of Dentistry, Institute of Postgraduate Education, Bogomolets National Medical University

<sup>b</sup> Head, Department of Dentistry, Center of Maxillofacial Surgery and Dentistry, Kyiv Regional Clinical Hospital.

<sup>c</sup> Year 1 Intern, 2-Year Internship Program, Center of Maxillofacial Surgery and Dentistry, Kyiv Regional Clinical Hospital.

\* Corresponding author's address: Center of Maxillofacial Surgery and Dentistry, Kyiv Regional Clinical Hospital, 1 Bahovutivska Street, Kyiv 04107, Ukraine.  
E-mail: [zhegulovich@gmail.com](mailto:zhegulovich@gmail.com) (Zinaida Zhehulovych)

Please cite this article as: Zhehulovych ZY, Stoliarchuk MM, Holodenko VM. Gnathology, occlusion, oral surgery and other sections in CRANIO® Journal. *J Diagn Treat Oral Maxillofac Pathol* 2021;5(3):35.

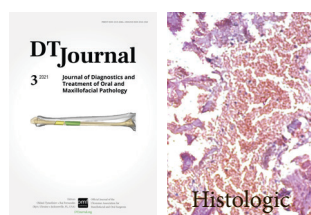
Paper received 27 February 2021

Accepted 03 March 2021

Available online 31 March 2021

<https://dx.doi.org/10.23999/j.dtmp.2021.3.2>

© 2021 OMF Publishing, LLC. This is an open access article under the CC BY license (<http://creativecommons.org/licenses/by-nc/4.0/>).



## CASE

# Multilocular Simple Bone Cyst of the Mandible: Part 2: Histopathologic Appearance and Brief Review of the Literature

Oleksandr A. Nozhenko<sup>a,\*</sup>, Pavlo P. Snisarevskiy<sup>b</sup>, & Valentyna I. Zaritska<sup>c</sup>

## SUMMARY

The purpose of this report is to highlight the histopathologic appearance of the mandibular simple bone cyst (SBC) – a pathologic condition which continues to stay an enigma for a lot of colleagues. Cone-beam computed tomography of a two-chamber SBC (ie, multilocular type) of the mandibular body in a 41-year-old white female is analyzed. Brief literature review is also performed giving the possibility to understand all intraoperative appearances of the SBCs and contemporary techniques of its management.

Kyiv, Ukraine

<sup>a</sup> Physician-Surgeon-Dentist, Center of Maxillofacial Surgery, Kyiv Regional Clinical Hospital.

<sup>b</sup> Head, Department of Pathomorphology, Kyiv Regional Clinical Hospital.

<sup>c</sup> PhD, Associate Professor, Department of Pathology, Shupyk National University of Healthcare of Ukraine.

\* Corresponding author's address: Center of Maxillofacial Surgery, Kyiv Regional Clinical Hospital, 1 Bahhovutivska Street, Kyiv 04107, Ukraine.  
E-mail: [alexdent@ukr.net](mailto:alexdent@ukr.net) (Oleksandr Nozhenko)  
Facebook: [Oleksandr Nozhenko](https://www.facebook.com/OleksandrNozhenko)

Please cite this article as: Nozhenko OA, Snisarevskiy PP, Zaritska VI. Multilocular simple bone cyst of the mandible: part 2: histopathologic appearance and brief review of the literature. *J Diagn Treat Oral Maxillofac Pathol* 2021;5(3):36–42.

The word 'Histologic' at the upper right icon means that article contains presentation of the histological appearance.

Paper received 14 December 2020

Accepted 15 January 2021

Available online 31 March 2021

<https://dx.doi.org/10.23999/j.dtemp.2021.3.3>

© 2021 OMF Publishing, LLC. This is an open access article under the CC BY license (<http://creativecommons.org/licenses/by-nc/4.0/>).

## INTRODUCTION

Simple bone cyst (SBC) is an intraosseous pseudocyst (ie, nonepithelial-lined bone cavity)<sup>1</sup> which may be uni- or multilocular.<sup>2</sup> Rudolf Virchow was a first one who recognized the SBCs in the long bones and published the report “About the formation of bone cysts” in 1876.<sup>3</sup> Such type of cysts located in a jaw bone was first discussed by Carl Lucas in the report of Theodor Blum in 1929 where traumatic injury was determined as causative factor.<sup>4</sup>

The SBC belongs to one of four types of jaws' pseudocysts<sup>5</sup>:

1. Aneurismal (haemorrhagic-aneurismal)<sup>6</sup> bone cysts.
2. Traumatic (ie, simple) bone cysts.
3. Static bone cysts (ie, Stafne's bone defects).
4. Focal osteoporotic bone marrow defect.

SBC is named in the literature as *hemorrhagic bone cyst*,<sup>7,8</sup> *traumatic cyst*,<sup>9</sup> *extravasation cyst*,<sup>10</sup> *progressive bone cavity*,<sup>11</sup> *solitary bone cyst*,<sup>12</sup> *idiopathic bone cavity*,<sup>13</sup> and *single-chamber bone cyst*.<sup>14,1</sup> Tymofieiev terms such type of cyst as a *sheathless* (ie, *capsuleless*) cyst (synonym: *post-traumatic cyst*).<sup>15</sup>

According to Olvi et al SBCs involve extra-maxillofacial bones in the next distribution: proximal humerus (in 50 percent), proximal femur (in 25 percent), and proximal tibia.<sup>16</sup> That statistics proves the fact that in 90 percent the SBCs involves metaphysis of the long bones.<sup>17</sup>

In the first part of our work<sup>2</sup> we presented the data of a 41-year-old white female with a multilocular type of mandibular SBC. Consecutive cone-beam computed tomography (CBCT) scans and surgical technique were analyzed.<sup>2</sup>

The purpose of this report is to highlight the histopathologic appearance of the mandibular SBC – a pathologic condition which continues to stay an enigma for a lot of colleagues.<sup>17</sup>

## CASE

A 41-year-old white female with a two-chamber SBC (ie, multilocular type) of the mandibular body (ie, corpus) was treated in the Center of Maxillofacial Surgery.<sup>2</sup> The preliminary diagnosis was confirmed by anamnesis, CBCT data (Fig 1), vitality of the

involved teeth, and asymptomatic course.<sup>2</sup>

Firstly, a biopsy was performed in the area of anterior bony chamber of the cystic lesion and a 1.0 ml of serous fluid was obtained after trepanation of buccal cortical plate. Specimen was received by curettage of the bone walls of the intraosseous cavity. Histology showed blood clots in the huge areas of fibrous tissue and collagen.<sup>2</sup> A 5-month follow-up CBCT demonstrated complete fulfillment of the anterior chamber by a new bone tissue (Fig 2).

Second surgery included curettage of the posterior chamber of the cyst (where a small sponge bone particles were obtained) (Fig 3) and bone grafting with xenograft (BIO-GEN® MIX [cancellous-cortical] Bioteck S.p.A., Vicenza, Italy). Histopathological examination revealed the appearance similar to the appearance presented in the study of Xanthinaki et al (reported a 25-year-old white female with a SBC of the ramus),<sup>18</sup> and showed the parts of vascular connective tissue and bone spicules (Fig 4).

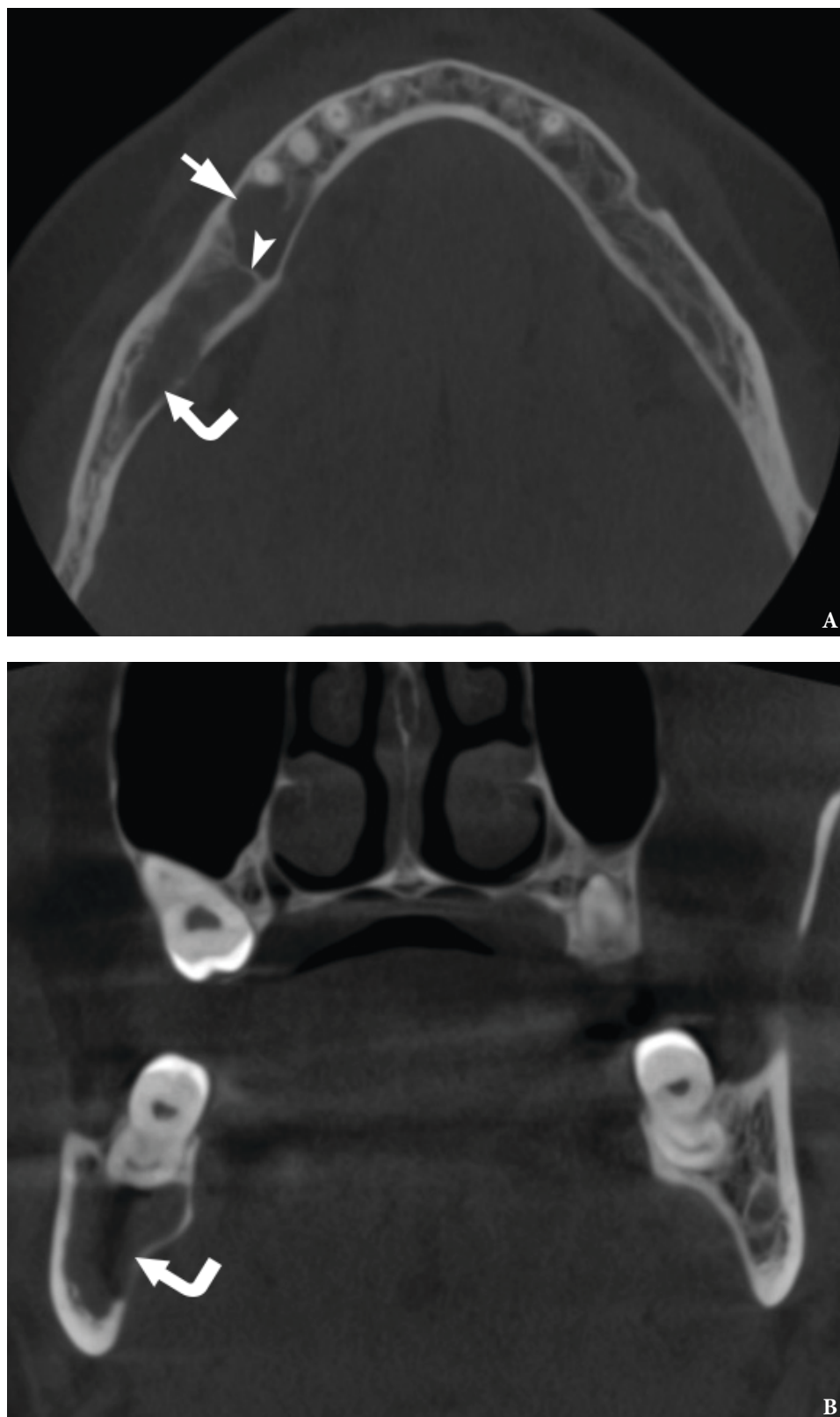
## DISCUSSION

SBCs is a rare clinical entity reaching only 1.05 percent among all jaw cysts.<sup>19</sup> Multilocular type of SBCs is even more rare and counts from 6.38 to 26.92 percent of total number of SBCs.<sup>20,21</sup>

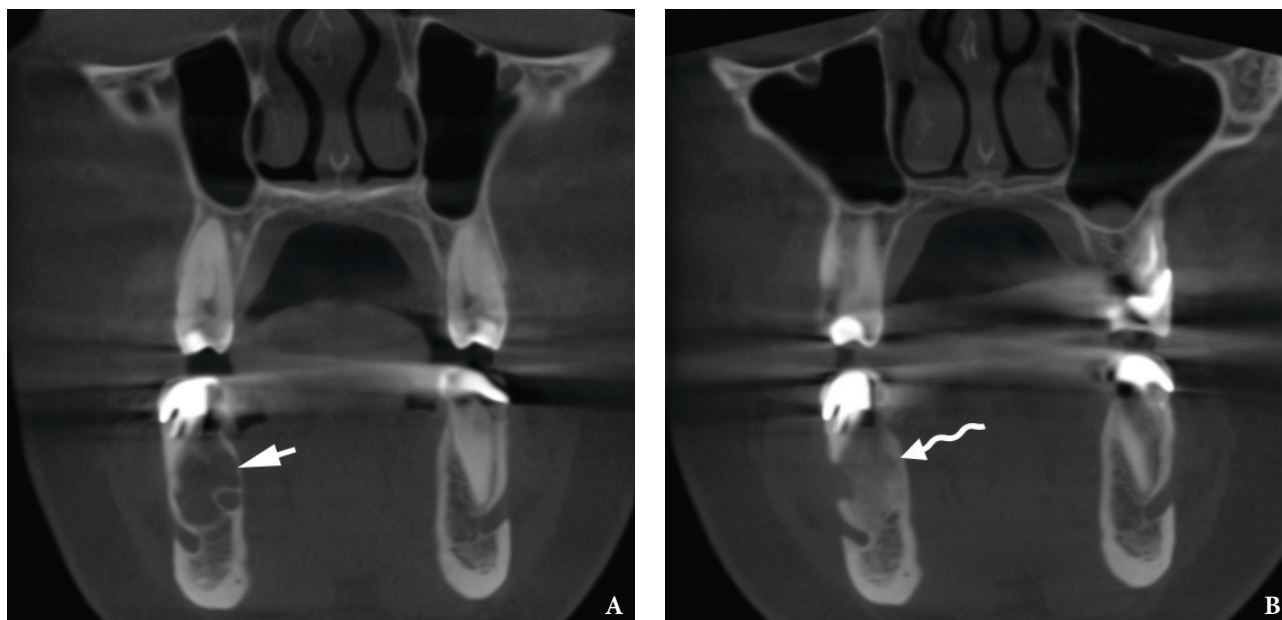
Already published multichamber variants of SBCs showed that the *single-chamber bone cyst* term cannot be applied to all SBCs as the published data and our case are proving the existence of two types of SBCs – uni- and multilocular.

You et al in 2017 analyzed 30 idiopathic bone cavities (ie, SBCs); and their study revealed next distribution of 30 idiopathic bone cavities in 27 patients:<sup>13</sup> in 13 cases the cysts localized in the right posterior mandible, in 11 cases – in the left posterior mandible, in 5 cases – in symphyseal area, and only in one case the cyst was found at the left lateral maxilla.<sup>13</sup> Thus, our case proves the majority cases data of You et al, in which SBCs were localized in the right posterior mandible.

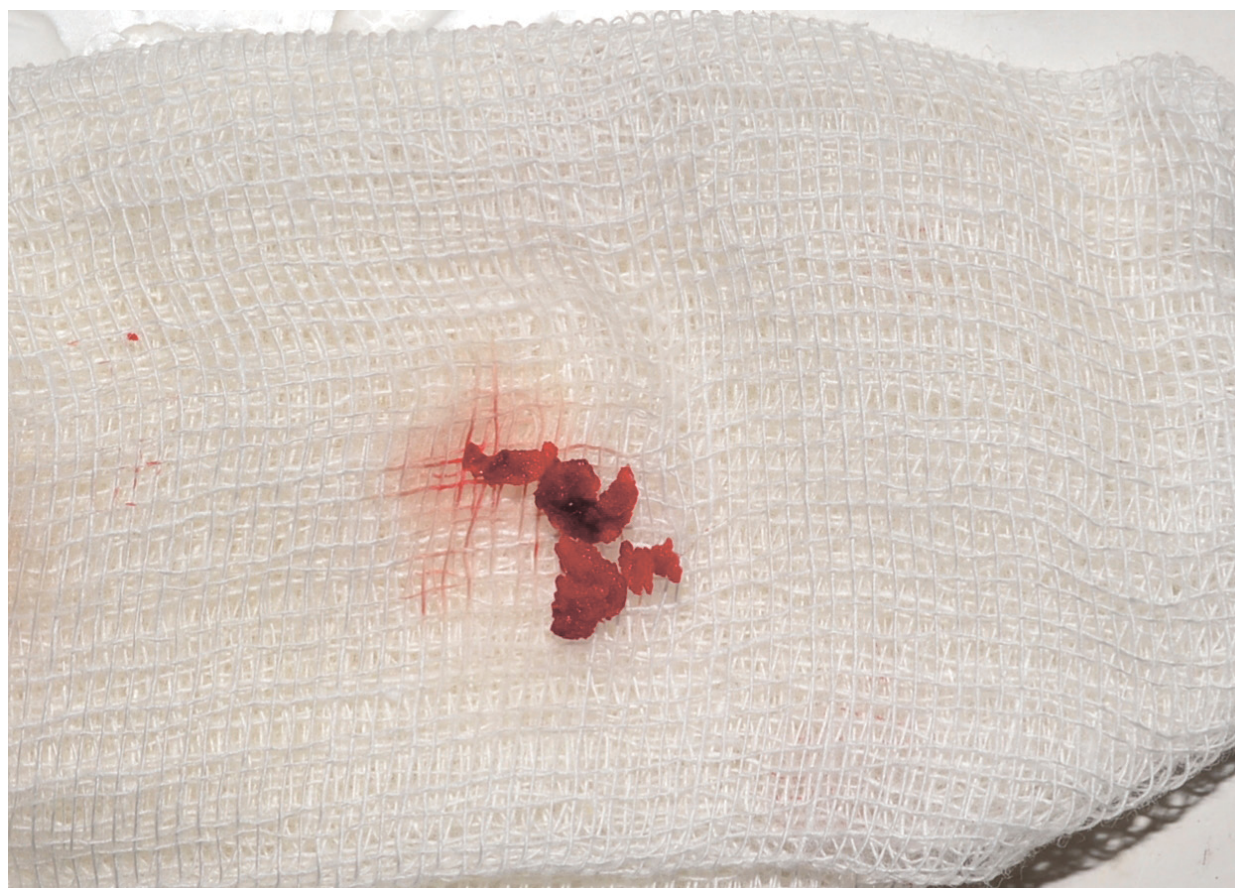Pseudocystic histological features of the SBCs have been proved by numerous publications. Discussion of twenty-two cases and treated by curettage in the study of Demirbas et al had shown next histopathological findings: loose connective tissue (n = 3 [13.6 percent]), empty (n = 16 [61.5 percent]), fluid content (n = 4 [18.1 percent]), and



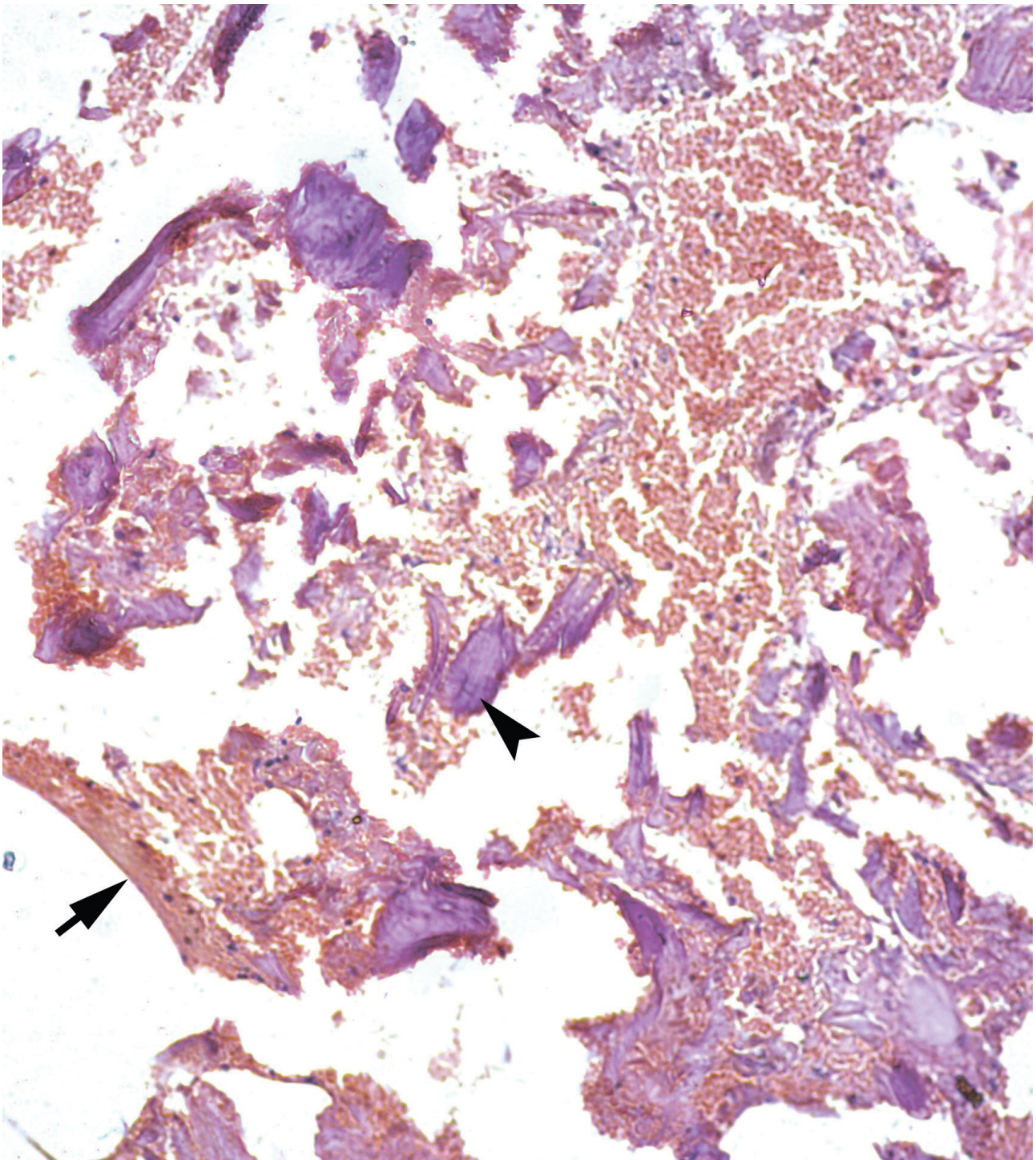
**FIGURE 1.** Axial (A) and coronal (B) CBCT scans of a 41-year-old white female with a multilocular SBC of the right mandible. The bone septa (*arrowhead*) divides the pseudocyst into anterior (*arrow*) and posterior (*curved arrow*) camera (ie, chamber). Printed with permission and copyrights retained by O.A.N.



**FIGURE 2.** **A**, a pre-biopsy coronal CBCT scan showed anterior chamber of mandibular SBC (*arrow*). **B**, a 5-month follow-up coronal CBCT scan demonstrates fulfillment of the anterior chamber by a new bone tissue (*waved arrow*). Printed with permission and copyrights retained by O.A.N.



**FIGURE 3.** Specimen (small sponge bone particles) received by curettage of the intraosseous cavity. Printed with permission and copyrights retained by O.A.N.



**FIGURE 4.** A 41-year-old white female with a multilocular type of SBC of the right mandible. Histological appearance, similar to the appearance presented in the study of [Xanthinaki et al](#) (reported a 25-year-old white female with a SBC of the ramus),<sup>18</sup> showed the parts of vascular connective tissue (*arrow*) and bone spicules (*arrowhead*) (hematoxylin and eosin stain, original magnification  $\times 10$ ). Printed with permission and copyrights retained by V.I.Z. and P.P.S.



osseous-like tissue (n = 3 [13.6 percent]).<sup>19</sup>

Bimaxillary SBC case (two – intramandibular cysts and one – intramaxillary cyst) of **Saldaña** et al macroscopically revealed samples of liquid content, bone tissue and cavity membranes, and microscopically – fibro-cellular wall with highly vascularized areas, multi-nucleated giant cells mainly in areas of hemorrhage.<sup>14</sup>

**Xanthinaki** et al inside the cavity of the intramandibular SBC have found only extremely thin layer of connecting tissue and only in some places.<sup>18</sup>

SBC in the paper of **Velasco** et al which showed the cystic evolution (growth after first surgery) contained mild haematogenous liquid and histologically presented vital lamellar bone tissue and recent hemorrhage areas.<sup>22</sup>

Despite the report of **Matsuda** et al presents the floating inferior alveolar neurovascular bundle in a large SBC involved mandibular body, in our case the bundle was just displaced inferiorly.<sup>23</sup>

The article by **Chell** et al should be a warning to physicians who have cases of SBCs because the mandibles weakened by such asymptomatic cysts may become more prone to fractures.<sup>24</sup>

Treatment options for SBCs are perfectly described in a recent orthopedic and oral-maxillofacial surgery works.<sup>2,20</sup> Three management strategies for jaws' SBCs became the most popular: 1) bone perforation and stimulation of blood clot formation, 2) curettage of the cavity and flap repositioning and suture, 3) decompression and warm saline solution irrigation.<sup>2</sup>

In our case we combined two surgical techniques in two separated chambers of the SBC. Both techniques showed efficacy in fulfillment of the cystic cavities and can be recommended for the usage in similar cases giving preference to the surgical exploration and gentle curettage.<sup>13</sup>

## CONCLUSION

The simple bone cyst as an asymptomatic intraosseous pseudocystic entity is proved to be effectively managed applying different strategies, giving minimally invasive techniques a clear priority. Histopathological findings of the simple bone cysts' specimens are well-documented and leave no space for possible malignization of such types of cyst due to the absence of true cystic lining.

## AUTHOR CONTRIBUTION

Conceptualization: Nozhenko OA. Data and interpretation acquisition: Nozhenko OA, Snisarevskiy PP, Zaritska VI. Drafting of the manuscript: Nozhenko OA. Critical revision of the manuscript: Snisarevskiy PP, Nozhenko OA, Zaritska VI. Approval of the final version of the manuscript: all authors.

## REFERENCES

1. Rattana P. Simple bone cyst of the anterior mandible: a case report. *JOJ Case Stud* **2017**;4(1):555626. <https://doi.org/10.19080/JOJCS.2017.04.555626>
2. Nozhenko OA, Zaritska VI, Snisarevskiy PP, Fesenko II. Case report: multilocular type of mandibular simple bone cyst. Part 1: cone beam computed tomography (CBCT) findings, revision of the synonyms and treatment strategies. *J Diagn Treat Oral Maxillofac Pathol* **2018**;2(4):179–85. <https://doi.org/10.23999/j.dtmp.2018.4.6>
3. Virchow RLL. Über die Bildung von Knochencysten. *Acad Mber* **1876**;369–81.
4. Lucas CD: Discussion. In Blum T: Do all cysts of the jaw originate from the dental system? *J Am Dent Assoc* **1929**;16(4):647–61. <https://doi.org/10.14219/jada.archive.1929.0086>
5. Regezi JA, Sciubba JJ, Jordan RCK. Oral pathology. 7th ed. Cysts of the jaws and neck. St. Louis, Missouri: Saunders **2017**. 245–68.
6. Grecchi F, Zollino I, Candotto V, Gallo F, Rubino G, Bianco R, Carinci F. A case report of haemorrhagic-aneurismal bone cyst of the mandible. *Dent Res J (Isfahan)* **2012**;9(Suppl 2):S222–4. <https://doi.org/10.4103/1735-3327.109763>
7. Howe GL. 'Haemorrhagic cysts' of the mandible. I. *Br J Oral Surg* **1965**;3(1):55–76. [https://doi.org/10.1016/s0007-117x\(65\)80008-7](https://doi.org/10.1016/s0007-117x(65)80008-7)
8. Howe GL. 'Haemorrhagic cysts' of the mandible. II. *Br J Oral Surg* **1965**;3(2):77–91. [https://doi.org/10.1016/s0007-117x\(65\)80011-7](https://doi.org/10.1016/s0007-117x(65)80011-7)
9. Freedman GL, Beigleman MB. The traumatic bone cyst: a new dimension. *Oral Surg Oral Med Oral Pathol* **1985**;59(6):616–18. [https://doi.org/10.1016/0030-4220\(85\)90191-4](https://doi.org/10.1016/0030-4220(85)90191-4)
10. Boyne PJ. Treatment of extravasation cysts with freeze-dried homogenous bone grafts. *J Oral Surg (Chic)* **1956**;14(3):206–12.
11. Whinery JG. Progressive bone cavities of the mandible: a review of the so-called traumatic bone

- cyst and a report of three cases. *Oral Surg Oral Med Oral Pathol* **1955**;8(9):903–16.  
[https://doi.org/10.1016/0030-4220\(55\)90289-9](https://doi.org/10.1016/0030-4220(55)90289-9)
12. Wong-Romo G, Carrillo-Terán E, Ángeles-Varela E. Solitary mandibular bone cyst. Case report and literature review. Quiste óseo solitario mandibular. Reporte de un caso y revisión de la literature. *Rev Odont Mex* **2016**;20(2):114–22.  
<https://doi.org/10.1016/j.rodmed.2016.04.007>
  13. You MS, Kim DY, Ahn KM. Surgical management of idiopathic bone cavity: case series of consecutive 27 patients. *J Korean Assoc Oral Maxillofac Surg* **2017**;43(2):94–9.  
<https://doi.org/10.5125/jkaoms.2017.43.2.94>
  14. Saldaña SA, Gómez PBA, Díaz CR, Castillo GH. Maxillary and mandibular solitary bone cyst. Case report and literature review. *Revista Odontológica Mexicana* **2018**;22(1):39–44.
  15. Tymofiev OO. Manual of maxillofacial and oral surgery [Russian]. 5th ed. Kyiv, Ukraine: Chervona Ruta-Turs; **2012**.
  16. Olvi LG, Lembo GM, Velan O, Santini-Araujo E. Simple bone cyst. In: Santini-Araujo E, Kalil R, Bertoni F, Park YK, eds. Tumors and tumor-like lesions of bone. 1st ed. London: Springer; **2015**:611–33.  
[https://doi.org/10.1007/978-1-4471-6578-1\\_47](https://doi.org/10.1007/978-1-4471-6578-1_47)
  17. Lokiec F, Wientroub S. Simple bone cyst: etiology, classification, pathology, and treatment modalities. *J Pediatr Orthop B* **1998**;7(4):262–73.
  18. Xanthinaki AA, Choupis KI, Tosios K, Pagkalos VA, Papanikolaou SI. Traumatic bone cyst of the mandible of possible iatrogenic origin: a case report and brief review of the literature. *Head Face Med* **2006**;2:40.  
<https://doi.org/10.1186/1746-160X-2-40>
  19. Demirbas AE, Colpak HA, Kutuk N, Gonen ZB, Alkan A. Analysis of traumatic bone cyst of the jaws: a retrospective study. *Meandros Med Dent J* **2019**;20(3):225–9.  
<https://doi.org/10.4274/meandros.galenos.2019.54376>
  20. Resnick CM, Dentino KM, Garza R, Padwa BL. A management strategy for idiopathic bone cavities of the jaws. *J Oral Maxillofac Surg* **2016**;74(6):1153–8.  
<https://doi.org/10.1016/j.joms.2015.12.014>
  21. Martins-Filho PR, Santos Tde S, Araújo VL, Santos JS, Andrade ES, Silva LC. Traumatic bone cyst of the mandible: a review of 26 cases. *Braz J Otorhinolaryngol* **2012**;78(2):16–21.  
<https://doi.org/10.1590/S1808-86942012000200004>
  22. Velasco I, Cifuentes J, Lobos N, San Martín F. The unusual evolution of a simple bone cyst in the mandible: a case report. *J Clin Exp Dent* **2012**;4(2):e132–5.  
<https://doi.org/10.4317/jced.50730>
  23. Matsuda S, Yoshimura H, Sano K. A floating inferior alveolar neurovascular bundle in a simple bone cyst: A case report. *Exp Ther Med* **2019**;17(6):4677–80.  
<https://doi.org/10.3892/etm.2019.7463>
  24. Chell M, Idle M, Green J. Case report: an unusual finding of a solitary bone cyst in a patient with a fractured mandible. *Dent Update* **2015**;42(10):977–8.  
<https://doi.org/10.12968/denu.2015.42.10.977>

# TANTUM VERDE®

QUICK RELIEF FROM PAIN  
AND INFLAMMATION IN THE  
MOUTH AND THROAT<sup>1</sup>

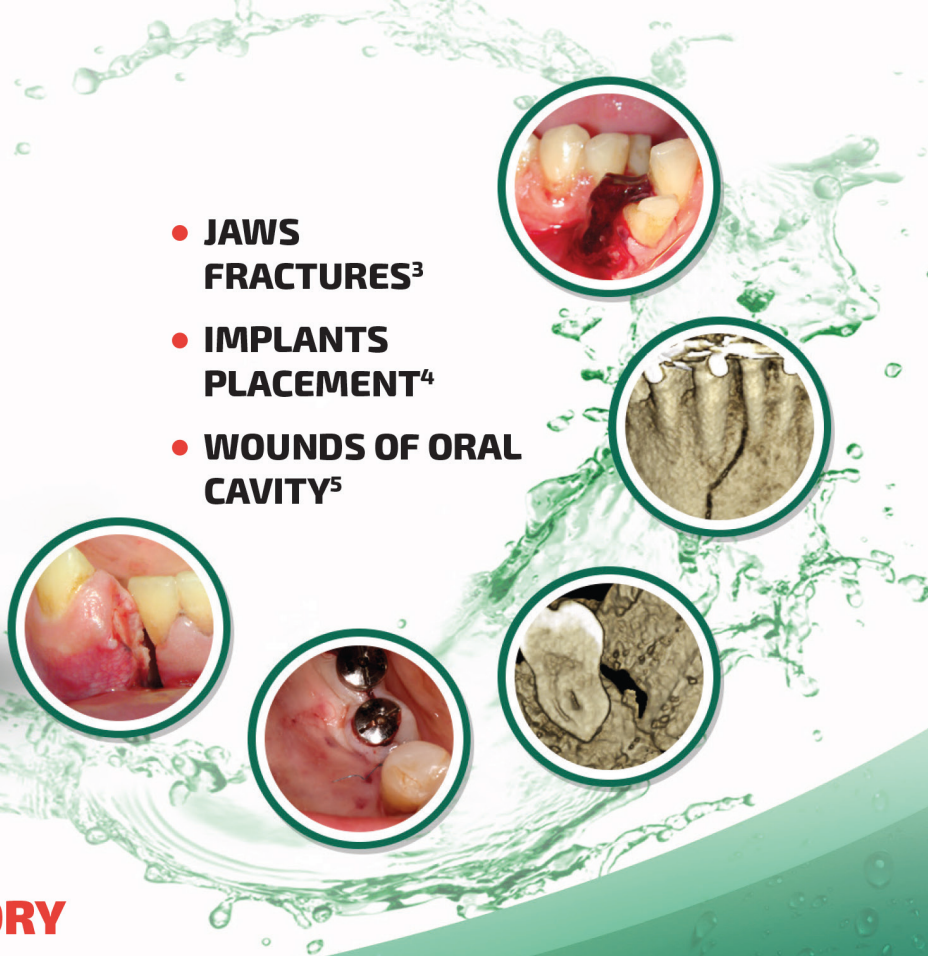
**AN INTEGRAL COMPONENT OF THE TREATMENT  
OF PAIN AND INFLAMMATION IN THE ORAL CAVITY  
IN 60 COUNTRIES WORLDWIDE!<sup>2</sup>**



Reg. № UA/3920/01/01

**LOCAL ANESTHETIC  
AND ANTI-INFLAMMATORY  
EFFECT<sup>1</sup>**

- **JAWS FRACTURES<sup>3</sup>**
- **IMPLANTS PLACEMENT<sup>4</sup>**
- **WOUNDS OF ORAL CAVITY<sup>5</sup>**



#### SUMMARY OF PRODUCT CHARACTERISTICS

**NAME OF THE MEDICINAL PRODUCT.** Tantum Verde 0.15% mouthwash. **QUALITATIVE AND QUANTITATIVE COMPOSITION.** Each 100 ml contains: active ingredient: benzydamine hydrochloride 0.15 g (equivalent to 0.134 g of benzydamine). **Therapeutic indications.** Treatment of symptoms such as irritation/inflammation including those associated with pain in the oropharyngeal cavity (e.g. gingivitis, stomatitis and pharyngitis), including those resulting from conservative or extractive dental therapy. **Posology and method of administration.** Pour 15 ml of Tantum Verde mouthwash into the measuring cup, 2-3 times per day, using it either at full concentration or diluted. If diluted, add 15 ml of water to the graduated cup. Do not exceed the recommended dosage. **Contraindications.** Hypersensitivity to benzydamine or to any of the excipient. **PHARMACOLOGICAL PROPERTIES. Pharmacodynamic properties.** Pharmacotherapeutic group: Stomatologic drugs: other agents for local oral treatment, ATC code: A01AD02. Clinical studies demonstrate that benzydamine is effective in relieving suffering from localised irritation of the mouth and pharynx. In addition, benzydamine possesses a moderate local anaesthetic effect. **Pharmacokinetic properties. Absorption.** Absorption through the oropharyngeal mucosa is demonstrated by the presence of measurable quantities of benzydamine in human plasma. These levels are insufficient to produce systemic effects. **Distribution.** When applied locally, benzydamine has been shown to accumulate in inflamed tissues where it reaches effective concentrations because of its capacity to penetrate the epithelial lining.

**Information about medicines. Information for health care professionals for use in professional activities.**

1. Інструкція для медичного застосування лікарського засобу Тантум Верде®, розчин для ротової порожнини, РПН № UA/3920/01/01, затверджено Наказом Міністерства охорони здоров'я України № 636 від 01.10.2015.

2. <http://www.angelini-pharma.com/wps/wcm/connect/com/home/Angelini+Pharma+in+the+world/>

3. Тимофеев А.А. и др. "Особенности гигиены полости рта для профилактики воспалительных осложнений при переломах нижней челюсти". Современная стоматология 2015;1(75):52-8.

4, 4.5. Tymofieiev O.O. et al "Prevention of inflammatory complications upon surgeries in maxillofacial region". J Diagn Treat Oral Maxillofac Pathol. 2017;1:105-12.

Clinical and CT images are courtesy of: Ievgen Fesenko (Department of Oral & Maxillofacial Surgery, PHEI "Kyiv Medical University", Kyiv, Ukraine), Oleg Mastakov ("SCIEDECE—Scientific Center of Dentistry & Ultrasound Surgery" Kyiv, Ukraine)



04119, Kiev, Melnikova str. 83D, of. 404.  
Tel.: (044) 538-01-26  
Fax: (044) 538-01-27

