

DT Journal

11 2020

**Journal of Diagnostics and
Treatment of Oral and
Maxillofacial Pathology**



Editors
Oleksii Tymofieiev • Rui Fernandes
(Kyiv, Ukraine • Jacksonville, FL, USA)



Official Journal of the
Ukrainian Association for
Maxillofacial and Oral Surgeons

DTJournal.org

U-Impl[®]

SWITZERLAND



№ R3M 804 252 B2

Сертифікат відповідності
технічного регламенту
щодо медичних виробів



Switzerland Aarbergerstrasse 107A, CH-2502
Biel, Phone/Fax +41 323230188
info@u-impl.com
www.u-impl.com

About the Journal: Aims and Scope

NOVEMBER 2020 • VOLUME 4 • ISSUE 11
www.djournal.org

Official Title

Journal of Diagnostics and Treatment of Oral and Maxillofacial Pathology

Standard Abbreviation: ISO 4

J. Diagn. Treat. Oral Maxillofac. Pathol.

International Standard Serial Number (ISSN)

Print ISSN 2519-2086 | Online ISSN 2522-1965

Aims & Scope

This is a monthly peer-reviewed oral and maxillofacial surgery journal focused on: Microvascular and jaw reconstructive surgery, dental implants, salivary gland tumors/diseases, TMJ lesions, virtual surgical planning, implementation of ultrasonography into the practice of oral and maxillofacial surgeons.

Editorial Board (EB) Composition

- EB shows significant geographic diversity representing 26 opinion leaders from 13 countries: Brazil, Canada, Colombia, Greece, Hong Kong (SAR, China), India, Israel, Italy, Slovak Republic, Spain, Ukraine, United Arab Emirates, and United States.
- The majority of the EB Members have a discernible publication history in Scopus, Web of Science, and journals with a high impact factor.
- The publication records of all EB members are consistent with the stated scope and published content of the journal.
- The journal has a several full-time professional editors.
- Gender distribution of the editors: 11.53% women, 88.47% men, 0% non-binary/other, and 0% prefer not to disclose.

Frequency

12 print/online issues a year (from January 2020)

Publication History

2017: 4 issues a year
2018: 4 issues a year
2019: 10 issues a year
From 2020: 12 issues a year

Publishing Model

Journal combines a *hybrid* and *delayed open access* publishing models. The articles of all types, except Editorials, are immediately in open access. Editorials became an open access publication too after 3-month embargo period.

Article Processing Charge (APC)

During hard times of Covid-19 pandemic our journal trying to support authors by reducing the APC by 50%. And by the end of December 2020 the APC will be 100 USD and 50 USD (excluding taxes) depending on the article's type. Details at website: dtjournal.org.

13 Types of Articles Currently Published by the Journal

Editorials/Guest Editorials/Post Scriptum Editorials, Images, Case Reports/Case Series, Original Articles, Review Articles, Discussions, Paper Scans (*synonyms*: Review of Articles, Literature Scan), Book Scans (*synonym*: Book Reviews), Letters to the Editor (*synonym*: Letters), and Viewpoints.

Registration: Ministry of Justice of Ukraine

Registration: July 28, 2016

Re-Registration: May 21, 2019 (Certificate: KB # 23999-13839IIP)

Co-Founders

1. Shupyk National Medical Academy of Postgraduate Education.
2. Private Higher Educational Establishment "Kyiv Medical University."
3. OMF Publishing, Limited Liability Company.

Publisher

OMF Publishing, LLC is an academic publisher focused on medical and linguistic sciences.
Address: 13-A Simferopolska Street, Office 121, Kyiv 02096, Ukraine.

Crossref Membership

OMF Publishing, LLC is a member of Publishers International Linking Association, Inc. which doing business as a Crossref. OMF Publishing's active membership: From February 2017 to present.

Official Journal of

Ukrainian Association for Maxillofacial and Oral Surgeons

Ukrainian Association for Maxillofacial and Oral Surgeons (UAMOS)

Address: 4-A Profesora Pidvysotskoho Street, Kyiv 01103, Ukraine.
Tel., fax: +38 044 528 35 17.
Website: uamos.org.

Subscription Index

In Ukraine: 60077 | In Donetsk/Luhansk Regions: 88263.
See page A5.

© 2020 OMF PUBLISHING, LLC

Editorial Board

NOVEMBER 2020 • VOLUME 4 • ISSUE 11
www.djournal.org

Editor in Chief

Oleksii O. Tymofieiev, ScD
(Kyiv, Ukraine)

Deputy Editor in Chief

Rui P. Fernandes, MD, DMD, FACS, FRCS(Ed)
(Jacksonville, Florida, United States)

Section Editors

Bone Augmentation Techniques

Nardy Casap, MD, DMD
(Jerusalem, Israel)

Head & Neck Radiology

Anil T. Ahuja, MBBS, MD, FRCR, FHKCR, FHKAM
(Hong Kong, SAR, China)

Craniofacial Deformities

Sunil Richardson, MDS
(Nagercoil, Tamil Nadu, India)

Images

Camilo Mosquera, DDS
(Bogotá, D.C., Colombia)

Facial Feminization Surgery

Kyle Keojampa, MD, FACS
(Los Angeles, California, United States)

Orthognathic Surgery

Mario Brinhole
(São Paulo, São Paulo, Brazil)

Facial Plastic Surgery

Tirbod Fattahi, MD, DDS, FACS
(Jacksonville, Florida, United States)

Robotic Surgery

Salam O. Salman, MD, DDS, FACS
(Jacksonville, Florida, United States)

Head & Neck Oncologic Surgery

Todd C. Hanna, MD, DDS, FACS
(New York, New York, United States)

TMJ Lesions/Disorders

Belmiro C. Vasconcelos, DDS, PhD
(Recife, Pernambuco, Brazil)

Editorial Board Members

Oleh M. Antonyshyn, MD, FRCS(C)
(Toronto, Ontario, Canada)

Anastasiya Quimby, DDS, MD
(Fort Lauderdale, Florida, United States)

Anthony M. Bunnell, MD, DMD, FACS
(Jacksonville, Florida, United States)

Daniel Robles Cantero, DDS, MSc
(Madrid, Spain)

Nur A. Hatab, DMD, PhD
(Ras Al Khaimah, United Arab Emirates)

Peter Stanko, MD, PhD
(Bratislava, Slovak Republic)

Andrey V. Kopchak, ScD
(Kyiv, Ukraine)

Olexander O. Tymofieiev, ScD
(Kyiv, Ukraine)

Olindo Massarelli, MD, PhD, FEBOMFS
(Sassari, Italy)

Natalia O. Ushko, ScD
(Kyiv, Ukraine)

Andrew Yampolsky, DDS, MD
Philadelphia, Pennsylvania, United States

Web & Social Media Editor

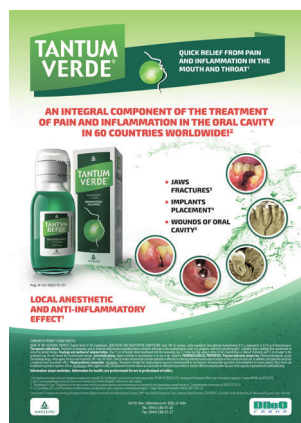João L. Monteiro, DDS
(Boston, Massachusetts, United States)

Director, Journal Development Department

Evangelos G. Kilipiris, DMD
(Thessaloniki, Greece | Bratislava, Slovak
Republic)

Managing Editor

Ievgen I. Fesenko, PhD
(Kyiv, Ukraine)



TANTUM VERDE®

INFORMATION LEAFLET for the medicinal product

Composition:

active substance: benzydamine hydrochloride;
100 mL of solution contain benzydamine hydrochloride 0.15 g;

excipients: ethanol 96%, glycerol, methyl parahydroxybenzoate (E 218), flavor (menthol), saccharin, sodium hydrocarbonate, Polysorbate 20, Quinoline Yellow (E 104), Patent Blue V (E 131), purified water.

Dosage form. Oromucosal solution.

Basic physical and chemical properties: a clear green liquid with a typical mint flavor.

Pharmacotherapeutic group. Dental preparations. Other agents for local oral treatment.

ATC code: A01A D02.

Pharmacological properties.

Pharmacodynamics.

Benzydamine is a non-steroidal anti-inflammatory drug (NSAID) with analgesic and antiexudative properties.

Clinical studies have shown that benzydamine is effective in the relief of symptoms accompanying localized irritation conditions of the oral cavity and pharynx. Moreover, benzydamine has anti-inflammatory and local analgesic properties, and also exerts a local anesthetic effect on the oral mucosa.

Pharmacokinetics.

Absorption through the oral and pharyngeal mucosa has been proven by the presence of measurable quantities of benzydamine in human plasma. However, they are insufficient to produce any systemic pharmacological effect. The excretion occurs mainly in urine, mostly as inactive metabolites or conjugated compounds.

When applied locally, benzydamine has been shown to cumulate in inflamed tissues in an effective concentration

due to its ability to permeate through the mucous membrane.

Clinical particulars.

Indications.

Symptomatic treatment of oropharyngeal irritation and inflammation; to relieve pain caused by gingivitis, stomatitis, pharyngitis; in dentistry after tooth extraction or as a preventive measure.

Contraindications.

Hypersensitivity to the active substance or to any other ingredients of the product.

Interaction with other medicinal products and other types of interaction.

No drug interaction studies have been performed.

Warnings and precautions.

If sensitivity develops with long-term use, the treatment should be discontinued and a doctor should be consulted to get appropriate treatment.

In some patients, buccal/pharyngeal ulceration may be caused by severe pathological processes. Therefore, the patients, whose symptoms worsen or do not improve within 3 days or who appear feverish or develop other symptoms, should seek advice of a physician or a dentist, as appropriate.

Benzydamine is not recommended for use in patients hypersensitive to acetylsalicylic acid or other non-steroidal anti-inflammatory drugs (NSAIDs).

The product can trigger bronchospasm in patients suffering from or with a history of asthma. Such patients should be warned of this.

For athletes: the use of medicinal products containing ethyl alcohol might result in positive antidoping tests considering the limits established by some sports federations.

Use during pregnancy or breast-feeding

No adequate data are currently available on the use of benzydamine in pregnant and breastfeeding women. Excretion of the product into breast milk has not been studied. The findings of animal studies are insufficient to make any conclusions about the effects of this product during pregnancy and lactation.

The potential risk for humans is unknown.

TANTUM VERDE should not be used during pregnancy or breast-feeding.

Effects on reaction time when driving or using machines

When used in recommended doses, the product does not produce any effect on the ability to drive and operate machinery.

Method of administration and doses.

Pour 15 mL of TANTUM VERDE solution from the bottle into the measuring cup and gargle with undiluted or diluted product (15 mL of the measured solution can be diluted with 15 mL of water). Gargle 2 or 3 times daily. Do not exceed the recommended dose.

Children.

The product should not be used in children under 12 years due to a possibility of ingestion of the solution when gargling.

Overdosage.

No overdose has been reported with benzydamine when used locally. However, it is known that benzydamine, when ingested in high doses (hundreds times higher than those possible with this dosage form), especially in children, can cause agitation, convulsions, tremor, nausea, increased sweating, ataxia, and vomiting. Such acute overdose requires immediate gastric lavage, treatment of fluid/salt imbalance, symptomatic treatment, and adequate hydration.

Adverse reactions.

Within each frequency group, the undesirable effects are presented in order of their decreasing seriousness.

Adverse reactions are classified according to their frequency: very common ($\geq 1/10$); common ($\geq 1/100$ to $<1/10$); uncommon ($\geq 1/1,000$ to $<1/100$); rare ($\geq 1/10,000$ to $<1/1,000$); very rare ($<1/10,000$); frequency unknown (cannot be estimated from the available data).

Gastrointestinal disorders: rare – burning mouth, dry mouth; *unknown* – oral hypesthesia, nausea, vomiting, tongue edema and discoloration, dysgeusia.

Immune system disorders: rare – hypersensitivity reaction, *unknown* – anaphylactic reaction.

Respiratory, thoracic and mediastinal disorders: very rare – laryngospasm; *unknown* – bronchospasm.

Skin and subcutaneous tissue disorders: uncommon – photosensitivity; very rare – angioedema; *unknown* – rash, pruritus, urticaria.

Nervous system disorders: *unknown* – dizziness, headache.

TANTUM VERDE contains methyl parahydroxybenzoate, which can cause allergic reactions (including delayed-type reactions).

Shelf life. 4 years.

Storage conditions.

Do not store above 25°C. Keep out of reach of children.

Packaging.

120 mL of solution in a bottle with a measuring cup; 1 bottle per cardboard box.

Dispensing category.

Over-the-counter medicinal product.

Manufacturer.

Aziende Chimiche Riunite Angelini Francesco A.C.R.A.F. S.p.A., Italy.

Location of the manufacturer and its business address.
Via Vecchia del Pinocchio, 22 – 60100 Ancona (AN), Italy.

Date of the last revision of the text.

September 26, 2018.

Information leaflet is

APPROVED by

Order of the

Ministry of Health of Ukraine

No. 636 dated 01.10.2015

Registration Certificate

No. UA/3920/01/01

Subscription in Ukraine

NOVEMBER 2020 • VOLUME 4 • ISSUE 11
www.dtjournal.org

Frequency of the *Journal of Diagnostics and Treatment of Oral and Maxillofacial Pathology*:
12 issues (synonym: numbers) a year.

Subscription index in Ukraine: 60077.

Subscription index for Donetsk and Luhansk Regions: 88263.



Three ways of individual/institutional subscription of print version of the *Journal*:

1. At Ukrposhta post offices.
2. At the website www.presa.ua.
3. At the website www.dtjournal.org (from December 1, 2020).

Issues	Fee in 2021
1 Issue	\$1.35 (37.88 UAH)
3 Issues	\$3.95 (110.64 UAH)
6 Issues	\$7.65 (214.28 UAH)
12 Issues	\$15.11 (423.36 UAH)

Content

of the Volume 4 • Issue 11 • November 2020

A1 **Publisher & Editorial Office Information**

A2 **Editorial Board**

A5 **Subscription in Ukraine**

A6 **Content, Courtesy, & Erratum**

EDITORIAL

195 **DTJournal.org: Growing with Technologies**

Oleksii O. Tymofeiev, Natalia O. Ushko, & Evangelos G. Kilipiris

SERIES

197 **Single and Multiple Odontogenic Cutaneous Sinus Tracts**

Olha S. Cherniak, Valentyna I. Zaritska, Pavlo P. Snisarevskyi, Ievgen I. Fesenko, Viktoria P. Blinova, Nataliia M. Koba, Ruslan A. Pavlenko, & Viktoria M. Holodenko



COURTESY

Journal's cover image (virtual surgical planning for a segmental mandibular reconstruction with fibula transplant) is courtesy of Rui P. Fernandes, MD, DMD, FACS, FRCS.

Image was taken from the article: Fernandes RP, Quimby A, Salman S. Comprehensive reconstruction of mandibular defects with free fibula flaps and endosseous implants. *J Diagn Treat Oral Maxillofac Pathol* 2017;1(1):6–10.



EDITORIAL

DTJournal.org: Growing with Technologies

Oleksii O. Tymofieiev^a, Natalia O. Ushko^a, & Evangelos G. Kilipiris^c

Ideas are easy. Implementation is hard.

—Guy Kawasaki

Co-Founder of Alltop

Every peer-reviewed journal evolves in a different way. Evolution and growth of the *Journal of Diagnostics and Treatment of Oral and Maxillofacial Pathology* have been accelerated in March 2020 by a launch of a new media platform (Fig 1) with a potential to become a core for absorption and development of new scientific technologies. Technologies and solutions specially created for the simplification of the scholar life of oral and maxillofacial surgeons.

Analysis of technological innovations is more than crucial. And thanks to last data from Google Analytics we received a possibility to review the geographical distribution of readers (as a result of our humble improvements) in March–November 2020 period (Fig 2). The highest number of readers was noted from United States (259 users [32.35 percent]). Second highest number – from Ukraine (150 users [18.68 percent]).¹ Comparing with such journals giants, like *Plastic and Reconstructive Surgery (PRS)*, which in 2020 attracted more than 92,500 visitors every month, we understand how reach we are... How extremely reach we are for a huge amount of beautiful editorial and publisher's work that is need to be done.

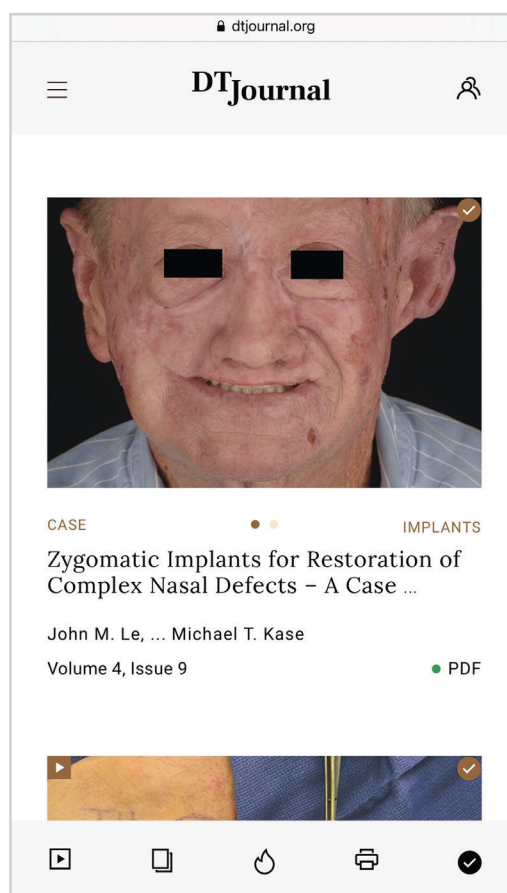


FIGURE 1. Mobile view of the website DTJournal.org.

^a Editor in Chief, Kyiv, Ukraine.
E-mail: tymofeev@gmail.com (Oleksii Tymofieiev)

^b Editorial Board Member, Kyiv, Ukraine.
E-mail: natalia.ushko@gmail.com (Natalia Ushko)

^c Director, Journal Development Department, Bratislava, Slovak Republic.
E-mails: varonos@live.co.uk (Evangelos Kilipiris)
kilipirishealthcenter7@gmail.com
Instagram: [@evangeloskilipiris](https://www.instagram.com/evangeloskilipiris)

Cite article as: Tymofieiev OO, Ushko NO, Kilipiris EG. Dtjournal.org: growing with technologies. *J Diagn Treat Oral Maxillofac Pathol* 2020;4(11):195–6.

Available online 30 November 2020

<https://dx.doi.org/10.23999/j.dtomp.2020.11.1>.

© 2020 OMF Publishing, LLC. This is an open access article under the CC BY license (<http://creativecommons.org/licenses/by-nc/4.0/>).

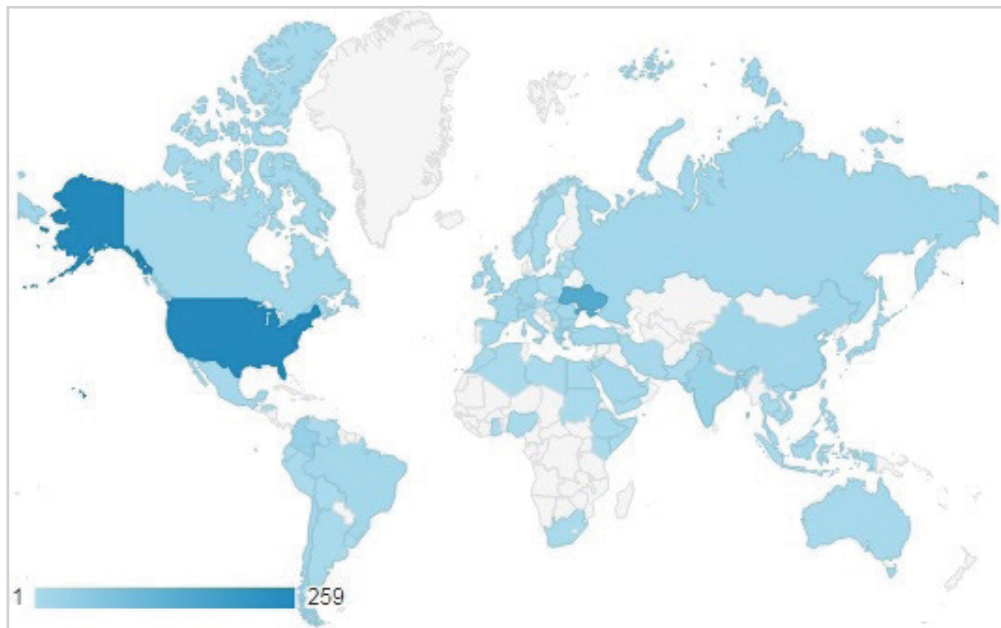


FIGURE 2. Map represents the geographical distribution of readers during last nine months (March–November 2020). The highest number of readers was noted from United States (259 users [32.35 percent]). Second highest number – from Ukraine (150 users [18.68 percent]). Data source: Google Analytics.¹

Progress of the *PRS*, as a leading publication in plastic surgery, through their 75-year experience teaches us a lot about the implementation of advanced technologies.² The *PRS*'s phenomenal success lies in deep concentration on cutting-edge articles acceptance only and on combination of approaches/technologies like 1) sectionalizing of the journal, 2) launch of Editorial Manager for the peer-review process online, 3) video content acceptance, 4) expanded continuing medical education (CME) program, 5) launch of standalone peer-review sponsored supplemental issues, 6) implementation of levels of evidence, 7) initiated "Outcomes Articles," 8) ferocious work in social media, 9) cover art from the selected articles, 10) introducing of "Resident Ambassadors to the Editorial Board" and built the wide network of the "Resident Advisory Board" ambassadors, 11) developing a *PRS* family of journals by launch of a new open-access online only publication – *PRS Global Open*, 12) launch of Special Topic Series for the exploration of important topics Women in Plastic Surgery, etc., 13) *PRS* Journal Club, 14) Podcasts, 15) *PRS* Grand Rounds, 16) labeling the articles by Patient Safety sings allowing surgeons to claim 1 hour of credits, etc.²

Summarizing digital achievements of our journal's (*DTJournal.org*) in 2020 we can emphasize that these technologies only have been started to grow and we will dedicate all our passion to help them flourish not only in 2021 but also in the decade to come.

When you find an idea that you just can't stop thinking about, that's probably a good one to pursue.

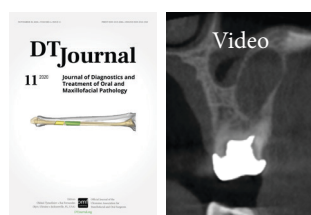—Josh James
Omniture CEO and Co-Founder

We must always remember that on the shoulders of giants, we can see more clearly what is next on the horizon.

—Rohrich et al²

REFERENCES

1. Analytics Google: dtjournal.org: all web site data: location [document on the internet]; November 29, 2020 [cited 2020 Nov 29]. Available from: https://analytics.google.com/analytics/web/?authuser=0#/report/visitors-geo/a167940479w234452851p219804564/_u.date00=20200301&_u.date01=20201129
2. Rohrich RJ, Weinstein AG, Stuzin J. Plastic and Reconstructive Surgery at 75: stronger, better, and always changing. *Plast Reconstr Surg* 2021;147(1):249–57. <https://doi.org/10.1097/PRS.00000000000007516>



SERIES

Single and Multiple Odontogenic Cutaneous Sinus Tracts

Olha S. Cherniak^a, Valentyna I. Zaritska^b, Pavlo P. Snisarevskiy^c, Ievgen I. Fesenko^{d,e,*}, Viktoria P. Blinova^f, Nataliia M. Koba^g, Ruslan A. Pavlenko^h, & Viktoria M. Holodenkoⁱ

SUMMARY

Odontogenic cutaneous sinus tract (OCST) (*synonyms*: odontogenic cutaneous fistula, odontogenic subcutaneous granuloma, etc.) is an abnormal tube-shape formation which serves as a pathway for pus drainage from the locus of tooth-associated infection to the cutaneous lesion. OCST is a collective term and commonly is manifested in six cutaneous forms: as dimpling with fistula, cutaneous infiltration, nodule, suppurated nodule, abscess, or even cyst-like cutaneous formation. The purpose of this paper is to present the diverse clinical and radiological appearance (cone-beam computed tomography [CBCT] and ultrasound [US]) of single and multiple OCSTs based on the literature and our four cases. As long as limited publications present the ultrasound appearance of the OCSTs, we will focus on meticulous description of sonograms as well, giving a possibility for oral and maxillofacial surgeons to understand all advantages of that type of non-ionizing radiation diagnostics, avoiding misdiagnosis and mistreatment of OCSTs.

Case 1: A 24-year-old male with OCST to the left mandibular region from the lower left first molar. Cutaneous lesion of OCST manifested as a transition stage from cutaneous infiltration to abscess.

Kyiv, Ukraine

^a Physician of Ultrasound Diagnostics; Head, Department of Ultrasound Diagnostics, Regional Diagnostic Center, Kyiv Regional Clinical Hospital.

^b PhD, Associate Professor, Department of Pathology, Shupyk National Medical Academy of Postgraduate Education.

^c Head, Department of Pathomorphology, Kyiv Regional Clinical Hospital.

^d Oral Surgeon, Physician of Ultrasound Diagnostics, Center of Maxillofacial Surgery, Kyiv Regional Clinical Hospital (place of work at moment of material collection).

^e PhD, Associate Professor, Department of Oral and Maxillofacial Surgery, Private Higher Educational Establishment "Kyiv Medical University."

^f Dentist; Assistant Professor, Department of Oral and Maxillofacial Surgery, Private Higher Educational Establishment "Kyiv Medical University."

^g Head Physician, SCIEDECE—Scientific Center of Dentistry and Ultrasound Surgery (place of work at moment of article preparing).

^h Oral Surgeon; Head, Center of Maxillofacial Surgery and Dentistry, Kyiv Regional Clinical Hospital.

ⁱ Year 1 Intern, 2-year Internship Program, Center of Maxillofacial Surgery and Dentistry, Kyiv Regional Clinical Hospital.

* Corresponding author's address: Department of Oral and Maxillofacial Surgery, Private Higher Educational Establishment "Kyiv Medical University," 7 Antona Tsedika Street, Kyiv 02000, Ukraine.
E-mail: i.i.fesenko@dtjournal.org (Ievgen Fesenko)
Instagram: [@dr_eugenfesenko](https://www.instagram.com/dr_eugenfesenko)
ORCID: <https://orcid.org/0000-0002-8901-1632>

Please cite this article as: Cherniak OS, Zaritska VI, Snisarevskiy PP, Fesenko II, Blinova VP, Koba NM, Pavlenko RA, Holodenko VM. Single and multiple odontogenic cutaneous sinus tracts. *J Diagn Treat Oral Maxillofac Pathol* 2020;4(11):197–216.

The word 'Video' at the upper right icon means that article contains cases with video.

Paper received 25 October 2020
Accepted 15 November 2020
Available online 30 November 2020

<http://dx.doi.org/10.23999/j.dtmp.2020.11.2>

© 2020 OMF Publishing, LLC. This is an open access article under the CC BY license (<http://creativecommons.org/licenses/by-nc/4.0/>).

Case 2: A 41-year-old male with odontogenic cutaneous fistula of the right mandibular body region from the lower right second molar. It's manifested as deep dimpling with active fistula.

Case 3: A 45-year-old male with unilateral multiple OCSTs: 1) odontogenic cutaneous fistula of the left cheek from the left second maxillary molar and 2) a scar from a surgically treated OCST located in the projection of the left mandible from the tooth #3.6.

Case 4: An 18-year-old male with OCST to left nasolabial fold and cheek from the upper left first molar. The pathology manifested as a subcutaneous abscess first and a nodule after the abscess lancing.

These cases highlight the diverse cutaneous manifestations of the OCSTs. The US appearances of different parts of the OCST are presented, the popular terminology for the same cutaneous lesions are discussed, the new terms are proposed, and the treatment strategies based on histologic results are debated.

INTRODUCTION

Odontogenic cutaneous sinus tract¹ (*synonyms*: odontogenic cutaneous fistula,^{2,3} extraoral sinus tract of endodontic origin⁴, odontogenic subcutaneous granuloma⁵, etc.) is an abnormal tube-shape formation which serves as a pathway for pus drainage from the locus of tooth-associated infection to the cutaneous lesion.

Odontogenic cutaneous sinus tract (OCST) is a collective term and commonly is manifested in six cutaneous forms: as dimpling with fistula, cutaneous infiltration, nodule, suppurated nodule, abscess, or even cyst-like cutaneous formation.³ Other common name for the cutaneous infiltration/abscess appearance is odontogenic subcutaneous granuloma.⁵ Those two clinically different manifestations are two clinical stages and in some countries are jointly named as odontogenic subcutaneous granuloma which has two clinical forms. Moreover, in some cases, when a subcutaneous granuloma do not has the sinus tract and the focus of odontogenic infection, it is considered non-odontogenic.⁶ In particular, Tymofieiev observed the onset of non-odontogenic subcutaneous granuloma due to the penetration of such organic-composed foreign bodies⁶ as a pine needle and nail.⁵

Some cutaneous manifestations of the OCST the authors describe as ulcerated nodules⁷ and nodulocystic cutaneous lesions^{7,8}.

One of the previously applied names for the OCST with fistula and notable extraoral pyorrhea was a "Partsch chronic granulating periodontitis"⁹.

The purpose of this paper is to present the diverse clinical and radiological appearance (cone-beam computed tomography [CBCT] and

ultrasound [US]) of a single and multiple OCSTs based on the literature and our four cases. Limited publications^{7,10,14} exist presenting ultrasonographic appearance of the OCSTs, so we will focus on meticulous description of sonograms as well, giving a possibility for oral and maxillofacial surgeons to understand all advantages of that type of non-ionizing radiation diagnostics, avoiding misdiagnosis and mistreatment of OCSTs.

REPORT OF CASES

CASE 1

In February 2012, a 24-year-old male was referred to the Center of Maxillofacial Surgery with complaints for several-week redness in the left mandibular region (Fig 1). Extraoral examination showed a round shape skin erythema with cutaneous infiltration. Intraoral examination revealed a destroyed crown of the tooth #3.6 by carious process. Panoramic radiography showed periapical radiolucency at the roots of mandibular first left molar measured 8.6 × 9 mm with no filling material inside the canals. Palpation revealed a firm strand from alveolar bone to the left mandibular region passing into the submucosal layer. Clinically, the cutaneous lesion manifested as a transition stage from infiltration to abscess stage of odontogenic subcutaneous granuloma. Cutaneous manifestations completely self-disappeared (after tooth #3.6 removal and prescription of antibiotics) at 25-day follow-up. Such fact gave us a reason to hypothesize that the case was a reversible cutaneous manifestation of OCST with no need of surgery.

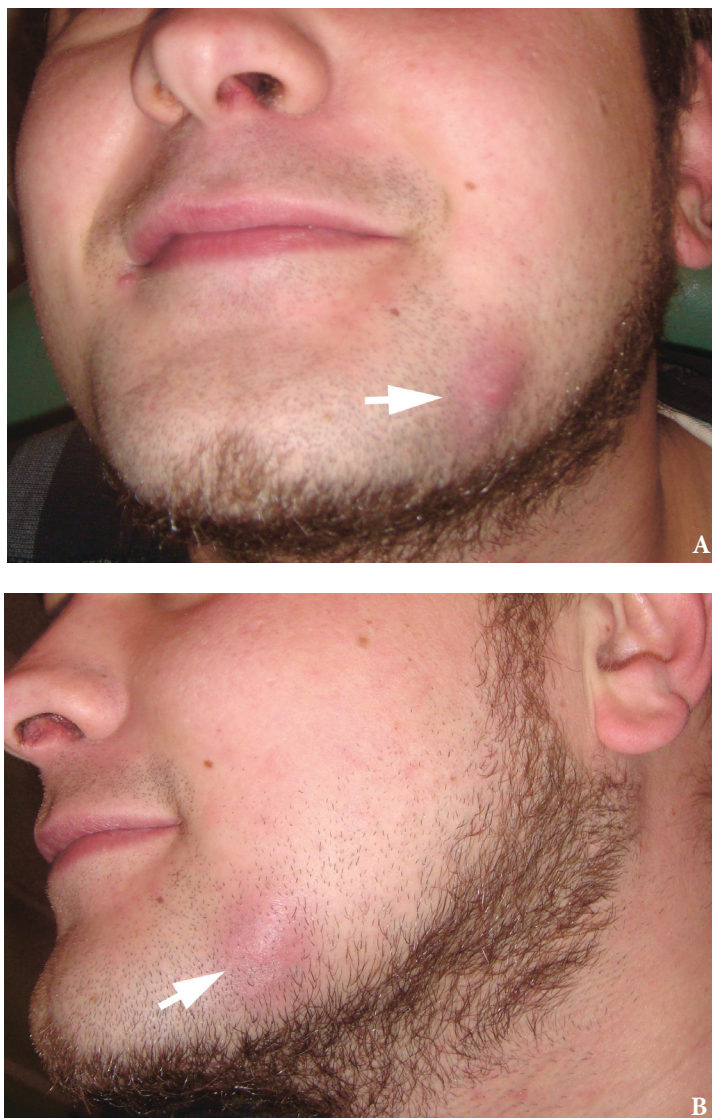

FIGURE 1. Case 1: A 24-year-old male with odontogenic cutaneous sinus tract (A, B) to the left mandibular region from the lower left first molar. OCST manifested as a transition stage from cutaneous infiltration to abscess of odontogenic subcutaneous granuloma (*arrow*). Cutaneous manifestations completely self-disappeared (after tooth #3.6 removal and prescription of antibiotic) at 25-day follow-up. Printed with permission and copyrights retained by R.A.P.

CASE 2

In January 2015, a 41-year-old male was referred to the Center of Maxillofacial Surgery and Dentistry with cosmetic complaints – a deep skin dimpling with active fistula in the right mandibular area (Fig 2A and B). Periodically, during the last years, the patient noted the appearance of purulent discharge in the center of dimpling.

Intraorally, a firm strand was palpated from the alveolar bone of the lower right second molar to

the cutaneous fistula. Simultaneously, a horizontal oblique anteroposterior direction of the strand was noted. No visual mucosal changes were visualized (Fig 2C).

Cone-beam computed tomography (CBCT) (Planmeca ProMax 3D, Helsinki, Finland) showed the absence of contrast filling material in all three canals of the tooth #4.7 and well-defined periradicular radiolucency around roots' ends and in a furcation area with an oval shape buccal cortical plate defect (Fig 2D-G). Using of a “draw

a panoramic curve” tool in the Planmeca Romexis Viewer 3.8.3R 15.12.14 allowed obtaining a panoramic view (Fig 2G).

Removal of the sinus tract and extraction of a tooth #4.7 have been performed under general anesthesia with local vestibular infiltration by 1.4 ml Ultracain D-S Forte (4 percent articaine hydrochloride, Aventis Pharma Deutschland GmbH, Frankfurt am Main, Germany). First, the

elevation of the mucoperiosteal flap with dissection of the sinus tract originated from the tooth #4.7’s alveola was done (Fig 2H). Then, the tract and a cutaneous fistula have been excised (Fig 2I and J) with a local plastic closure of the skin defect.

Histopathological examination of the specimen (ie, sinus tract) established the presence of the soft tissues with a cavity lined with granulations and inflammation around.

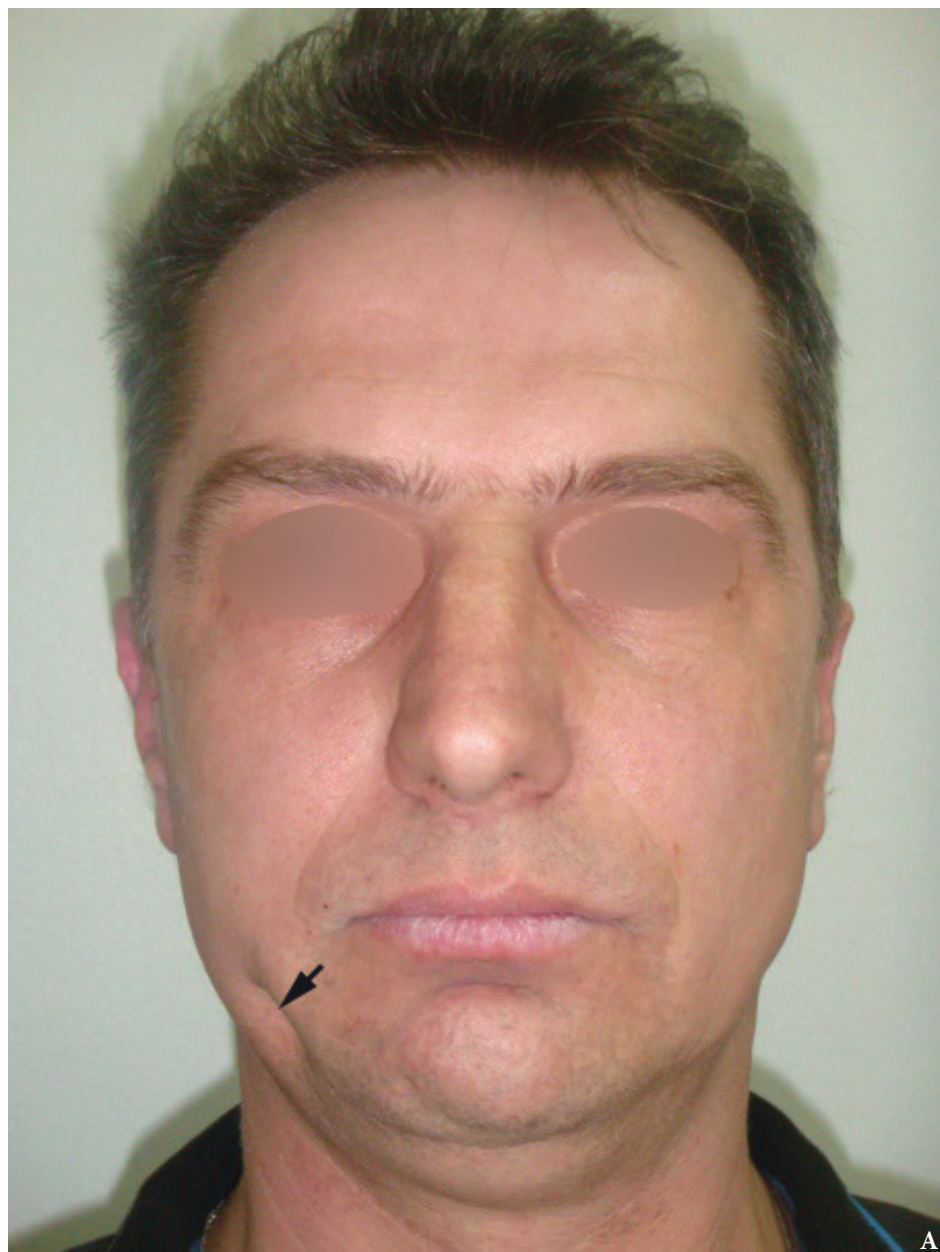

FIGURE 2. Case 2: A 41-year-old male with odontogenic cutaneous fistula of the right mandibular body region from the lower right second molar (ie, tooth #4.7). At the anterior view (A) the deep skin dimpling is indicated by *arrow*. Printed with permission and copyrights retained by I.I.F. (Fig 2 continued on next page.)

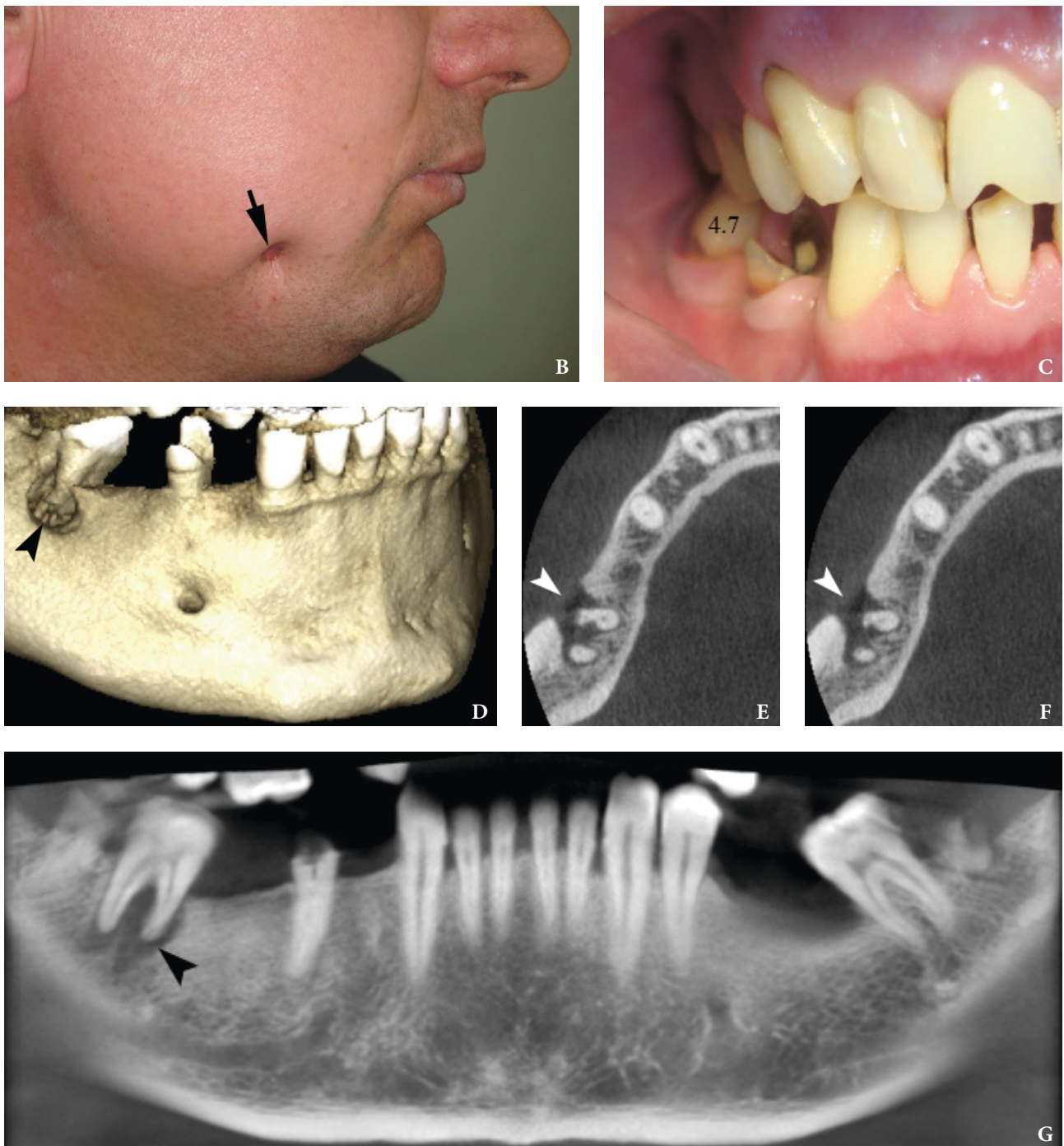


FIGURE 2 (continued). Case 2: A 41-year-old male with odontogenic cutaneous fistula of the right mandibular body region from the lower right second molar (ie, tooth #4.7). At the lateral view (**B**) the deep skin dimpling is indicated by *arrow*. **C** – No visual mucosal changes were noted near the teeth #4.7 and 4.5. Three-dimensional CBCT (**D**) visualized an oval shape defect (*arrowhead*) on the buccal cortical plate. Axial scans (**E**, **F**) and panoramic view (**G**) (obtained using a tool “draw a panoramic curve”) showed well-defined periradicular radiolucency with buccal defect (*arrowheads*) around the tooth #4.7 and no contrast filling material in its all three canals (mesiobuccal, mesiolingual, and distal). Printed with permission and copyrights retained by I.I.F. (**Fig 2 continued on next page.**)

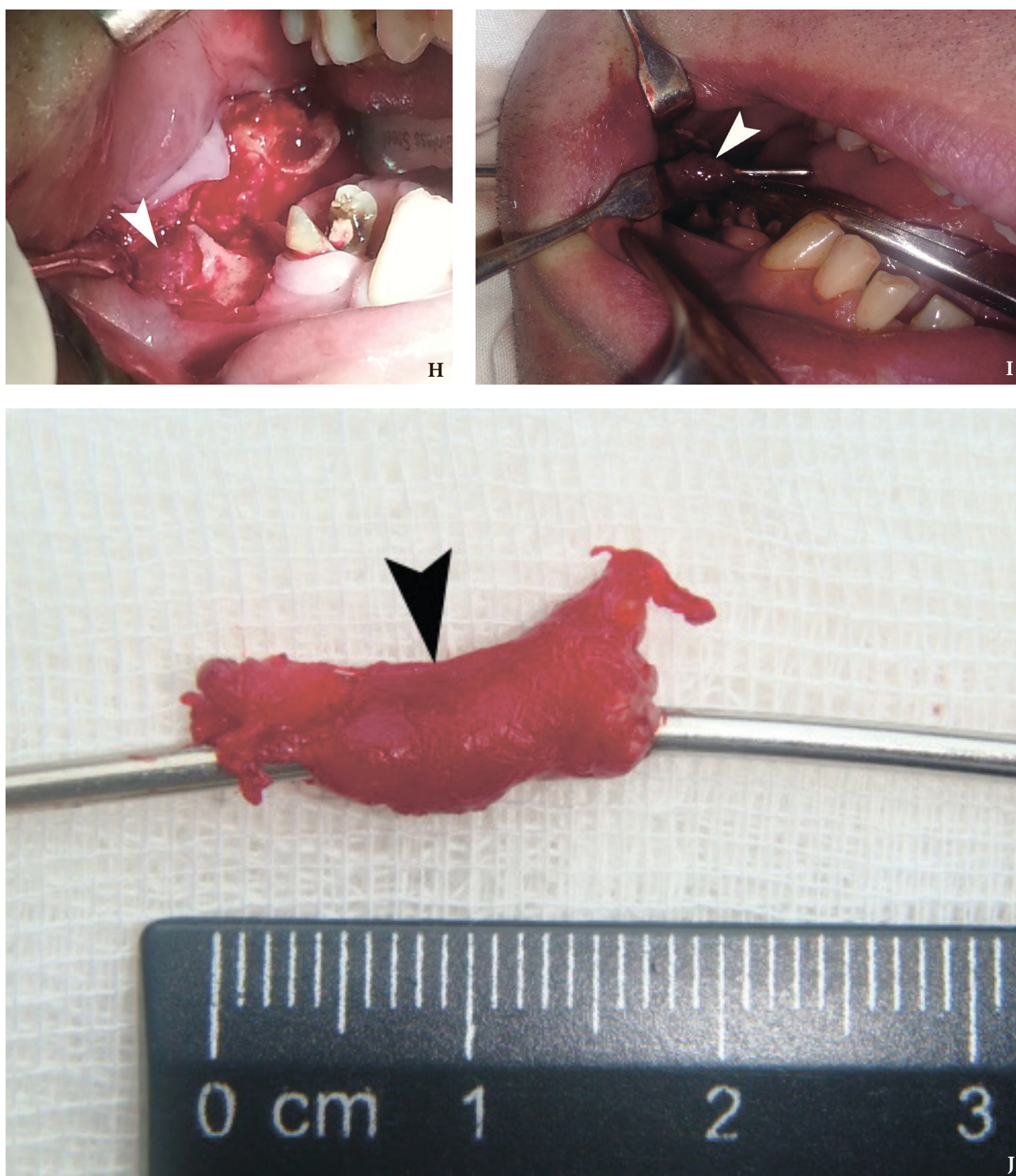


FIGURE 2 (continued). Case 2: A 41-year-old male with odontogenic cutaneous fistula of the right mandibular body region from the lower right second molar (ie, tooth #4.7). Image **H** demonstrates operative field after elevation of the mucoperiosteal flap and dissection of the sinus tract (*arrowhead*) originated from the tooth #4.7 alveola through the buccal plate perforation. On the images during (**I**) and after (**J**) the excision the sinus tract is labeled by *arrowhead*. Total length of the tract reached 1.3 cm. Printed with permission and copyrights retained by I.I.F.

CASE 3

In March 2016, a 45-year-old male was treated in Orthopedic Surgery Department due to the fracture of lower extremity. Simultaneously, an odontogenic cutaneous fistula of the left cheek (Fig 3) from the maxillary left second molar was diagnosed by an oral surgeon of the same hospital. Despite the recommendations the patient declined the further

maxillofacial diagnostics and treatment. Figure 3 also demonstrates a scar in the left mandibular region where a similar fistula had been excised several years ago (according to patient's words). During surgery, a causative tooth #3.6 was extracted. So, that case with unilateral multiple OCSTs supports the data of Tymofiev describing multiple odontogenic cutaneous sinus tracts with cutaneous manifestations in a form of infiltration or abscess.^{5,6}

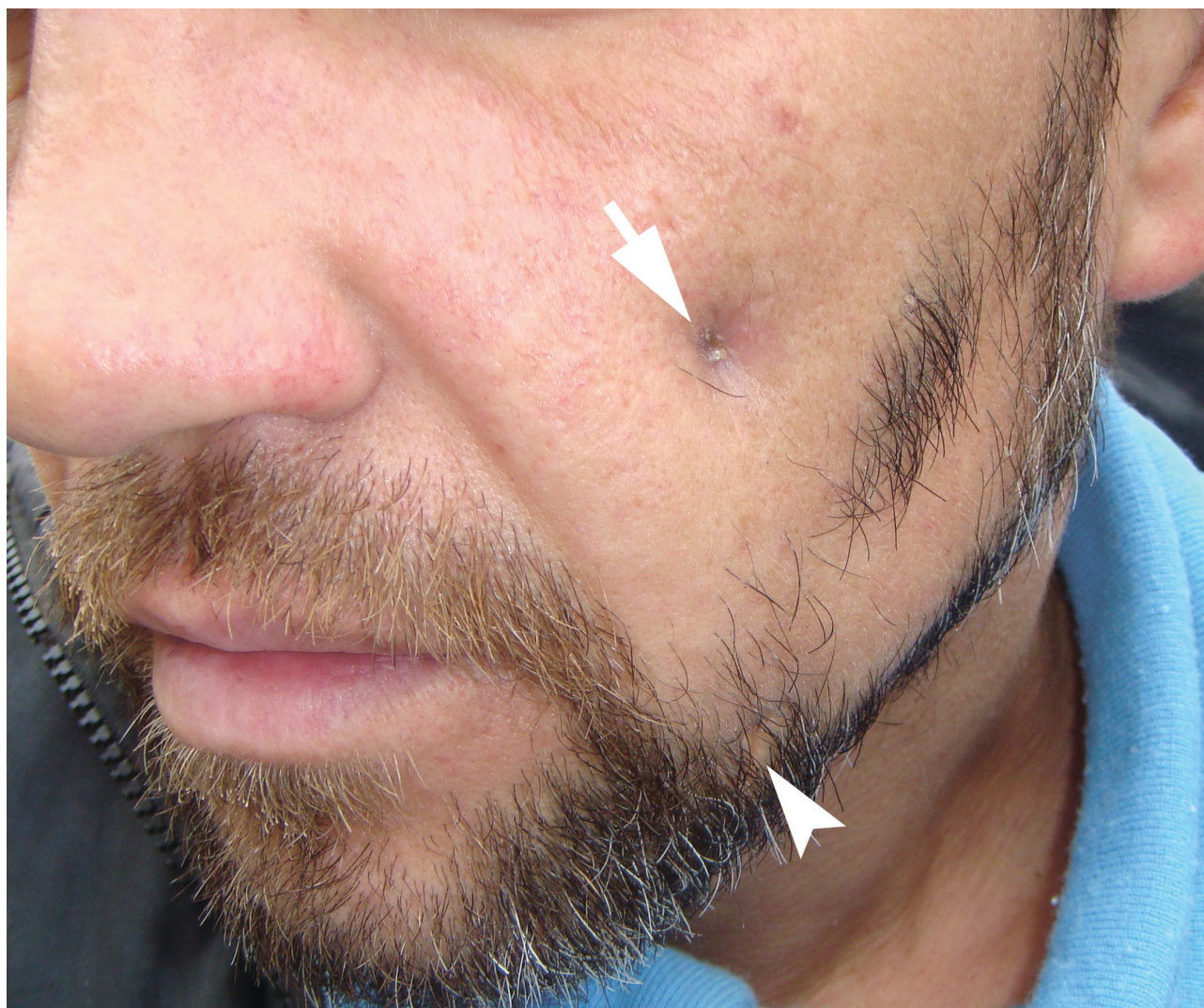

FIGURE 3. Case 3: A 45-year-old male with odontogenic cutaneous fistula (*arrow*) of the left cheek from the maxillary left second molar. *Arrowhead* labels a postoperative scar in the left mandibular region where a similar fistula had been excised several years ago in other hospital. Printed with permission and copyrights retained by I.I.F.

CASE 4

In July 2016, an 18-year-old male was referred to the Center of Maxillofacial Surgery and Dentistry complaining for a painful increasing skin swelling in the left cheek region with erythema. According to patient's words, edema started to grow after the football game left cheek trauma.

During the extraoral examination, an oval shape painful skin erythema with well-defined margins (Fig 4A and B) was noted in the region of left nasolabial fold and upper aspect of buccal region. Intraoral examination with palpation revealed a firm strand (*synonym*: cord-like⁸ formation) in submucosal layer originated from the buccal alveolar bone near tooth #2.6 passing to the region of left nasolabial fold. Tooth #2.6 was non-movable and percussion test was negative. Figures 4C and D have been taken 19 days after the abscess was surgically drained: an oval-shaped erythematous nodule in a place of the previously treated subcutaneous abscess was visualized.

CBCCT (Planmeca ProMax 3D, Helsinki, Finland), performed during the first visit (Figs 4E–M), showed two incompletely treated canals of the tooth #2.6: mesiobuccal – with round shape periapical radiolucency measured $0.91 \times 0.7 \times 1.36$ cm involving buccal plate and palatal – with periapical radiolucency measured $0.58 \times 0.46 \times 0.64$ cm. According to the CT, palatal canal was sealed 3/4 of the length and mesiobuccal – 1/4 of the length.

A minimal (1.72 mm) maxillary sinus mucosa thickening¹¹ (Fig 4M) was observed at the inferior and lateral walls of the left antrum (ie, left maxillary sinus) close to the periapical radiolucency areas. According to Bornstein et al,¹² mucosal thickening less than 2 mm is considered as a non-pathologic sinus membrane.

Figure 4N demonstrates the longitudinal position (related to sinus tract passage) of the linear probe (frequency range: 12–3 MHz) during ultrasonography (model HD11 XE, Philips) on day 19 after the subcutaneous abscess lancing with antibiotic prescription. Gray scale ultrasound (Fig 4O) showed hypoechoic triangular well-defined lesion (measured 1.11 cm in longitudinal direction) in subcutaneous layer with a tube-form hypoechoic curved continuation (0.62 cm in diameter and 2.19 cm in length) to the echoic surface of the left maxilla. Artifact of acoustic shadowing was clearly visualized behind the echoic

surface. The lack of intralesional vascularity on color (Fig 4P) and power (Fig 4Q) Doppler sonograms indicated the team that there was no acute inflammation in the area of lesion. US of the intraosseous part (ie, tooth #2.6 periradicular lesion's part) of the tract (Fig 4R) showed a round-shaped hypoechoic lesion (with heterogenic content) measured 0.7×1.02 cm and surrounded by echoic borders of intraosseous maxillary cavity (formed by chronic periapical abscess).

The surgery was done under general anesthesia with local infiltration by 1.4 ml Ultracain D-S Forte (4 percent articaine hydrochloride, Aventis Pharma Deutschland GmbH, Frankfurt am Main, Germany). First, the mucoperiosteal flap was reflected and a cord-like sinus tract was dissected (Fig 4S) after its empty structure and direction has been confirmed through the transnodal (ie, transcutaneous) introduction of a metal probe. Then, simultaneously with cutaneous nodule, the tract was excised and the tooth #2.6 was extracted.

Histologic examination of the specimen revealed granulomatous tissue with inflammation.

Video 1 shows periradicular lesion of the tooth #2.6 which involved both apices and furcation area.

Video is available in the page of the full-text article on dtjournal.org and in the YouTube channel, available at <https://youtu.be/QkQDvrRMZYw>. Total video's duration: 39 seconds.

RESULTS

Analysis of the four cases with OCSTs revealed (Table 1):

1. A complete resolution of cutaneous manifestation (after causative tooth extraction and antibiotics prescription) in a 24-year-old male with OCST to the left mandibular region from the lower left first molar. His cutaneous lesion of OCST manifested as a cutaneous infiltration stage.
2. A case with 45-year-old male with unilateral multiple OCSTs confirmed the literature data about the multiple OCSTs from different teeth.
3. Histologic report in two cases with OCST (one manifested as cutaneous dimpling with stoma [ie, fistula] and second as cutaneous nodule), managed with tooth extraction, sinus tract and cutaneous excision, showed that in both cases the presence of the soft tissues with a cavity lined with granulations and inflammation around were noted.

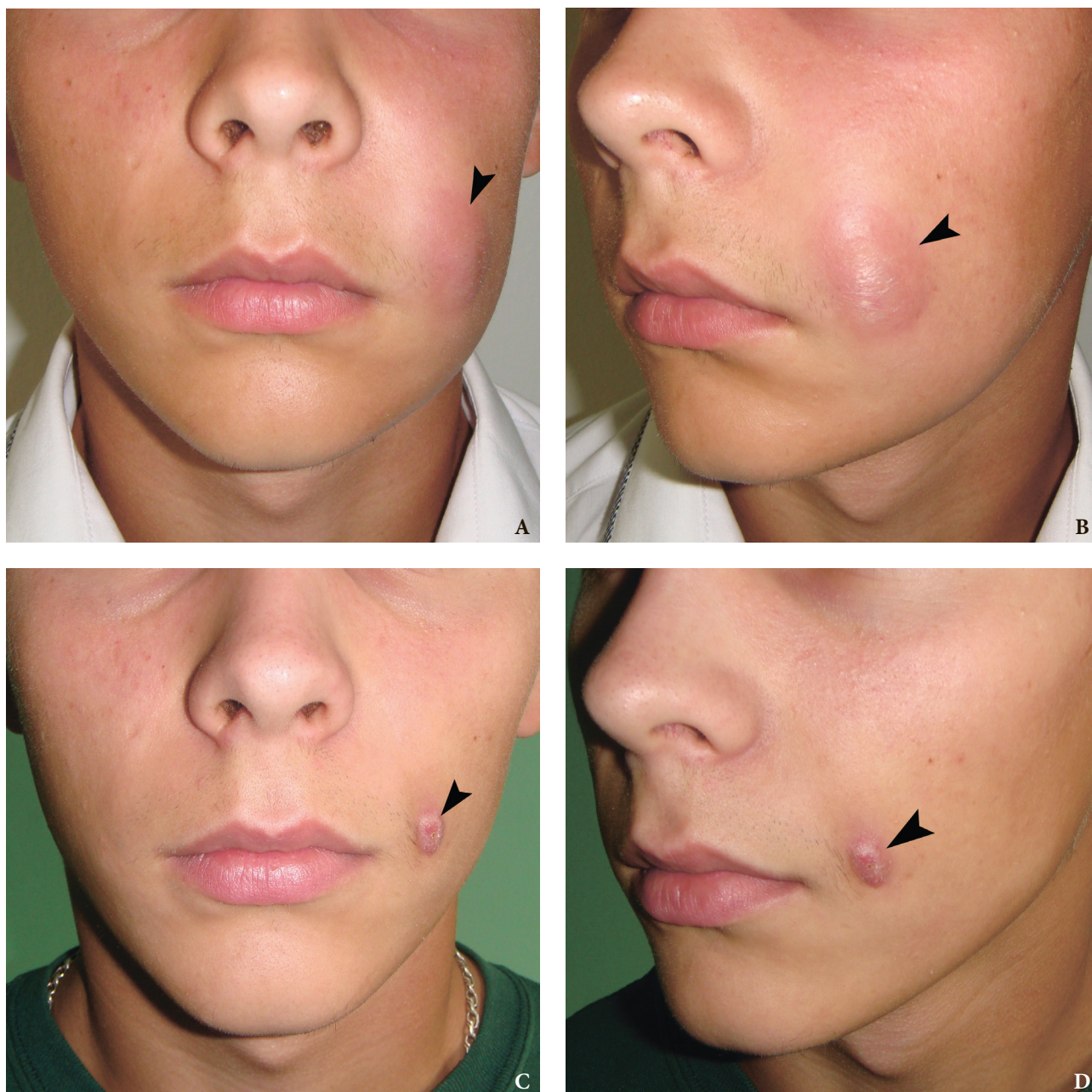


FIGURE 4. Case 4: An 18-year-old male with odontogenic cutaneous sinus tract to left nasolabial fold and cheek from the upper left first molar (ie, tooth #2.6). Images **A** and **B** are taken at moment of the developed abscess (*arrow*). Images **C** and **D** are taken on day 19 after the subcutaneous abscess have been surgically drained: Noted a nodule in a place of the previously treated abscess. Printed with permission and copyrights retained by I.I.F. (**Fig 4 continued on next page.**)

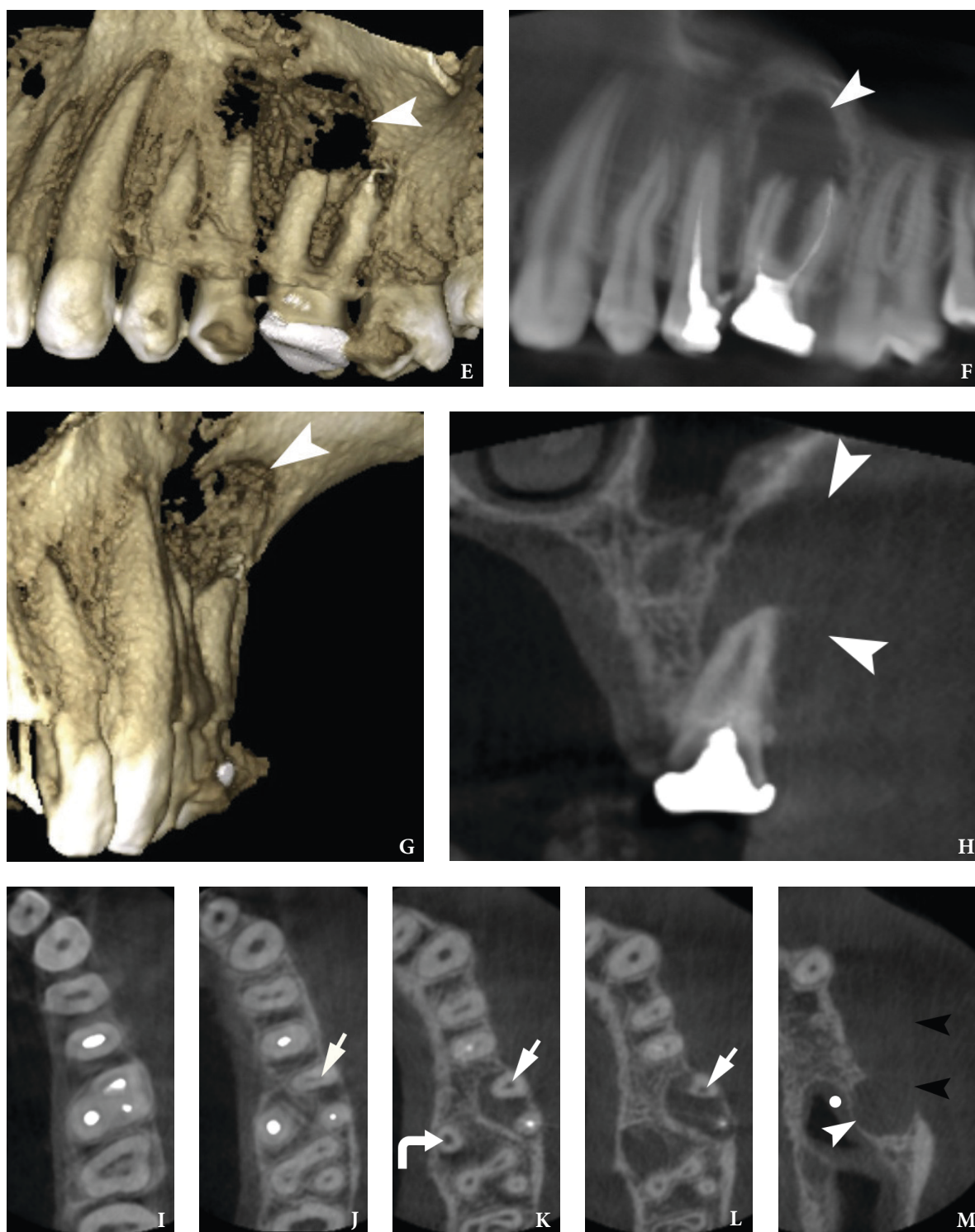


FIGURE 4 (continued). Case 4: An 18-year-old male with odontogenic cutaneous sinus tract to left nasolabial fold and cheek from the upper left first molar (ie, tooth #2.6). Chronic infection–induced bone defect on 3-dimensional (**E, G**) and panoramic (obtained using slice autofocus option) (**F**) CBCT images is indicated by *arrowheads*. Coronal scan (**H**) precisely visualizes the alveolar part of the tract (*arrowheads*). Sequence of axial scans (**I–M**) showed untreated mesiobuccal canal (*arrows*) which became a cause of the chronic periapical abscess (*white arrowhead*). The direction and the lateral wall of the sinus tract are labeled by *black arrowheads*. Incompletely treated palatal canal is labeled by *curved arrow*. Larger periapical radiolucency (in the area of buccal roots) (*arrowhead*) measured $9.17 \times 7.00 \times 13.69$ mm. An insignificant (1.72 mm) maxillary sinus mucosa thickening is indicated by *dot*. Printed with permission and copyrights retained by I.I.F. (**Fig 4 continued on next page.**)

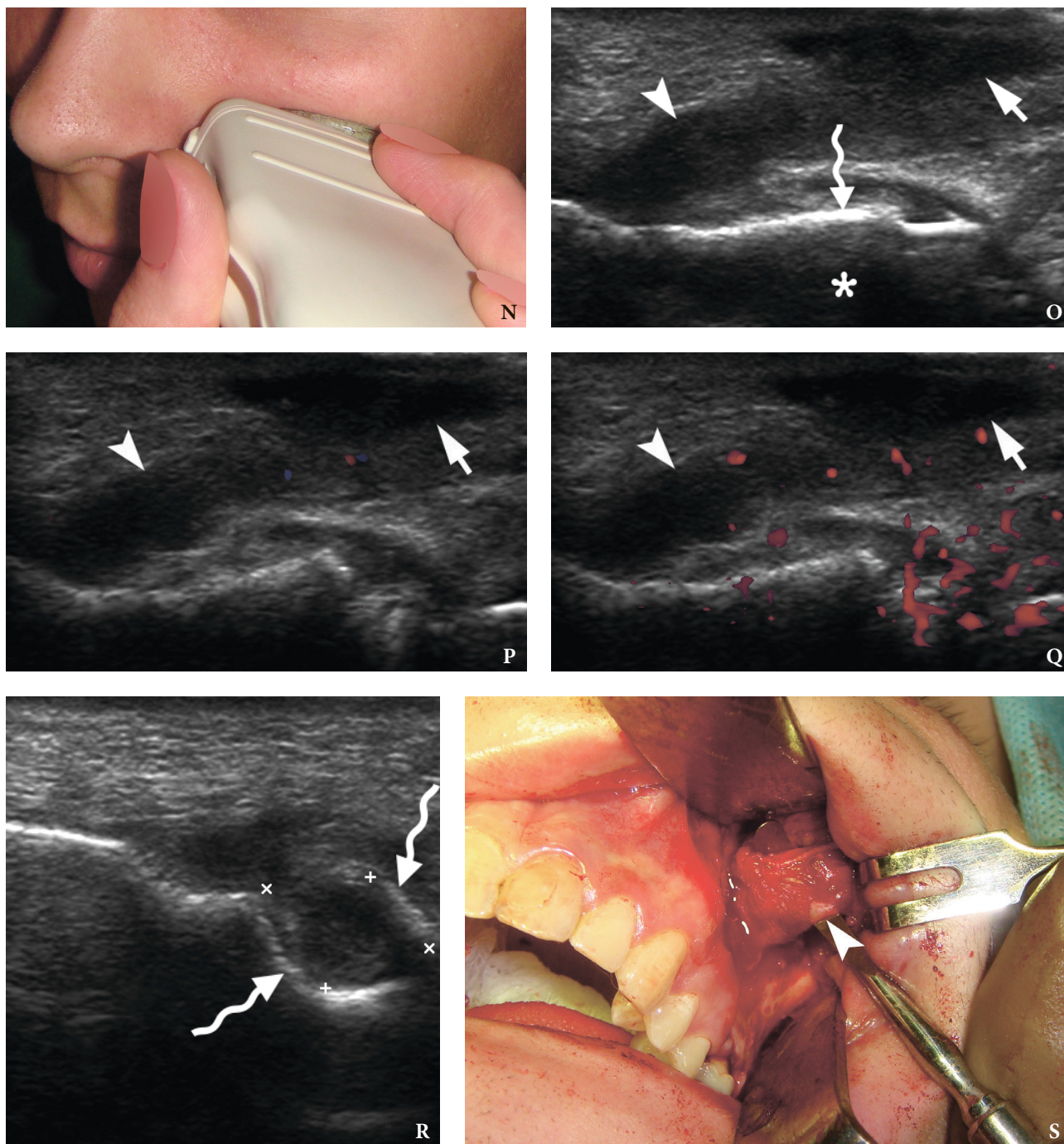
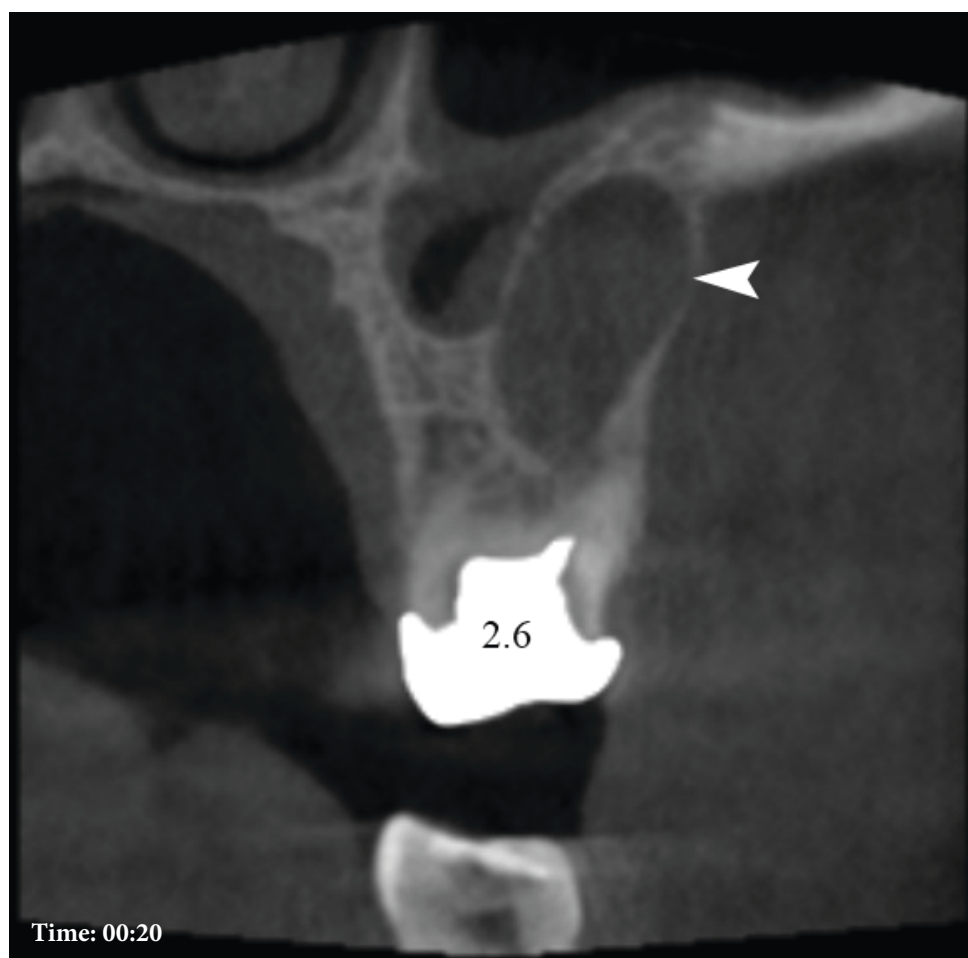


FIGURE 4 (continued). Case 4: An 18-year-old male with odontogenic cutaneous sinus tract to left nasolabial fold and cheek from the upper left first molar (ie, tooth #2.6). Image **N** demonstrates the longitudinal position (related to sinus tract passage) of the linear transducer during ultrasonography (images **O–Q**) on day 19 after the subcutaneous abscess lancing with antibiotic prescription. Gray scale ultrasound (**O**) showed hypoechoic triangular well-defined lesion (*arrow*) (measured 1.11 cm in longitudinal direction) in subcutaneous layer with a tube-form hypoechoic curved continuation (0.62 cm in diameter and 2.19 cm in length) to the echoic surface (*waved arrow*) of the left maxilla. Artifact of acoustic shadowing is indicated by *asterisk*. Color (**P**) and power (**Q**) Doppler sonograms revealed no intralésional vascularity. This means that there is no acute inflammation in the area of lesion. Gray scale US of the intraosseous part of the tract (**R**) showed a round shape hypoechoic lesion (indicated by '+' and 'x' calipers) (with heterogenic content) measured 0.7×1.02 cm and surrounded by echoic borders (*waved arrows*) of intraosseous maxillary cavity (formed by chronic periapical abscess). At the intraoperative image (**S**) the dissected sinus tract (*arrowhead*) is elevated by an instrument before its excision. Printed with permission and copyrights retained by O.S.C. (images **O–R**) and I.I.F (images **S**).



VIDEO 1. Case 4: An 18-year-old male with odontogenic cutaneous sinus tract to left nasolabial fold and cheek from the improperly treated upper left first molar (ie, tooth #2.6). Video represents a sequence of coronal CBCT scans. Notes two periradicular lesions: 1) a larger one (a sinus tract causative lesion) (*arrowhead*) around the tooth #2.6 which involves mesio- and distobuccal root apices and furcation area and 2) a smaller lesion around the apex of the palatal root.

Video is available in the page of the full-text article on dtjournal.org and in the YouTube channel, available at <https://youtu.be/QkQDvrRMZYw>. Or just point the smartphone/tablet camera at the QR code and click on the pop-up menu "Open ... in" Total video `s duration: 39 seconds.

Printed with permission and copyrights retained by I.I.F.



QR code leads to Video 1 at
YouTube channel [Videos DTJournal](#)

TABLE 1. Patient Data, Cutaneous Manifestations of the OCSTs, Associated Teeth, and Management.

Case	Age (yr)/ Gender	Cutaneous Manifestations	Area of Manifestations	Tooth #	Management
1	24/M	Cutaneous infiltration with formation of the abscess	Left mandibular body	3.6	Tooth extraction + antibiotics
2	41/M	Fistula with deep dimpling	Right mandibular body	4.7	Tooth extraction, tract + cutaneous lesion excision, and local skin plasty
3	45/M	Fistula with dimpling	Left cheek	2.7	The patient refused any treatment
		Scar after treated fistula with dimpling	Left mandibular body	3.6	In anamnesis: tooth extraction, tract + cutaneous lesion excision, and local skin plasty was performed
4	18/M	Abscess at first consultation	Left nasolabial fold	2.6	First visit – abscess lancing, second visit – tooth extraction and excision of the skin lesion with a sinus tract
		Nodule at day 19 after abscess lancing			

DISCUSSION

Odontogenic cutaneous sinus tract can be termed as “chronic periapical abscess with an extraoral sinus opening¹³”. Metzger et al applied a similar term, “a chronic apical abscess,” describing the origin of OCST.¹⁴ Giménez-García et al¹⁵ highlighted that sinus tracts can also originate from loci of the osteomyelitis, osteonecrosis, suppurative infections, infected cysts, and tubercular infection. Even the case of an extraoral draining actinomycotic sinus tract with bifurcation was described by Göçmen et al.¹⁶

Kishore Kumar et al’s clinical study of 200 patients with cutaneous sinuses of the cervicofacial region clearly showed that 80 percent of them are of odontogenic origin.¹⁷

Usually OCST appears as a single unilateral pathologic process, but in rare cases can be noted a several OCSTs (ie, multiple OCSTs)^{5,6} what is proved by the case 3 (with unilateral multiple OCSTs) of our report. The multiple OCSTs in the study of Sakamoto and Stratigos were named as bilateral cutaneous sinus tracts of dental etiology due to the localization of the last.¹⁸

Tremendously huge variety of cutaneous manifestations of the OCSTs leads to its different clinical descriptions in the publications, terms, and the number of initial misdiagnosis¹⁹.

Lee et al³ in 2016, based on the analysis of thirty-four OCSTs, described four most common morphological types of cutaneous manifestations:

1. Dimpling (41.2 percent).

2. Nodule (32.4 percent).
3. Abscess (20.6 percent).
4. Cyst (5.9 percent).

Literature also allocates such forms of skin lesion appearances of the OCSTs like *cutaneous infiltration*^{5,6}, *suppurated nodule*,⁷ and even seventh form of manifestations—*odontogenic cutaneous granuloma with fistula*.⁶

Trying to highlight a wide variety of descriptions of cutaneous part of the OCSTs, here are just a few of them: 1) erythematous, exophytic nodule with a crusted surface and a central stoma¹³, 2) puckered appearance on the skin²⁰, 3) an erythematous, crusted nodule measuring about 50 mm with pus discharge²¹, 4) affected skin can be hyperemic or of a normal color, thinned, cyanotic, glossy, forms folds and unevenness^{5,6}, 5) reddish abscess 2.5 cm in diameter²², 6) orocutaneous fistula¹⁹, 7) granuloma (ie, such type of cutaneous manifestation of OCST [not a pyogenic granuloma]) sizes are variable (from 1 to 3-4 cm)⁵, 8) classically, the lesion presented as an erythematous nodule of diameter up to 2 cm with or without drainage²³, 9) nodulocystic cutaneous lesion⁷, 10) cutaneous fistula with hyperpigmented retracted skin²⁴, etc.

Though the term “parulis” is sometimes applied²⁵ to the skin part of the OCST, predominantly, the “parulis” (ie, gingival abscess) name, is used for the submucosal abscess in the gingival tissues²⁶ linked by fistula with a locus of odontogenic infection and can be diagnosed by gutta-percha point (ie, gutta-percha cone⁷). Neville et al²⁷ described parulis as

an exophytic, erythematous or yellowish mass of granulation tissue on the gingival/alveolar mucosa.

In our opinion, all cutaneous manifestations of the OCSTs can be divided into the two types (Fig 5):

1. Manifestations above the skin level (cutaneous infiltration, nodule, and abscess).
2. Manifestations below the skin level (ie, dimpling with active/non-active fistula).

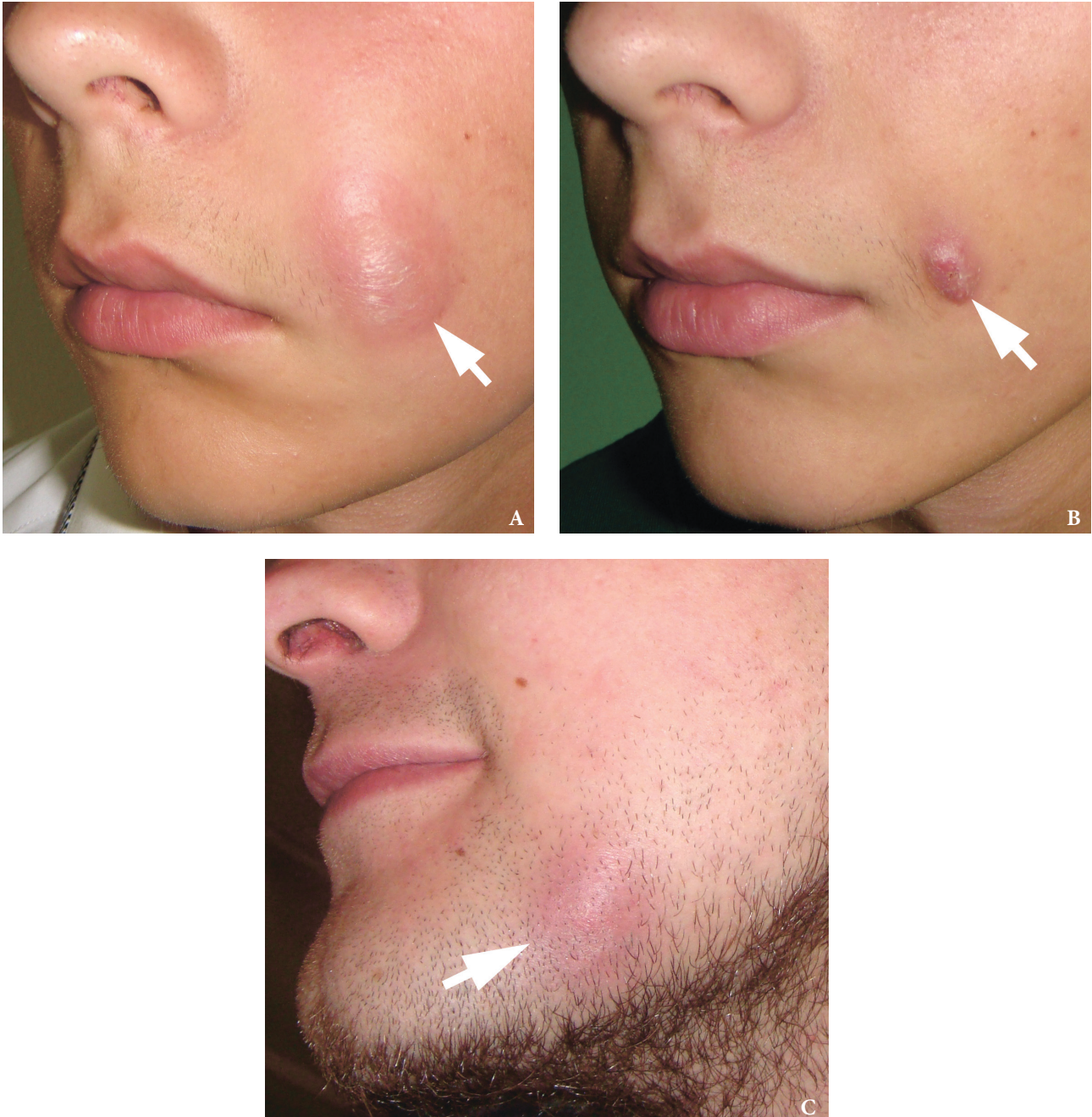

FIGURE 5. Comparison of odontogenic cutaneous sinus tracts with “above” (A–C) and “below the skin level” (D, E) cutaneous manifestations in four patients. Abscess (A), nodule (B), cutaneous infiltration (C), dimpling with non-active fistula (D), and the deep dimpling with active fistula (E) are labeled by arrows. (Fig 5 continued on next page.)

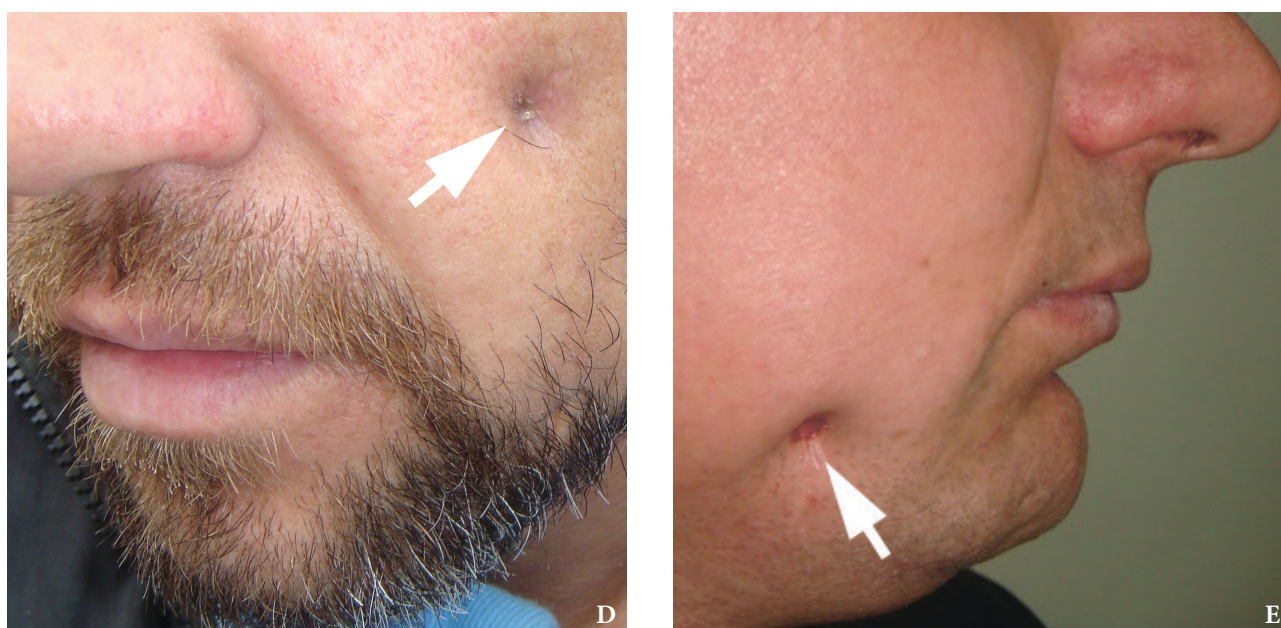


FIGURE 5 (continued). Comparison of odontogenic cutaneous sinus tracts with “above” (A–C) and “below the skin level” (D, E) cutaneous manifestations in four patients. Abscess (A), nodule (B), cutaneous infiltration (C), dimpling with non-active fistula (D), and the deep dimpling with active fistula (E) are labeled by arrows.

This partitioning of OCST cutaneous part appearances is similar to the partitioning into 1) odontogenic cutaneous fistulas and 2) odontogenic subcutaneous granulomas.^{5,6}

It should be remembered that 50 percent of patients affected by OCSTs are subjected to incorrect management before the correct diagnosis is established.²⁸ But it’s easy to avoid the misdiagnosis by using the combination of such an advanced technologies like ultrasonography (ie, ultrasound [US]) and CBCT. There is an urgent need to highlight for oral and maxillofacial surgeons the advantages of the US for their practice in general and for the diagnostics of the OCSTs in particular.

The differential diagnosis of OCST includes the sinus tracts of all other origins (actinomyces, osteomyelitis, etc)^{16,17}, pyogenic granuloma¹⁹, non-odontogenic subcutaneous granuloma^{5,6}, infected sebaceous gland cyst (also known as atheroma)⁵, suppurative lymphadenitis^{5,21}, furuncle²⁹, malignancies^{30,31}, etc. Moreover, Kim et al reported a unique case of cutaneous basal cell carcinoma arising in the area of odontogenic cutaneous fistula in a 64-year-old male patient.³²

Pseudofluctuation (feeling upon palpation for the false wavelike motion of the collected fluid [eg, pus]) is one of the core signs for the OCST manifested as a subcutaneous granuloma.⁶ In fact, the symptom of

pseudofluctuation is explained by the abundance of granulation tissue in the pathological focus.⁵

Honestly saying, Lee, Oh, and Yoon and other authors^{27,33} are more than right when notice that a term “pyogenic granuloma” is a misnomer as it does not contain purulent content and is not, strictly speaking, a granuloma upon the histopathological examination.¹⁹

The best way to avoid OCST misdiagnosis and mismanagement is to choose the best diagnostic technology or its combination. Such a radiation free imaging modality as ultrasound proved its efficacy even upon assessment of jaw bone healing after root-end surgeries.³⁴ The soft tissues US investigation has even much wider diagnostic horizons. And we found four English language articles which described fifteen OCST cases examined by US (Table 2): 3 (Shobatake et al, 2014)⁷, 1 (Garido Colmenero et al, 2015)¹⁰, 1 (Lee and Yun, 2016)¹, and 10 cases (Cotti et al, 2019)⁴. Two papers (50 percent) were published in dermatological journals, one (25 percent) in the emergency medicine journal, and one (25 percent) in the dental journal devoted to endodontics.

Analyzing the international experience and our case we summarized the US features of the OCSTs in the Table 3.

So, the US proved its usefulness in understanding

TABLE 2. English Language Publications Which Describe Ultrasonography of the OCSTs.

#	Authors and Article's Title	Year	Number of Examined OCSTs	Journal
1	Shobatake et al. Usefulness of ultrasonography for rapidly diagnosing cutaneous sinus tracts of dental origin. ⁷	2014	3	European Journal of Dermatology
2	Garrido Colmenero et al. Diagnostic value of color Doppler ultrasound for cutaneous odontogenic sinus tract. ¹⁰	2015	1	Actas Dermo-Sifiliográficas
3	Lee and Yun. Odontogenic cutaneous sinus tract presenting as a growing cheek mass in the emergency department. ¹	2017	1	American Journal of Emergency Medicine
4	Cotti et al. Ultrasound examination to visualize and trace sinus tracts of endodontic origin. ⁴	2019	10	Journal of Endodontics

TABLE 3. Ultrasound Appearance (Description) of Different Parts of the OCSTs Based on the Data of Literature and Our Report.

Article	Intra-/ Periosteal Part	Sinus Tract	Cutaneous/ Subcutaneous Part
Shobatake et al ⁷	No data	Gray scale US: Hypoechoic band that originated from the cutaneous lesion and extended through the subcutaneous tissue to the alveolar bone. Color Doppler US showed some color signals around the lesion	No data
Garrido Colmenero et al ¹⁰	No data	Gray scale US: A slightly tortuous, relatively well-defined, hypoechoic linear structure extending to the surface of the cortical plate of the jaw	No data
Lee and Yun ¹	No data	Gray scale US: A heterogeneous hypoechoic mass	Gray scale US: Hyperechoic. Color Doppler US reveals intralesional vascularity
Cotti et al ⁴	Gray scale US: Apical periodontitis visualized as anechoic to hypoechoic areas	Gray scale US: The sinus tracts appeared as dishomogeneous, hypoechoic pathways lined by echogenic and reinforced walls	Gray scale US: Hypoechoic band (ie, sinus tract) crossed the muscular layer of the muscle to reach the surface of the skin
Our study: Cherniak et al	Gray scale US: Round-shape hypoechoic lesion (with heterogenic content) surrounded by echoic borders of pathologic intraosseous jaw cavity	Gray scale US: Tube-form (curved strand) hypoechoic continuation (0.62 cm in diameter and 2.19 cm in length) of the cutaneous lesion to the echoic jaw surface	Gray scale US: A hypoechoic triangular well-defined lesion (measured 1.11 cm in longitudinal direction) in subcutaneous layer

weather the cutaneous lesion has the sinus tract and in helping to trace its direction (ie, to perform ultrasound tracing [*synonym*: ecographic tracing⁴]) and find the locus of its origin.

Highest precision of endodontic diagnosis/management in cases of the OCSTs is proved by the studies highlighted the CBCT.^{35,36} **Sodnom-Ish** et al presented the arguments for using a CT with soft tissue window setting, as the path of the sinus tract was easily identified in both of their cases.²⁸ **Figure 4M** also demonstrates the possibilities of CBCT in the identification of the sinus tract.

Swales et al's review analysis of the implemented treatment tactics showed its great variety.²⁹ But the most correct choice of treatment in every particular situation will be possible if we take into consideration two core things: 1) microscopical composition of the sinus tracts and 2) all pro and contra of management tactics.

Harrison and **Larson** proved that 9 of the 10 intraoral (ie, oral) sinus tracts (ie, those which extend from periapical lesions to the alveolar mucosa) were lined with granulation tissue that contained chronic inflammatory cells.³⁷ Only one of the 10 was lined with stratified squamous epithelium.³⁷ The authors concluded that there is no dependence of presence of the epithelial lining from the existence of the sinus tract.^{37,38}

Baumgartner et al presented a study based on 30 examined oral sinus tracts and in 67 percent of cases the sinus tracts were lined by granulomatous tissue and only in 33 percent cases by epithelial lining to the level of periapex.³⁸ In the investigated cases the epithelial lining originated not from the periapical lesion's epithelium but from the mucosal surface.³⁷

Bai et al presented a data of 53-year-old man with OCST of the submental area from lower left second molar; and pathological analysis clearly confirmed that the tract was lined with granulation tissue.³⁹

In a 64-year-old male patient with cutaneous basal cell carcinoma arising in odontogenic cutaneous fistula the sinus tract was also lined by inflamed granulation tissue.³²

Chang highlighted two case reports (23-year-old and 55-year-old males) with extraoral odontogenic sinus tracts which included its excision and in both patients the histologic report revealed chronic inflammation with fibrosis.⁴⁰

Other sources, which describe an odontogenic subcutaneous granuloma (as an OCST

manifestations), reported the presence of granulation tissue in subcutaneous layer (in a place of cutaneous lesion), where it develops in the form of separate clusters – granulomas.^{5,6}

The sinus tract lining with granulations was also proved by our two cases (case 2 and 4). This pathohistological feature of sinus tracts in the published reports and in our cases supports the opinions presented in the works of **Barrowman** et al⁴¹ and **Pasternak-Júnior** et al⁴² that OCSTs can and should be treated endodontically. **Berman** and **Rotstein** insisted that presence/absence of an epithelial lining does not seem to prevent closure of the tract as long as the source of the problem is properly diagnosed and adequately treated and the tooth-associated infection has eliminated.²⁵

Thus, although conservative treatment^{22,29,36} nowadays is highly advocated, we strongly recommend (taking into account the experience from Korea)³² to choose between two different management combinations for the group of elderly patients: 1) endodontic plus surgical treatment (apicoectomy + excision of the tract and cutaneous lesion) or 2) necrotic tooth extraction + excision of the tract and cutaneous lesion.

But we should remember the experience of **Pérez-Alfonzo** et al⁴³ who emphasized that OCST can be refractory to standard treatments in cases of possible infection due to nontuberculous mycobacteria.

Varghese et al notice: in some cases (when the cutaneous changes are reversible) endodontic treatment of the necrotic tooth alone can eliminate the need for surgery, and in other cases (when the cutaneous changes are irreversible) – at least such treatment can improve the condition of the tissues in area of cutaneous lesion.¹³ Resolution of dimpling and hyperpigmentation is usually very slow and it can remain for a long time. So, the surgical revision may be needed for esthetic reasons.³

Rahpeyma and **Khajehahmadi** recommended performing a needle subcision for the conservative treatment for facial dimpling after elimination of the source of odontogenic infection.⁴⁴

It's important to understand that possibility of the extraoral sinus tract to develop appears not only in the case of chronic periapical abscess but also in cases after the tooth extraction.⁴⁵ In about 19 percent of the 117 patients (with nonhealing sinuses and fistulous tracts) from the study of **Chowdri** et al, the

sinus tracts followed teeth extractions.⁴⁵ Such post-extraction sinus tract may be caused by incorrect sterilization, antibiotic use, surgical technique, or attempted tooth extraction in the presence of infection.⁴⁵

Summarizing, it's important to remember the opinion of Jibbe and Tolkachjov.⁴⁶ No matter what is a level of radiological knowledge of the surgeon the need to re-read or to re-watch the sonograms or CT scans are very important when clinical suspicion does not correlate with the radiological report.⁴⁶ Also, taking into consideration the histological structure of the extraoral sinus tract itself and its skin manifestations, we can consider appropriate to continue to use the term *odontogenic subcutaneous granuloma* in a certain cases, but with mandatory indication of its clinical stage. Such cases are *above the skin level manifestations* of the OCST like cutaneous infiltration, nodule, and abscess.

CONCLUSIONS

In sum, the *odontogenic cutaneous sinus tract* is a collective term for the locus of tooth-associated infection and pathologic exudate-draining tube-shape formation to one of at least seven possible cutaneous manifestations, such as *dimpling with fistula, cutaneous infiltration, abscess, nodule, suppurated nodule, odontogenic cutaneous granuloma with fistula, or even cyst-like lesion*. Moreover, those manifestations can transform one into another depending on different reasons, what is proved by a literature and our cases. Combination of diagnostics methods like ultrasound and computed tomography can guarantee the highest level of accuracy in establishing the diagnosis and lowest level of mistreatment especially for the less experienced doctors.

TERM OF CONSENT

Written patient consent was obtained from all patients to publish the clinical photographs.

AUTHOR CONTRIBUTIONS

Conceptualization: Fesenko II. Data acquisition: Cherniak OS, Snisarevskyi PP, Zaritska VI, Pavlenko RA. Data analysis or interpretation: Koba NM, Fesenko II. Drafting of the manuscript: Blinova VP,

Holodenko VM. Critical revision of the manuscript: Zaritska VI, Fesenko II, Cherniak OS. Approval of the final version of the manuscript: all authors.

CONFLICT OF INTERESTS

The authors declare no conflict of interest.

FUNDINGS

No funding was received for this study.

REFERENCES

1. Lee SH, Yun SJ. Odontogenic cutaneous sinus tract presenting as a growing cheek mass in the emergency department. *Am J Emerg Med* **2017**;35(5):808.e5–808.e7. <https://doi.org/10.1016/j.ajem.2016.12.024>
2. Guevara-Gutiérrez E, Riera-Leal L, Gómez-Martínez M, Amezcua-Rosas G, Chávez-Vaca CL, Tlacuilo-Parra A. Odontogenic cutaneous fistulas: clinical and epidemiologic characteristics of 75 cases. *Int J Dermatol* **2015**;54(1):50–5. <https://doi.org/10.1111/ijd.12262>
3. Lee EY, Kang JY, Kim KW, Choi KH, Yoon TY, Lee JY. Clinical characteristics of odontogenic cutaneous fistulas. *Ann Dermatol* **2016**;28(4):417–21. <https://doi.org/10.5021/ad.2016.28.4.417>
4. Cotti E, Musu D, Goddi A, Dettori C, Campisi G, Shemesh H. Ultrasound examination to visualize and trace sinus tracts of endodontic origin. *J Endod* **2019**;45(10):1184–91. <https://doi.org/10.1016/j.joen.2019.07.009>
5. Tymofieiev OO. Manual of maxillofacial and oral surgery [Russian]. 5th ed. Kyiv, Ukraine: Chervona Ruta-Turs; **2012**.
6. Tymofieiev OO. Maxillofacial surgery and surgical dentistry [Russian]. Kyiv, Ukraine: Medicine; **2020**.
7. Shobatake C, Miyagawa F, Fukumoto T, Hirai T, Kobayashi N, Asada H. Usefulness of ultrasonography for rapidly diagnosing cutaneous sinus tracts of dental origin. *Eur J Dermatol* **2014**; 24(6):683–7. <https://doi.org/10.1684/ejd.2014.2441>
8. Tidwell E, Jenkins JD, Ellis CD, Hutson B, Cederberg RA. Cutaneous odontogenic sinus tract to the chin: a case report. *Int Endod J* **1997**;30(5):352–5. <https://doi.org/10.1046/j.1365-2591.1997.00084.x>
9. Jacobs HG. Contribution to clinical findings of the so-called chronic granulating periodontitis Partsch. *Dtsch Stomatol* **1991**;41(6):214–8.
10. Garrido Colmenero C, Blasco Morente G, Latorre Fuentes JM, Ruiz Villaverde R. Diagnostic value of color Doppler ultrasound for cutaneous odontogenic sinus tract [English, Spanish]. *Actas Dermosifiliogr* **2015**;106(8):678–80. <https://doi.org/10.1016/j.ad.2014.12.023>

11. Block MS, Dastoury K. Prevalence of sinus membrane thickening and association with unhealthy teeth: a retrospective review of 831 consecutive patients with 1,662 cone-beam scans. *J Oral Maxillofac Surg* **2014**;72(12):2454–60. <https://doi.org/10.1016/j.joms.2014.06.442>
12. Bornstein MM, Wasmer J, Sendi P, Janner SF, Buser D, von Arx T. Characteristics and dimensions of the Schneiderian membrane and apical bone in maxillary molars referred for apical surgery: a comparative radiographic analysis using limited cone beam computed tomography. *J Endod* **2012**;38(1):51–7. <https://doi.org/10.1016/j.joen.2011.09.023>
13. Varghese LL, Bhattacharya A, Sharma P, Apratim A. Non-surgical management of an extraoral cutaneous sinus tract of odontogenic origin. *BMJ Case Rep* **2020**;13(7):e234699. <https://doi.org/10.1136/bcr-2020-234699>
14. Metzger Z, Abramovitz I, Bergenholtz G. Apical periodontitis. In: Bergenholtz G, Hørsted-Bindslev P, Reit C, editors. *Textbook of endodontology*. 2nd ed. Wiley-Blackwell: Oxford, United Kingdom; **2010**:113–27.
15. Giménez-García R, Martínez-Vera F, Fuentes-Vera L. Cutaneous sinus tracts of odontogenic origin: two case reports. *J Am Board Fam Med* **2015**;28(6):838–40. <https://doi.org/10.3122/jabfm.2015.06.150046>
16. Göçmen G, Varol A, Göker K, Basa S. Actinomycosis: report of a case with a persistent extraoral sinus tract. *Oral Surg Oral Med Oral Pathol Oral Radiol Endod* **2011**;112(6):e121–3. <https://doi.org/10.1016/j.tripleo.2011.06.008>
17. Kishore Kumar RV, Devireddy SK, Gali RS, Chaithanyaa N, Chakravarthy C, Kumarvelu C. Cutaneous sinuses of cervicofacial region: a clinical study of 200 cases. *J Maxillofac Oral Surg* **2012**;11(4):411–5. <https://doi.org/10.1007/s12663-012-0353-y>
18. Sakamoto E, Stratigos GT. Bilateral cutaneous sinus tracts of dental etiology: report of case. *J Oral Surg* **1973**;31(9):701–4.
19. Lee JH, Oh JW, Yoon SH. Orocutaneous fistulas of odontogenic origin presenting as a recurrent pyogenic granuloma. *Arch Craniofac Surg* **2019**;20(1):51–4. <https://doi.org/10.7181/acfs.2018.01991>
20. Fragiskos FD. Odontogenic infections. In: Fragiskos FD, editor. *Oral surgery*. 1st ed. Heidelberg, Germany: Springer; **2007**: 205–41.
21. Ohta K, Yoshimura H. Odontogenic cutaneous fistula of the face. *CMAJ* **2019**;191(46):E1281. <https://doi.org/10.1503/cmaj.190674>
22. Chen K, Liang Y, Xiong H. Diagnosis and treatment of odontogenic cutaneous sinus tracts in an 11-year-old boy: a case report. *Medicine (Baltimore)* **2016**;95(20):e3662. <https://doi.org/10.1097/MD.0000000000003662>
23. Samir N, Al-Mahrezi A, Al-Sudairy S. Odontogenic cutaneous fistula: report of two cases. *Sultan Qaboos Univ Med J* **2011**;11(1):115–8.
24. Figaro N, Juman S. Odontogenic cutaneous fistula: a cause of persistent cervical discharge. *Case Rep Med* **2018**;2018:3710857. <https://doi.org/10.1155/2018/3710857>
25. Berman LH, Rotstein I. Diagnosis. In: Berman LH, Hargreaves KM, editors. *Cohen's pathways of the pulp expert consult*. 11th ed. St. Louis, MO, United States: Mosby; **2015**:2–32.
26. Eversole LR. Intraoral soft tissues swellings. In: Eversole LR, editor. *Clinical outline of oral pathology*. 3rd ed. Hamilton, Canada: BC Decker; **2002**:111–60.
27. Neville BW, Damm DD, Allen CM, Chi AC. Pulp and periapical disease. In: Neville BW, Damm DD, Allen CM, Chi AC. *Color atlas of oral and maxillofacial diseases*. Philadelphia, PA, United States: Elsevier; **2019**:79–92.
28. Sodnom-Ish B, Eo MY, Kim SM. An accurate diagnosis of odontogenic cutaneous sinus tract by different CT unit setting. *J Korean Assoc Oral Maxillofac Surg* **2020**;46 [article in press].
29. Swales KL, Rudralingam M, Gandhi S. Extraoral cutaneous sinus tracts of dental origin in the paediatric patient. A report of three cases and a review of the literature. *Int J Paediatr Dent* **2016**;26(5):391–400. <https://doi.org/10.1111/ipd.12205>
30. Baba A, Okuyama Y, Shibui T, Ojiri H. Odontogenic cutaneous fistula mimicking malignancy. *Clin Case Rep* **2017**;5(5):723–4. <https://doi.org/10.1002/ccr3.907>
31. Okorochoa N, Denny JW, Ardehali B. A dental sinus mimicking skin cancer. *BMJ* **2018**;363:k4461 <https://doi.org/10.1136/bmj.k4461>
32. Kim NG, Kim JO, Park YJ, Kim JS, Lee YJ, Lee KS. Cutaneous basal cell carcinoma arising in odontogenic cutaneous fistula. *Arch Craniofac Surg* **2017**;18(2):141–4. <https://doi.org/10.7181/acfs.2017.18.2.141>
33. Patil K, Mahima VG, Lahari K. Extralingival pyogenic granuloma. *Indian J Dent Res* **2006**;17(4):199–202. <https://doi.org/10.4103/0970-9290.29864>
34. Curvers F, Meschi N, Vanhoenacker A, Strijbos O, Van Mierlo M, Lambrechts P. Ultrasound assessment of bone healing after root-end surgery: echoes back to patient's safety. *J Endod* **2018**;44(1):32–7. <https://doi.org/10.1016/j.joen.2017.08.028>
35. Shemesh A, Hadad A, Azizi H, Lvovsky A, Ben Itzhak J, Solomonov M. Cone-beam computed tomography as a noninvasive assistance tool for oral cutaneous sinus tract diagnosis: a case series. *J Endod* **2019**;45(7):950–6. <https://doi.org/10.1016/j.joen.2019.03.017>
36. Tian J, Liang G, Qi W, Jiang H. Odontogenic cutaneous sinus tract associated with a mandibular second molar having a rare distolingual root: a case report. *Head Face Med* **2015**;11:13. <https://doi.org/10.1186/>

- s13005-015-0072-y
37. Harrison JW, Larson WJ. The epithelized oral sinus tract. *Oral Surg Oral Med Oral Pathol* **1976**;42(4):511–7. [https://doi.org/10.1016/0030-4220\(76\)90299-1](https://doi.org/10.1016/0030-4220(76)90299-1)
 38. Baumgartner JC, Picket AB, Muller JT. Microscopic examination of oral sinus tracts and their associated periapical lesions. *J Endod* **1984**;10(4):146–52. [https://doi.org/10.1016/S0099-2399\(84\)80117-X](https://doi.org/10.1016/S0099-2399(84)80117-X)
 39. Bai J, Ji AP, Huang MW. Submental cutaneous sinus tract of mandibular second molar origin. *Int Endod J* **2014**;47(12):1185–91. <https://doi.org/10.1111/iej.12266>
 40. Chang LS. Common pitfall of plastic surgeon for diagnosing cutaneous odontogenic sinus. *Arch Craniofac Surg* **2018**;19(4):291–5. <https://doi.org/10.7181/acfs.2018.02110>
 41. Barrowman RA, Rahimi M, Evans MD, Chandu A, Parashos P. Cutaneous sinus tracts of dental origin. *Med J Aust* **2007**;186(5):264–5. <https://doi.org/10.5694/j.1326-5377.2007.tb00886.x>
 42. Pasternak-Júnior B, Teixeira CS, Silva-Sousa YT, Sousa-Neto MD. Diagnosis and treatment of odontogenic cutaneous sinus tracts of endodontic origin: three case studies. *Int Endod J* **2009**;42(3):271–6. <https://doi.org/10.1111/j.1365-2591.2008.01519.x>
 43. Pérez-Alfonzo R, Poleo Brito LE, Vergara MS, Ruiz Damasco A, Meneses Rodríguez PL, Kannee Quintero CE, Carrera Martínez C, Rivera-Oliver IA, Da Mata Jardim OJ, Rodríguez-Castillo BA, de Waard JH. Odontogenic cutaneous sinus tracts due to infection with nontuberculous mycobacteria: a report of three cases. *BMC Infect Dis* **2020**;20(1):295. <https://doi.org/10.1186/s12879-020-05015-5>
 44. Rahpeyma A, Khajehahmadi S. Needle subcision: a conservative treatment for facial dimpling after elimination of odontogenic infection source: a technical note. *Oral Maxillofac Surg* **2014**;18(4):415–8. <https://doi.org/10.1007/s10006-013-0429-y>
 45. Chowdri NA, Sheikh S, Gagloo MA, Parray FQ, Sheikh MA, Khan FA. Clinicopathological profile and surgical results of nonhealing sinuses and fistulous tracts of the head and neck region. *J Oral Maxillofac Surg* **2009**;67(11):2332–6. <https://doi.org/10.1016/j.joms.2008.06.084>
 46. Jibbe A, Tolkachjov SN. Cutaneous odontogenic sinus: an inflammatory mimicker of squamous cell carcinoma and epidermal cysts. *Cutis* **2020**;106(4):196–8. <https://doi.org/10.12788/cutis.0081>

TANTUM VERDE®

QUICK RELIEF FROM PAIN
AND INFLAMMATION IN THE
MOUTH AND THROAT¹

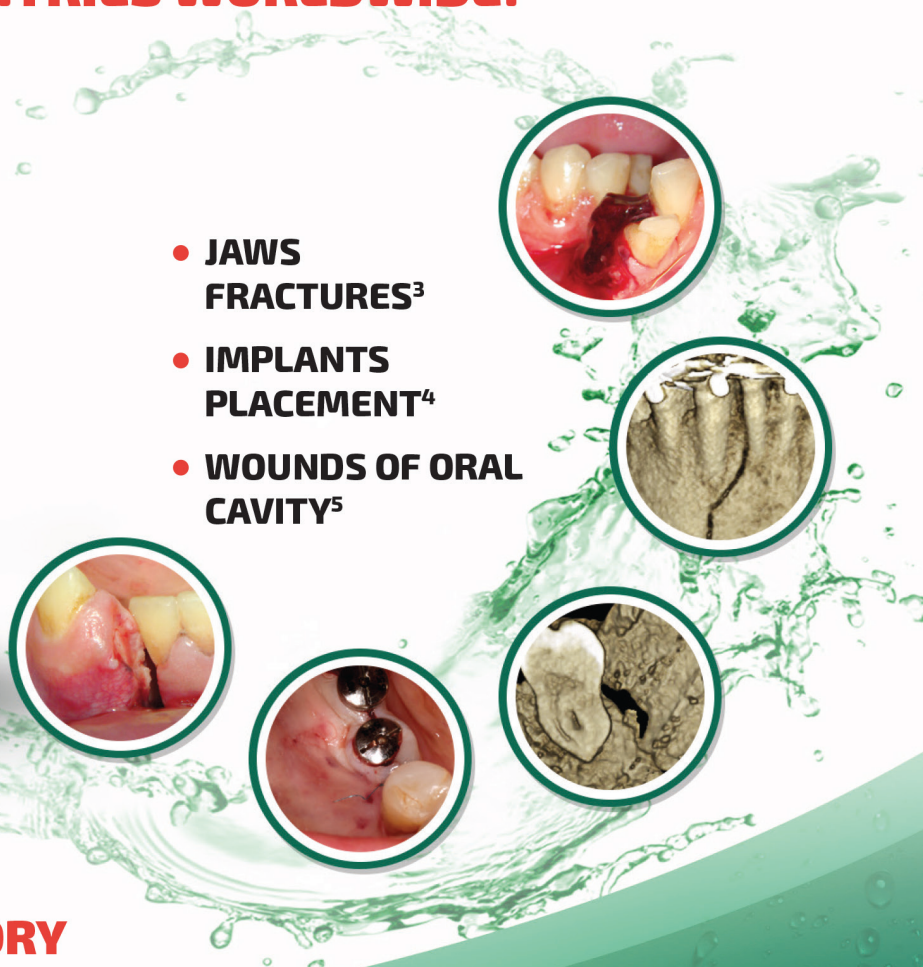**AN INTEGRAL COMPONENT OF THE TREATMENT
OF PAIN AND INFLAMMATION IN THE ORAL CAVITY
IN 60 COUNTRIES WORLDWIDE!²**



Reg. № UA/3920/01/01

**LOCAL ANESTHETIC
AND ANTI-INFLAMMATORY
EFFECT¹**

- **JAWS FRACTURES³**
- **IMPLANTS PLACEMENT⁴**
- **WOUNDS OF ORAL CAVITY⁵**



SUMMARY OF PRODUCT CHARACTERISTICS

NAME OF THE MEDICINAL PRODUCT. Tantum Verde 0.15% mouthwash. **QUALITATIVE AND QUANTITATIVE COMPOSITION.** Each 100 ml contains: active ingredient: benzydamine hydrochloride 0.15 g (equivalent to 0.134 g of benzydamine). **Therapeutic indications.** Treatment of symptoms such as irritation/inflammation including those associated with pain in the oropharyngeal cavity (e.g. gingivitis, stomatitis and pharyngitis), including those resulting from conservative or extractive dental therapy. **Posology and method of administration.** Pour 15 ml of Tantum Verde mouthwash into the measuring cup, 2-3 times per day, using it either at full concentration or diluted. If diluted, add 15 ml of water to the graduated cup. Do not exceed the recommended dosage. **Contraindications.** Hypersensitivity to benzydamine or to any of the excipient. **PHARMACOLOGICAL PROPERTIES. Pharmacodynamic properties.** Pharmacotherapeutic group: Stomatologic drugs: other agents for local oral treatment, ATC code: A01AD02. Clinical studies demonstrate that benzydamine is effective in relieving suffering from localised irritation of the mouth and pharynx. In addition, benzydamine possesses a moderate local anaesthetic effect. **Pharmacokinetic properties. Absorption.** Absorption through the oropharyngeal mucosa is demonstrated by the presence of measurable quantities of benzydamine in human plasma. These levels are insufficient to produce systemic effects. **Distribution.** When applied locally, benzydamine has been shown to accumulate in inflamed tissues where it reaches effective concentrations because of its capacity to penetrate the epithelial lining.

Information about medicines. Information for health care professionals for use in professional activities.

1. Інструкція для медичного застосування лікарського засобу Тантум Верде®, розчин для ротової порожнини, РПН № UA/3920/01/01, затверджено Наказом Міністерства охорони здоров'я України № 636 від 01.10.2015.

2. <http://www.angelini-pharma.com/wps/wcm/connect/com/home/Angelini+Pharma+in+the+world/>

3. Тимофеев А.А. и др. "Особенности гигиены полости рта для профилактики воспалительных осложнений при переломах нижней челюсти". Современная стоматология 2015;1(75):52-8.

4, 4.5. Tymofieiev O.O. et al "Prevention of inflammatory complications upon surgeries in maxillofacial region". J Diagn Treat Oral Maxillofac Pathol. 2017;1:105-12.

Clinical and CT images are courtesy of: Ievgen Fesenko (Department of Oral & Maxillofacial Surgery, PHEI "Kyiv Medical University", Kyiv, Ukraine), Oleg Mastakov ("SCIEDECE—Scientific Center of Dentistry & Ultrasound Surgery" Kyiv, Ukraine)



04119, Kiev, Melnikova str. 83D, of. 404.
Tel.: (044) 538-01-26
Fax: (044) 538-01-27

