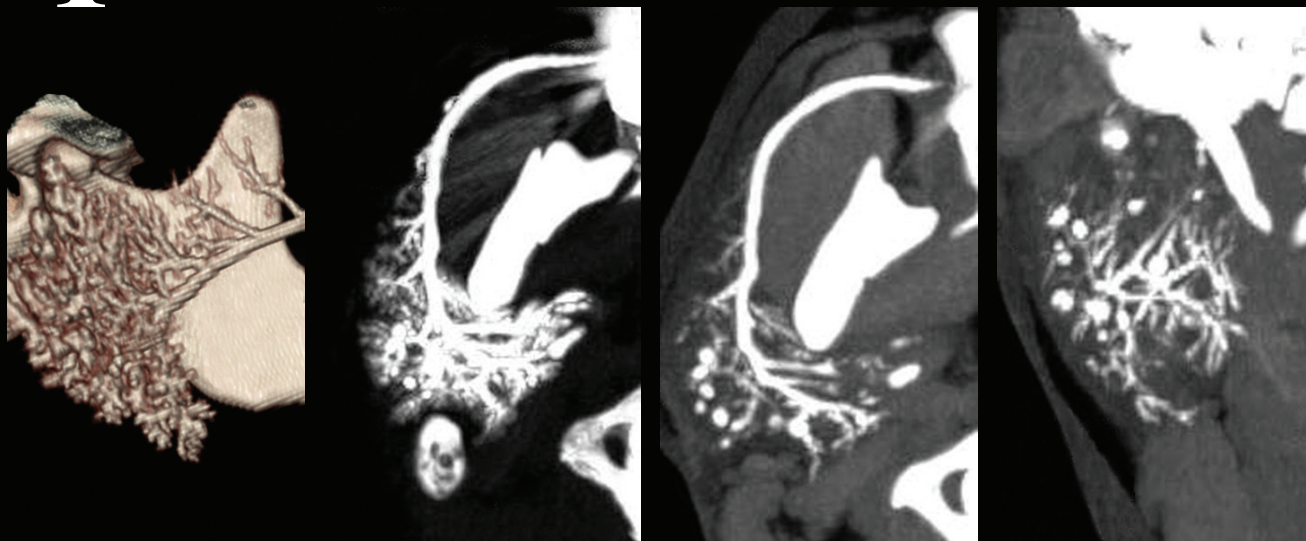


Journal of

# DIAGNOSTICS & TREATMENT

of Oral and Maxillofacial Pathology

3-4<sup>2017</sup>



## Pediatric Surgery

Surgical Correction of Craniosynostosis. A Single Institution`s Outcome Analysis of 70 Patients

## Robotic Surgery

Review of “Transoral Robotic Surgery With Radial Forearm Free Flap Reconstruction: Case Control Analysis”

Official Journal of the Ukrainian Association  
for Maxillofacial and Oral Surgeons





# Goals & Scope

Journal of *Diagnostics & Treatment of Oral & Maxillofacial Pathology* goals to publish the cutting-edge and peer-reviewed articles on work in oral and maxillofacial surgery and neighboring specialties. The journal includes the following topics: implants surgery, head and neck imaging, microvascular and reconstructive surgery, oral and maxillofacial pathology, head and neck surgery/oncology, TMJ lesions/disorders, head and neck trauma, plastic surgery, pharmacology/drugs.

## Official Registered Multilingual Journal Name

Diagnostics and Treatment of  
Oral and Maxillofacial Pathology  
Журнал “Діагностика і лікування оральної  
та щелепно-лицевої патології”  
Журнал “Диагностика и лечение оральной  
и челюстно-лицевой патологии”

Registered in Ministry of Justice (Ukraine)  
Registration Certificate: KB №22251-12151P  
Issued on July 28, 2016  
ISSN 2522-1965 (Online)  
ISSN 2519-2086 (Print)

**1 (3-4) 2017**

**Circulation:** 1,000

**Frequency:** 4 times a year

The *Journal* is included in the list of scientific professional publications of Ukraine, in which the results of dissertation papers can be published for obtaining degrees of doctor and candidate of sciences. Issued on December 28, 2017 (protocol #1714)

## Founders

Shupyk National Medical Academy of Postgraduate Education  
PHEE “Kyiv Medical University”  
OMF Publishing, LLC

## Ukrainian Association for Maxillofacial and Oral Surgeons (UAMOS)

4-a Prof Pidvysotskogo Street, Kyiv 01103, Ukraine.  
Tel., fax: +38 (044) 528 35 17.  
E-mail: [info.uamos@gmail.com](mailto:info.uamos@gmail.com)  
UAMOS webpage: [www.uamos.org](http://www.uamos.org)



© 2017 Shupyk National Medical Academy of Postgraduate Education  
© 2017 PHEE “Kyiv Medical University”  
© 2017 OMF PUBLISHING, LLC

## Citations

CrossRef, Google Scholar

## Members of Journal Development Department

**Al-Makhamid N.** (Ukraine)  
**Beridze B., PhD** (Georgia)  
**Cruz R.L.** (Brazil)  
**Kilipiris E.** (Greece/Slovakia)  
**Kondratiuk B.R.** (Ukraine)  
**Potapova O.A.** (Ukraine)  
**Slobodianiuk A.S.** (Ukraine)  
**Starodub Y.** (New Zealand)

## English Language Editors

**Grishko T.** (United Kingdom)  
**Fesenko I.P., ScD,** Leading Researcher (Ukraine)

## Ukrainian and Russian Language Editor

**Fesenko O.D.** (Ukraine)

## Layout

**Smirnova L.Ie.** (Ukraine)  
[lesya.smirnova@dtjournal.org](mailto:lesya.smirnova@dtjournal.org)

## Scientific Adviser

**Goushcha O., PhD** (USA)

## Legal Adviser

**Vashulenko O.V.** (Ukraine)

## Investments

**Ellet E.** (Ukraine)

## Marketing and Advertising

**Dushyna A.I.** (Ukraine)  
[a.i.dushyna@dtjournal.org](mailto:a.i.dushyna@dtjournal.org)

**Is recommended by** Ukrainian Association for Maxillofacial and Oral Surgeons, Ukrainian Association of Prophylactic and Children’s Stomatology, Ukrainian Association of Pathologists.

## Published by

OMF Publishing, LLC  
13-A Simferopolska Street, office 121, Kyiv, Ukraine, 02096  
Tel: +38 (097) 301 55 92,  
E-mail: [omfpublishing@ukr.net](mailto:omfpublishing@ukr.net)  
Instagram: [omf\\_publishing](https://www.instagram.com/omf_publishing)  
[www.omfpublishing.com](http://www.omfpublishing.com)  
Printed in Ukraine

The articles published in the Journal of *Diagnostics and Treatment of Oral and Maxillofacial Pathology* are distributed under the terms of the Creative Commons Attribution 4.0 International License (<http://creativecommons.org/licenses/by/4.0/>), which permits unrestricted use, distribution, and reproduction in any medium, provided you give appropriate credit to the original author(s) and the source, provide a link to the Creative Commons license, and indicate if changes were made. The Creative Commons Public Domain Dedication waiver (<http://creativecommons.org/publicdomain/zero/1.0/>) applies to the data made available in this article, unless otherwise stated.

SUBSCRIPTION INDEX IN UKRAINE: 60077

# Editorial Board

## Editor-in-Chief

**Tymofieiev O.O.** (Ukraine)

ScD, Prof, Honored Science and Technology Worker of Ukraine. The chair of both the Department for Maxillofacial Surgery at the Shupyk NMAPE and the Department of Oral and Maxillofacial Surgery at the PHEE "Kyiv Medical University". President of Ukrainian Association for Maxillofacial and Oral Surgeons. Director General in the American Biographical Institute (USA). Deputy Director General in the International Biographical Centre (England).

Address: 4-a Prof Pidvysotskogo Street, Kyiv 01103, Ukraine. Tel., fax: +38 (044) 528 35 17.

*tymofoev@gmail.com; @oleksii.tymofieiev*

## Deputy Editor-in-Chief

**Savychuk N.O.**, ScD, Prof (Ukraine)

## Section Editors

### Autoimmune Diseases

**Naishtetik I.M.**, PhD (Ukraine)  
*@irina\_nayshtetik*

### Benign Clinical Conditions

**Tymofieiev O.O.**, ScD, Prof (Ukraine)

### Bone Augmentation Techniques

**Casap N.**, Prof (Israel)

### Craniofacial Deformities

**Richardson S.**, Visit Prof (India)  
*@drsunitrichardson*

### Facial Feminization Surgery

**Keojampa K.** (USA)  
*@keojampamd*

### Head & Neck Oncological Surgery

**Todd Hanna** (USA)  
*@doctor.hanna*

### Head & Neck Radiology

**Ahuja A.T.**, Prof (Hong Kong, SAR)

### Microvascular Surgery

**Fernandes R.P.**, Assoc Prof (USA)

### Mohs Surgery

**Khan M.**, Assis Prof (USA)  
*@khanmisbah6*

### MRONJ

**Hatab N.**, PhD, Assis Prof (UAE)

### Myofascial Pain|Disorders

**Zhehulovych Z.Y.**, ScD, Assoc Prof (Ukraine)

### Orthognathic Surgery

**Brinhole M.** (Brazil)

### Osteosynthesis of Facial Bones

**Kopchak A.V.**, ScD, Prof (Ukraine)

### Pathology

**Tuffaha M.S.**, ScD, Prof (Germany)

### Plastic Surgery

**Fattahi T.**, Assoc Prof (USA)

### Robotic Surgery

**Salman S.O.**, Assis Prof (USA)

### Salivary Glands Diseases

**Lisova I.G.**, ScD, Prof (Ukraine)

### TMJ Lesions|Disorders

**Vasconcelos B.C.**, PhD, Prof (Brazil)

### Trigeminal|Facial Nerve Trauma

**Vesova O.P.**, ScD, Prof (Ukraine)

### Zygoma & Orbital Trauma

**Chepurnii Y.V.**, PhD, Assoc Prof (Ukraine)

## Editorial Board

**Antonyshyn O.M.**, Prof (Canada) · **Araujo M.M.**, Prof (Brazil) · **Bida V.I.**, ScD, Prof (Ukraine) · **Chichua Z.**, ScD, Prof (Georgia) · **Doroshenko O.M.**, ScD, Prof (Ukraine) · **Gichka S.G.**, ScD, Prof (Ukraine) · **Guliuk A.G.**, ScD, Prof (Ukraine) · **Ivnev B.B.**, ScD, Prof (Ukraine) · **Komskyi M.P.**, ScD, Prof (Ukraine) · **Kulbashna Y.A.**, ScD, Prof (Ukraine) · **Lesnukhin V.L.**, PhD, Assoc Prof (Sweden) · **Lutskaia I.K.**, ScD, Prof (Belorussia) · **Maksymcha S.V.**, PhD, Assoc Prof (Ukraine) · **Medvediev V.E.**, ScD, Prof, Honored Science & Technology Worker of Ukraine (Ukraine) · **Pavlenko O.V.**, ScD, Prof, Honored Science & Technology Worker of Ukraine (Ukraine) · **Potapchuk A.M.**, ScD, Prof, Honored Science & Technology Worker of Ukraine (Ukraine) · **Protsyk V.S.**, ScD, Prof (Ukraine) · **Ragimov C.R.**, ScD, Prof (Azerbaijan) · **Ruslin M.** (Indonesia) · **Savychuk O.V.**, ScD, Prof (Ukraine) · **Shtai T.M.**, Prof (Jordan) · **Stanko P.**, PhD, Prof (Slovakia) · **Szabó G.**, Prof Emeritus (Hungary) · **Tkachenko P.I.**, ScD, Prof (Ukraine) · **Tymofieiev O.O.**, ScD, Assoc Prof (Ukraine) · **Ushko N.O.**, PhD, Assoc Prof (Ukraine) · **Vares Y.E.**, ScD, Prof (Ukraine) · **Voronenko Y.V.**, Academician of NAMS, ScD, Prof, Honored Science & Technology Worker of Ukraine (Ukraine) · **Yakovenko L.M.**, ScD, Prof (Ukraine) · **Zaritska V.I.**, PhD, Assoc Prof (Ukraine) · **Zhang C.P.**, Prof (China) · **Zhezzini A.A.**, Prof (Lebanon)

## Web & Social Media Editor

**Monteiro J.L.** (Brazil)  
*j.l.monteiro@dtjournal.org*  
*@joaoluizmonteiro*

## Review of Events

**Khadem A.A.** (Ukraine)  
*ariana.khadem@dtjournal.org*  
*@aria\_ni*

## Managing Editor

**Fesenko Ie.I.**, Assis Prof (Ukraine)  
*i.i.fesenko@dtjournal.org*  
*@dr\_eugenfesenko*

## Statistical Editor

**Petasyuk G.A.**, ScD, Leading Researcher (Ukraine)

## Assistant Managing Editors

**Szmirnova I.** (Hungary)  
**Dushyn I.I.** (Canada)  
**Popovych K.O.** (Ukraine)

## Books Scan (Radiology)

**Babkina T.M.**, ScD, Prof (Ukraine)

# Content

of the Volume 1 (Issue 3-4) 2017

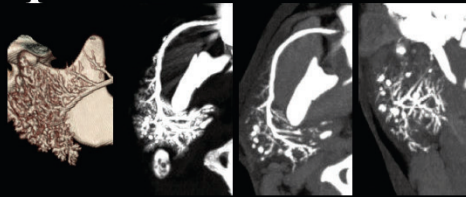
- 123 **Editorial**  
**Clash of Videos in the Cutting-Edge Medical Publications**  
Tymofieiev OO
- 130 **Review of “Transoral Robotic Surgery With Radial Forearm Free Flap Reconstruction: Case Control Analysis” by Biron VL, O’Connell DA, Barber B, et al**  
Salman SO
- 132 **Review of “Cartilage Framework Reconstruction After Resection of Thyroid Cartilage Chondrosarcoma: A Case Report” by Navach V, Chu F, Cattaneo A, et al**  
Todd Hanna
- 134 **Review of “A Case of Bisphosphonate-Related Osteonecrosis of the Jaw With a Particularly Unfavourable Course: A Case Report” by Viviano M, Addamo A, Cocca S**  
Hatab N
- 136 **Review of the Book “Essentials Radiology for Medical Students, Interns and Residents” by Ahuja AT, Antonio GE, Nung RC, et al**  
Medvediev VE
- 137 **Surgical Correction of Craniosynostosis. A Single Institution’s Outcome Analysis of 70 Patients**  
Kilipiris EG, Horn F, Petrik M, Kabat M, Trnka J, Stanko P
- 147 **Management of Alveolar Osteitis in Dental Practice: A Literature Review**  
Hatab N, Yahya J, Alqulaihi S
- 156 **Assessment of the Relationship of the Frankfort Horizontal Plane and the Orbitomeatal Line With Attainment of the Natural Head Position**  
Cruz RLA, Gasperini G
- 164 **Correction of Lysozyme Content in Mixed Saliva in Patients With Jaw Ameloblastomas**  
Ushko NO
- 168 **The Integral Indicator of the Evaluation of the General State Severity in Patients With Inflammatory Processes of the Mandibular Bone According to the Data of Peripheral Clinical Blood Analysis**  
Komykyi MP, Romanenko OH, Buzoveria OA, Makohon MV
- 175 **Question of the Etiology of Malignant Neoplasms**  
Tymofieiev OO, Tymofieiev OO, Ushko NO, Yarifa MO
- 183 **Prospects of Dental Implants Placement in Cases of Periodontal Disease**  
Tymofieiev OO, Yarifa MO
- A6 **Review of Events**
- A9 **Future Events**
- A10 **Submission of Articles**

VOLUME 1 • ISSUE 3-4 • 2017

ISSN 2519-2088

Journal of  
**DIAGNOSTICS  
& TREATMENT**  
of Oral and Maxillofacial Pathology

**3-4** 2017



**Pediatric Surgery**

Surgical Correction of Craniosynostosis. A Single Institution's Outcome Analysis of 70 Patients

**Robotic Surgery**

Review of "Transoral Robotic Surgery With Radial Forearm Free Flap Reconstruction: Case Control Analysis"

Official Journal of the Ukrainian Association  
for Maxillofacial and Oral Surgeons

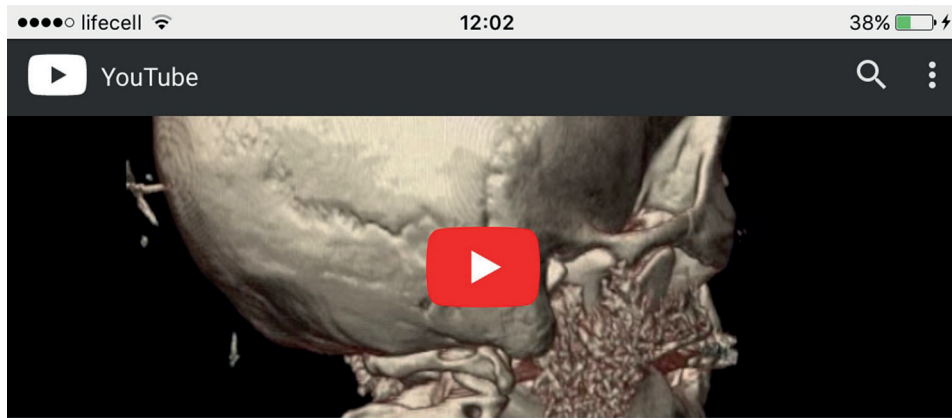


[www.djournal.org](http://www.djournal.org)

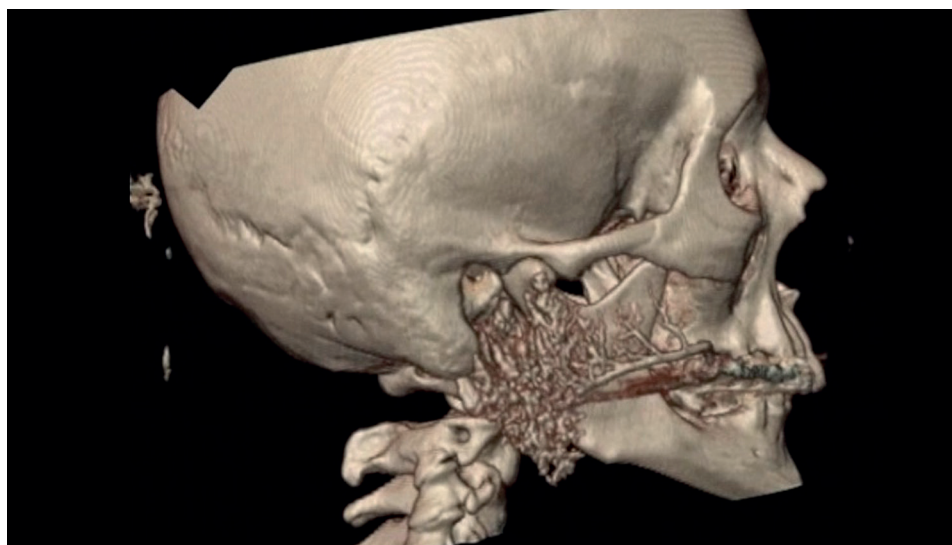
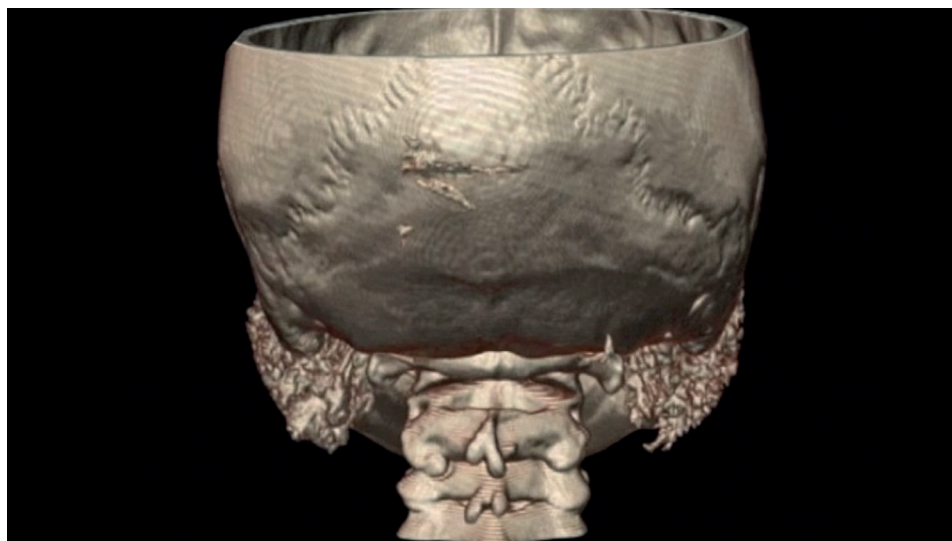
Cover images (Multidetector CT sialogram scans of the right parotid gland of 39-year-old lady with chronic recurrent parotitis. Noted "pruning of the tree" sign caused by acinar destruction) are courtesy of:  
*Dr. Tetiana O. Shamova (Diagnostic Center "Asklepi", Kyiv, Ukraine),  
Ievgen I. Fesenko, Assis Prof (Department of Oral & Maxillofacial Surgery, PHEE "Kyiv Medical University", Kyiv, Ukraine),  
Lesia Ie. Smirnova (Kyiv, Ukraine)*



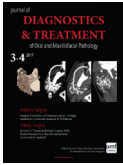3D CT cine loop  
of Sialogram.  
Example of  
opening  
(Fig 1) is on the  
next page



Dx: chronic recurrent right side parotitis. Vol 1 Issue #3-4.  
dtjournal.org. Description included  
OME Publishing LLC 14 days



**FIGURE 1.** Cropped smartphone consecutive screenshots (A-C) from the YouTube channel. Case from the cover images and is linked with previous page QR code.



Editorial

# Clash of Videos in the Cutting-Edge Medical Publications

Oleksii O. Tymofieiev\*

Chair, Department of Maxillofacial Surgery, Shupyk National Medical Academy of Postgraduate Education, Kyiv, Ukraine (Prof, ScD)

ABOUT ARTICLE

Article history:

Paper received 2 December 2017

Accepted 4 December 2017

Available online 28 December 2017

*“The customers were no longer looking purely for information, but also ‘actionable’ information to tell them what to do”*

N. McKinstry, CEO Wolters Kluwer [1]

## Introduction

Recently the video becomes deeply integrated into scientific articles of printed and electronic forms of peer-reviewed journals and textbooks. The journals at the fields of oral and maxillofacial surgery, head and neck surgery are among leading ones [2, 3]. The goal of this Editorial is to illustrate how the process of video integration is possible on the example of peer-reviewed cutting-edge scientific publications.

First we want to highlight the most prominent, #1 Journal in the field of Plastic Surgery – *Plastic and Reconstructive Surgery*® (PRS). PRS is a peer-reviewed medical journal and the official publication of the American Society of Plastic Surgeons ([www.plasticsurgery.org](http://www.plasticsurgery.org)). Its impact Factor is incredibly high – 3.784. Being the Journal dedicated to practical part of medicine its readers are the first among other medical specialties who needed the precise understanding how surgical techniques should be performed. Every article with video content marked in PRS with special symbol and word ‘VIDEO+’ (Fig 1).



## The Six-Step Lower Blepharoplasty: Using Fractionated Fat to Enhance Blending of the Lid-Cheek Junction

Ronnie A. Pezeshk, M.D.  
David A. Sieber, M.D.  
Rod J. Rohrich, M.D.  
Dallas, Texas



**Summary:** Lower lid blepharoplasty is one of the most complex procedures performed by plastic surgeons and may cause significant long-term sequelae, including inadequate aesthetic outcomes if not performed with a thorough understanding of anatomy and proper technique. The authors’ practice is consistently evolving to deliver the highest quality results for their patients. The purpose of this article is to introduce an additional sixth step to the lower lid blepharoplasty procedure involving the targeted injection of fractionated fat to better blend the lid-cheek junction. This added step will enhance overall facial rejuvenation, is reproducible, and will provide patients with exceptional outcomes. (*Plast. Reconstr. Surg.* 139: 1381, 2017.)

The evolution of the lower lid blepharoplasty Superficial and deep fat compartments are

**FIGURE 1.** Cropped screenshot from the title of article Pezeshk RA, Sieber DA, Rohrich RJ. The six-step lower blepharoplasty: using fractionated fat to enhance blending of the lid-cheek junction. *Plast Reconstr Surg* 2017;139(6):1381–3 [1] ([www.journals.lww.com/plasreconsurg/pages/default.aspx](http://www.journals.lww.com/plasreconsurg/pages/default.aspx)). Existence of video in that article marked by ‘VIDEO+’ (arrow) and red symbol (curved arrow)

\* Corresponding author. Department of Maxillofacial Surgery, Shupyk National Medical Academy of Postgraduate Education, 4-a Pivvysotskogo Street, Kyiv 01103, Ukraine. Tel., fax: +38 (044) 528 35 17. E-mail address: [tymofeev@gmail.com](mailto:tymofeev@gmail.com) (O.O. Tymofieiev) Instagram: [oleksii.tymofieiev](https://www.instagram.com/oleksii.tymofieiev); [dt\\_journal](https://www.instagram.com/dt_journal)



And has an obligatory guide in a box (Fig 2) how to use a link for a video: “Video Plus content is available for this article. Direct uniform resource locator (URL) citations appear in the printed text; simply type the URL address into any Web

browser to access this content. Clickable links to the material are provided in the HTML text of this article on the *Journal’s* website ([www.PRSJournal.com](http://www.PRSJournal.com))” [1]. Each page can contain from one to three/four videos (Fig 3 and 4) [2, 3].

be prevented with a thorough appreciation of the delicate peri-orbital anatomy and sound technical expertise.<sup>1-5</sup> For the past 3 years, the senior author (R.J.R.) has incorporated an additional sixth step to the lower blepharoplasty intended to better blend the lower lid and cheek junction with fractionated fat consisting of stromal cells, devoid of intact adipocytes.<sup>6</sup> This article and accompanying video provide a better understanding of how to blend the lower eyelid–cheek junction in a safe and reproducible manner.

single side-hole cannula approximately one finger-breadth below the orbital rim. (See Video, Supplemental Digital Content 1, which demonstrates the six-step lower blepharoplasty, available in the “Related Videos” section of the full-text article on PRSJournal.com or, for Ovid users, at <http://links.lww.com/PRS/C174>.) This corrects malar deflation, uneven texture, and the inverted-V deformity seen with deep malar fat pad atrophy.<sup>11</sup> Overcorrection is not necessary. Volumization and contouring of the deep cheek fat compartment plays an integral

**STEP 1: DEEP MALAR FAT COMPARTMENT AUGMENTATION**

Detailed understanding of the complexities in superficial and deep fat compartments from previous cadaveric investigations, particularly in the cheek, have allowed plastic surgeons to combat facial aging by reversing the deflation process.<sup>7,8</sup>

**Disclosure:** *The authors have no financial interests in this research project or in any of the techniques or equipment used in this study. Rod J. Rohrich, M.D., receives instrument royalties from Eriem Surgical, Inc., and book royalties from Thieme Medical Publishing. No funding was received for this article.*

Video Plus content is available for this article. Direct URL citations appear in the printed text; simply type the URL address into any Web browser to access this content. Clickable links to the material are provided in the HTML text of this article on the *Journal’s* website ([www.PRSJournal.com](http://www.PRSJournal.com)).

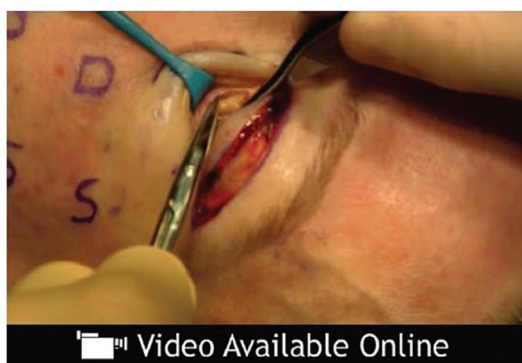*From the Department of Plastic Surgery, University of Texas Southwestern Medical Center; and the Dallas Plastic Surgery Institute.  
Received for publication February 2, 2016; accepted August 31, 2016.  
Copyright © 2017 by the American Society of Plastic Surgeons  
DOI: 10.1097/PRS.0000000000003398*

[www.PRSJournal.com](http://www.PRSJournal.com)

1381

**FIGURE 2.** Cropped screenshot from the 1<sup>st</sup> page of article Pezeshk *et al*, 2017 [1] ([www.journals.lww.com/plasreconsurg/pages/default.aspx](http://www.journals.lww.com/plasreconsurg/pages/default.aspx)). Each article with video content has a guide in a box (curved arrow) how to use the video link noted in the text (red marks).

Plastic and Reconstructive Surgery • June 2017



**Video.** Supplemental Digital Content 1, which demonstrates the six-step lower blepharoplasty, is available in the “Related Videos” section of the full-text article on PRSJournal.com or, for Ovid users, at <http://links.lww.com/PRS/C174>.

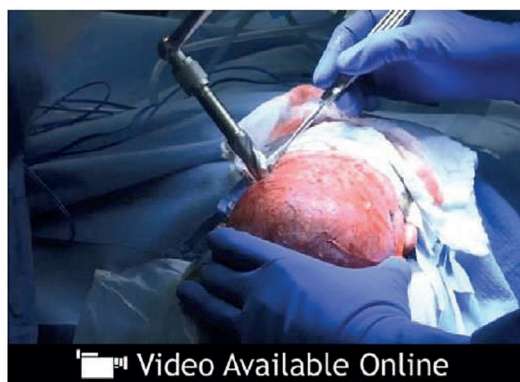role in improvement of the tear trough deformity and creates a base to further refine the lid-cheek junction.

blunt manner through the supraperiosteal plane. The preoperative tear trough markings will guide the surgeon in determining where and how much

**FIGURE 3.** Cropped screenshot from the page with video image of article Pezeshk *et al*, 2017 [1] ([www.journals.lww.com/plasreconsurg/pages/default.aspx](http://www.journals.lww.com/plasreconsurg/pages/default.aspx)).



**Video 1.** Supplemental Digital Content 1, which depicts performance of posterior cranial vault distraction on a skull model. This video is available in the “Related Videos” section of the full-text article on PRSJournals.com or at <http://links.lww.com/PRS/C202>.



**Video 2.** Supplemental Digital Content 2, which depicts performance of posterior cranial vault distraction on an infant with syndromic craniosynostosis. This video is available in the “Related Videos” section of the full-text article on PRSJournals.com or at <http://links.lww.com/PRS/C203>.

provide objective metrics by which to evaluate their conclusions.<sup>31</sup>

Even when patients have had successful

step osteotomies and intercalated bone grafts. The ability to delay fronto-orbital advancement

**FIGURE 4.** Cropped screenshot from the page with several video at page of article Taylor JA, Bartlett SP. What’s new in syndromic craniosynostosis surgery? *Plast Reconstr Surg* 2017;140:82e [2] ([www.journals.lww.com/plasreconsurg/pages/default.aspx](http://www.journals.lww.com/plasreconsurg/pages/default.aspx)).

Other peer-reviewed Journals like *Journal of Oral and Maxillofacial Surgery* [4]. ([www.joms.org](http://www.joms.org)) gives another type of video integration into articles. The *Journal* is published monthly on behalf of the American Association of Oral and Maxillofacial Surgeons ([www.aaoms.org](http://www.aaoms.org)). The *Journals’* Impact Factor is 1.916. For example, at the article of Qaisi *et al*, 2016 [4] we can see a different type of video integration. They place only word ‘video’ and its number near some notion about Figure and print the word ‘video’ in other color. For example: (Fig 5C, video 1) [4]. And the readers can go to a video being at the website of the *Journal*, but it is impossible to go and watch that movie reading PDF file.

Secondly we move to the videos which are integrated into the textbooks. Initially the publishing houses and authors added a CD/DVD to their books (Moy and Fincher, 2006) [5]. So the video content is revolutionized precisely into book pages. As we can see in the *Orthognathic Surgery: principles and practice* (Posnick, 2014) [6], in which the notes about video of some surgical technique are placed into the book chapters. For example in Chapter *Sequence of Orthognathic Procedures: Step-by-Step Approach* the notion about video content is indicated in text in the next manner – (Video 6 and 7) with an obligatory label of video [6]. Totally the 2 Volume Set textbook of Dr. Posnick consist of more than 40 videos. And the storage of the videos is at the textbook website of the publishing house ([www.elsevierorthognathicsurgery.com](http://www.elsevierorthognathicsurgery.com)). Every reader who’s bought the book has an access to that collection of video via unique code noted in each book.

An absolutely new smart way how to integrate video into publications offers a team of radiologist from Hong Kong (SAR) China (Ahuja *et al*; 2017) [7]. Their new

textbook *Essential Radiology for Students, Interns and Residents* contains 1100 unique QR-codes (Figs 5-7), quick scan of which via smartphone gives the readers a possibility in several clicks of smartphone (opening a QR-code reader and scanning) watching cine loops (video).

TERMINOLOGY

*Cine film* literally means “moving” film; deriving from the Greek “kine” for motion; it also has roots in the Anglo-French word ‘cinematograph’, meaning *moving picture* [8].

Loop (noun) a series, or process, the end of which is connected to the beginning [9].

A cine loop (synonyms: cine-loop, cineloop) is a period of images (CT, MRI scans, ultrasound images), stored digitally as a sequence of individual frames in one movie [9]. According to Ahuja *et al*, 2017 [7] each cine loop contains consecutive images covering the area scanned during the examination. In many cases, the cine loops are of scans in different planes (sagittal, coronal or oblique), in different phases of contrast enhancement (pre-contrast, post-contrast arterial/ venous/ equilibrium/ delayed), and for MRI in different sequences (T1W/ T2/ PD/ DWI etc.)

QR code (abbreviated from Quick Response Code) is the trademark for a type of matrix barcode (or two-dimensional barcode) first designed for the automotive industry in Japan by Denso Wave in 1994 [10]. Denso Wave is a subsidiary that produces automatic identification products (bar-code readers and related products), industrial robots and programmable logic controllers [11].

The QR codes can be scanned (read) via QR Code

Reader & Barcode Scanner (for iOS users), QR Code Reader (for Android users) etc. Nowadays the QR codes can be easily generated by anyone. And it will take only a several seconds. For that purpose the person can use free

online generator (for example [www.goqr.me](http://www.goqr.me), etc.) or QR code generator software. And nowadays the QR codes can be generated for Web links (URLs), texts, vcards, geolocation, etc.

### 3 Nasopharyngeal Carcinoma

#### Introduction

- Nasopharyngeal carcinoma (NPC) is a common seen head and neck cancers, particularly in southeast Asia.
- Clinical presentations include:
  - Nasal symptoms: nasal obstruction, epistaxis
  - Hearing: hearing loss, otitis media
  - Neck swelling due to cervical nodal metastasis
  - Late: visual impairment, cranial nerve palsy (due to intracranial or orbital extension)

#### Imaging Features

- MRI
  - Soft tissue mass centered at the nasopharynx
  - Superior extension: skull base (Fig 3e) and intracranial (Fig 3f)
  - Anterior extension: nasal cavity (Fig 3g), Eustachian's tube (otomastoid effusion)
  - Lateral extension: parapharyngeal space (Fig 3h), carotid sheath,
  - Posterior extension: prevertebral muscle (Fig 3g)
  - Inferior extension: oropharynx (Fig 3h)
  - Cervical nodal metastases: retropharyngeal, jugular chain, posterior triangle (Fig 3i)

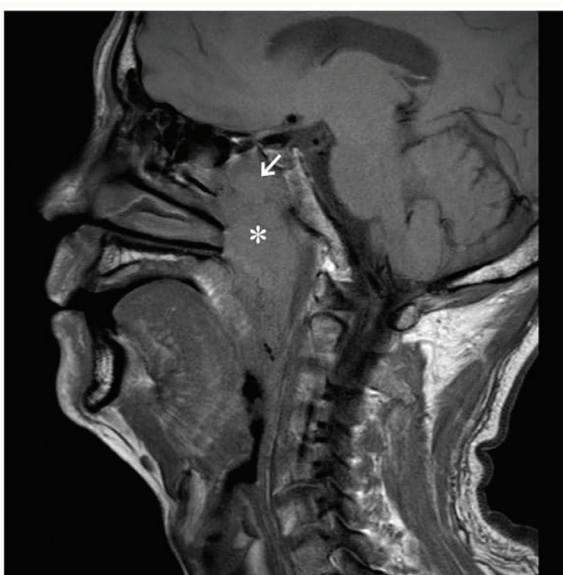


Fig 3e Sagittal T1 W MRI shows large nasopharyngeal carcinoma (\*) invading the sphenoid sinus (→).

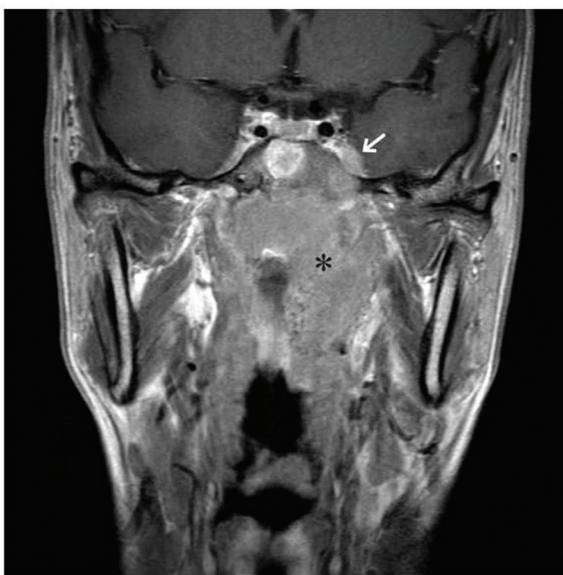


Fig 3f Post-Gd Coronal T1 WFS MRI shows large nasopharyngeal carcinoma (\*). Note the small intracranial component the left cavernous sinus (→).



Otomastoid Effusion



Intracranial Extension

## Vascular Malformation 6

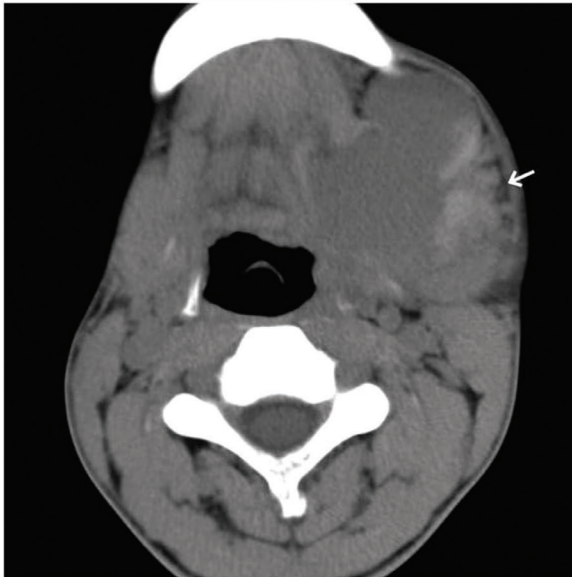


Fig 6g Axial NECT (same patient as Fig 6f) shows internal hyperdense component (→), suggestive of previous hemorrhage. Overall features indicate a lymphatic malformation with recent hemorrhage.

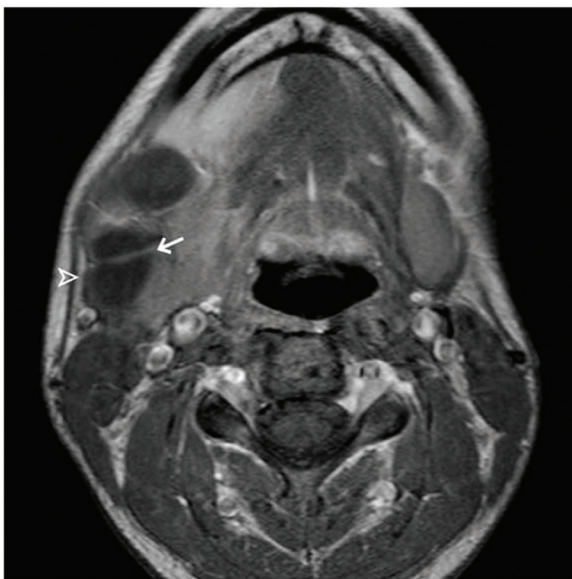


Fig 6h Axial Post-Gd T1 W MRI shows an uncomplicated lymphatic malformation in the right submandibular region (Δ). Note the thin enhancing septa (→).

- Common in young adults
- Common locations: oral cavity and tongue (Figs 6a-d), orbit (Fig 6e), face, intramuscular (masseter, digastric, sternocleidomastoid)
- Treatment: percutaneous sclerotherapy, surgery

### 2. Lymphatic malformation (LM) (Figs 6f-i)

- Slow flow vascular malformation
- Comprising of lymphatic channels
- Transpatial / multispatial characteristic
- Unilocular / multilocular cystic lesion insinuating between adjacent structures
- **Uncomplicated LM**: thin non-enhancing wall and septations, no vascularity
- **Hemorrhagic LM**: fluid-fluid level, hyperdense component on CT
- **Infected LM**: thick enhancing wall and septation with mass effect
- Common locations: submandibular (Figs 6f-h) and posterior triangle, axilla
- Treatment: percutaneous sclerotherapy, surgery

### 3. Arteriovenous malformation (AVM) (Fig 6j)

- High flow vascular malformation
- Comprises of feeding arteries, nidus and draining veins
- US/CT: mass lesion with serpiginous vessels. Arterialised flow void can be seen on spectral Doppler ultrasound. Phleboliths / cystic space unusual.



Hemorrhagic LM

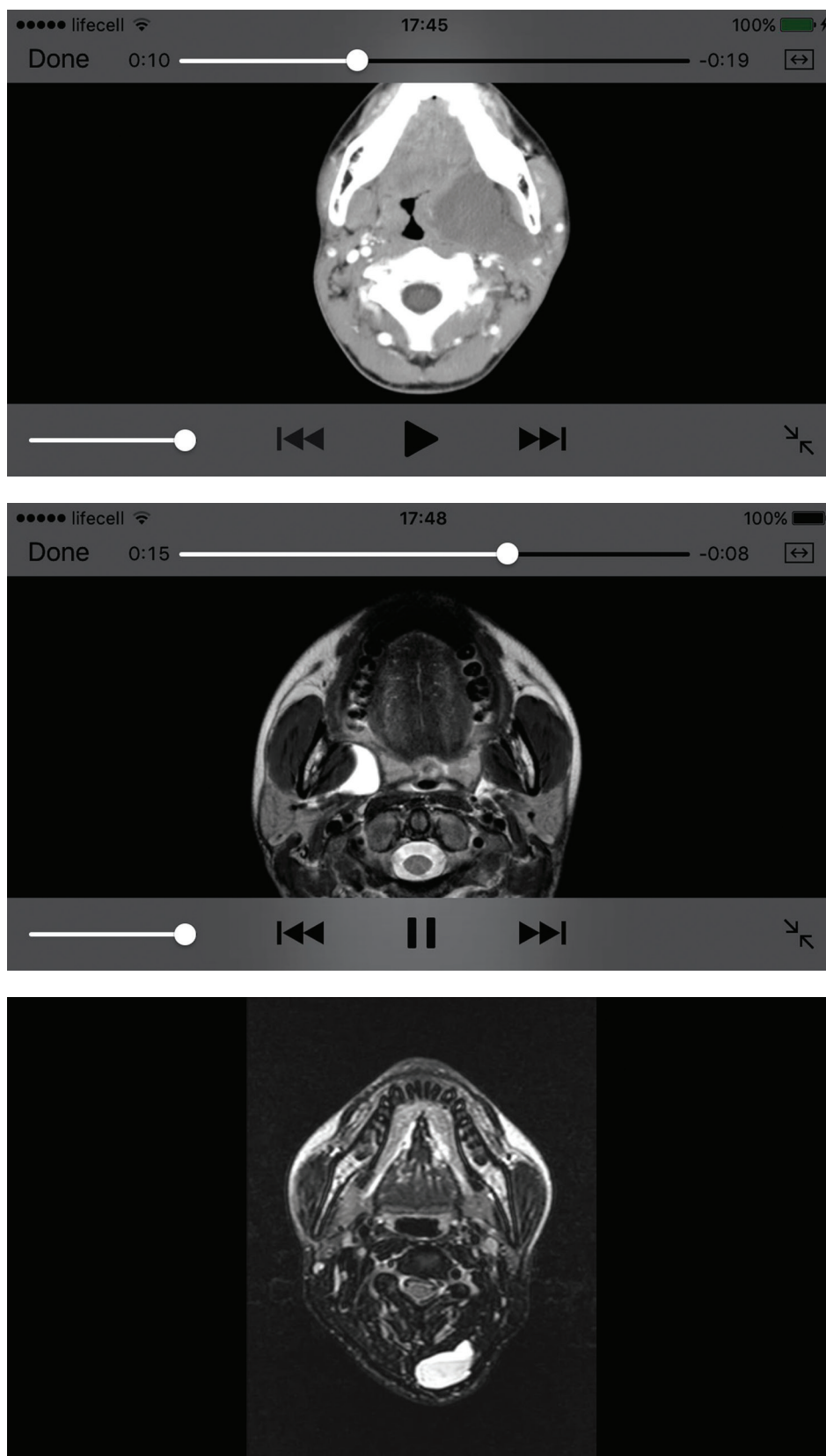


Uncomplicated LM



Occipital LM

FIGURE 6. Cropped screenshot from the book *Essential Radiology for Students, Interns and Residents* (Ahuja et al, 2017) [7] shows the readers an example of scientific publication with integrated cine loops via QR-codes on the cases of lymphatic malformations (hemorrhagic, uncomplicated, and occipital).



**FIGURE 7.** Cropped smartphone consecutive screenshots from the YouTube channel (A-C) of the textbook *Essential Radiology for Students, Interns and Residents* (Ahuja *et al*, 2017) shows the readers a place of video storage with which the QR-codes are connected [7]. Thus allowing for the book or journal readers to get a quick access (in three touches at the smartphone: open a QR-code reader, scan the necessary QR-code and open a video at the browser the user like). Cine loops from **Figure 6** shows: hemorrhagic lymphatic malformation (A), uncomplicated lymphatic malformation (B), and occipital lymphatic malformation (C).

## STORAGE OF VIDEOS/CINE LOOPS

The journal or textbook publishers can choose different place for storage their videos/cine loops. The choice can differ from the website of the publishing house, journal to YouTube channel or even page of any user of some social network (Instagram, Facebook, etc.) [12].

## CONCLUSIONS

Analysis of the whole spectrum of peer-reviewed scientific publications shows first that an urgent need among both readers and practitioners (surgeons, radiologists) for integration of videos/cine loops into papers and books exists. Second, the videos/cine loops should be integrated into print and electronic versions of journals via combination of usage web-links (for the online users or PDF readers) and QR codes. This approach from one hand allows the readers of print versions to watch cine loops/videos via quick scan of QR code. And on other hand the users of online/electronic version of the publication will not lose time with smartphones for scanning QR codes. All that will be needed is just click at the web link. But for the companies that don't want to share electronic copies of the book is more reasonable to use only QR codes.

Nancy McKinstry, CEO Wolters Kluwer, in Management Scope Interview notes that "the customers were no longer looking purely for information, but also 'actionable' information to tell them what to do" [1]. And those words are the holy truth. The role of this 'actionable' information in publications is constantly increasing. And maybe the scientific publication which gives us the best combination of text-picture-video material can win the battle for readers and authors attention.

## Acknowledgments

*The author would like to thank Rod J. Rohrich (PRS, PRS Global Open, Editor-in-Chief, USA), Aaron G. Weinstein (PRS, PRS Global Open, Senior Managing Editor, USA), Theresa Kircher (Wolters Kluwer Permissions Team, USA), Andrew Richardson (Wolters Kluwer VP of Business Development - Health Learning Research & Practice Division), Mohammed Qaisi (Assis Prof, Department of Oral & Maxillofacial Surgery, USA) for guidance and help in getting permissions. Also wish to thank Anil T. Ahuja (Prof, Hong Kong, SAR), Eric Law (Hong Kong, SAR)*

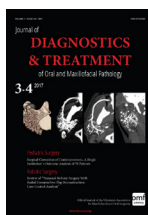
*for inspiration and Ievgen I. Fesenko (Managing Editor, Ukraine) for assistance in editing this Editorial.*

## Publication Permissions

Written permissions of Wolters Kluwer and OMF Publishing, LLC were obtained to publish the cropped images.

## References

1. Van Weegen J, Grootengel P. Nancy McKinstry digitizes Wolters Kluwer [document on the internet]; **2017** September 10 [cited 2017 Dec 01]. Available from: <https://managementscope.nl/magazine/artikel/1067-nancy-mckinstry-digitalisering>
2. Pezeshk RA, Sieber DA, Rohrich RJ. The six-step lower blepharoplasty: using fractionated fat to enhance blending of the lid-cheek junction. *Plast Reconstr Surg* **2017**;139(6):1381–3.
3. Taylor JA, Bartlett SP. What's new in syndromic craniosynostosis surgery? *Plast Reconstr Surg* **2017**;140:82e.
4. Qaisi M, Kolodney H, Swedenburg G, Chandran R, Caloss R. Fibula jaw in a day: state of the art in maxillofacial reconstruction. *J Oral Maxillofac Surg* **2016**;74(6):1284.e1–1284.e15.
5. Moy RL, Fincher EF. Procedures in cosmetic dermatology series: blepharoplasty: textbook with DVD. 1st ed. Saunders; **2006**.
6. Posnick JC. Orthognathic Surgery: principles and practice. 1st ed. St. Louis, Missouri: Elsevier Saunders; **2014**.
7. Wong SS, Dai EY, Tang EW, Ahuja AT. Essential radiology for medical students, interns and residents. In: Ahuja AT, Antonio GE, Nung RC, Sitt JC, Yu JW, Wong SS, Dai EY, Law EK, Tang EW, Yuen BT, editors. OMF Publishing, **2017**: 1–50.
8. Cine film [document on the internet]; **2016** April 14 [cited 2017 Dec 01]. Available from: [https://en.wikipedia.org/wiki/Cine\\_film](https://en.wikipedia.org/wiki/Cine_film).
9. Dormagen JB, Gaarder M, Drolsum A. Standardized cine-loop documentation in abdominal ultrasound facilitates offline image interpretation. *Acta Radiol* **2015**;56(1):3–9.
10. QR code [document on the internet]; **2017** September 10 [cited 2017 Dec 01]. Available from: [https://en.wikipedia.org/wiki/QR\\_code](https://en.wikipedia.org/wiki/QR_code).
11. Denso [document on the internet]; **2017** August 08 [cited 2017 Dec 01]. Available from: [https://en.wikipedia.org/wiki/Denso#Denso\\_Wave](https://en.wikipedia.org/wiki/Denso#Denso_Wave).
12. Tymofieiev OO. Swimming in the oceans of media technologies. *J Diagn Treat Oral Maxillofac Pathol* **2017**;1:57–8.



## PAPERS SCAN

Review of “Transoral Robotic Surgery  
With Radial Forearm Free Flap  
Reconstruction: Case Control Analysis”  
by Biron VL, O’Connell DA, Barber B,  
Clark JM, Andrews C, Jeffery CC, Côté DW,  
Harris J, Seikaly H in *Journal of  
Otolaryngology – Head and Neck Surgery*  
2017;46:20

**S**urgical management of large oropharyngeal malignancies has always been a challenging procedure due to the risk of significant morbidity. Traditional approaches to surgical management of these tumors involved a lip-splitting mandibulotomy to completely excise these complex lesions and appropriately reconstruct the defects.

Biron *et al* present an interesting and innovative approach (Fig 1) to managing these malignancies surgically, with a less morbid approach. The use of robotic surgery in oral and maxillofacial, and head and neck surgery, continues to increase. Biron *et al* compared the outcomes of patients with oropharyngeal squamous cell carcinoma, 18 of whom were treated with transoral robotic surgery (TORS) resection and reconstruction with a radial forearm free flap

(RFFF), and 39 patients being treated with a lip-splitting mandibulotomy and RFFF reconstruction. Their results demonstrated that addressing these lesions with TORS led to a shorter hospital stay post-operatively (14.4 days vs. 19.7 days), but no significant differences in regards to post-operative complications or morbidity. It is important to note that the RFFF inset was not performed with TORS, but with direct visualization via the neck dissection incision and lateral pharyngotomy approach.

This study describes another treatment modality for oropharyngeal malignancies, and demonstrates the primary benefit of decreased hospital length of stay post-operatively. The use of TORS in head and neck surgery also affords us the ability to appropriately treat patients with a less morbid approach.

Section Editor – Robotic Surgery  
Salam O. Salman, MD, DDS  
Assistant Professor  
Jacksonville, FL, USA  
[salam.salman@jax.ufl.edu](mailto:salam.salman@jax.ufl.edu)



Full Article  
Biron et al

**Table 1** Matched demographic, exposure and tumor characteristics of patients with oropharyngeal squamous cell carcinoma in this study

Variable	TORS (n = 18)	Mandibulotomy (n = 29)	P
Age, years	59.6	57.6	0.69
Sex, % M	66.7	80.7	0.31
Smoking status (%)	10 (55.5)	17 (58.6)	0.67
P16 positivity (%)	16 (88.9)	25 (93.1)	0.61
Tumor subsite (%)			
Tonsil	13 (72.2)	16 (55.2)	0.36
Base of Tongue	5 (27.8)	13 (44.8)	
Pathologic stage (%)			
T1	5 (27.8)	7 (26.9)	0.96
T2	10 (55.5)	17 (58.6)	
T3	3 (16.7)	5 (19.2)	
N0	1 (5.6)	1 (3.8)	
N1	1 (5.6)	3 (11.5)	0.68
N2	13 (72.2)	23 (79.3)	
N3	3 (16.7)	2 (7.7)	

which did not occur in TORS patients. There were no free flap failures in either group. No intraoperative or perioperative fatalities occurred.

**Cost comparison**

Comparison of cost estimates for TORS vs mandibulotomy approaches showed reduced cost of surgical instruments, physician billings and hospital stay associated with TORS (Table 4). Overall, the TORS approach is estimated to result in a cost reduction of \$ 6409.98 per case.

**Discussion**

TORS has been mainly used for the resection of small (T1 or T2) OPSCCs with the resulting defect left to heal

**Table 2** Outcomes of oropharyngeal cancer patients treated with TORS vs mandibulotomy and radial forearm free flap reconstruction

Outcome	TORS	Mandibulotomy	P
Operative time	15.0	15.5	0.77
LOHS (days)	14.4	19.7	0.03
Positive margins (%)	0	6.9	0.52
ICU stay (days)	1.9	2.0	0.76
Decannulation (days)	7.5	9.1	0.97
G-tube 1 month (%) <sup>a</sup>	16.6	13.7	0.68
G-tube 12 months (%) <sup>b</sup>	5.5	13.7	0.50

ICU intensive care unit; LOHS length of hospital stay  
<sup>a</sup>G-tube dependency and readmissions to hospital reported for up to 30 days post-discharge  
<sup>b</sup>1 year g-tube rates not available for all given the study end date (July 2016) but is available to all patients who did receive a g-tube

**Table 3** Adverse events in patients receiving TORS vs mandibulotomy and radial forearm free flap reconstruction

Event	TORS	Mandibulotomy
Hematoma	1	1
Abscess	2	3
Chyle leak	1	1
Blood transfusion <sup>a</sup>	3	5
Airway obstruction <sup>b</sup>	0	3
Pulmonary embolism	0	1
Stroke	0	1
Fistula	0	0
TOTAL	7	15

No significant differences were seen between groups  
<sup>a</sup>Blood transfusions were measured as either intra-operative or post-operatively up to the point of discharge from hospital  
<sup>b</sup>Airway obstruction post-tracheostomy decannulation requiring further intervention

secondarily or by primary closure. Recently, a number of reports have described the use of TORS for the resection of larger tumors, traditionally approached by lip-splitting mandibulotomy followed with free flap reconstruction [32–40]. To date, this study reports outcomes on the largest cohort of OPSCC patients treated with TORS and free flap reconstruction and provides the best available evidence for this approach.

TORS with free flap reconstruction is a recent surgical advancement with literature describing this procedure limited to case reports and small case series ranging from one to eleven patients [32–40, 42]. The most common post-TORS free flap reported in the literature is the radial forearm (N = 37), followed by anterolateral thigh

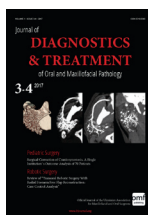
**Table 4** Cost comparison of TORS vs mandibulotomy and radial forearm free flap reconstruction

Items	TORS	Mandibulotomy
Surgical instruments <sup>a</sup>		
Robotic arms (x2)	\$ 1109.72	-
Robotic drapes	\$ 469.67	-
Plates and screws	-	\$ 1072.58
Saw blades and tubing	-	\$ 693.53
Physician billings <sup>b</sup>	\$ 181.19	\$ 235.25
Surgical ward stay (mean)	\$ 16,761.6	\$ 22,930.8
Totals	\$ 18, 522.18	\$ 24,932.16

Cost shown per case in Canadian dollars. Operating time and intensive care unit stays were not statistically different between both groups and is not shown in the analysis  
<sup>a</sup>Only surgical items that are different between both cases are included. Cost of non-disposable items such as the Da Vinci robotic system (purchased prior to the study for non-head and neck robotic surgery) and drills/saws are not included  
<sup>b</sup>Includes only billings that are different between both cases, for anesthesia and surgeon codes as per the 2014–2016 Alberta Health Services Schedule of Medical Benefits

**FIGURE 1.** Cropped screenshot from the article Biron VL, O’Connell DA, Barber B, Clark JM, Andrews C, Jeffery CC, Côté DWJ, Harris J, Seikaly H. Transoral robotic surgery with radial forearm free flap reconstruction: case control analysis. *Journal of Otolaryngology – Head and Neck Surgery* 2017;46:20. <http://dx.doi.org/10.1186/s40463-017-0196-0>. This is an open access article and distributed under the terms of the Creative Commons Attribution 4.0 International License (<http://creativecommons.org/licenses/by/4.0/>).





## PAPERS SCAN

Review of “Cartilage Framework Reconstruction After Resection of Thyroid Cartilage Chondrosarcoma: A Case Report” by Navach V, Chu F, Cattaneo A, Zorzi S, Scelsi D, Ansarin M in *Otolaryngology Case Reports* 2017;4:12–4

This was a well written and creative case report on thyroid cartilage reconstruction (Fig 1) using a novel and simple technique of a free cartilage graft.

As noted by the authors, there is literature to support the benefit of thyroid cartilage reconstruction by reducing incidence of airway collapse and emphysema. I do feel that this is somewhat subjective as there is literature to support unaffected levels of airway and respiratory function with no reconstruction for hemisphere resection of thyroid cartilage. I feel that that literature should also at least be addressed in this paper

to be candid and objective.

I do feel that this method of reconstruction is simple with minimal donor site morbidity, risk of major complications, or markedly increased operative time.

My only criticisms are:

1. That it should address the literature suggesting it may not be needed, as well as the literature stating is of benefit.
2. In cases where a soft tissue envelope is not maintained, a nonvascularized graft would be a poor choice.

In short, well written, useful paper.

Section Editor – Head and Neck Oncological Surgery  
Todd Hanna, MD, DDS, A-FACS  
New York City, NY, USA  
[info@toddhannamdds.com](mailto:info@toddhannamdds.com)



Full Article  
Navach et al

was performed and histopathological findings indicated "low-grade chondrosarcoma".

Computed tomography (CT) results showed a round-shaped lesion arising from the right ala of the thyroid cartilage, with inhomogeneous contrast enhancement surrounded by an incomplete calcified shell, partially dislocating the surrounding structures without signs of infiltration (Fig. 1).

## 2.2. Surgery

The surgical procedure was performed under general anaesthesia with orotracheal intubation. A sterile surgical field was set from the mandibular line, down to the abdomen.

A 6-cm cervical incision was performed at the level of the thyroid cartilage along a natural skin crease of the neck. Sternothyroid and sternohyoid muscles were separated in order to expose the larynx. After cutting the inferior constrictor muscle, the upper and lower horns of the thyroid cartilage were identified and cut, preserving the upper and lower laryngeal nerves, in accordance with the standards of a partial laryngectomy.

The mass was inseparable from the rest of the thyroid cartilage. The laryngeal mucosa was undamaged and gently detached from the neoplasia. The thyroid cartilage was cut at the midline and the neoplasia was safely removed without opening the hypopharynx and larynx. (Fig. 2). The perichondrium was included with the resection.

The ala was reconstructed with a cartilaginous fragment taken from the cartilaginous synchondrosis located between the sixth and eighth rib. During harvesting, we took care to avoid perforating parietal pleura.

The cartilaginous graft was harvested with a synthetic template based on the left residual thyroid ala. It was carved by thinning the internal concave face while the external convex perichondrium was preserved in order to spare graft vascularization.

The graft was placed inside, fixed to the remaining part of the thyroid cartilage along the midline (Fig. 3) with the graft perichondrium facing towards the infra-hyoid muscles to facilitate revascularization of the rib cartilage. A temporary tracheotomy was performed and removed in the fourth day after surgery. No major events occurred during the hospitalization, oral feeding was restored on the second day after surgery and the patient was dismissed after six days. Post-operative laryngeal endoscopy revealed normal laryngeal function and motility with mild ecchymosis of

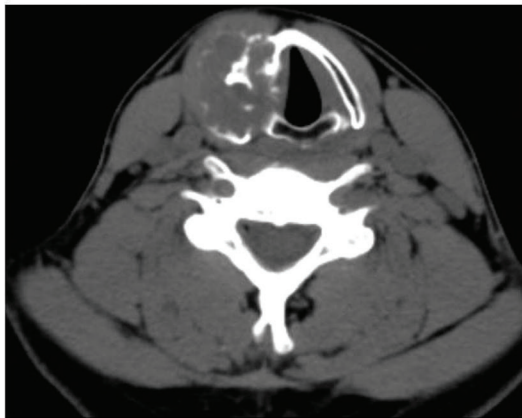


Fig. 1. Preoperative CT scan showing a round shaped, calcified neoplasia of the right ala of the thyroid cartilage.

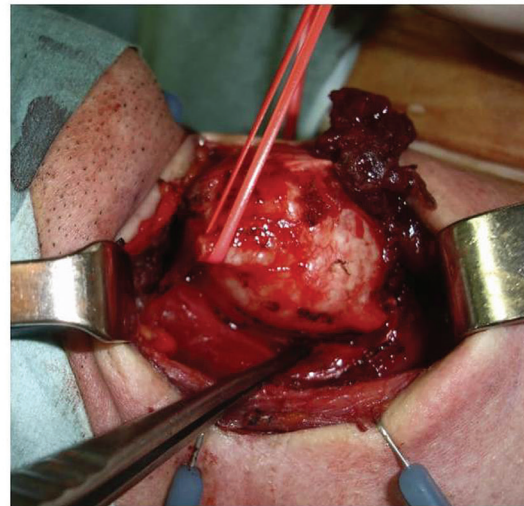


Fig. 2. Intraoperative view: the thyroid ala is cut at the midline and the neoplasia is removed.

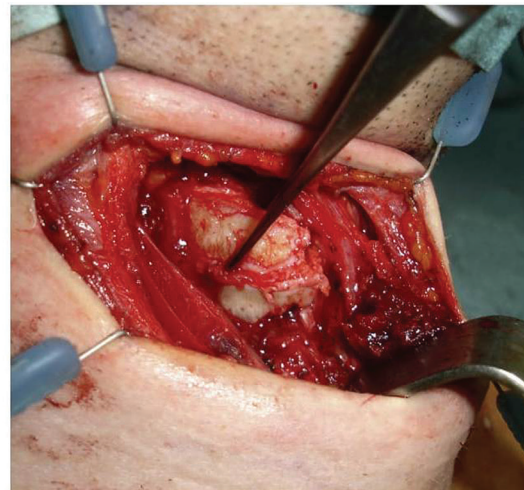


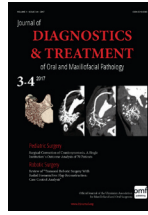
Fig. 3. The cartilage graft replaces the right ala of the thyroid cartilage.

the right hypo-pharyngeal wall. The pathological examination confirmed the diagnosis of low-grade chondrosarcoma, radically excised with safe margins. A CT scan was prescribed at three and six months of follow up, showing no recurrence of disease, the correct inserting of the cartilaginous graft and restoration of its blood supply (Fig. 4). After five years the patient is fully satisfied without evidence of disease.

## 3. Discussion

Chondrosarcomas are a group of heterogeneous tumors that behave very differently depending on the site and the biological characteristics. Low-grade chondrosarcoma has a torpid evolution and good prognosis, while high-grade chondrosarcoma may have a fast negative course [3].

FIGURE 1. Cropped screenshot from the article of Navach V, Chu F, Cattaneo A, Zorzi S, Scelsi D, Ansarin M. Cartilage framework reconstruction after resection of thyroid cartilage chondrosarcoma: a case report. *Otolaryngology Case Reports* 2017;4:12-4. <http://dx.doi.org/10.1016/j.xocr.2017.07.002>. This is an open access article under the CC BY license (<http://creativecommons.org/licenses/by/4.0/>).



## PAPERS SCAN

Review of “A Case of Bisphosphonate-Related Osteonecrosis of the Jaw With a Particularly Unfavourable Course: A Case Report” by Viviano M, Addamo A, Cocca S in *J Korean Assoc Oral Maxillofac Surg* 2017;43:272–5

**B**isphosphonate-related osteonecrosis of the jaw (BRONJ) is side-effects of Bisphosphonates (BP) used to prevent and treat osteoporosis, to treat Paget’s disease, multiple myeloma, bone metastases, and associated malignant hypercalcemia. Nowadays the American Association of Oral and Maxillofacial Surgeons is renamed BRONJ into MRONJ (medication-related osteonecrosis of the jaw) according to due to reports of several non-bisphosphonate drugs resulting in the loss of alveolar bone and clinically appearing similar to BRONJ. Those terms can be used as synonyms but BRONJ is more detailing the pharmaceutical etiology of the specific case of osteonecrosis. BRONJ is currently diagnosed on the basis of necrotic bone exposed in the oral cavity for at least 8 weeks in patients with no history of head or neck radiotherapy.

Viviano *et al* have described case (Fig 1) treated with zoledronic acid after breast cancer surgery diagnosed and confirmed by histological examination diagnosed and confirmed by histological examination. The patient was treated for the necrosis (mechanical debridement, washing with hydrogen peroxide, iodopovidone, and 1% chlorhexidine gel). This treatment controlled her pain, inflammation, and infectious episodes, but bone necrosis continued to spread. Patient was treated by amoxicillin

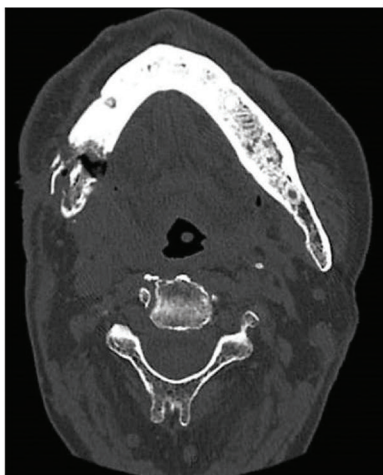and clavulanic acid (1g 3 times a day for 10 days) and metronidazol (250mg 3 times a day for 10 days). After 15 days patient presented with temperature of 39.1°C with tachycardia, dysphagia, dyspnea, and tachypnea, extensive swelling of the face and neck, bright red extended skin, extremely painful to palpation, and incipient trismus. The patient was transferred to the intensive care unit, where antibiotic therapy was integrated with ciprofloxacin (500 mg twice a day i.v.) and imipenem (1.5 g/day) on the basis of an antibiogram. After initial clinical improvement observed about 4 days after cervicotomy, the patient’s condition deteriorated sharply. Despite systemic antibiotic treatment and repeated bronchial lavage, the patient’s general condition deteriorated, culminating in septic shock. This was followed by kidney and liver failure and death due to multiple organ dysfunction on the 10th day.

The findings of this case reveals possibility of fatal consequences after areas of necrosis permitted entry of infective agents and their spread to the oral floor and submandibular space through sublingual tissue and the mylohyoid muscle which gave rise to empyema involving the cervical fascia as necrotizing fasciitis. Therefore the use of BP should be carefully monitored in order to prevent such severe complications.

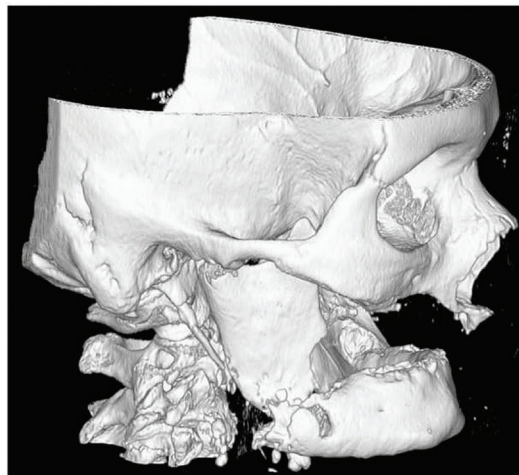
Section Editor – Medication Related Osteonecrosis of the Jaw (MRONJ)  
Nur Hatab, DMD, PhD  
Assistant Professor  
Ras Al Khaimah, UAE  
[nur.hatab@rakmhsu.ac.ae](mailto:nur.hatab@rakmhsu.ac.ae)



Full Article  
Viviano et al



**Fig. 3.** Computed tomography (CT) scan of the head; transversal view. CT scan of the face, neck and chest was performed without contrast, showing pathological fracture of right jaw and periosteal reaction, besides mixed lytic and sclerotic lesion of the jaw.  
*Massimo Viviano et al: A case of bisphosphonate-related osteonecrosis of the jaw with a particularly unfavourable course: a case report. J Korean Assoc Oral Maxillofac Surg 2017*



**Fig. 4.** Three-dimensional computed tomography reconstruction of the head. Radiological image shows a noticeable pathological fracture of right jaw in a 69-year-old woman with breast cancer history and treated with zoledronic acid.  
*Massimo Viviano et al: A case of bisphosphonate-related osteonecrosis of the jaw with a particularly unfavourable course: a case report. J Korean Assoc Oral Maxillofac Surg 2017*

showing impaired cardiovascular function treated with calcium antagonists, beta blockers, antiplatelet agents, diuretics, electrolytes, and albumin (which is typically depleted in such conditions).

A CT scan showed an absence of empyema of the oral floor and cervical spaces due to drainage; however, the lungs showed diffuse signs of pneumonia with massive involvement on the left side. Despite systemic antibiotic treatment and repeated bronchial lavage, the patient's general condition deteriorated, culminating in septic shock. This was followed by kidney and liver failure and death due to multiple organ dysfunction on the 10th day.

### III. Discussion

Bone necrosis is a complication of therapy with BP and is related to the strength of the drug administered, duration of therapy<sup>6</sup>, and concomitance of trauma exposing bone of the jaws. Extraction of a tooth is often the triggering event. If dental treatment is necessary, BP should only be suspended when the risk of complications is high<sup>7</sup>.

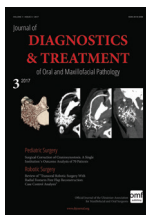Our patient has previously undergone surgery for breast cancer and was immediately treated with zoledronic acid. After seven months of BP therapy, she developed BRONJ. No dental events can explain the osteonecrosis. In the present case, progression of areas of necrosis led to jaw fracture,

permitting entry of infective agents (usually *Staphylococcus aureus* and *P. aeruginosa*<sup>8,9</sup>) and their spread to the oral floor and submandibular space through sublingual tissue and the mylohyoid muscle. This gave rise to empyema involving the cervical fascia as necrotizing fasciitis<sup>10</sup>. The first therapies indicated were high doses of broad-spectrum antibiotics. The flora that generally cause this type of infection consist of resistant anaerobic and aerobic bacteria. The most suitable drugs for appropriate initial antibiotic therapy include penicillinase-resistant penicillin for streptococci and staphylococci, clindamycin or metronidazole for anaerobic gram-negative flora, and fluoroquinolones for *Pseudomonas* and aerobic and anaerobic bacteria<sup>11</sup>.

Other systemic diseases, conditions, and pharmacological therapies that contribute to poor general condition (diabetes, positivity for hepatitis B virus, hepatitis C virus, human immunodeficiency virus, smoking, alcohol abuse, obesity, cardiovascular disease, and immunosuppressant therapy) are fundamental factors in the evolution of BRONJ, infection, and fasciitis, as in the present case, and predispose the patient to a negative outcome. A good prognosis is often aided by early diagnosis, specific pharmacological therapy, and prompt surgical debridement<sup>12</sup>. In the present case, the poor general condition of the patient made it impossible to limit spread of the infection.

Like other pathologies of odontogenic origin that can lead

**FIGURE 1.** Cropped screenshot from the article Viviano M, Addamo A, Cocca. A case of bisphosphonate-related osteonecrosis of the jaw with a particularly unfavourable course: a case report. *SJ Korean Assoc Oral Maxillofac Surg* 2017;43:272-5. <https://doi.org/10.5125/jkaoms.2017.43.4.272>. This is an open-access article distributed under the terms of the Creative Commons Attribution Non-Commercial License (<http://creativecommons.org/licenses/by-nc/4.0/>).

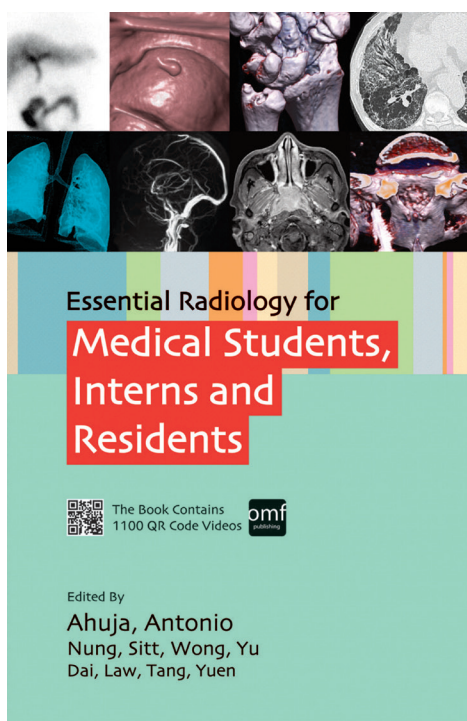


## BOOKS SCAN

Serving our readers, *Journal of Diagnostics and Treatment of Oral and Maxillofacial Pathology* starts to review the most prominent books and book chapters in the field of oral and maxillofacial surgery, head and neck surgery, and radiology. All items are copyrighted and available commercially. Please, send books for consideration to: Tetiana M. Babkina, MD, *Journal of Diagnostics and Treatment of Oral and Maxillofacial Pathology*, Department of Radiodiagnostics, Kyiv Regional Clinical Hospital, 1 Bagovutivska Street, 04107 Kyiv, Ukraine.

Section Editor – Books Scan (Radiology)  
Tetiana M. Babkina, MD, ScD, Professor  
[tbabkina@ukr.net](mailto:tbabkina@ukr.net)

*Essential Radiology for Medical Students, Interns and Residents*  
by Ahuja AT, Antonio GE, Nung RC, et al  
Kyiv, Ukraine: OMF Publishing, 2017, pp. 518



After a hard work, it is finally here: radiologists deeply specialized in the diagnostics of head and neck disorders give the readers a possibility to touch the cutting-edge practical book *Essential Radiology for Medical Students, Interns and Residents*. The textbook is edited by Professor Ahuja AT, the most experienced world radiologist from Hong Kong (SAR).

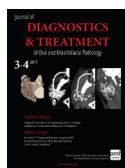Content consists of ten Sections. 1st of which, *Head & Neck*, is critically important to the specialists related with that area of human body. Uniqueness of that work – it consists of 1100 cine loops (CT, MRI scans, US images, etc.) connecting via QR codes. And to *Head & Neck* Section belongs 111 of them covering the whole range of pathologic conditions.

In summary, I would not hesitate to recommend this book to anyone interested in making diagnosis as precise as possible.

Volodymyr E. Medvediev, MD, ScD, Professor  
Honored Science & Technology Worker  
Kyiv, Ukraine  
[vmedvediev@gmail.com](mailto:vmedvediev@gmail.com)



Book Preview



## Surgical Correction of Craniosynostosis. A Single Institution's Outcome Analysis of 70 Patients\*

Evangelos G. Kilipiris<sup>1,\*</sup>, Frantisek Horn<sup>2</sup>, Michal Petrik<sup>3</sup>, Michal Kabat<sup>4</sup>, Jan Trnka<sup>5</sup>, Peter Stanko<sup>6</sup>

<sup>1</sup> Oral and Maxillofacial Surgery Residency Program, PGY4, Comenius University, Faculty of Medicine, Bratislava, Slovak Republic

<sup>2</sup> Department of Pediatric Surgery, Division of Pediatric Neurosurgery, Comenius University, Faculty of Medicine, Pediatric University Hospital and Polyclinic, Bratislava, Slovak Republic (*PhD*)

<sup>3</sup> Department of Pediatric Surgery, Division of Pediatric Neurosurgery, Comenius University, Faculty of Medicine, Pediatric University Hospital and Polyclinic, Bratislava, Slovak Republic

<sup>4</sup> Department of Pediatric Surgery, Division of Pediatric Neurosurgery, Comenius University, Faculty of Medicine, Pediatric University Hospital and Polyclinic, Bratislava, Slovak Republic (*PhD*)

<sup>5</sup> Chair of the Department of Pediatric Surgery, Comenius University, Faculty of Medicine, Pediatric University Hospital and Polyclinic, Bratislava, Slovak Republic (*CSc, Assoc Prof*)

<sup>6</sup> Chair of the Department of Stomatology, Oral and Maxillofacial Surgery, Comenius University, Faculty of Medicine and St. Elizabeth Oncologic Institute, Bratislava, Slovak Republic (*PhD, Prof*)

### ABOUT ARTICLE

#### Article history:

Paper received 3 December 2017

Accepted 6 December 2017

Available online 28 December 2017

#### Keywords:

Cranial vault

Cranial sutures

Craniosynostosis

Synostosis

Scaphocephaly

Total cranial vault reconstruction

Trigonocephaly

Barrel-staving cuts

Fronto-orbital advancement

### ABSTRACT

#### Purpose.

The goal of the current study is to provide outcome data for open cranial vault reconstruction at a single institution by a single craniofacial-neurosurgical team.

#### Patients and Methods.

A total of 70 patient records were reviewed. The inclusion criteria were patients less than 3 years of age undergoing primary surgery with open cranial vault reshaping and a minimum follow up time of 2 years.

#### Findings.

Of the 70 patients meeting the selection criteria (32 female, 38 male), 5 were syndromic and 65 nonsyndromic. Average age and weight were 8.8 months and 9 kg respectively. The oldest child was 21 months and the youngest 3.5 months at the time of surgery. The estimated blood volume lost was 35.8% of total calculated blood volume. Average surgical time was 223.2 minutes.

#### Conclusion.

Our review of 70 open repairs of patients with craniosynostosis demonstrates good long-term results with an overall low complication rate and represents open cranial vault reconstruction as a valuable method for repair of such defects.

© 2017 OMF Publishing, LLC. This is an open access article under the CC BY licence

(<http://creativecommons.org/licenses/by-nc/4.0/>).

### Introduction

Craniosynostosis, the premature fusion of cranial sutures, occurs in approximately 3.5-4.5 out of 10,000 live births worldwide [1]. It can affect one or multiple sutures, occur as an isolated defect or be associated with a craniofacial syndrome. Nonsyndromic craniosynostosis presents more commonly than syndromic craniosynostosis. Single suture synostosis results in head shape deformities with classic presentations depending on which suture is involved. Sagittal suture fusion results in scaphocephaly, the most common synostosis abnormality in Europe, following by metric suture fusion resulting in trigonocephaly. Unilateral

coronal suture fusion, more commonly, or lambdoid suture fusion, less commonly result in plagiocephalic head shapes, and bilateral coronal or lambdoid fusions present with brachiocephalic head shape deformities [2].

Intracranial hypertension, visual impairment, limitation of brain growth and neuropsychiatric disorders are associated with craniosynostosis. Generally, a greater functional disturbance appears in proportion to the number of sutures involved [3]. In surgically correctable cases, various approaches have been described. Historically, all repairs were performed via open transcranial approaches. Recently, interest in minimally invasive techniques, such as endoscopic suture release, spring assisted surgery, and distraction osteogenesis have been studied in an effort to potentially reduce surgical morbidity [4].

While inherent risks of open cranial vault reshaping exist, the past two decades have enjoyed advances in resorbable fixation, imaging modalities, and perioperative medical management. The purpose of this retrospective

\* This manuscript has not been presented

\* Corresponding author. Department of Oral and Maxillofacial Surgery, Comenius University, Faculty of Medicine, Moskovska 15, Bratislava 81108, Slovak Republic  
Tel.: +421944715632, Fax: +421232249724

E-mail address: [varonos@live.co.uk](mailto:varonos@live.co.uk) (E. G. Kilipiris)

Instagram: [@evangeloskilipiris](https://www.instagram.com/evangeloskilipiris)

study is to provide a single institution's experience in types of craniosynostosis, management techniques, perioperative data and complication rates for open cranial vault reshaping at Kramare Pediatric University Hospital with Polyclinic in Bratislava.

### Patients and Methods

The inclusion criteria for this study were patients less than three years of age undergoing primary surgery with open cranial vault reshaping and a minimum of 2 years follow-up. Based on inclusion criteria, 70 patients with craniosynostosis, treated with surgical correction between 2005 and 2015 by the institutional craniofacial and neurosurgical team were included. The surgical procedure of choice was single stage open transcranial vault reshaping with barrel-staving and orbital bandeau advancement as required for existing fronto-orbital dysmorphism. Resorbable plates with screws and absorbable sutures were used, based on their success and safety in pediatric craniofacial surgery [5].

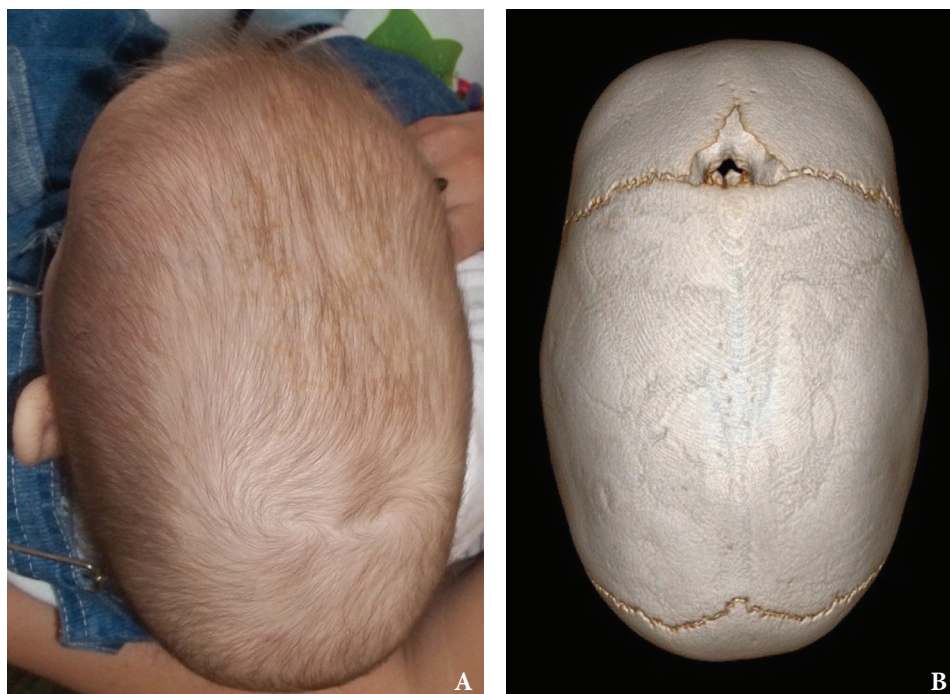All cases were performed by a single craniofacial-pediatric neurosurgical team, and rotating anesthesiologists and pediatric intensivists assigned to the team. Patient medical records were used to assess the length of surgery, estimated blood loss, postoperative complications and average length of hospital stay.

A complete history and physical exam were performed along with computed tomography utilizing three-dimensional reconstruction for pre-surgical planning. Standard monitoring using temperature probes, electrocardiography, capnography, and pulse oximetry

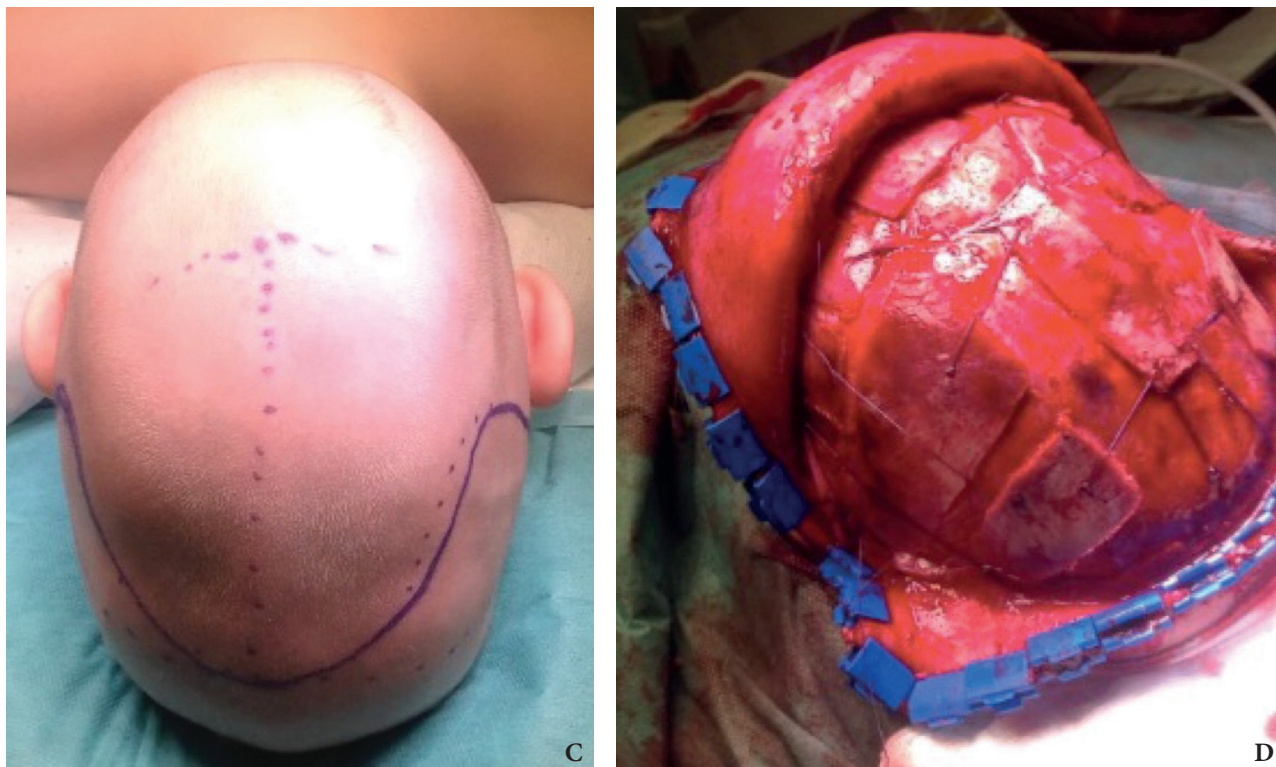
were employed. Induction was achieved with sevoflurane in most cases. The standard protocol included central venous access and an arterial line, hypotensive anesthesia, and packed red blood cell transfusions given at key portions of each case to correspond with anticipated blood loss.

Patients undergoing anterior cranial vault reshaping for metopic or coronal suture synostosis were placed supine in the pediatric horseshoe headrest. Those undergoing surgery for posterior or total cranial vault reshaping were placed prone with the neck slightly extended to allow access to the entire cranial vault. In prone cases, extra care in the way of foam padding was used to protect the globes.

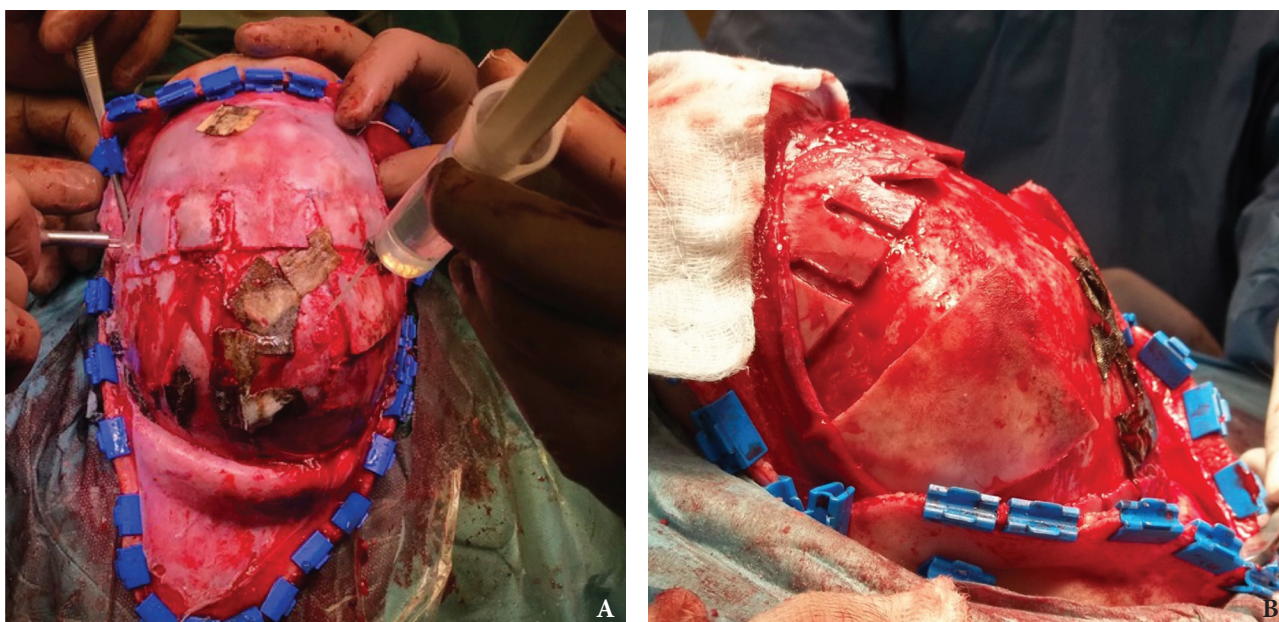
All procedures employed a coronal incision with Raney clips for hemostatic assistance. Dissection was carried out in a subperiosteal plane to expose the necessary area for reshaping. Treatment of scaphocephaly consists of total cranial vault reshaping, with variations depending on the extent of fusion and which part of the sagittal suture is involved (Fig 1A-D). When the posterior half was fused, the patient was treated in the prone position with the posterior two thirds of the cranial vault reshaped. When the anterior half was fused, the patient was treated in the supine position with the anterior two thirds of the cranial vault reshaped, with or without superior orbital rim reshaping (Fig 2A-C). Complete sagittal suture synostosis was treated at one operative setting in the prone position via total cranial vault reshaping. Typically sagittal synostosis procedures are performed between 6 and 9 months of age. In older children (older than 1 year) or children with a need for upper orbital reconstruction, the preference was to treat them in the supine position at one operative setting.



**FIGURE 1.** (A) Clinical picture of patient with scaphocephaly due to sagittal suture synostosis. (B) Preoperative 3D reconstruction CT scan demonstrating fusion of the sagittal suture. (Fig 1 continued on the next page.)

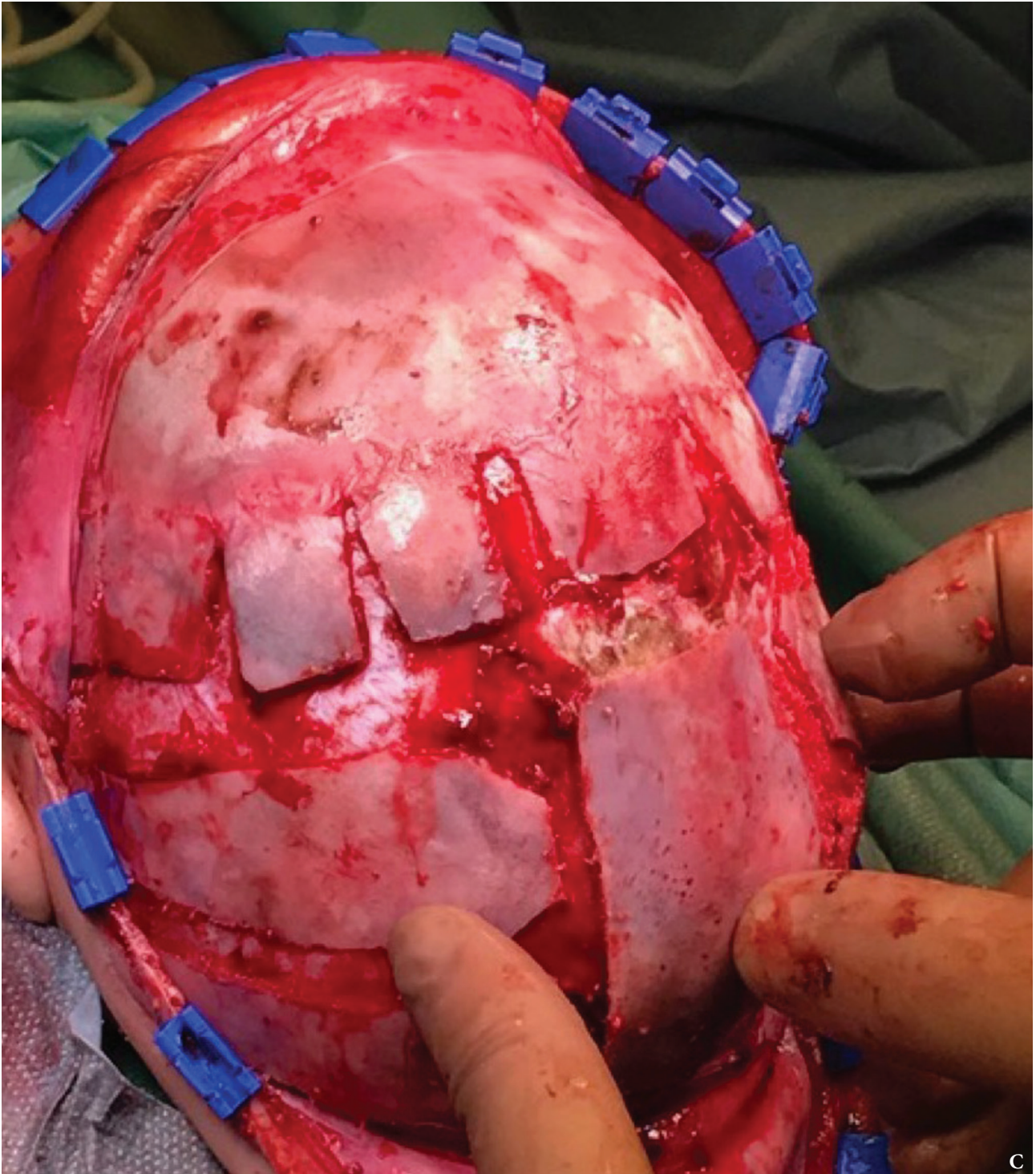


**FIGURE 1. (cont'd).** (C) Patient on prone position with proposed coronal incision marked. (D) Total cranial vault reconstruction with absorbable Vicryl sutures for fixation of bone flaps.



**FIGURE 2. (A-C)** Patient with sagittal suture synostosis and a normal supraorbital region on supine position after release of the fused suture and barrel-staving cuts to facilitate bitemporal widening. (Fig 2 continued on the next page.)

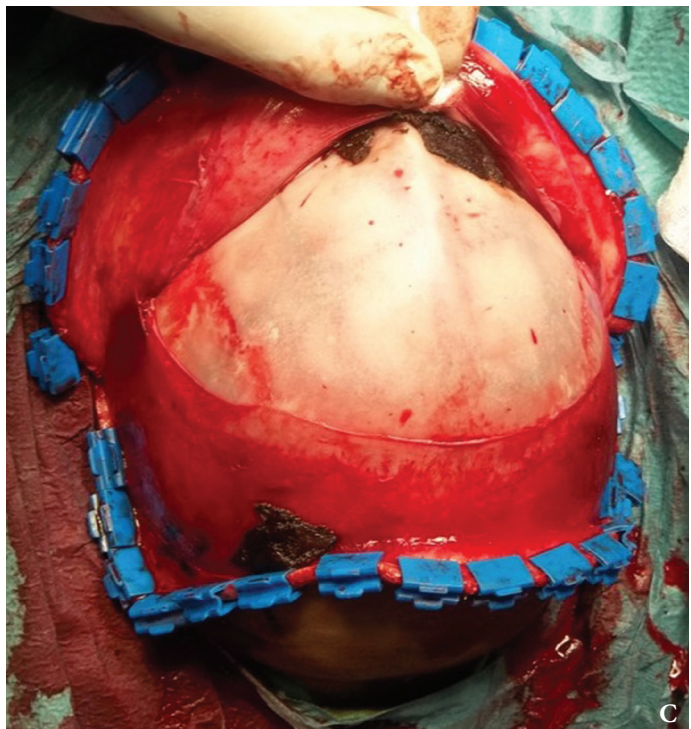
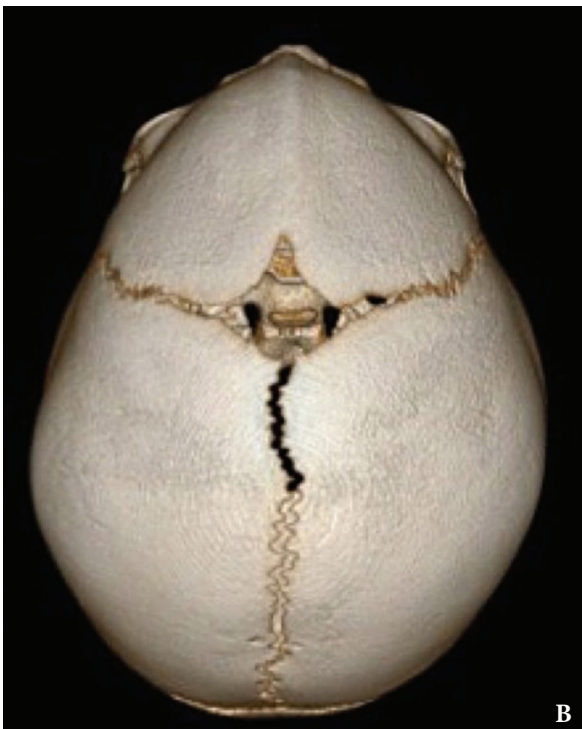
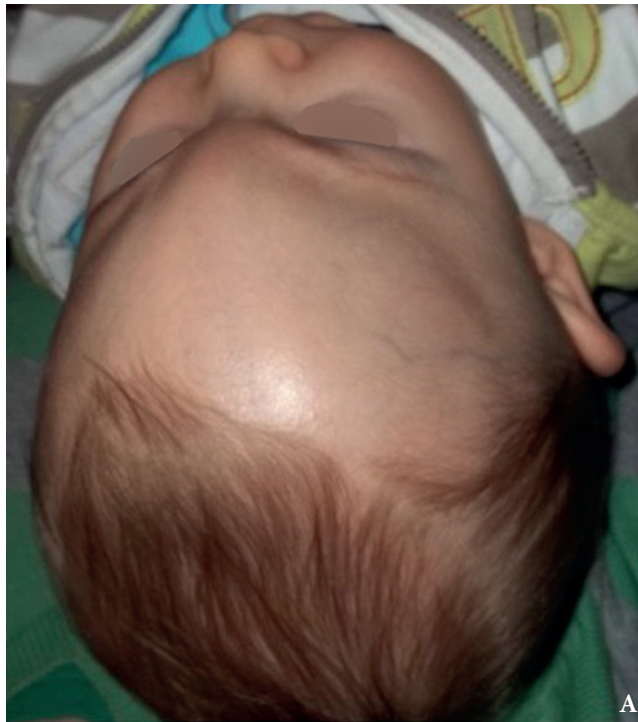


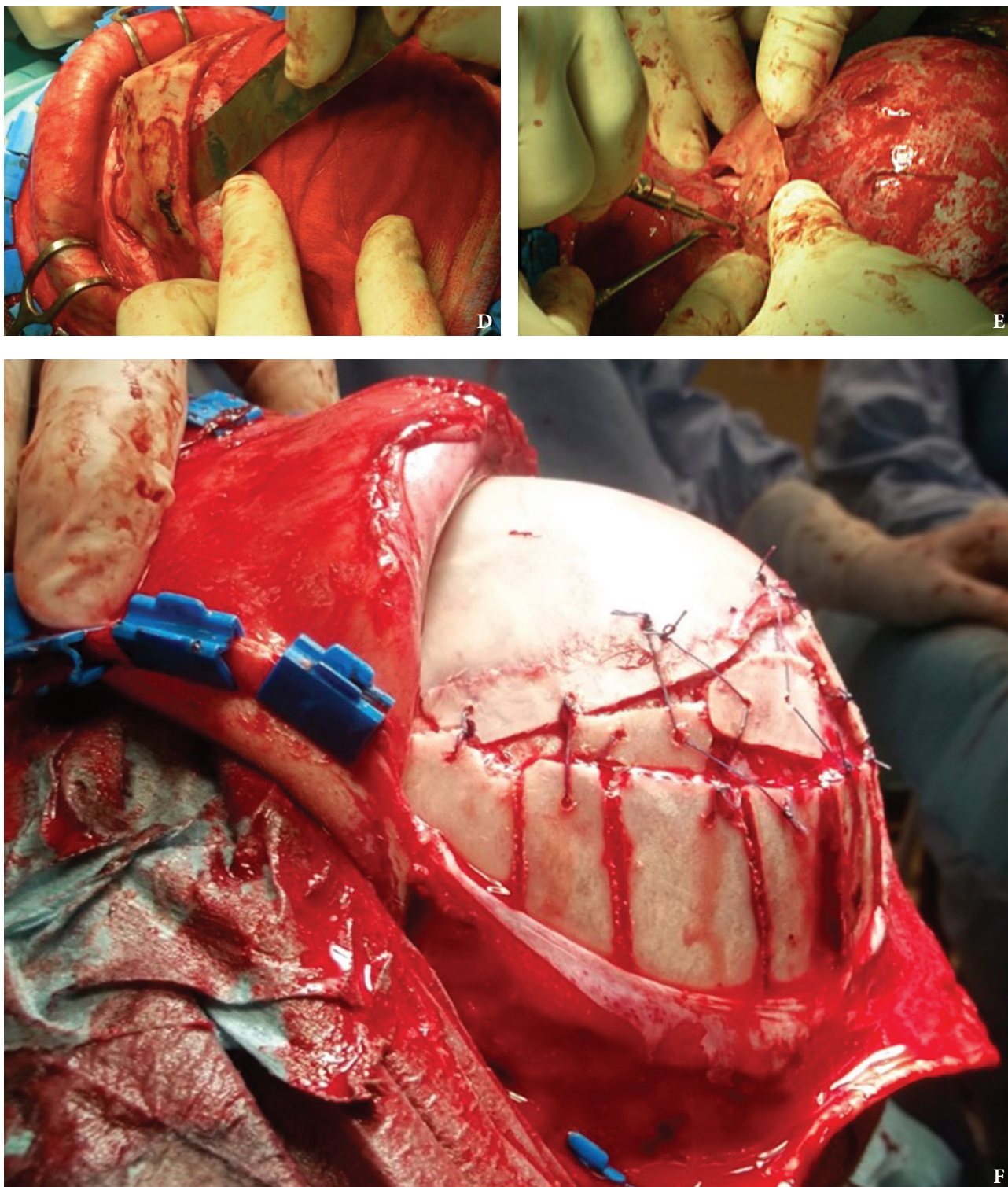
**FIGURE 2. (cont'd).** (A-C) Patient with sagittal suture synostosis and a normal supraorbital region on supine position after release of the fused suture and barrel-stapling cuts to facilitate bitemporal widening.

Cases of bilateral coronal suture synostosis were treated with simultaneous frontal bone and bilateral orbital rim advancement. Correction of trigonocephaly involved metopic suture release, simultaneous bilateral rim advancements, and lateral

widening via frontal bone advancement (Fig 3A-G). Orbital hypotelorism was corrected by splitting the supraorbital unit in the midline and placing autogenous cranial bone grafts to increase the intraorbital distance.



**FIGURE 3.** (A) A 9-month-old boy with metopic synostosis resulting in trigonocephaly. (B) 3D reconstruction CT scan showing fusion of the metopic suture. (C) Intraoperative view of the fused metopic suture. (Fig 3 continued on the next page.)



**FIGURE 3. (cont'd).** (D), (E) Bilateral superior orbital rim reshaping and advancement. (F) Anterior cranial vault reshaping. (Fig 3 continued on the next page.)

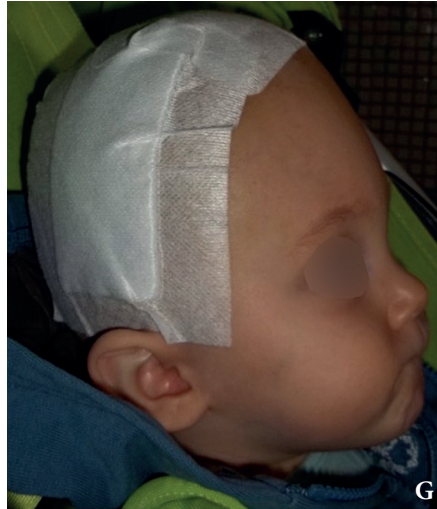

FIGURE 3. (cont'd). (G) Lateral view one week after reconstruction.

**Results**

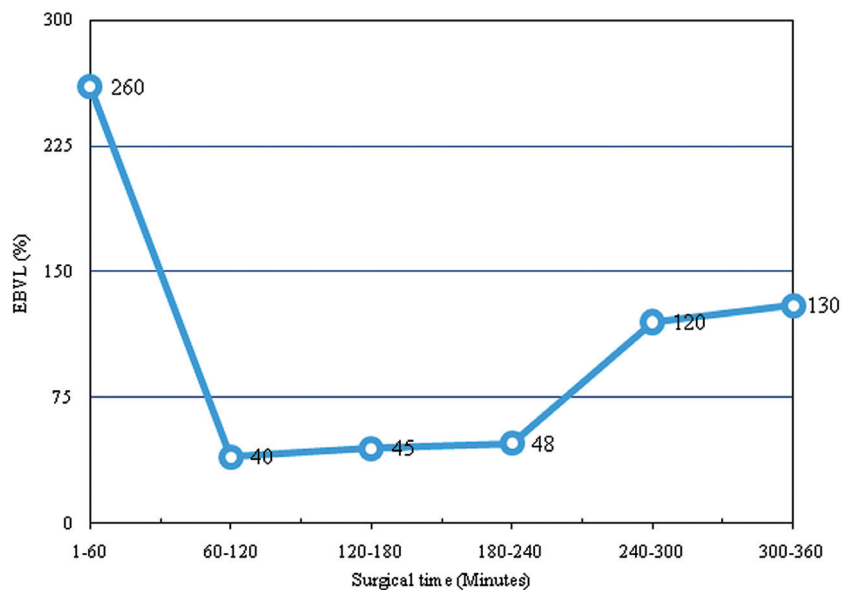
Of the 70 patients meeting the selection criteria, the average age and weight at the time of surgery were 8.8 months and 9 kg respectively. The oldest child was 21 months and the youngest 3.5 months at the time of surgery. The most

commonly synostosed suture was the sagittal followed by the metopic. The estimated blood volume (EBV) loss was on average 241.6 ml, and the surgical time 223.2 min (Chart 1). Average length of PICU stay was 3.17 days. Of the 70 cranial vaults 5 were associated with a syndrome and 65 were isolated synostosis (Table 1).

TABLE 1. Results – Articles Included in the Study and Relevance

Perioperative Demographics	Number
Average surgical age (months)	8.9 (range 3.5-21)
Average weight at time of surgery (kg)	9 (range 5.2-21)
Estimated average blood loss (ml)	241.6 (range 90-2100)
Average hospital stay (days)	7.24 (range 5-16)
Average surgical time (minutes)	223.2 (range 72-442)

CHART 1. Estimated blood volume loss versus surgical time (minutes)

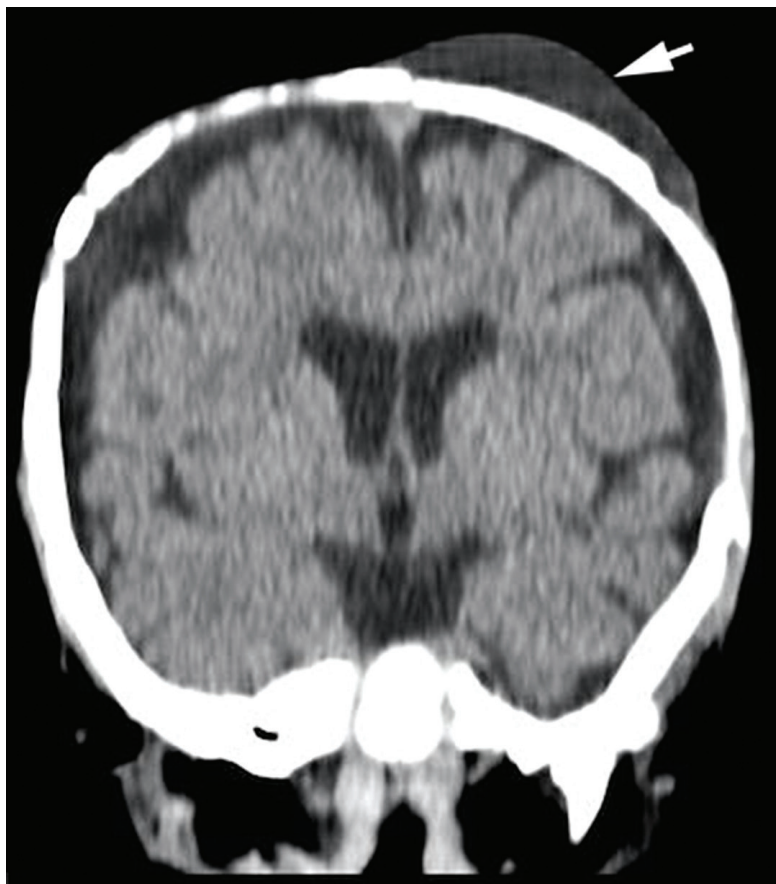

Complications included 1 subgaleal hematoma that was aspirated, 1 wound infection treated with oral cephalixin, 1 subgaleal abscess requiring drainage, 4

dural tears were repaired intraoperatively with Nurolon suture, and 1 case with sagittal sinus bleed (Table 2), (Fig 4).

**TABLE 2.** Number of complications.

Summary of Complications	Number
Subgaleal hematoma (Fig 4)	1
Wound infection	1
Subgaleal abscess	1
Dural tear	4
Sagittal sinus bleed	1



**FIGURE 4.** CT scan coronal projection of one patient developing a subgaleal hematoma (arrow) requiring drainage postoperatively.

Nearly half of the patients in the study (44%) had a scaphocephalic head shape as a result of sagittal suture synostosis. Trigonocephaly was the second most common head shape deformity encountered in this study with 27% due to metopic suture synostosis. While the most common cause of plagiocephalic head shape is deformational, the most common form of synostotic plagiocephaly is a result of unilateral fusion of the coronal suture, with lambdoid synostosis occurring very rarely [6]. Whenever posterior plagiocephaly was encountered, positional or infant molding with or

without congenital torticollis were ruled out. All cases of plagiocephaly in this series were the result of unilateral coronal synostosis. Out of 70 patients, 4 presented with a brachycephalic head shape due to fusion of the coronal sutures bilaterally. Of the 4 cases of brachycephaly in this study, the majority (3/5) of our syndromic patients fell in this category. Two patients had Crouzon syndrome and one patient Apert's syndrome.

Eight patients presented with fusion of more than one suture (Chart 2 and Table 3). Four patients demonstrated a fusion of the unilateral coronal suture in association

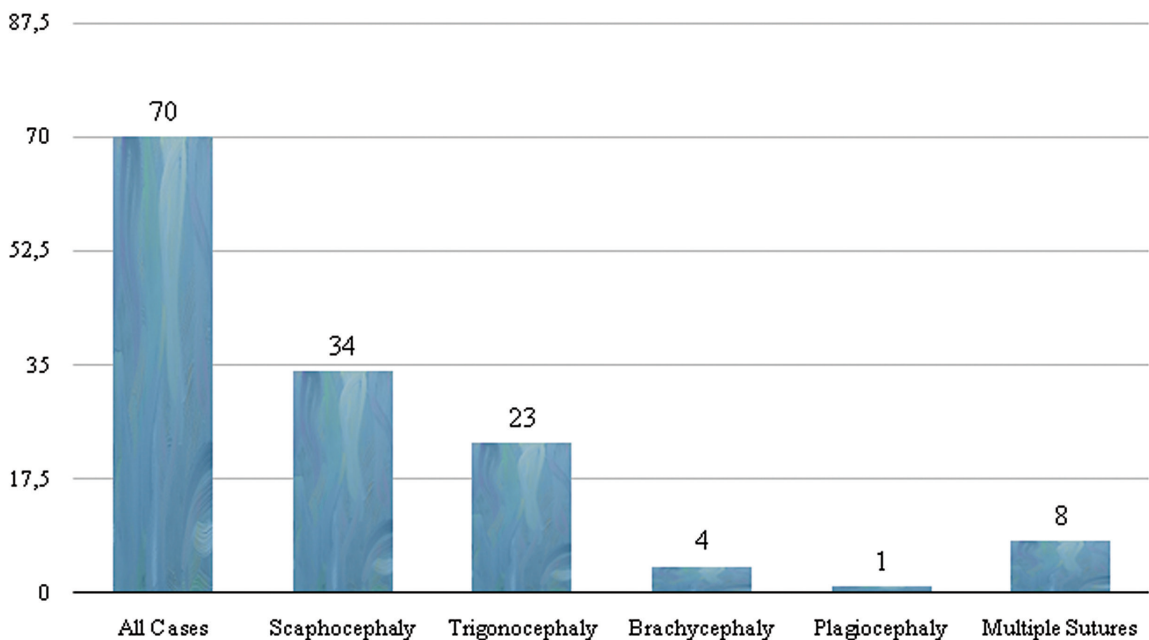
with the sagittal suture. Three patients presented with fusion of the metopic and sagittal sutures, and one patient encountered fusion of the metopic suture together with the coronal sutures bilaterally. The procedure planned for treatment of the patients with unilateral coronal and sagittal suture fusion was orbital rim advancement along with bifrontal and unilateral parietal craniotomies for cranial vault reshaping. In the second group of patients, the metopic suture fusion resulted in frontal bossing and suture ridging but did not affect the orbital rims. For

correction of the metopic suture fusion, direct frontal contouring was performed using a round bur. The sagittal suture was removed. Occipital and bilateral parietal craniotomies were performed. Barrel-staving cuts were developed to facilitate the final reshaping and bone flaps were fixated with absorbable Vicryl sutures. The only patient with fusion of metopic and bicoronal sutures was managed with anterior cranial vault reshaping, bilateral superior orbital rim advancements and bitemporal widening via barrel-staving osteotomies.

TABLE 3. Distribution of involved sutures and syndromic versus nonsyndromic patients.

70 Total Patients (32 Female, 38 Male)	Syndromic vs Nonsyndromic
34 Scaphocephalic	65 Nonsyndromic
23 Trigonocephalic	5 Syndromic ( 2 Apert, 3 Crouzon)
1 Plagiocephalic	
4 Brachycephalic	
8 Multiple Suture	

CHART 2. Distribution of head shape deformity and synostosis in total numbers.



**Conclusion**

The results of recent studies report significantly low complication rates. The intraoperative outcomes presented in this series follow a similar trend with an overall complication rate of 12.7%. With the ability to achieve the desired shape at the time of surgery and relatively low incidences of reoperation, as well as low morbidity and

mortality rates, open cranial vault reconstruction remains a valuable method in the management of patients with craniosynostosis.

**Funding**

No funding was received for this study.

**Conflict of Interests**

The authors declare no conflict of interest.

**Role of Author and Co-authors**

Evangelos Kilipiris (concept – design of the paper and writing)  
 Frantisek Horn (material collection and writing)  
 Michal Petrik (material collection and writing)  
 Michal Kabat (material collection and writing)  
 Jan Trnka (material collection and writing)  
 Peter Stanko (editing)

**Ethical Approval**

Approval was obtained from the Medical Ethics Committee of the Comenius University in Bratislava.

**Patient Consent**

Written patient consent was obtained from parents to publish the clinical photographs.

**Acknowledgements**

None.

**References**

1. Zakhary G, Montes D, Woerner J, Notarianni C, Ghali G. Surgical correction of craniosynostosis. A review of 100 cases. *J Cranio-Maxillo-Fac Surg* **2014**;42:1684–91.
2. Slater B, Lenton K, Kwan M, Gupta D, Wan D, Longaker M. Cranial sutures: a brief review. *J Plast Reconstr Surg* **2008**; 121:170–8.
3. Ghali G, Sinn D, Tantipasawasin S. Management of nonsyndromic craniosynostosis. *Atlas Oral Maxillofac Surg Clin North Am* **2002**;10:1–41.
4. Jiminez D, Barone C. Multiple suture nonsyndromic craniosynostosis: early and effective management using endoscopic techniques. *J Neurosurg Pediatr* **2010**;5:223–31.
5. Eppley B, Morales L, Wood R, Penslar J, Goldstein J, Havlik R, et al. Resorbable PLLA-PGA plate and screw fixation in pediatric craniofacial surgery: clinical experience in 1883 patients. *J Plast Reconstr Surg* **2004**;114:850–6.
6. Panchal J, Amirshaybani H1, Gurwitch R, Cook V, Francel P, Neas B, et al. Neurodevelopment in children with single-suture craniosynostosis and plagiocephaly without synostosis. *J Plast Reconstr Surg* **2001**;108:1492–8.

Kilipiris EG, Horn F, Petrik M, Kabat M, Trnka J, Stanko P.  
 Surgical correction of craniosynostosis. A single institution's outcome analysis of 70 patients.  
*J Diagn Treat Oral Maxillofac Pathol* **2017**;1:137–146.  
<http://dx.doi.org/10.23999/j.dtopm.2017.3-4.6>



## Management of Alveolar Osteitis in Dental Practice: A Literature Review\*

Nur Hatab<sup>1,\*</sup>, Jenan Yahya<sup>2</sup>, Sara Alqulaihi<sup>3</sup>

RAK College of Dental Sciences, RAK Medical and Health Sciences University, Ras Al Khaimah, United Arab Emirates (UAE)

<sup>1</sup> Senior Lecturer, DMD, PhD, Assis Prof

<sup>2</sup> Student, BDS

<sup>3</sup> Student, BDS

### ABOUT ARTICLE

#### Article history:

Paper received 10 June 2017

Accepted 16 June 2017

Available online 28 December 2017

#### Keywords:

Alveolar osteitis (AO)

Dry socket

Osteomyelitis

Third molar extractions

Chlorhexidine

### ABSTRACT

#### Background.

Dry socket is one of the most common post-extraction complications with its incidence reaching up to 30% after impacted third molar extractions. In spite of its high incidence, there is no established treatment for the condition.

#### Objectives.

To investigate how efficient different management methods of Alveolar osteitis are, in regards to pain relief, healing process and reduction of the incidence.

#### Materials and Methods.

A literature search of "PubMed-MEDLINE" database was conducted using the keywords "dry socket management", "alveolar osteitis", "fibrinolytic alveolitis", "post-extraction complications". The inclusion criteria were clinical studies, case reports, reviews and human studies, related to alveolar Osteitis published from 2011-2016, written in English language. The exclusion criteria were animal studies, studies that discussed other post-extraction complications, and in any other languages than English.

#### Results.

63 articles were found and only 31 were reviewed. 18 out of 31 articles were included in the results, after reading the full text, due to lack of significant results in the rest of the articles. Out of these there were 12 clinical studies, 3 systematic reviews and 1 retrospective study.

#### Conclusion.

It was concluded that there is no specific management that could be rated as the best to treat dry socket, due to the lack of evidence to support the use of one management over the other, although there are many options that can help manage it and have proved to be highly effective recently and until today.

© 2017 OMF Publishing, LLC. This is an open access article under the CC BY licence (<http://creativecommons.org/licenses/by-nc/4.0/>).

### Introduction

Dry socket is one of the most common post-extraction complications with its incidence reaching up to 30% after impacted third molar extractions. Many terms can refer to this complication like "fibrinolytic alveolitis", "localized osteitis", "alveolitis sicca dolorosa", "septic socket", and "necrotic socket" [1]. It has been a topic of discussion in the literature recently, as the main cause and management method haven't been decided yet.

This study discusses dry socket and focus on the different types of management that have been found in the literature.

### Review of the Literature

Alveolar osteitis (AO), or dry socket, is a relatively common complication that can occur after tooth extraction. It causes a lot of pain and discomfort but is easily treatable. Its incidence is only 2-5% for normal extractions but can get up to 30% after impacted third molar extractions (Fig 1). Smokers and people with poor oral hygiene are more likely to experience AO after an extraction [2].

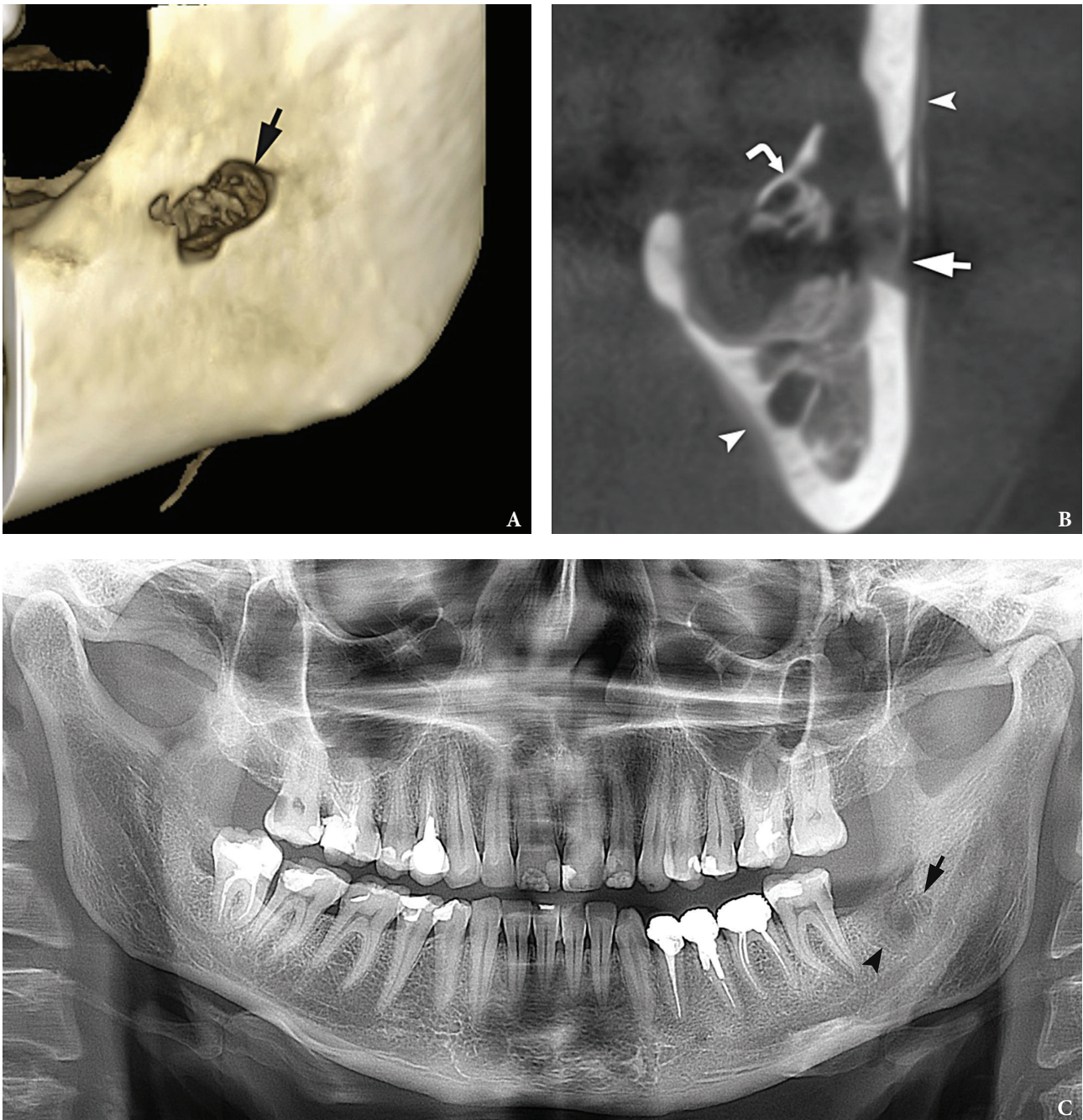
The reason behind AO is that the bone and the nerves in the extraction socket stay exposed to air and fluids after the extraction due to dislodgment or disintegration of the blood clot that was previously present inside the socket right after extraction. This causes an infection which can last for multiple days until it is treated. The symptoms of dry socket include pain, halitosis and an unpleasant taste. The halitosis is accompanied by gingival inflammation and ipsilateral

\*This manuscript has not been presented

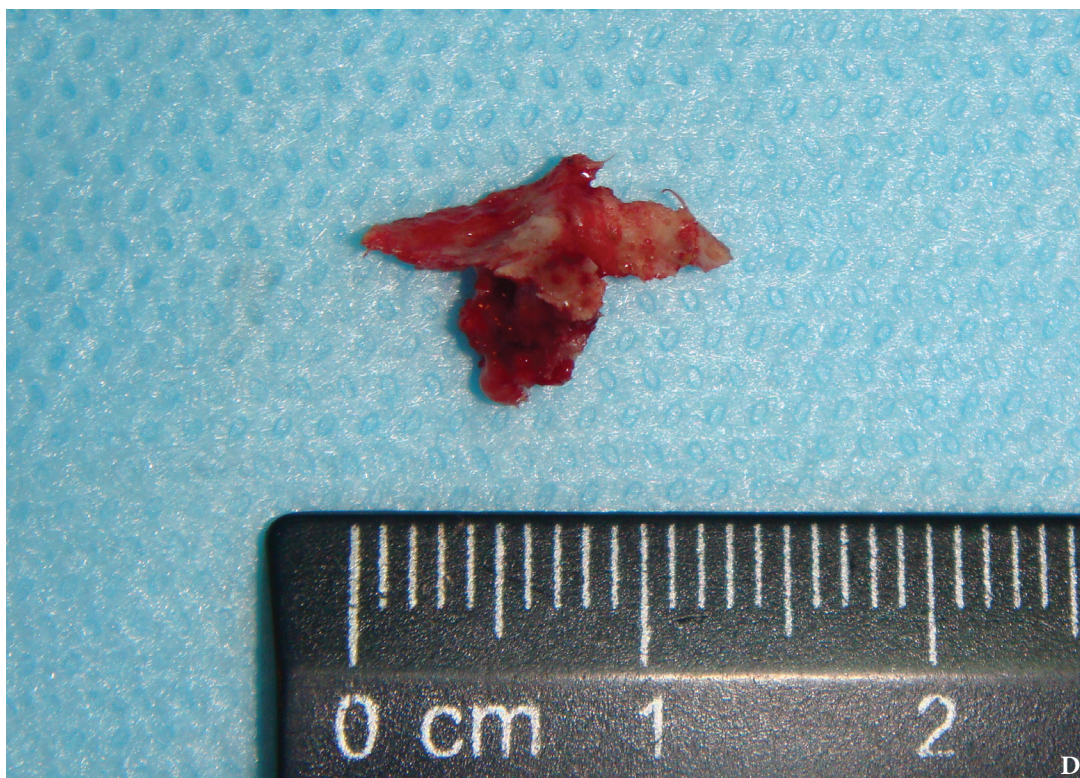\* Corresponding author. Oral and Maxillofacial Surgery, RAK College of Dental Sciences, RAK Medical & Health Sciences University, UAE  
Tel.: +971 54 429 7376

E-mail address: [nur.hatab@rakmsu.ac.ae](mailto:nur.hatab@rakmsu.ac.ae) (N. Hatab)





**FIGURE 1.** A 35-year-old lady with alveolar osteitis of the mandible complicated with local osteomyelitis. Alveolar osteitis starts after removal of lower wisdom tooth. 3D reconstructed (A) and coronal (B) CBCT scans shows cortical bone defect (*arrow*) of the ramus. Also the periosteal reaction (*arrowheads*) and bone sequester (*curved arrow*) is noted. On panoramic x-ray the bone resorption (*arrow*) of the ramus near the postextraction socket (*arrowhead*) is noted. A sequestered fragment of the mandibular bone (D) after its removal 8 week after the process starts. (Images of **Figure 1** are courtesy of Ievgen I. Fesenko, Assis Prof; Kyiv, Ukraine) (**Fig 1 continued on the next page.**)



**FIGURE 1. (cont'd).** A sequestered fragment of the mandibular bone (**D**) after its removal 8 week after the process starts. (Images of **Figure 1** are courtesy of Ievgen I. Fesenko, *Assis Prof*, Kyiv, Ukraine)

regional lymphadenopathy. The pain can be localized or can extend to the temporal region and to the ear (if the dry socket occurs at the third molar region). There are various risk factors for this complication including difficulty of the surgery, age and gender, trauma, irrigation methods, infection and smoking, medical history, systemic disorders, amount of anesthesia, operator's experience, menstrual cycle and the use of oral contraceptives [3-5].

There are many treatment options for AO including, topical and systemic antibiotics, NSAIDs, antifibrinolytic drugs, avoiding curettage of the socket, relieving the pain by packing a paste of zinc oxide eugenol (ZOE) into the socket and other drug combinations have been used as well. None of the mentioned treatment options has gained universal acceptance or success.

The prevention methods include use of antibiotics, avoiding smoking and the use of mouth rinse and gels, which can help reduce the incidence of AO [5]. This study reviews and discusses on the causes and possible management of alveolar osteitis as a complication after dental extractions which are available in the literature until now.

#### Material and Methods

In this study, a literature search of "PubMed-MEDLINE" database was conducted with the following search terms

"dry socket management", "alveolar osteitis", "fibrinolytic alveolitis", "post-extraction complications". The terms were also merged using the word "AND" to find results that contained two or more of the keywords.

The inclusion criteria were clinical studies, case reports, reviews and human studies, related to alveolar osteitis published from 2011-2016, written in English language.

The exclusion criteria were animal studies, studies that discussed other post-extraction complications, and in any other languages than English.

The selection of articles was based on reading the titles and the abstract in order to identify the relevance of the contents of the articles.

#### Results

In this study, 63 articles were found using the keywords, and after applying the inclusion and exclusion criteria only 31 were reviewed. 18 out of 31 articles were included in the results, after reading the full text, due to lack of significant results in the rest of the articles.

Out of these there were 12 clinical studies, 3 systematic reviews and 1 retrospective study. The studies included were divided according to the level of pain, healing process, reduction of the incidence of AO and reduction in the inflammation and swelling.

In attempting to find the management that can reduce the incidence of AO, it was found that many

options were available including CHX (chlorhexidine), which works as an antibacterial and an antiseptic in the socket, antibiotics like Penicillin V and amoxicillin with clavulanic acid, PRF (platelet rich fibrin) and PRP (platelet rich plasma), PRGF (plasma rich in growth factors), ozone gas, tranexamic acid, and the use of collagen sponge.

The management options that were found to be

successful at reducing the levels of pain were the use of CHX, alvogyl, PRF and PRP, PRGF, LLLT (low level laser therapy), honey and zinc oxide eugenol.

Accelerated healing was achieved by the use of PRF and PRP, PRGF, honey and Tranexamic acid. Honey also reduced the inflammation and the C-reactive protein levels in the sockets. PRF and PRP reduced the swelling.

**TABLE 1.** Comparing different management options of alveolar osteitis.

	Authors	Title	Management	Result	Year/Type of Study
<b>Chlorhexidine</b>	Daly <i>et al</i> [3]	Local interventions for the management of alveolar osteitis. Local interventions for the management of alveolar osteitis.	Use of different concentrations of CHX mouth rinses (0.12% and 0.2%).	Prevention of dry socket by approximately 42% and 58% using mouth rinses and gel respectively. Results were statistically significant.	2012/Randomized controlled trials
	Zhou <i>et al</i> [7]	The efficacy of intra-alveolar 0.2% chlorhexidine gel on alveolar osteitis.	Use of different types of chlorhexidine (gel and mouthwash).	Both types of CHX were effective in preventing AO by 56%. This result was significant.	2016/A meta-analysis
	Sridhar <i>et al</i> [6]	Evaluation of the Perioperative Use of 0.2% Chlorhexidine Gluconate for the Prevention of Alveolar Osteitis After the Extraction of Impacted Mandibular Third Molars.	Use of 0.2% chlorhexidine mouthwash (rexidine).	CHX decreased the incidence of AO and the result was statistically significant.	2011/A clinical study
	Requena-Calla <i>et al</i> [8]	Effectiveness of intra-alveolar chlorhexidine gel in reducing dry socket following surgical extraction of lower third molars.	Use of intra-alveolar chlorhexidine gel.	A significant reduction in the pain levels in the sockets where chlorhexidine gel was applied compared to the placebo gel.  There was no significant difference in the reduction of alveolar osteitis.	2016/ Pilot study
<b>Antibiotics</b>	Marcussen <i>et al</i> [10]	Effect of single-dose preoperative antibiotics at surgical osteotomy extraction of lower third molars.	Use of single dose of penicillin.	A significant reduction in AO.	2016/Systematic review
	Arteagoitia <i>et al</i> [9]	Efficacy of amoxicillin and amoxicillin/clavulanic acid in the prevention of infection and dry socket after third molar extraction. A systematic review and meta-analysis.	Used of prophylactic amoxicillin, with or without clavulanic acid	The risk of alveolar osteitis was reduced when amoxicillin with clavulanic acid was administered. And the difference was statistically significant.	2016/Systematic review, meta-analysis.

	Authors	Title	Management	Result	Year/Type of Study
<b>Alvogyl</b>	Eshghpour <i>et al</i> [11]	Comparison of the effect of low level laser therapy with alvogyl on the management of alveolar osteitis.	Use of alvogyl and low level laser therapy.	Alvogyl was quickest at relieving pain.  The result was statistically significant.	2015/Randomized clinical trial pilot study.
<b>LLLT</b>	Eshghpour <i>et al</i> [11]	Comparison of the effect of low level laser therapy with alvogyl on the management of alveolar osteitis.	Use of alvogyl and low level red laser and infrared laser therapy to reduce alveolar osteitis	Alvogyl was quickest at relieving pain, but on day 2, after 12 hours, low power red laser (660nm wavelength) was more efficient.	2015/ Randomized clinical trial pilot study.
<b>PRF/PRP</b>	Hoaglin <i>et al</i> [13]	Prevention of localized osteitis in mandibular third-molar sites using platelet-rich fibrin.	Use of platelet-rich-fibrin.	Prevalence of dry socket decreased (from 9.5% to 1% (90%). This result was statistically significant.	2013/Clinical trial.
	Dutta <i>et al</i> [12]	A randomized comparative prospective study of platelet-rich plasma, platelet-rich fibrin, and hydroxyapatite as a graft material for mandibular third molar extraction socket healing.	Use of platelet-rich plasma (PRP), platelet-rich fibrin (PRF), and hydroxyapatite (HA) .	Pain and swelling significantly reduced and the site showed better soft tissue healing after used of PRP, PRF compared to HA.	2016/A randomized comparative prospective study.
<b>PRGF</b>	Pal <i>et al</i> [14]	Comparative evaluation of zinc oxide eugenol versus gelatin sponge soaked in plasma rich in growth factor in the treatment of dry socket: An initial study.	Use of PRGF with gelatin sponge, and zinc oxide eugenol dressing.	Extraction sockets that were treated with PRGF gelatin sponge showed significantly faster healing.	2013/Clinical trial.
	Haraji <i>et al</i> [12]	Effect of plasma rich in growth factors on alveolar osteitis.	Use of plasma rich in growth factors.	Intensity of pain and occurrence of AO significantly decreased. Faster healing with PRGF.	2012/In vivo.
<b>ZOE</b>	Pal <i>et al</i> [14]	Comparative evaluation of zinc oxide eugenol versus gelatin sponge soaked in plasma rich in growth factor in the treatment of dry socket: An initial study.	Use of PRGF with gelatin sponge, and zinc oxide eugenol dressing in the treatment of dry socket.	Extraction sockets that were treated with PRGF gelatin sponge showed faster healing than sockets that were treated with ZOE, and the difference was statistically significant. But, ZOE helped relief pain faster than PRGF.	2013/Clinical trials.
<b>Ozone</b>	Ahmedi <i>et al</i> [16]	Efficiency of gaseous ozone in reducing the development of dry socket following surgical third molar extraction.	Use of ozone gas (O <sub>3</sub> ) to reduce the incidence of alveolar osteitis.	Dry socket was more prevalent in the group that didn't receive O <sub>3</sub> gas (16.67%) than the group that did receive O <sub>3</sub> gas (3.33%). The difference was statistically insignificant. Significant pain relief.	2016/Clinical trial-pilot study.

	Authors	Title	Management	Result	Year/Type of Study
Honey	Soni <i>et al</i> [20]	Effects of honey in the management of alveolar osteitis: a study.	Use of honey as a dressing to manage alveolar osteitis.	Faster healing and a significant decrease in C-reactive protein (CRP) levels	2016/Clinical trial
	Singh <i>et al</i> [19]	Honey a sweet approach to alveolar osteitis: a study.		Significant reduction in inflammation, pain. Significant reduction in levels of C-reactive protein (CRP).	2016/Clinical trial
Tranexamic Acid	Anand <i>et al</i> [17]	The efficacy of tranexamic acid in the reduction of incidence of dry socket.	Use of Tranexamic acid either orally or in Gel foam that's soaked in Tranexamic acid to reduce the incidence of alveolar osteitis.	Significant decrease in incidence of AO and faster healing.	2015/An Institutional double blind study.
Collagen Sponge	Cho <i>et al</i> [18]	Complication rates in patients using absorbable collagen sponges in third molar extraction sockets: a retrospective study.	Evaluation of the postoperative complication rates for absorbable type-I collagen sponge (Ateloplug; Bioland) used in third molar extraction.	The overall complication rate was 4.52%, with 3% experiencing surgical site infection (SSI), 1.14% showing alveolar osteitis, and 0.39% experiencing hematoma.	2015/A retrospective study.

## Discussion

Each one of the mentioned articles discussed different management options for alveolar osteitis. About 4 reviews discussed the use of different types of Chlorhexidine (CHX) as a management option. CHX is antiseptic and antimicrobial, it reduces the oral microbes in the wound and plays a primary role in stopping fibrinolysis by killing the bacteria that causes it [6]. Daly *et al* [3] studied the difference between CHX mouth rinses with different concentrations of 0.12% and 0.2%, and CHX gel with 0.2% concentration. These groups were compared with a placebo group. It was found that rinsing with CHX mouth rinses both before and after the extractions prevented about 42% of alveolar osteitis when compared to the placebo group. There was no significant difference in the results when both the concentrations of the mouth rinses (0.12% and 0.2%) were compared. It was also found that placing 0.2% CHX gel in the sockets after extractions prevented about 58% of alveolar osteitis compared to the placebo group [3].

Zhou *et al* [7] assessed the effect of 0.2% CHX gel in the prevention of dry socket, where it was established that the gel reduced the risk of dry socket by 56% compared to the placebo group. However, there was no significant difference between 0.2% CHX gel and 0.12% CHX mouthwash.

Sridhar *et al* [6] evaluated the perioperative use of 0.2% CHX gluconate as a preventive method for alveolar osteitis. The reduction of the complication was statistically significant, as there was no case of alveolar osteitis when CHX was used 1 day before and 7 days after the surgery, twice daily. However, Requena-Calla *et al* [8] found that there was no relationship between the type of gel that is administered intra-alveolarly and the incidence of alveolar osteitis, but there was a significant reduction in the pain levels in the sockets where chlorhexidine gel was applied compared to the placebo gel.

Antibiotics also kill and inhibit the growth of bacteria due to the antimicrobial and antibacterial properties, therefore they inhibit fibrinolysis and reduce the incidence of dry socket [9, 10]. Marcussen *et al* [10] reviewed the effect of single-dose antibiotics on surgical extractions where it was found that a single dose of penicillin V 0.8g administered before the surgical osteotomy extraction significantly reduced the incidence of alveolar osteitis.

Arteagoitia *et al* [9] assessed the use of amoxicillin with or without clavulanic acid in the prevention of dry socket after extractions and concluded that the combination of amoxicillin with clavulanic acid reduced the risk of the complication significantly compared to amoxicillin on its own.

Alvogyl and laser therapy are also included in the treatment options for alveolar osteitis. Alvogyl contains

eugenol which acts as an analgesic, iodoform which acts as an antimicrobial and butamben which acts as an anesthetic [11]. The laser has antimicrobial features and it also increases the speed and quality of wound healing [11]. Eshghpour *et al* [11] compared the effects of both these options to manage the complication. He found that alvogyl helped relief pain the quickest compared to the low power red laser (660nm wavelength), but on day 2 and after 12 hours, low power red laser was more efficient than alvogyl. Low level infrared laser (810nm wavelength) did not show any better results than both alvogyl and low power red laser.

Platelet-rich fibrin (PRF) and platelet-rich plasma (PRP) are also one of the management options. They act as bone grafting materials, which help in bone repair by stimulating mitogenic responses in the periosteum. They can also prevent foreign body inflammatory reactions [12, 1]. Hoaglin *et al* [13] used platelet-rich fibrin to treat localized osteitis in the sockets after extractions and as a result there was better healing and clot retention in the sockets and it greatly reduced the post-operative management time. PRF caused 90% reduction in the prevalence of alveolar osteitis. Dutta *et al* [12] compared the use of PRF, PRP and hydroxyapatite (HA) in the management of dry socket and found that there was significant reduction of pain and swelling and also better soft tissue healing when PRF and PRP were used, compared to HA.

Plasma rich in growth factors (PRGF) and zinc oxide eugenol (ZOE) can be used as a treatment option for dry socket. PRGF contains platelets, fibrinogen and growth factors like PDGF, TGF, PDEGF, PDAF, IGF-1 and PF-4, these factors increase angiogenesis, chemotaxis of macrophages and fibroblasts and therefore increase vascularity. They also enhance osteogenesis by increasing granulation tissue production and epithelialization. It is biocompatible and can also have antimicrobial features. ZOE has antiseptic and anesthetic properties as it depresses sensory receptors involved in pain perception [14]. Pal US *et al* [14] compared both of these treatments in a study and the result was that the use of PRGF resulted in better tissue healing than ZOE, but ZOE was faster in relieving pain. When compared to each other, the differences were statistically significant. Haraji *et al* [15] assessed the preventive effect of PRGF on alveolar osteitis (AO) and concluded that there was a significant reduction in AO occurrence and pain, and accelerated healing of the sockets.

Ozone gas is also effective in reducing the occurrence of AO. It has antibacterial features as it has the ability to form oxidizing free radicals and destroy the membranes and cell walls of bacteria. In addition, O<sub>3</sub> gas helps in synthesis of leukotrienes, interleukins and prostaglandins, which gives it anti-inflammatory properties. It can also improve delivery of oxygen to hypoxic tissues by stimulating oxygen metabolism [16]. Ahmedi *et al* [16] studied the efficacy of O<sub>3</sub> gas and found that there was a

significant reduction in inflammation, pain levels, post-operative recovery period, and there was also improved tissue healing. But there was no significant reduction in the occurrence of AO.

Tranexamic acid is an antifibrinolytic as it prevents the attachment of plasminogen and plasmin and therefore prevents the degradation of fibrin. Anand *et al* [17] evaluated the efficacy of Tranexamic acid either systemically or locally as a gel foam in comparison with a placebo, he concluded that there was a significant decrease in the incidence of AO and there was faster tissue healing in comparison with the placebo group. There was no difference between the local or systemic administration of the medicament.

Cho *et al* [18] suggested that the use of absorbable type-1 collagen sponge reduced the risk of AO but the result was not statistically significant. Type-1 collagen is a fibrillar collagen which supports bone matrix. It enhances hemostasis, facilitates granulation tissue formation, and protects the wound surface.

Recently, Soni *et al* [20] and Singh *et al* [19] evaluated the effects of honey as a dressing as a management option for AO. Honey is hyperosmolar and due to that it can reduce the edema. It forms a physical barrier, keeps moist environment and prevent bacterial colonization due to its viscous property. It is also bactericidal due to its low PH and the hydrogen peroxide content. Due to its high nutrient content, it promotes rapid epithelialization. As a result, honey significantly reduced C-reactive protein levels and thus reduced inflammation and pain, it also helped in accelerated tissue healing.

According to all the results that we reviewed, the percentages of success were better when substances that accelerated the healing process and regeneration of the bone were used like PRGF and PRF (90% reduction rate), in comparison with the substances that acted as antibacterials and antimicrobials like CHX (ranging from 42% to 58% being the maximum reduction rate). This is due to the fact that the main cause of AO is not from bacterial origin. Therefore we can say that the best results would be achieved if both those management options were used together at the same time.

## Conclusion

In this study, and according to the literature [1-32], it was concluded that there is no specific management that could be rated as the best to treat dry socket, due to the lack of evidence to support the use of one management over the other, although there are many options that can help manage it and have proved to be highly effective recently and until today. Further investigations on larger samples need to be done in order to reach the main cause and the best management for AO. However, the primary aim of a practitioner in a dental clinic is to relief pain, reduce post-operative time and promote healing to preserve the socket.

## Funding

None.

## Conflict of Interests

The authors declare no conflict of interest.

## Role of Author and Co-authors

Nur Hatab (concept of the paper and editing)  
Jenan Yahya (material collection and writing)  
Sara Alqulaihi (material collection and writing)

## Ethical approval

Approval was obtained from the Medical Ethics Committee of the RAK Medical and Health Sciences University.

## Patient Consent

Not needed.

## Acknowledgements

None

## References

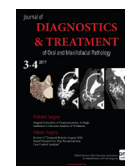
- Kolokythas A, Olech E, Miloro M. Alveolar osteitis: a comprehensive review of concepts and controversies. *Int J Dent* **2010**;249073. <http://doi.org/10.1155/2010/249073xxxxxxx>.
- Bowe DC, Rogers S, Stassen LF. The management of dry socket/alveolar osteitis. *J Ir Dent Assoc* **2011**;57(6):305–10.
- Daly B, Sharif MO, Newton T, Jones K, Worthington HV. Local interventions for the management of alveolar osteitis (dry socket). *Cochrane Database Syst Rev* **2012**;12:CD006968. <http://doi:10.1002/14651858.CD006968.pub2>.
- Eshghpour M, Nejat AH. Dry socket following surgical removal of impacted third molar in an Iranian population: incidence and risk factors. *Niger J Clin Pract* **2013**;6(4):496–500.
- Tarakji B, Saleh LA, Umair A, Azzeghaiby SN, Hanouneh S. Systemic review of dry socket: aetiology, treatment, and prevention. *J Clin Diagn Res* **2015**;9(4):ze10–3.
- Sridhar V, Wali GG, Shyla HN. Evaluation of the perioperative use of 0.2% chlorhexidine gluconate for the prevention of alveolar osteitis after the extraction of impacted mandibular third molars: a clinical study. *J Maxillofac Oral Surg* **2011**;10(2):101–11.
- Zhou J, Hu B, Liu Y, Yang Z, Song J. The efficacy of intra-alveolar 0.2% chlorhexidine gel on alveolar osteitis: a meta-analysis. *Oral Dis* **2017**;23(5):598–608.
- Requena-Calla S, Funes-Rumiche I. Effectiveness of intra-alveolar chlorhexidine gel in reducing dry socket following surgical extraction of lower third molars. A pilot study. *J Clin Exp Dent* **2016**;8(2):e160–3.
- Arteagoitia M-I, Barbier L, Santamaría J, Santamaría G, Ramos E. Efficacy of amoxicillin and amoxicillin/clavulanic acid in the prevention of infection and dry socket after third molar extraction. A systematic review and meta-analysis. *Med Oral Patol Oral Cir Bucal* **2016**;21(4):e494–e504.
- Marcussen KB, Laulund AS, Jorgensen HL, Pinholt EM. A systematic review on effect of single-dose preoperative antibiotics at surgical osteotomy extraction of lower third molars. *J Oral Maxillofac Surg* **2016**;74(4):693–703.
- Eshghpour M, Ahrari F, Najjarkar N-T, Khajavi M-A. Comparison of the effect of low level laser therapy with alvogyl on the management of alveolar osteitis. *Med Oral Patol Oral Cir Bucal* **2015**;20(3):e386–92.
- Dutta SR, Passi D, Singh P, Sharma S, Singh M, Srivastava D. A randomized comparative prospective study of platelet-rich plasma, platelet-rich fibrin, and hydroxyapatite as a graft material for mandibular third molar extraction socket healing. *Natl J Maxillofac Surg* **2016**;7(1):45–51.
- Hoaglin DR, Lines GK. Prevention of localized osteitis in mandibular third-molar sites using platelet-rich fibrin. *Int J Dent* **2013**;875380. <http://doi.org/10.1155/2013/875380>.
- Pal US, Singh BP, Verma V. Comparative evaluation of zinc oxide eugenol versus gelatin sponge soaked in plasma rich in growth factor in the treatment of dry socket: an initial study. *Contemp Clin Dent* **2013**;4(1):37–41.
- Haraji A, Lassemi E, Motamedi MH, Alavi M, Adibnejad S. Effect of plasma rich in growth factors on alveolar osteitis. *Natl J Maxillofac Surg* **2012**;3(1):38–41.
- Ahmedi J, Ahmedi E, Sejfiya O, Agani Z, Hamiti V. Efficiency of gaseous ozone in reducing the development of dry socket following surgical third molar extraction. *Eur J Dent* **2016**;10(3), 381–5.
- Anand KP, Patro S, Mohapatra A, Mishra S. The efficacy of tranexamic acid in the reduction of incidence of dry socket: an institutional double blind study. *J Clin Diagn Res* **2015**; 9(9):ZC25–8.
- Cho H, Jung H-D, Kim B-J, Kim C-H, Jung, Y-S. Complication rates in patients using absorbable collagen sponges in third molar extraction sockets: a retrospective study. *J Korean Assoc Oral Maxillofac Surg* **2015**;41(1):26–9.
- Singh V, Pal US, Singh R, Soni N. Honey a sweet approach to alveolar osteitis: A study. *Natl J Maxillofac Surg* **2014**;5(1):31–4.
- Soni N, Singh V, Mohammad S, Singh RK, Pal US, Singh R, Pal M. Effects of honey in the management of alveolar osteitis: a study. *Natl J Maxillofac Surg* **2016**;7(2):136–47.
- Summers A. Emergency management of alveolar osteitis. *Emerg Nurse* **2011**; 19(8):28–30.
- Taberner-Vallverdú M, Nazir M, Sánchez-Garcés MÁ, Gay-Escoda C. Efficacy of different methods used for dry socket management: a systematic review. *Med Oral Patol Oral Cir Bucal* **2015**;20(5):e633–9.
- Yengopal S, Mickenautsch S. Chlorhexidine for the prevention of alveolar osteitis. *Int J Oral Maxillofac Surg* **2012**;41(10):1253–64.
- Sharif MO, Dawoud BE, Tschlakai A, Yates JM. Interventions for the prevention of dry socket: an evidence-based update. *Br Dent J* **2014**;217(1):27–30.
- Ramos E, Santamaría J, Santamaría G, Barbier L, Arteagoitia I. Do systemic antibiotics prevent dry socket and infection after third molar extraction? A systematic review and meta-analysis. *Oral Surg Oral Med Oral Pathol Oral Radiol* **2016**;122(4):403–25.
- Rakhshan V. Common risk factors for postoperative pain

## MANAGEMENT OF ALVEOLAR OSTITIS: A LITERATURE REVIEW

- following the extraction of wisdom teeth. *J Korean Assoc Oral Maxillofac Surg* **2015**;41(2):59–65.
27. Motamedi MRK. To irrigate or not to irrigate: immediate postextraction socket irrigation and alveolar osteitis. *Dent Res Journal (Ishafan)* **2015**;12(3):289–90.
  28. Akinbami BO, Godspower T. Dry socket: incidence, clinical features, and predisposing factors. *Int J Dent* **2014**:796102. <http://doi.org/10.1155/2014/796102>.
  29. Tymofieiev OO, Ushko NO, Tymofieiev OO, Yarifa MO, Fesenko IeI. Prevention of inflammatory complications upon surgeries in maxillofacial region. *J Diagn Treat Oral Maxillofac Pathol* **2017**;1:105–12.
  30. Barona-Dorado C, González-Regueiro I, Martín-Ares M, Arias-Irimia O, Martínez-González JM. Efficacy of platelet-rich plasma applied to postextraction retained lower third molar alveoli. A systematic review. *Med Oral Patol Oral Cir Bucal* **2014**;19(2):e142–8.
  31. Hatab N, Patel T, Bakkour A. The efficiency of rhBMP-7 in oral and maxillofacial bone defects: a systematic review. *J Diagn Treat Oral Maxillofac Pathol* **2017**;1:77–88.
  32. Rodríguez-Pérez M, Bravo-Pérez M, Sánchez-López JD, Muñoz-Soto E, Romero-Olvid MN, Baca-García P. Effectiveness of 1% versus 0.2% chlorhexidine gels in reducing alveolar osteitis from mandibular third molar surgery: a randomized, double-blind clinical trial. *Med Oral Patol Oral Cir Bucal* **2013**;18(4):e693–e700.

Hatab N, Yahya J, Alqulaihi S.  
Management of alveolar osteitis in dental practice: a literature review.  
*J Diagn Treat Oral Maxillofac Pathol* **2017**;1:147–155.  
<http://dx.doi.org/10.23999/j.dtopm.2017.3-4.7>





# Assessment of the Relationship of the Frankfort Horizontal Plane and the Orbitomeatal Line With Attainment of the Natural Head Position\*

Renata Laís Almeida Cruz<sup>1,\*</sup>, Giovanni Gasperini<sup>2,\*</sup>

Department of Oral and Maxillofacial surgery. UFG (The Federal University of Goiás) Hospital, Goiânia, Goiás, Brazil.

<sup>1</sup> PGY 3. Surgical resident in the UFG residency program of Oral and Maxillofacial surgery.

<sup>2</sup> PhD, Prof and chief, department of Oral and Maxillofacial surgery. UFG Hospital.

## ABOUT ARTICLE

### Article history:

Paper received 15 July 2017

Accepted 28 July 2017

Available online 28 December 2017

### Keywords:

Natural head position

Frankfort horizontal plane

True vertical line

Orbitomeatal line

True horizontal line

## ABSTRACT

The diagnosis of dentofacial deformities and the choice of ortho-surgical treatment depend on the correct positioning of the head at the time of registration in 2D or 3D, called the natural head position (NHP). We selected 32 subjects from Arnett class I and obtained their frontal and lateral photographs in NHP to evaluate the relationship and stability between the orbitomeatal line, the Frankfort horizontal plane and the face midline with the true vertical line (TVL) and the true horizontal line (THL). Mean and standard deviation of angulation were obtained for all cited variables, with the results leading to the conclusion that the orbitomeatal line and the Frankfort horizontal plane can be used to obtain the NHP in an individualized way.

© 2017 OMF Publishing, LLC. This is an open access article under the CC BY licence (<http://creativecommons.org/licenses/by-nc/4.0/>).

## Introduction

Facial esthetics can influence psychological factors, social development, and the quality of life of patients. The contour of the soft tissue, the skeletal relationships, and the functional occlusion should be considered in the diagnosis and planning of ortho-surgical treatment. Therefore, orthodontic treatment and orthognathic surgery have the objective of correcting facial and skeletal facial discrepancies, and altering the facial profile, in order to achieve satisfactory esthetic and functional results in patients [1].

Anthropomorphic studies of the head for investigation or clinical evaluation require a standard orientation of the skull as a reference. In 1884, the concept that the Frankfort horizontal plane could be used as the horizontal intracranial reference was adopted, which served as a guide for the correct positioning of the head.

Since 1950, the perception that the Frankfort plane may not always be horizontal when the natural head position (NHP) is adopted has resulted in a greater interest in obtaining the NHP for cephalometric measurements [2-4].

The NHP was first described in 1862 and occurs when a patient is looking at a distant point at eye level, which implies that the visual axis is horizontal [5]. However, it was only during the 1950s that the term “natural head position” was introduced into orthodontic assessment, considered to be a stable, reproducible position that seems to correlate better with the actual craniofacial morphology, in addition to being related to future patterns of skeletal growth and type of respiration [6].

Obtaining the NHP has the advantage that it can be associated with extra-cranial reference lines for cephalometric analysis [3]. According to Arnett and McLaughlin [7], these references are the true vertical line that is drawn along the subnasal area perpendicular to the NHP, and the true horizontal line that is parallel to the ground.

NHP and natural head posture are terms that are constantly used as synonyms. However, more specifically, the NHP determines the relationship of the head to the TVL and the natural posture of the head determines the relationship of the head to the cervical spine [3, 8].

The Frankfort horizontal plane (porion-orbital) is

\*This manuscript has not been presented

\* Corresponding authors:

Department of Oral and Maxillofacial surgery.

UFG Hospital, Primeira Avenida, s/n – Setor Universitário, 74605-020 Goiânia, Goiás, Brazil

Renata Laís Almeida Cruz. Tel.: +55 62 986600789

E-mail: [dra.renata.ctbmf@gmail.com](mailto:dra.renata.ctbmf@gmail.com)

Instagram: [renataalmeidacruz](https://www.instagram.com/renataalmeidacruz)

Giovanni Gasperini. Tel.: +55 62 981228511

E-mail: [gasperinibuco@gmail.com](mailto:gasperinibuco@gmail.com)

used to obtain cephalograms oriented parallel to the ground. The technique is reproducible and provides a clear view of cephalograms, with few projection errors, but can modify the patient's natural posture and consequently also cause variations in the NHP of each person [7, 9].

When taking cranial radiographs, there are other reference lines that can be used in addition to the Frankfort horizontal plane. The orbitomeatal line, located between the outer corner of the eye and the midpoint of the patient's tragus, is one of them. Used for the clinical positioning of the patient prior to radiography, it forms an angle of approximately 10 degrees with the Frankfort horizontal plane [10-13].

The objectives of this study are to evaluate the relationships of the Frankfort horizontal plane and the orbitomeatal line with the TVL and THL and to evaluate the relationship of the face midline with the TVL, in order to determine whether there is a standard measure to achieve the NHP for all patients.

### Materials and Methods

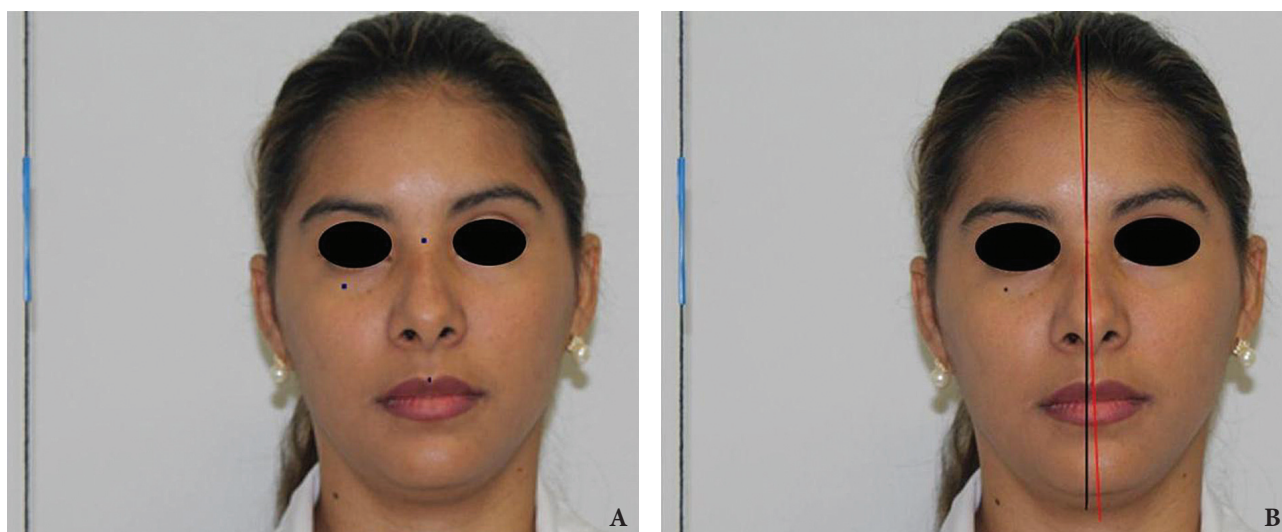
This was a comparative cross-sectional study, approved by the Ethics Committee of the Clinical Hospital of the Federal University of Goiás. It initially involved the evaluation of 85 subjects randomly selected from the community, from June 2016 to December 2016, who were older than 18 years of age and had complete dentition to at least the first molars. Those with a scar

in the facial region or a deformity or postural difficulty were excluded.

Frontal and profile photographs of each subject were obtained with a Canon EOS Rebel T5 DSLR digital camera, 18MP, in the same environment and by the same operator, using a white background and a plumb representing the TVL. At the moment of photographing, the subjects were standing with a NHP, which was obtained by directing them to look at the image of their own pupils in a mirror placed 2 m away, with shoulders and head relaxed. The camera was positioned on a tripod, 2 m away from each subject, at face level, with a central focus centered on the point of the greatest prominence of the zygomatic bone in the profile photographs and at the tip of the nose in the frontal photographs. The operator did not perform accommodation maneuvers or postural modification on the subjects.

Markings with a blue tip pen were made on the following anatomical landmarks of the subject:

1. Mean point of the distance between the medial corners of the eyes and the point located in the upper lip filtrum, for the facial midline (Fig 1A, B).
2. Orbital craniometric point and superior point of the external acoustic meatus, for the Frankfort horizontal plane.
3. Skin point of the outer corner of the eye and tragus midpoint for orbitomeatal line tracing (Fig 2A, B).

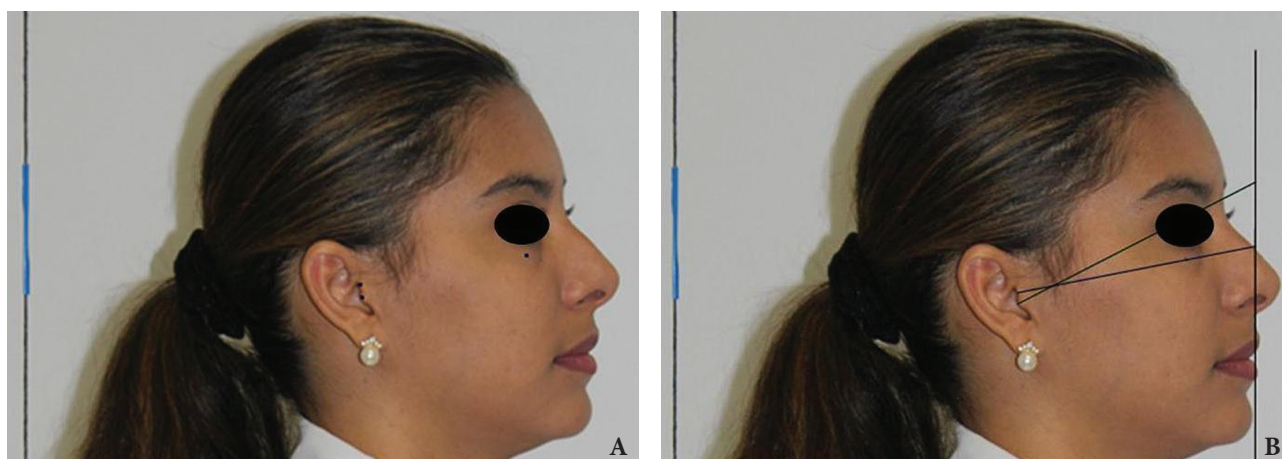

**FIGURE 1.** (A) Markings (dots) in the mean point of the distance between the medial corners of the eyes and the point located in the upper lip filtrum. (B) Tracing of the facial midline (red line) and the TVL (black line).

All photographs included a 7-cm marking device on the plumb and the distance between the tragus and the outer corner of the eye was also recorded to aid in reproducing the original size of the profile photograph at the time of the computerized analysis of data. At the

end of the recording, all photographs were scanned and analyzed in the AutoCAD® measurement and drawing program, version 2010.

The orbitomeatal line, the Frankfort horizontal plane and the midline of the face were identified by using



**FIGURE 2.** (A) Markings (dots) in the orbital craniometric point, the superior point of the external acoustic meatus, the skin point of the outer corner of the eye and the tragus midpoint. (B) Tracing of the orbitomeatal line (*upper line*) and the Frankfort horizontal plane (*lower line*).

tracing and angulation tools. The TVL was identified by transferring the line formed by the plumb, passing through the middle intercantal point in the frontal photograph, and passing through the subnasal point in the profile photo.

Arnett's cephalometric analysis of soft tissue (CAST) was performed and it was determined that only 32 subjects from the 85 chosen initially had the Arnett Class I-compatible facial profile, which is considered to be the most esthetic and harmonious; therefore, 53 subjects were excluded from the final sample.

The following angles were obtained in the AutoCAD® program, version 2010:

#### 1. Profile photograph:

- a. Angle formed between orbitomeatal line and true vertical line (OML-TVL).
- b. Angle formed between Frankfort horizontal plane and true vertical line (FHP-TVL).
- c. Angle formed between orbitomeatal line and true horizontal line (OML-THL).
- d. Angle formed between Frankfort horizontal plane and true horizontal line (FHP-THL).
- e. Angle formed between orbitomeatal line and Frankfort horizontal plane (OML-FHP).

#### 2. Frontal photograph:

- a. Angle formed between face midline and true vertical line (FML-TVL).

A sample calculation was performed to compare the means of all angulation variables and the CAST variables that had been calculated between male ( $n = 11$ ) and female ( $n = 21$ ) subjects; the calculation was of the two-tailed type, with absolute error of 5%, and effect of the delineation of 3.0 (determined from data of the present study) totaling test power of 100%. The analysis was performed using G\* Power® software

version 3.1.9.2.

To perform the statistical analysis, the collected data were tabulated and stored using a spreadsheet, specially developed for this research, of the Microsoft Office Excel® program, version 2013. Statistical analysis of the variables was performed in the statistical package STATA® version 12.0.

For descriptive analysis, continuous variables were expressed as mean, standard deviation, and 95% confidence interval of the mean. Then, the normality of the continuous variables was tested using the Shapiro–Wilk test. Subsequently, we compared the means by classifying subjects by sex (male/female) using the Student's *t* or Mann–Whitney test. Statistically significant data were those that presented a *P* value  $< 0.05$ .

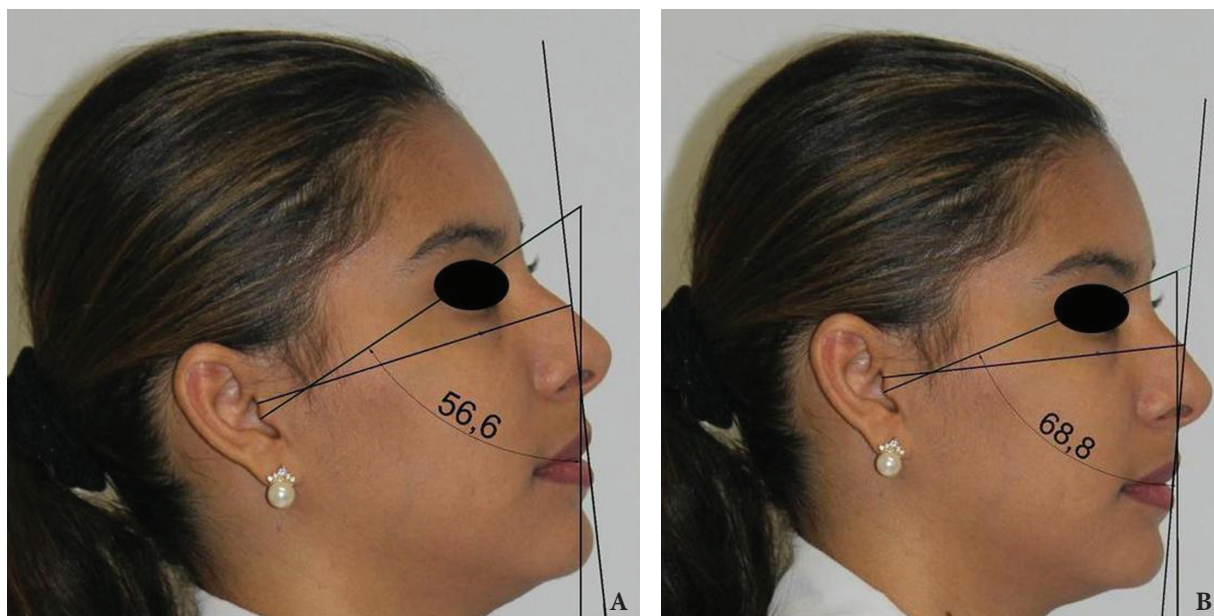
A simulation was performed with the values obtained in a subject using the AutoCAD® software, version 2010, by adapting the position of the photograph to the mean angulation obtained for OML-TVL and FHP-TVL, and to the higher and lower recorded values of both variables to determine the true clinical impact of these variables in the antero-posterior projection of important structures for the cephalometric analysis of soft tissue (Figs 3 and 4).

## Results

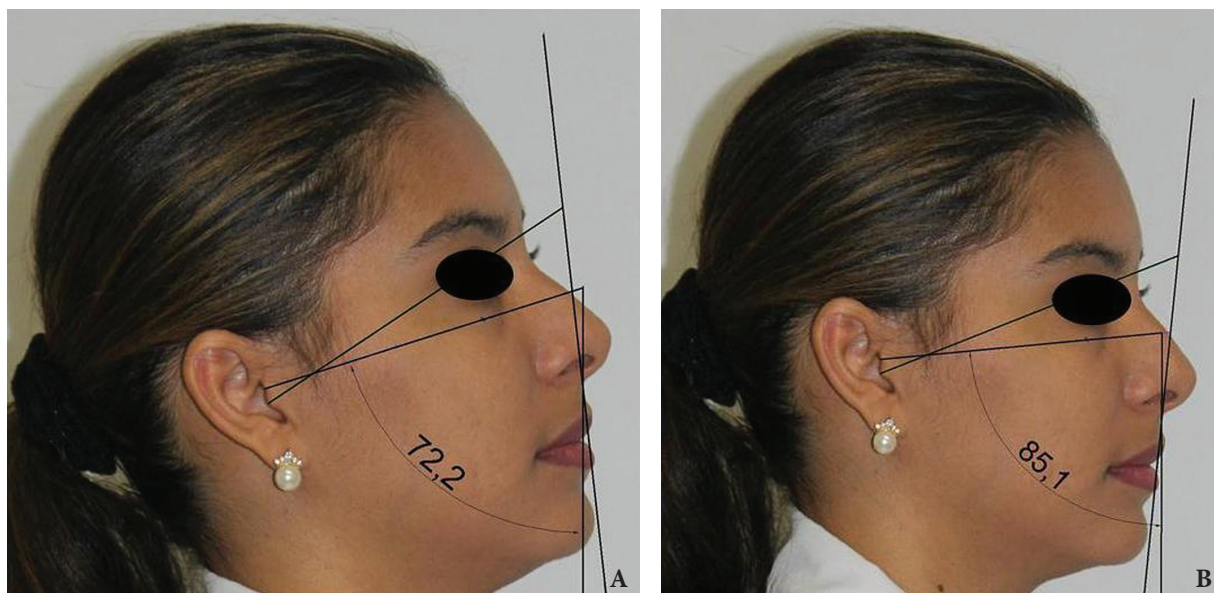
The cephalometric analysis of soft tissue performed on the 32 subjects was consistent with the values established for Arnett Class I, where prominence of the upper lip (UL), lower lip (LL), and soft-tissue pogonium (PG) in relation to the TVL expresses a more harmonic and esthetic facial profile (Table 1).

The angulation values obtained in the analysis of the variables showed different amplitudes between the lowest and highest values recorded (Table 2).

The results of the statistical analysis on the achievement of normality in the male and female genders



**FIGURE 3.** Simulation performed with the values obtained in OML-TVL. (A) Adapting the position of the photograph to the lower value recorded. (B) Adapting the position of the photograph to the higher value recorded.



**FIGURE 4.** Simulation performed with the values obtained in FHP-TVL. (A) Adapting the position of the photograph to the lower value recorded. (B) Adapting the position of the photograph to the higher value recorded.

**TABLE 1.** Mean and standard deviation in Arnett's CAST and in this study.

	Female		Male	
	Arnett (mm)	Obtained (mm)	Arnett (mm)	Obtained (mm)
UL- TVL	3.7 ± 1.2	3.5 ± 0.7	3.3 ± 1.7	2.7 ± 0.8
LL- TVL	1.9 ± 1.4	1.7 ± 0.8	1.0 ± 2.2	0.4 ± 1.0
PG - TVL	-2.6 ± 1.9	-2.5 ± 1.1	-3.5 ± 1.8	-3.0 ± 1.1

showed that there were no statistically significant differences when comparing the values of most of the angulation measures between the two genders. When the t-test was performed with a significance level of 0.05, it was found that the only measures that showed a notable difference between males and females were the relationship of upper lip and TVL and the relationship of lower lip and TVL, but both values remained within

**TABLE 2.** Angulation values obtained in the analysis of the variables and difference between the lowest and highest values recorded.

Variable	Average value	Difference
OML -TVL	67.7°	12.2°
FH - TVL	82.5°	12.9°
OML - THL	22.2°	12.2°
FH - THL	7.4°	12.9°
OML - FH	14.8°	4.6°
FML - TVL	1.0°	3.7°

parameters considered normal by Arnett (Table 3).

The simulation performed with the photograph of a subject showed that the different angulation values of the OML-TVL and FHP-TVL variables can cause a small but important difference at the time of the cephalometric analysis of soft tissue when the patient is positioned according to the data obtained in this study (Table 4).

**TABLE 3.** Results of the statistical analysis showing mean, standard deviation and trust interval for every variable analyzed.

Variable	Total n = 32			Male n = 11			Female n = 21			P Value
	M	SD	TI	M	SD	TI	M	SD	TI	
OML-TVL	67.8	3.1	66.7-68.9	68.8	3.2	66.6-70.9	67.3	3.0	65.9-68.7	0.197
FH - TVL	82.5	2.9	81.4-83.5	83.0	3.8	80.4-85.5	82.2	2.5	81.1-83.3	0.517
OML - THL	22.2	3.1	21.1-23.3	21.1	3.2	19.1-23.3	22.7	3.0	21.3-24.1	0.197
FH - THL	7.5	2.9	6.4-8.5	7.0	3.8	4.4-9.5	7.7	2.5	6.6-8.8	0.517
OML - FH	14.8	1.4	14.3-15.3	14.4	1.1	13.7-15.1	15.1	1.5	14.4-15.8	0.161
FML - TVL	1.1	1.1	0.7-1.5	1.1	1.2	0.3-1.9	1.1	1.1	0.6-1.6	0.740**
UL - TVL	3.2	0.8	2.9-3.5	2.7	0.8	2.2-3.2	3.5	0.7	3.2-3.8	0.010
LL - TVL	1.3	1.0	0.9-1.7	0.4	1.0	-0.3-1.1	1.7	0.8	1.3-2.1	<0.001
PG - TVL	-2.7	1.0	-3.1- -2.3	-3.0	1.0	-3.7 - -2.3	-2.5	1.1	-3.0 - -2.0	0.283

**TABLE 4.** Results of the simulation performed with the photograph of a subject.

Table 4 a. Simulation performed with LOM - TVL values			
	Lower value 56.6°	Mean 62.7°	Higher value 68.8°
CAST (mm)			
UL - TVL	3.6	2.6	1.5
LL - TVL	4.6	1.4	-1.2
PG - TVL	4.7	-1.4	-5.5

Table 4 b. Simulation performed with FH - TVL values			
	Lower value 72.2°	Mean 78.7°	Higher value 85.1°
CAST (mm)			
UL - TVL	3.5	2.6	1.3
LL - TVL	4.5	1.4	-1.5
PG - TVL	4.6	-1.4	-6.3

## Discussion

The Frankfort horizontal plane is one of the clinical cephalometric references used more frequently to obtain the NHP. Upon performing teleradiography, the patient is positioned in the cephalostat with the Frankfort horizontal plane, parallel to the ground, which means that, in the image examination, the Frankfort horizontal plane can be traced parallel to the THL [10]. However, in 1993, Arnett and McLaughlin [7] reported that no person has the Frankfort horizontal plane parallel to the ground and there may be patients in the NHP, but with the Frankfort horizontal plane tilted up or down. It is for this reason that the objective of this study was to evaluate the NHP as a better reference related to the craniofacial morphology of subjects.

Obtaining the NHP can be achieved in different ways. Verma *et al* in 2012 [3] mentioned in their work the study by Solow and Tallgren performed in 1971, in which the patient was asked to walk, perform downward oscillations of the head back and forth until reaching the standing position of “self-equilibrium” and then look at the reflection of his eyes in a mirror 200 cm away. In 1988, Cooke and Wei [14] studied and compared the previous method with another method in which no external reference was used and concluded that reproducibility was better with the mirror method (1.9°) than without it (2.7°). The study by Bister *et al* in 2002 [15], contradicted previous ones by eliminating the previous procedures of walking and oscillation of the patient’s head. The operator was allowed to interfere and repeat the procedure if the patient’s head was clearly not in the NHP. These authors found reproducibility of 1.4°. In 2015, Tian *et al* [16] compared the previous methods and added a last method of obtaining the NHP called “estimated position,” and the positioning criteria were that there could be no flexion or extension of the head when observing the side view of the subject, and there could be no obvious inclination from head to the sides when looking at the subject from the front, finding in this method greater reproducibility with a value of 0.9° when compared with the mirror method. In carrying out this study, we opted for the method of Bister *et al* reported in 2002 [15], using the mirror method without previous oscillatory movements, but contrary to the author’s guidelines there was no interference by the operator, in order to evaluate the subject’s estimated position when positioning for photography as proposed by Tian *et al* (2015) [16].

Damstra *et al* (2010) [6] emphasized the importance of recording and studying the NHP in the three planes of space and, from this, Weber *et al* (2013) [17] stated that the natural position of the head and the inclinations in the coronal axis of individuals are influenced by the vestibulo-ocular and vestibulospinal reflexes, demonstrating that there is less variability of inclination in the coronal axis than in the sagittal axis. To complement this, Liu *et al*

(2015) [18] reported that the gravitational response of the inner ear causes interaction among the head position, the visual axis, the posture of the head, and the muscles. In this study, an average inclination of 1.1° was found between the face midline and the TVL, with a standard deviation of 1.1°. However, the average OML-TVL was 67.8° with standard deviation of 3.1°, and the average FHP-TVL was 82.5° with standard deviation of 2.9°, demonstrating similarity to the findings of Weber *et al* (2013) [17], showing that there is less inclination in the coronal axis than in the sagittal axis due to the adequate balance among muscular components, visual axis, and inner ear in a homogeneous sample of participants with a harmonic facial profile.

Ramirez *et al* (2013) [8] performed a study in which the relationship between FHP and THL was 4.4° in men and 3.1° in women without distinction of facial pattern; a result similar to that was obtained by Cooke and Wei in 1988 [14] in their study of the NHP in Chinese children, which was 5.2° in males and 4° in females, also being performed without distinction of facial pattern in their sample. Both studies contradict the work of Lundström and Lundström (1995) [19], who studied the NHP in 79 British children without specific facial pattern, finding statistically significant differences between the genders in the angle formed by FHP and THL, with values of 2.6° for males and 4.1° for females. The discrepancy of the value obtained for males was higher than in the other studies. In contrast to the studies of these authors, the current study has greater homogeneity of the sample when considering only the Arnett Class I facial pattern in the sample. The result for the same angle in this study has mean values of 7.0° for men and 7.7° for women, showing no significant difference between males and females, which is also an important discrepancy when compared with the values obtained in the cited studies.

Ferragio *et al* (1993) [20], in a study on craniofacial morphometry, performed evaluations of 108 adult subjects, including 57 men and 51 women, without distinction of facial pattern, by taking frontal and lateral facial photographs. The results obtained when evaluating the angle between the Frankfort horizontal plane and the THL were 13° for men and women who were standing and 5° for men and 8° for women who were sitting. This demonstrates that people hold their heads higher when standing. The present study obtained results differing from these, presenting an average angulation of 7.5° with a standard deviation of 2.9° for men and women who were standing at the time of being photographed. This discrepancy may be related to the homogeneity of the sample in this study when compared with the study by Ferragio *et al* (1993) [20], which included participants with different facial patterns, who compensated the head position in the photograph.

The orbitomeatal line is a reference used less frequently when positioning for and performing cranial

radiography. It was found that this line forms an angle of approximately  $10^\circ$  with the Frankfort horizontal plane when studied in radiographs (10–13). This study evaluates the same angulation, but in photography, and the result shows an average value of  $14.8^\circ$  with a standard deviation of  $1.4^\circ$ .

In 1992, Lundström and Lundström [21] took photographs of 52 subjects aged between 10 and 14 years in the NHP. As in the current study, a vertical line was also recorded, obtained by installing a plumb, representing the TVL. Lundström and Lundström also performed radiographic recording of each subject and demonstrated that the reproducibility of the NHP in studies using photographic and radiographic evaluation was approximately  $2^\circ$ . In 1958, Moorrees and Kean [4] studied the reproducibility of the NHP on radiographs, obtaining results of approximately  $1.5^\circ$ . This contrasts to the findings of Kim *et al* in 2014 [22], who performed evaluation of the NHP on photographs, but obtained similar results with reproducibility of approximately  $2^\circ$  and standard deviation of less than  $1^\circ$ . From this study, Kim *et al* (2014) [22] determined that the acceptable standard deviation to be clinically insignificant is  $2^\circ$ .

Therefore, small changes in the protocol to obtain the NHP can have considerable effects on possible facial discrepancies. Similarly, the data analysis of this study demonstrated that the angulation values of OML-TVL and FHP-TVL show standard deviations of  $3.1^\circ$  and  $2.9^\circ$ , respectively, showing values that were slightly higher than the proposed clinically acceptable standard deviation reported by Kim *et al* in 2014 [22].

Like the present study, many others have investigated the variability of cephalometric planes observed on radiographs, such as the Frankfort horizontal plane, saddle-nasion, or Camper plane, with the THL or the TVL to help determine the NHP. In 2012, Verma *et al* [3] in their study of NHP concluded that the inclination of all intracranial reference lines is subject to biological variation, and therefore they are unsuitable for meaningful cephalometric analysis. These authors have reported that some patients consistently assume a modified NHP, often in an attempt to mask a Class II or Class III facial pattern. For example, a subject with Class II mandibular retrognathism can usually lean back the head to mask the Class II appearance. It is thus, necessary for the clinician to identify these subjects in order to adjust their head position to the registry of the NHP and thus avoid inappropriate values in the cephalometric analysis of bone and soft tissues. This head position is termed “clinician-determined” and provides a more reliable basis for cephalometric analysis. In 2014, Barbera *et al* [23] reported the difficulty of using a single plane to correct the position of the head because its location, marking, and angulation may vary between subjects.

This study verified that the NHP varies in each

person, so it is an individual and biological characteristic that cannot be obtained by assigning an absolute mean to all patients for the purposes of orthognathic surgery planning. It is known that, by performing the wrong positioning at the time of diagnosis and planning, the final result will also be wrong.

The relationship obtained in this study between the orbitomeatal line and the Frankfort horizontal plane with the TVL and the THL has sufficient stability to be an auxiliary method that guides the positioning of the head in cases of extreme discrepancies. Likewise, the relationship between the midline of the face and the TVL demonstrates stability in the coronal axis at the time of obtaining the NHP, providing a suitable reference for its use when positioning the patient’s head and thus avoiding extreme inclinations.

## References

1. Chen CM, Lai S, Tseng YC, Lee KT. Simple technique to achieve a natural head position for cephalography. *Br J Oral Maxillofac Surg* **2008**;46:677–8.
2. Chiu CSW, Clark RKF. Reproducibility of natural head position. *J Dent* **1991**;19:130–1.
3. Verma SK, Maheshwari S, Gautam SN, Prabhat KC, Kumar S. Natural head position: key position for radiographic and photographic analysis and research of craniofacial complex. *J Oral Biol Craniofac Res* **2012**;1:46–9.
4. Moorrees CFA, Kean MR. Natural head position, a basic consideration in the interpretation of cephalometric radiographs. *Am J Phys Anthropol* **1958**;16:213–34.
5. Usumeze S, Orhan M. Reproducibility of natural head position measured with an inclinometer. *Am J Orthod Dentofacial Orthop* **2003**;123:451–4.
6. Damstra J, Fourie Z, Ren Y. Simple technique to achieve a natural position of the head for cone beam computed tomography. *Br J Oral Maxillofac Surg* **2010**;48:236–8.
7. Arnett GW, McLaughlin RP. Facial and dental planning for orthodontists and oral surgeons. 1st ed. London: Elsevier/Mosby; **2004**.
8. Ramírez DM, Jiménez JC, Ramírez EG, Paniagua HJ, Ruidíaz VC. Discrepancies in cephalometric measurements in relation to natural head position. *Rev Mex de Ortodoncia* **2013**;1:27–32.
9. Cassi D, De Biase C, Tonni I, Gandolfini M, Di Blasio A, Piancino MG. Natural position of the head: review of two-dimensional and three-dimensional methods of recording. *Br J Oral Maxillofac Surg* **2016**;54:233–40.
10. Vinita M. Atlas of roentgenographic positions, Vol. 2, 3rd ed. St. Louis: C. V. Mosby CO; **1967**.
11. Jacobi CA, Paris DQ. Textbook of radiologic technology. 6th ed. St. Louis: C. V. Mosby; **1977**.
12. Bontrager KL, Lampignano JP. Textbook of radiographic positioning and related anatomy. 8th ed. Philadelphia: Elsevier/Mosby; **2013**.
13. Swallow RA, Naylor E, Roebuck EJ, Whitley AS. Clark’s Positioning in Radiography. 11 ed. New York: William Heinemann; **1986**.
14. Cooke MS, Wei SHY. The reproducibility of natural head posture: a methodological study. *Am J Orthod Dentofacial Orthop* **1988**;93:280–8.

## CHOICE OF ORTHO-SURGICAL TREATMENT DEPENDS ON THE NATURAL HEAD POSITION

15. Bister D, Edler RJ, Tom DDM, et al. Natural head posture – considerations of reproducibility. *Eur J Orthod* **2002**; 24:457–70.
16. Tian K, Li Q, Wang X, Liu X, Wang X, Li Z. Reproducibility of natural head position in normal Chinese people. *Am J Orthod Dentofacial Orthop* **2015**;148:503–10.
17. Weber DW, Fallis DW, Packer MD. Three-dimensional reproducibility of natural head position. *Am J Orthod Dentofacial Orthop* **2013**;143:738–44.
18. Liu XJ, Li QQ, Pang YJ, Tian KY, Xie Z, Li ZL. Modified method of recording and reproducing natural head position with a multicamera system and a laser level. *Am J Orthod Dentofacial Orthop* **2015**;147:781–7.
19. Lundström F, Lundström A. The Frankfort horizontal as a basis for cephalometric analysis. *Am J Orthod Dentofacial Orthop* **1995**;107:537–40.
20. Ferragio VF, Sforza C, Miani A, Tartaglia G. Craniofacial morphometry by photographic evaluations. *Am J Orthod Dentofacial Orthop* **1993**;103:327–37.
21. Lundström F, Lundström A. Natural head position as a basis for cephalometric analysis. *Am J Orthod Dentofacial Orthop* **1992**;101:244–7.
22. Kim DS, Yang HJ, Huh KH, Lee SS, Heo MS, Choi SC, Hwang SJ, Yi WJ. Three-dimensional natural head position reproduction using a single facial photograph based on the POSIT method. *J Craniomaxillofac Surg* **2014**;42:1315–21.
23. Barbera AL, Sampson WJ, Townsend GC. Variation in natural head position and establishing corrected head position. *Homo* **2014**;65:187–200.

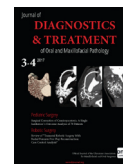
Cruz RLA, Gasperini G.

Assessment of the relationship of the frankfort horizontal plane and the orbitomeatal line with attainment of the natural head position.

*J Diagn Treat Oral Maxillofac Pathol* **2017**;1:156–163.

<http://dx.doi.org/10.23999/j.dtopm.2017.3-4.8>





## Correction of Lysozyme Content in Mixed Saliva in Patients With Jaw Ameloblastomas\*

Natalia O. Ushko

Associate Professor of Maxillofacial Surgery Department of Shupyk National Medical Academy of Postgraduate Education (PhD, Assoc Prof)

### ABOUT ARTICLE

#### Article history:

Paper received 3 December 2017

Accepted 6 December 2017

Available online 28 December 2017

#### Keywords:

Ameloblastoma

Jaw tumors

Inflammatory complications

Mixed saliva

Lysozyme

Lysobact

Pyridoxine

Local nonspecific resistance of the organism

### ABSTRACT

#### Purpose.

Determine the content of lysozyme in mixed saliva in patients with ameloblastomas of the jaws in the dynamics of the treatment, as well as the effectiveness of using the drug Lysobact for immunocorrection.

#### Material and Methods.

31 patients with ameloblastomas of the jaws were examined in the dynamics of the treatment and in the rehabilitation period.

#### Results.

A decrease in local non-specific resistance of the body (studied by the content of lysozyme in mixed saliva) in patients with jaw ameloblastomas during hospitalization and after surgical treatment was established. The purpose of the drug Lysobact allowed normalizing the level of lysozyme content in the mixed saliva of these patients in the rehabilitation period.

#### Conclusions.

The use of the drug Lysobact for 2 weeks in patients with ameloblastomas of the jaws allows to completely normalizing the local nonspecific resistance of the organism and significantly reduces the number of inflammatory complications.

© 2017 OMF Publishing, LLC. This is an open access article under the CC BY licence (<http://creativecommons.org/licenses/by-nc/4.0/>).

### Introduction

Based on the examination of patients with ameloblastomas of the jaws, the secretion of mixed saliva (oral fluid), the saliva of large salivary glands (parotid and submandibular), as well as the number and functional activity of small salivary glands, significantly decreased in comparison with healthy people after surgical treatment. Normalization of saliva secretion, which is secreted by large and small salivary glands, occurs not earlier than 2-3 weeks after gentle resection of the lower jaw and 2 months after the classical resection (with violation of bone continuity). This fact indicates that in patients with ameloblastomas in the postoperative period [1-4], the local protective factors of the organism appear to decrease, which leads to the development of inflammatory processes from the mucous membrane of the oral cavity.

To correct the local nonspecific resistance of the body, which is regulated by the level of lysozyme in mixed saliva,

there are a lot of medications in the arsenal of the doctor. We were interested in medications that would be as close to the natural components of the human body as possible. Lysozyme. Thus, our attention was drawn to the drug Lysobact.

“Lysobact®” (Bosnalijek d.d., Sarajevo, Bosnia and Herzegovina) approved by the order of the Ministry of Health of Ukraine on March 14, 2005, No. 106 (registration certificate No. UA/2790/01/01). The drug is produced in blisters of 10 tablets, which are used for resorption. One tablet contains 20 mg of lysozyme chloride and 10 mg of pyridoxine hydrochloride. It is known that lysozyme is a mucopolysaccharide effective against gram-positive and gram-negative bacteria (the insoluble polysaccharides of the cell wall of the microbe are transformed into soluble mucopeptides), and also effective against fungi and viruses. Lysozyme exhibits local anti-inflammatory activity and increases the nonspecific resistance of the body. Pyridoxine (vitamin B6) provides a protective effect on the mucosa of the oral cavity, preventing the development of thrush. Scheme of drug usage: adults take 2 tablets (dissolve) 3-4 times a day for 14 days. Contraindication to the use of Lysobact is an increased sensitivity to the components of the drug.

The purpose of the study was to determine the level of

\*This manuscript has not been presented

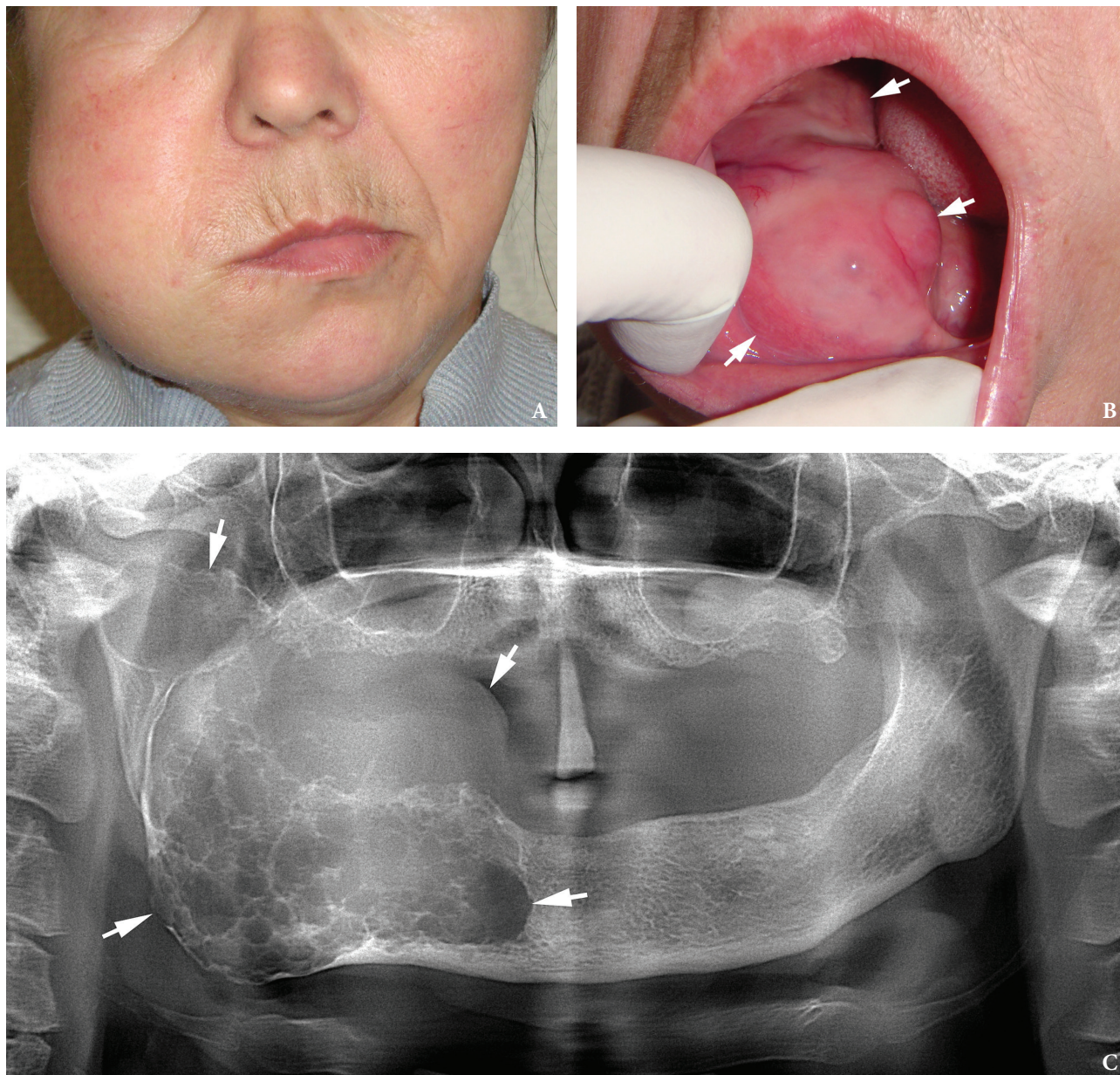
\* Corresponding author. Department of Maxillofacial Surgery, Stomatology Institute, Shupyk NMAPE, 4-a Pidvysotskogo Street, Kyiv 01103, Ukraine.

Tel.: +380687077707 Fax: +380445283517.

E-mail address: [natalia.ushko@gmail.com](mailto:natalia.ushko@gmail.com) (N.O. Ushko)

lysozyme in mixed saliva of patients with ameloblastomas before surgical treatment (Fig 1), in the dynamics of the

postoperative period, and to establish the effectiveness of using the drug Lysobact for immunocorrection.



**FIGURE 1.** An extraoral (A) and intraoral (B) appearance of follicular ameloblastoma of the right mandible in 57-year-old lady. The patient is noted the tumor growth during last 30 years. On the intraoral image (B) and panoramic x-ray (C) the tumor is indicated by arrows.

### Materials and Methods

31 patients with ameloblastomas of jaws aged from 24 to 59 years were examined. Patients were examined at hospitalization, 5-7 and 14-17 days after surgery, 7-8 days and 16-18 days after the start of treatment with the drug Lysobact, and also 2-2.5 months after the performed operation.

All patients were assessed the level of lysozyme in mixed saliva (oral fluid). The following saliva collection conditions were applied: saliva was collected on an

empty stomach, the patient collected saliva in the mouth for 1 minute, then spit it into a special container. The concentration of lysozyme in the investigated material was determined by the method of Motavkina (1979) [5].

In addition to the previously mentioned drug Lysobact, patients in the postoperative period underwent symptomatic treatment (using anesthetics, hygienic oral care, etc.).

The control group consisted of 29 practically healthy people (without concomitant diseases) with a sanitized oral cavity.

All the data obtained in the course of the study are processed mathematically using the Student test. The parameters were considered reliable at  $p < 0.05$ .

## Results

The results of the examination of 31 patients showed (Table 1) that when the patients with ameloblastoma were hospitalized, the content of lysozyme in mixed saliva (oral fluid) was  $0.016 \pm 0.001$  g/l ( $p < 0.001$ ), which indicated a significant decrease in its level in comparison with the control group, healthy people ( $0.023 \pm 0.001$  g/l). Five to seven days after the operation, the content of lysozyme in

mixed saliva decreased even more than in the previous study period (hospitalization), as well as in the control group, and was  $0.012 \pm 0.001$  g/l ( $p < 0.001$ ). 14-17 days after surgery, the content of lysozyme in mixed saliva continued to decrease and already significantly differed not only in comparison with healthy people, but also in comparison with the previous survey period (5-7 days after the surgery). Attention is drawn to the fact that the more difficult the operation was, the lower the lysozyme levels in the mixed saliva. The lowest levels of lysozyme content in mixed saliva were found in patients after classical lower jaw resection, and less pronounced – after excisional biopsy and gentle resection of the mandible.

TABLE 1. The content of lysozyme in mixed saliva in patients with ameloblastoma in the dynamics of the treatment

Subjects Groups	Number of Patients	Timing of the Survey	The Content of Lysozyme in Mixed Saliva (g/l)
			M ± m
Patients with ameloblastomas	31	At hospitalization	$0.016 \pm 0.001$ $p < 0.001$
		5-7 days after surgery	$0.012 \pm 0.001$ $p < 0.001$ $p_1 < 0.01$
		14-17 days after surgery	$0.006 \pm 0.001$ $p < 0.001$ $p_1 < 0.001$
		7-8 days after the beginning of treatment with the drug Lysobact	$0.011 \pm 0.001$ $p < 0.001$ $p_1 < 0.01$
		16-18 days after the beginning of treatment with the drug Lysobact	$0.021 \pm 0.001$ $p > 0.05$ $p_1 < 0.001$
		2-2.5 months after the operation (1-1.5 months after treatment with the drug Lysobact)	$0.022 \pm 0.001$ $p > 0.05$ $p_1 > 0.05$
Control group (healthy people)	29	$0.023 \pm 0.001$	

*p* – reliability of differences compared to the control group (healthy people)  
*p*<sub>1</sub> – reliability of differences compared to the previous survey period.

Thus, on the basis of the conducted examination of patients with ameloblastomas of the jaws, it was found that when they were hospitalized, the content of lysozyme in the mixed saliva was already significantly lower in them than in healthy people. After 5-7 days after the operation, the content of lysozyme in mixed saliva was even greater and significantly decreased, and after 14-17 days after the surgical intervention (at discharge of the patients from the hospital) the level of lysozyme reached the lowest values. A significant decrease in the level of lysozyme in mixed saliva in this period of the survey indicated a decrease in local nonspecific resistance of the organism not only during hospitalization (in the presence of this tumor in the oral cavity), but also in the postoperative period. This was

evidenced by an increase in the number of inflammatory manifestations from the mucous membrane of the oral cavity from 46.7% (when hospitalized) to 96.7% (when discharging from the hospital).

As a result of examination of 31 patients in the rehabilitation period, after the operative intervention, we found that the level of lysozyme in mixed saliva on the 7th-8th day after the use of the drug Lysobact significantly increased in comparison with the previous period of the examination (when the patient was discharged from the hospital), but still remained 2 times lower than normal and was  $0.011 \pm 0.001$  g/l ( $p < 0.001$ ). This indicated the preservation of a low level of local nonspecific resistance of the organism in these patients (Table 1). Therefore, the

treatment of patients with this drug, we continued in the previous dosages.

16-18 days after the beginning of treatment with the drug Lysobact, the content of lysozyme in mixed saliva significantly increased in comparison with the previous period of the examination and practically did not differ from the group of healthy people. The content of lysozyme in mixed saliva on the 16-18 day after the appointment of this drug was  $0.021 \pm 0.001$  g/l ( $p > 0.05$ ). At this stage, the use of the drug Lysobact was completed. Thus, the duration of the drug Lysobact was 14 days (2 weeks).

To determine the level of lysozyme in mixed saliva, we conducted another, final, examination of previously treated patients 2-2.5 months after the surgery (1-1.5 months after the end of treatment with the drug Lysobact). It was established that the content of lysozyme in mixed saliva in this period was not significantly different from the control group of observation (healthy people) and was  $0.023 \pm 0.001$  g/l ( $p > 0.05$ ). In the oral cavity of these patients, we did not reveal any inflammatory complications from the oral mucosa.

### Conclusion

Based on the conducted examinations of patients with ameloblastomas of the jaws [6-14], it was found that the content of lysozyme in the mixed saliva of patients during hospitalization was significantly lower than normal, and after surgery it was further reduced.

To correct the local nonspecific resistance of the body, we applied the drug Lysobact. The drug Lysobact was prescribed for 14 days (2 weeks). After 16-18 days after the start of treatment with this drug, the content of lysozyme in mixed saliva was normalized and preserved in a remote postoperative period.

### Funding

None.

### Conflict of Interests

None.

### Role of Author

Natalia O. Ushko (concept of the paper, material collection, and writing)

### Ethical Approval

Approval was obtained from the Medical Ethics Committee of the Shupyk National Medical Academy of Postgraduate Education, Kyiv, Ukraine.

### Patient Consent

Written patient consent was obtained to publish the clinical images.

### Acknowledgements

High quality image C of **Figure 1** is courtesy of Nadia I. Paterega, *PhD Student*, Lviv, Ukraine; Image A and B of **Figure 1** is courtesy of Ievgen I. Fesenko, *Assis Prof*, Kyiv, Ukraine.

### References

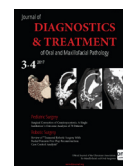1. Tymofieiev OO. Manual of maxillofacial and oral surgery [Russian]. 5th ed. Kyiv: Chervona Ruta-Turs; 2012.
2. Fernandes RP, Quimby A, Salman S. Comprehensive reconstruction of mandibular defects with free fibula flaps and endosseous implants. *J Diagn Treat Oral Maxillofac Pathol* 2017;1(1):6–10.
3. Qaisi M, Kolodney H, Swedenburg G, et al. Fibula jaw in a day: state of the art in maxillofacial reconstruction. *J Oral Maxillofac Surg* 2016;74(6):1284.e1-1284.e15.
4. Tymofieiev OO. Maxillofacial surgery [Russian]. 2nd ed. Kyiv: Medytsyna; 2015.
5. Motavkina NS, Kovalev VM, Sharonov AS. Micromethod of quantitative determination of lysozyme [Russian]. *Laboratornoye delo* 1979;12:722–4.
6. Chukwunke FN, Anyanechi CE, Akpeh JO, et al. Clinical characteristics and presentation of ameloblastomas: an 8-year retrospective study of 240 cases in Eastern Nigeria. *Br J Oral Maxillofac Surg* 2016;54(4):384–7.
7. Tymofieiev OO, Ushko NO, Vesova OP, Yarifa MO. Diagnostics of severity of the trigeminal nerve injuries during jaws surgeries. *J Diagn Treat Oral Maxillofac Pathol* 2017;1:32–9.
8. Tymofieiev OO, Ushko NO, Vesova OP, Yarifa MO. Treatment of postoperative neuropathy of the trigeminal nerve. *J Diagn Treat Oral Maxillofac Pathol* 2017;1:113–22.
9. Hammarfjord O, Roslund J, Abrahamsson P, et al. Surgical treatment of recurring ameloblastoma, are there options? *Br J Oral Maxillofac Surg* 2013;51(8):762–6.
10. Tymofieiev OO, Ushko NO, Tymofieiev OO, Yarifa MO, Fesenko IeI. Prevention of inflammatory complications upon surgeries in maxillofacial region. *J Diagn Treat Oral Maxillofac Pathol* 2017;1:105–12.
11. Chernushenko YeF, Kogosova LS. Immunological researches in clinic [Russian]. Kyiv: Zdorov'ya; 1978.
12. Tymofieiev OO. Essentials of maxillofacial surgery [Russian]. 1st ed. Moscow: Meditsinskoye Informatsionnoye Agentstvo; 2007.
13. Bansal S, Desai RS, Shirsat P, et al. The occurrence and pattern of ameloblastoma in children and adolescents: an Indian institutional study of 41 years and review of the literature. *Int J Oral Maxillofac Surg*. 2015;44(6):725–31.
14. Tymofieiev OO. Maxillofacial surgery [Ukrainian]. 2nd ed. Kyiv: Medytsyna; 2017.

Ushko NO.

Correction of lysozyme content in mixed saliva in patients with jaw ameloblastomas.

*J Diagn Treat Oral Maxillofac Pathol* 2017;1:164–167.

<http://dx.doi.org/10.23999/j.dtopm.2017.3-4.9>



# The Integral Indicator of the Evaluation of the General State Severity in Patients With Inflammatory Processes of the Mandibular Bone According to the Data of Peripheral Clinical Blood Analysis\*

Mark P. Komskyi<sup>1,\*</sup>, Olena H. Romanenko<sup>2</sup>, Oleksandr A. Buzoveria<sup>3</sup>, Mariia V. Makohon<sup>4</sup>

<sup>1</sup> Dnipro Medical Institute of Conventional and Alternative Medicine. Faculty of Dentistry. The Cycle of Surgical Dentistry. Dnipro, Ukraine (Chief, PhD, Professor).

<sup>2</sup> Dnipropetrovsk Medical Academy. Faculty of Dentistry. (PhD, Assis Prof)

<sup>3</sup> Urban Head and Neck Surgical Center of the Dnipropetrovsk City Multifield Clinical Hospital #4. Dnipro, Ukraine (Hospital Physician)

<sup>4</sup> Urban Head and Neck Surgical Center of the Dnipropetrovsk City Multifield Clinical Hospital #4. Dnipro, Ukraine (Hospital Physician)

## ABOUT ARTICLE

### Article history:

Paper received 21 November 2017

Accepted 25 November 2017

Available online 28 December 2017

### Keywords:

Osteomyelitis

Odontogenic osteomyelitis

Traumatic osteomyelitis

Mandible

Inflammatory process

Maxillofacial area

Blood analysis

## ABSTRACT

### Purpose.

To study the possibility of using a clinical blood analysis for the mathematical determination of the severity level in patients with inflammatory processes in the maxillofacial area.

### Materials and Methods.

Under our supervision were 150 patients with acute (50), subacute (50) and chronic (50) inflammatory processes in the lower jaw area. 170 blood tests were analyzed for 11 signs: Blood sedimentation rate, white blood cells (cytosis and leukopenia), myelocyte, juvenile, stub, segmented neutrophil, eosinophile, lymphocyte, monocytes, plasma cell, which are conditionally divided according to the degree of severity from 0 to 3 points in the form of a table.

### Results and Discussion.

From the archive were selected 300 case histories of patients hospitalized in the clinic for acute, subacute and chronic stages of odontogenic and traumatic osteomyelitis of the mandible (50 patients for each nosology). Laboratory analyses of peripheral blood were taken from the patient upon admission to the department. 300 blood analyses were analyzed in accordance with the scale of patients developed by us in assessing the severity of the patient's condition with the inflammatory processes of the maxillofacial area by peripheral blood analysis.

As a result, sum of points were obtained that corresponded to three degrees of severity in patients with odontogenic and traumatic osteomyelitis of the mandibular bone: mild stage from 1 to 7; medium stage from 8 to 15 and severe stage from 16 to 27 points.

### Conclusion.

The proposed methodology for the integral calculation of the evaluation of the degree of severity of general status in terms of indicators of peripheral blood in patients with inflammatory processes of the maxillofacial area allows for early diagnosis of the severity of the pyoinflammatory process of the maxillofacial area.

© 2017 OMF Publishing, LLC. This is an open access article under the CC BY licence (<http://creativecommons.org/licenses/by-nc/4.0/>).

## Introduction

Inflammatory processes in the maxillofacial area continue to occupy the main place among the causes of temporary disability in surgical dental patients [1, 2].

It is often noted the progression of the inflammatory process, the development of inflammatory complications, which significantly prolongs the duration of treatment and can lead to serious complications up to a mortality [3].

In recent years, was shown the prospects of using the method of mathematical prediction of the course of the inflammatory processes of the maxillofacial area [4-6].

To create a mathematical model, use various biochemical, immunological indicators, genetic markers, etc. However, in everyday clinical practice, the most

\*This manuscript has not been presented

\* Corresponding author. Dnipro Medical Institute of Conventional and Alternative Medicine. Faculty of Dentistry. The Cycle of Surgical Dentistry. Dnipro, 17 Sevastopolska Street, 49000, Ukraine.

Tel.: +380675628517

E-mail address: [rolex-50@yandex.ru](mailto:rolex-50@yandex.ru) (M.P. Komskyi)

## GENERAL STATE OF PATIENTS WITH MANDIBULAR OSTEOMYELITIS

common are the parameters of peripheral blood. Therefore, the further search for laboratory blood indicators that are informative and accessible to most medical institutions, which allow us to assess the severity and predict the course of the disease on the basis of mathematical modeling, is topical.

The purpose of the research is to study the possibility of using a clinical blood analysis for the mathematical determination of the severity level in patients with inflammatory processes in the maxillofacial area and to use the data obtained for the purpose of active control over the reduction in the length of stay in the hospital.

### Materials and Methods

Under our supervision, in the Clinic of the Dentistry Faculty of Dnipro Medical Institute of Conventional and Alternative Medicine on the basis of Dnipropetrovsk City

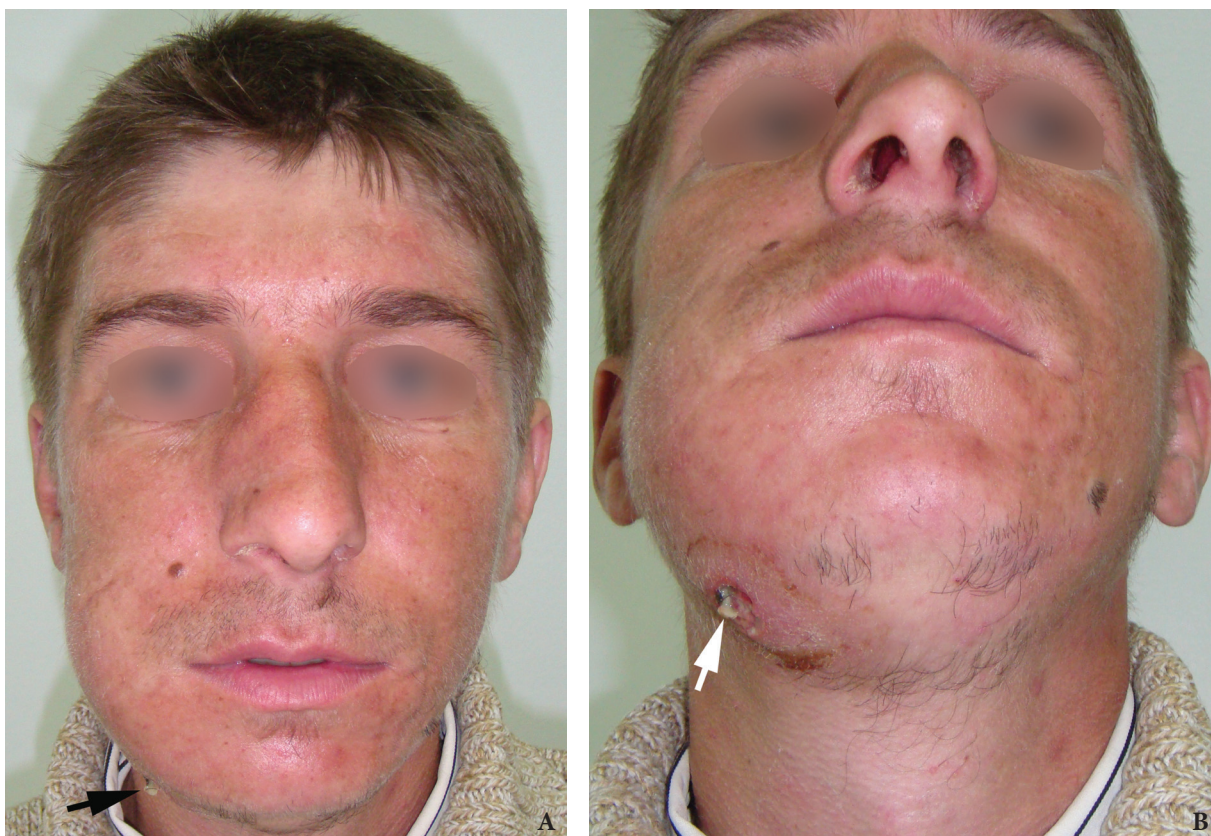Multifield Clinical Hospital #4 there were 150 patients (105 men, 45 women) with various inflammatory processes (Fig 1) in the maxillofacial area (Table 1). Age of patients from 18 to 58 years.

On presentation in the inpatient department, all patients underwent the standard complex of curative services in accordance with the nosological entity of the disease, due to the quality standard of the treatment [7].

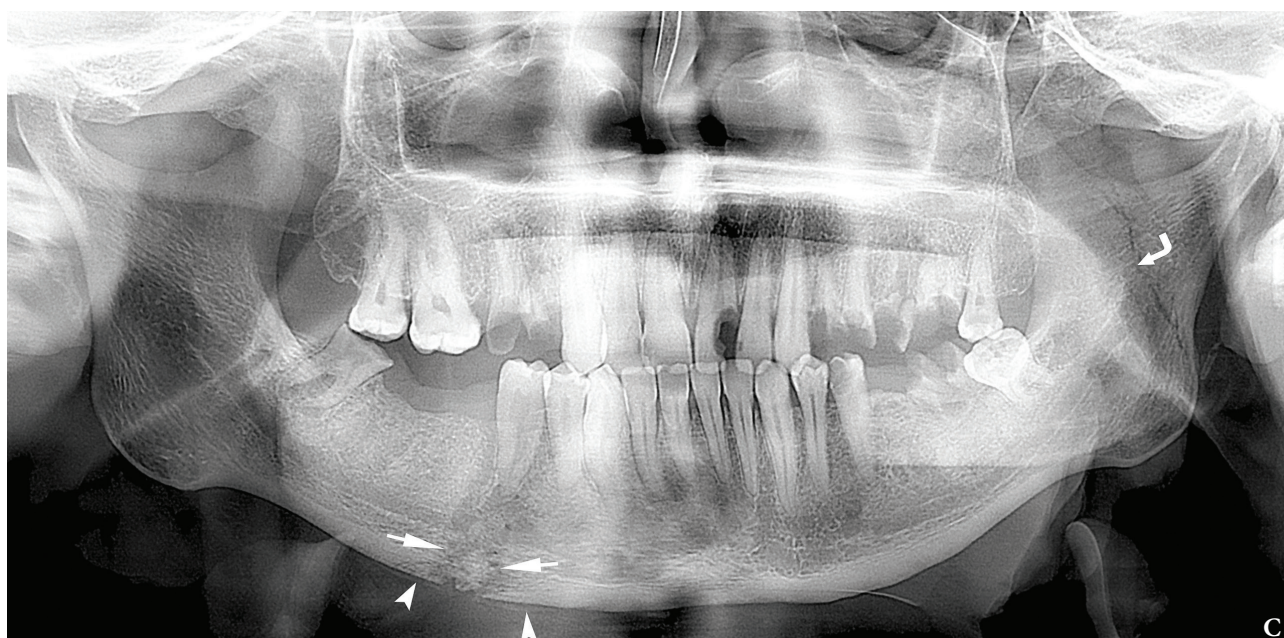
Laboratory examination of the patient was carried out on admission to the department.

Mathematical processing of data was carried out on a personal computer, it was used the standard package of mathematical statistics applications.

170 blood tests were analyzed for 11 signs, which are conditionally divided according to the severity from 0 to 3 points (Table 2), while 0 points correspond to the norm of the peripheral blood analysis for the Dnipropetrovsk region.



**FIGURE 1.** An extraoral (A, B) appearance of 27-year-old gentleman with acute posttraumatic osteomyelitis of the mandible as a result of two week trauma and bilateral fracture (right body and left subcondylar). Noted the swelling of soft tissues and cutaneous fistula (arrow) with purulent discharge. (Fig 1 continued on the next page.)



**FIGURE 1. (cont'd).** Panoramic x-ray (C) shows irregularity of bony margins in the gap of right body fracture and `doubling` sign (arrows). Left subcondylar fracture – curved arrow. Periosteal reaction at the lower border of the mandible (near the fracture gap) is indicated by arrowheads. (Images of **Figure 1** are courtesy of Ievgen I. Fesenko, *Assis Prof*; Kyiv, Ukraine)

**TABLE 1.** 150 patients (105 men, 45 women) with various inflammatory processes in the maxillofacial area.

#	Nosological Entity	Number of Observations
1.	Practically healthy people (volunteers).	20
2.	Acute stage of odontogenic osteomyelitis of the mandible.	25
	Osteal abscess of the mandible.	25
3.	Subacute stage of odontogenic osteomyelitis of the mandibular bone.	25
	Subacute stage of traumatic osteomyelitis of the mandibular bone.	25
4.	Chronic stage of odontogenic osteomyelitis of the mandible.	25
	Chronic stage of traumatic osteomyelitis of the mandible.	25

**TABLE 2.** Scale of the points of severity of peripheral blood state in patients with odontogenic osteomyelitis of lower jaw bone.

#	Abbreviation	Designation	Points			
			Norm 0	Mild 1	Medium 2	Severe 3
1	BSR	Blood sedimentation rate	8-14	15-22	23-40	41 and above
2	Lc	White blood cells /cytosis/	4-9	10-15	16-20	21 and above
3	Lp	White blood cells / leukopenia/	9-4	3	2	1
4	Mc	Myelocyte	0	1	2	3 and above
5	J	Juvenile	0	1-3	4-10	11-20
6	St	Stab	0-5	6-8	9-15	16 and above
7	N	Segmented neutrophil	47-70	71-72	73-74	75 and above

#	Abbreviation	Designation	Points			
			Norm 0	Mild 1	Medium 2	Severe 3
8	Es	Eosinophile	0.5-5.0	0,4	0,3-0,2	0.1-0
9	Lh	Lymphocyte	19-37	18-14	13-11	10 and above
10	Mo	Monocyte	2-8	9-10	11-12	13 and above
11	Pc	Plasma cell	2-8	9-10	11-12	13 and above

When using this table, you must follow the following rules:

1. Evidence of the investigated symptoms are either present or absent.
2. The severity of the status of peripheral blood in patients is determined by summing the points of

the signs present.

### Results and Discussion

From the archives of the dental clinic for 2010-2015 years, 300 case histories were selected, hospitalized for:

TABLE 3. Nosological entity of the disease.

#	Nosological Entity	Number of Observations
1.	Acute stage: - odontogenic osteomyelitis of mandibular bone; - osteal abscess of mandibular bone.	50 50
2.	Subacute stage: - odontogenic osteomyelitis of mandibular bone; - traumatic osteomyelitis of the mandibular bone.	50 50
3.	Chronic stage: - odontogenic osteomyelitis of mandibular bone; - traumatic osteomyelitis of the mandibular bone.	50 50

Among the patients were 255 men and 45 women aged 18 to 52 years. All patients underwent the standard complex of curative services in accordance with the nosological entity of the disease, due to the quality standard of the treatment [7].

Laboratory analyses of peripheral blood were taken from the patient upon admission to the department. 300 blood analyses were analyzed in accordance with the scale of patients developed by us in assessing the severity of the patient's condition with the inflammatory processes of the maxillofacial area by peripheral blood analysis.

As a result, sum of points were obtained that corresponded to three degrees of severity in patients with odontogenic (Fig 2) and traumatic osteomyelitis of the mandibular bone (Table 4), while there was no significant difference in the odontogenic inflammatory process and an inflammatory complication of injury of the mandible [8-15].

### Conclusion

By such manners, the proposed method of integral calculation of the degree of severity of the peripheral blood state indices in patients with inflammatory processes of the maxillofacial area allows early diagnosis of the severity

of the pyoinflammatory process of the maxillofacial area of various genesis and to solve the question of rational individual treatment of the patient [15].

### Funding

None.

### Conflict of Interests

The authors declare no conflict of interest.

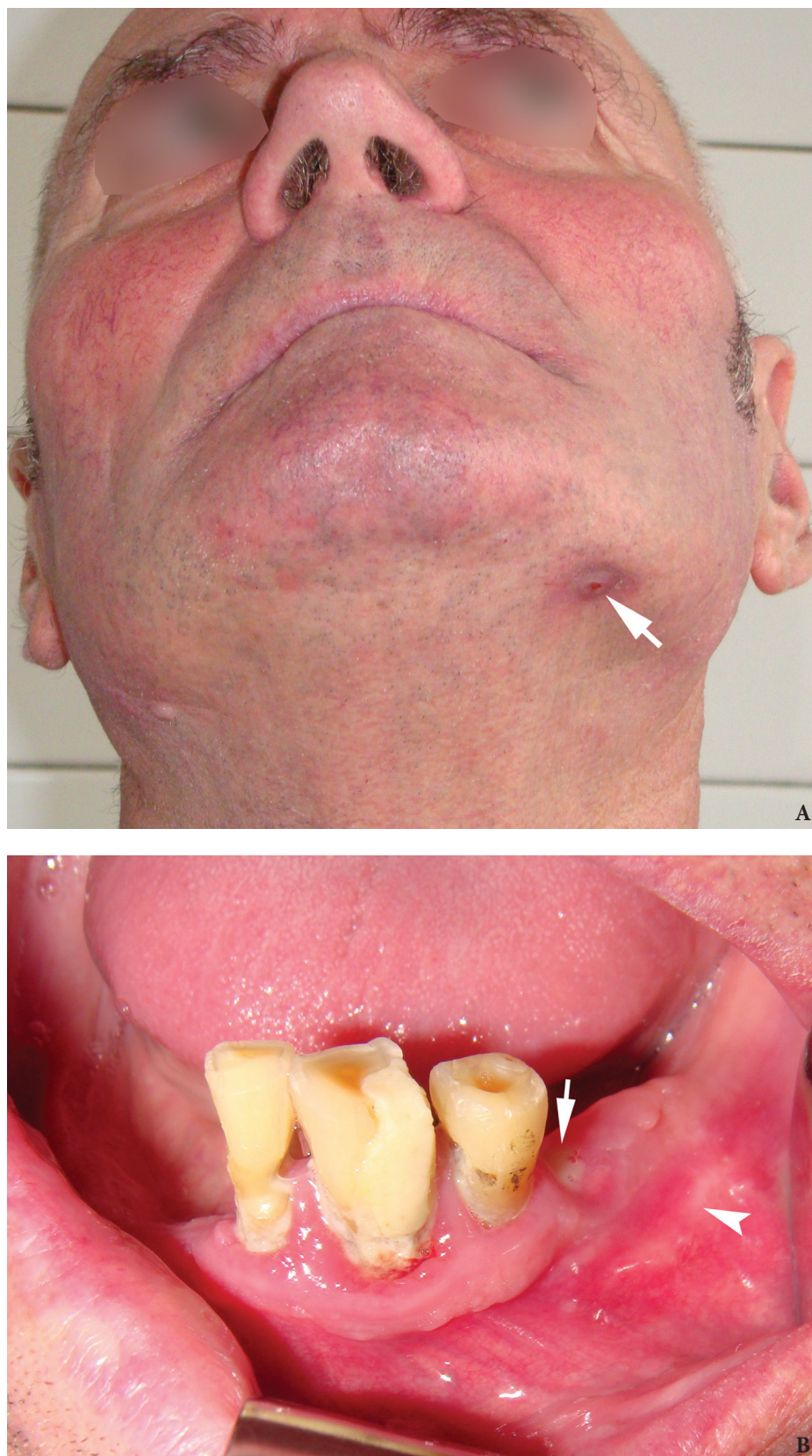### Role of Author and Co-authors

Mark P. Komsyki (concept of the paper and editing)  
Olena H. Romanenko (material collection and writing)  
Oleksandr A. Buzoveria (material collection and writing)  
Mariia V. Makohon (material collection and writing)

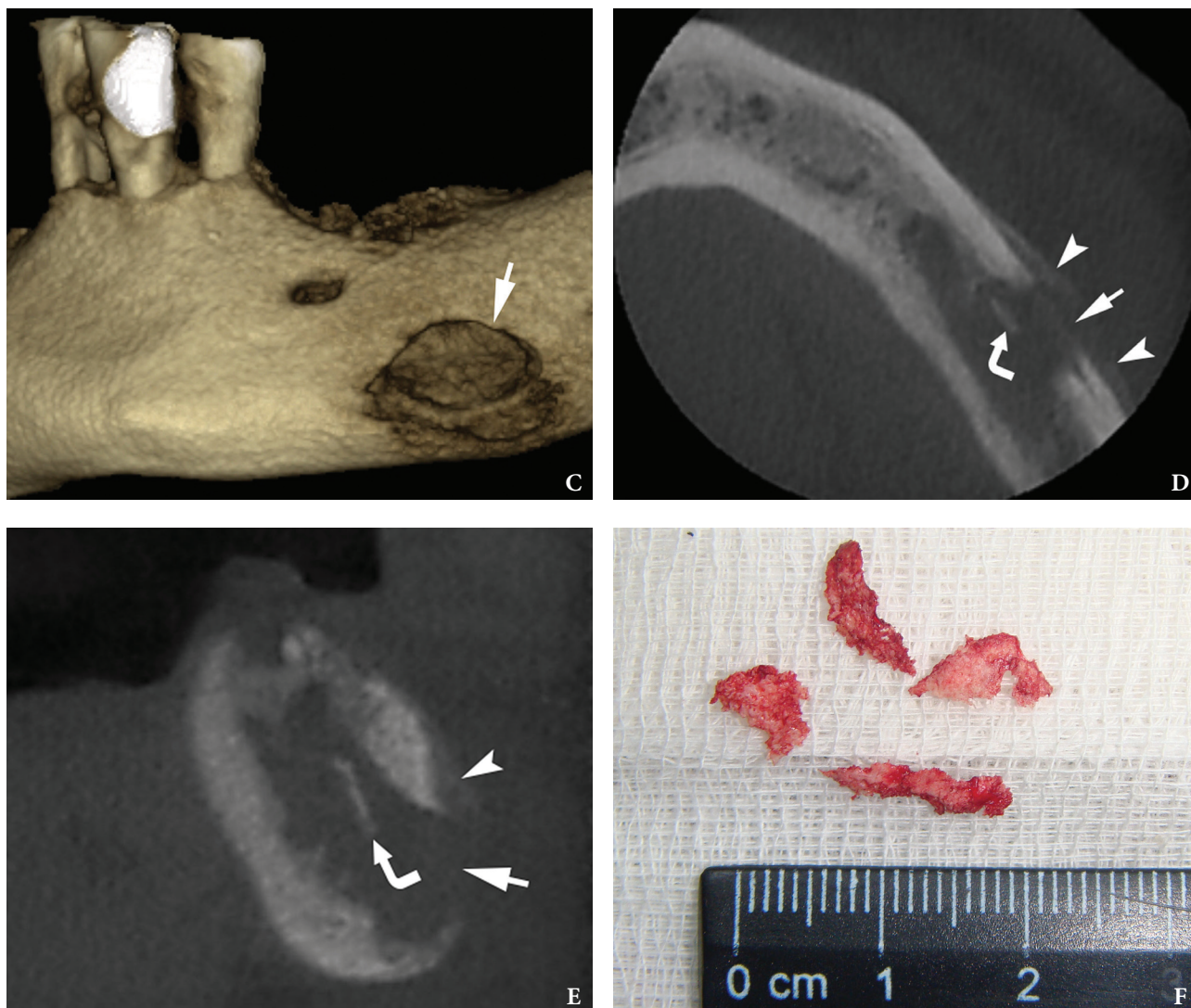
### Ethical Approval

Approval was obtained from the Medical Ethics Committee of the Dnipro Medical Institute of Conventional and Alternative Medicine.





**FIGURE 2.** An extraoral (**A**) and intraoral (**B**) appearance of 70-year-old male with chronic odontogenic osteomyelitis of the mandible as a result of alveolitis (synonym: alveolar osteitis) after extraction of teeth 35, 36. On the image **A** is noted a skin fistula (*arrow*) at lower border of mandible. On intraoral view (**B**) a purulent discharge indicated by *arrow*, scar tissue after previously performed lancing of tissues by non-experienced surgeon – by *arrowhead*. Erythema of surrounding mucosa and extremely bad hygiene are also noted. (**Fig 2 continued on the next page.**)



**FIGURE 2. (cont'd).** A 3D reconstructed (C), axial (D), and coronal (E) CBCT scans showed cortical bone defect (arrows). Sequestered bone fragment is indicated by curved arrow, periosteal reaction – by arrowheads. (F) Appearance of periosteal reaction after its removal. (Images of **Figure 2** are courtesy of Ievgen I. Fesenko, Assis Prof, Kyiv, Ukraine)

**TABLE 4.** The sum of points characterizing the degree of severity of the pathological process in patients with inflammatory diseases of the maxillofacial localization.

#	Degree of Severity of Peripheral Blood State in Patients With Osteomyelitis of the Mandible	Sum of Points
1.	Mild stage	From 1 to 7 points
2.	Medium stage	From 8 to 15 points
3.	Severe stage	From 16 to 27 points

**Patient Consent**

Written patient consent was obtained to publish the clinical photographs.

**Acknowledgements**

The authors are grateful to Sergii I. Khrulenko (*x-ray laboratory assistant*; Kyiv, Ukraine) for high quality

panoramic x-ray (**Fig 1C**).

**References**

1. Tymofieiev OO. Manual of maxillofacial and oral surgery [Russian]. 5th ed. Kyiv: Chervona Ruta-Turs; 2012.
2. Levy MM, Fink MP, Marshall JC et al. 2001 SCCV/ESICM/ACCP/ATS/SIS International Sepsis Definitions Conference. *Crit Care Med* 2003;31(4):1250–6.
3. Kabanova AA, Pokhodenko-Chudakova IO. The role of

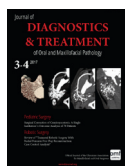- specific and nonspecific resistance in the development of infectious and inflammatory processes of the maxillofacial area (current state of the matter). *Dentistry* **2015**;4(19):45–9.
4. Shepel MA, Shvyrkov MB, Obiedkov RH. The use of non-traditional methods for predicting the course of fractures of the lower jaw bone: Collection of abstracts Dentistry on the eve of the third millennium; Moscow, **2001**. p. 516.
  5. Shliapnikov VV, Fedorova VV. Comparative evaluation of the results of clinical and microbiological studies for predicting the outcome of peritonitis. *Infections in Surgery* **2003**;2:40–4.
  6. Ruzin HP, Hryhorov SN, Vakulenko EN, Pokhodenko-Chudakova IO, Kabanova AA, Krainiaia VO. Data of retrospective analysis of the course and prognosis of phlegmon of maxillofacial area in various territorial conditions. *Medical Magazine* **2016**;1(55):130–6.
  7. On the approval of temporary branch unifiers of medical technology standards for the diagnostic-treatment process of inpatient care for the adult population in treatment and prophylactic institutions of Ukraine and temporary standards for the volume of diagnostic studies, treatment measures and criteria for the quality of children's treatment". Ministry of Health of Ukraine, Order #226 July 27, **1998**.
  8. Larheim TA, Westesson P-L. Maxillofacial imaging. 1st ed. Berlin Heidelberg: Springer-Verlag; **2006**.
  9. Tymofieiev OO, Ushko NO, Tymofieiev OO, Yarifa MO, Fesenko IeI. Prevention of inflammatory complications upon surgeries in maxillofacial region. *J Diagn Treat Oral Maxillofac Pathol* **2017**;1:105–12.
  10. Chattopadhyay PK, Nagori SA, Menon RP, Thanneermalai B. Osteomyelitis of the mandibular condyle: a report of 2 cases with review of the literature. *J Oral Maxillofac Surg* **2017**;75(2):322–35.
  11. Lucchesi L, Kwok J. Long term antibiotics and calcitonin in the treatment of chronic osteomyelitis of the mandible: case report. *Br J Oral Maxillofac Surg* **2008**;46:400–2.
  12. Huang Z, Huang Z, Zhang D, et al. Endoscopically-assisted operations in the treatment of odontogenic peripheral osteomyelitis of the posterior mandible. *Br J Oral Maxillofac Surg* **2016**;54(5):542–6.
  13. Chang Y-C, Shieh Y-S, Lee S-P, et al. Chronic osteomyelitis with proliferative periostitis in the lower jaw. *Journal of Dental Sciences* **2015**;10:450-5.
  14. Goda A, Maruyama F, Michi Y, et al. Analysis of the factors affecting the formation of the microbiome associated with chronic osteomyelitis of the jaw. *Clin Microbiol Infect* **2014**;20:O309–17.
  15. Marx RE, Tursun R. Suppurative osteomyelitis, bisphosphonate induced osteonecrosis, osteoradionecrosis: a blinded histopathologic comparison and its implications for the mechanism of each disease. *Int J Oral Maxillofac Surg* **2012**;41(3):283–9.

Komskiy MP, Romanenko OH, Buzoveria OA, Makohon MV.

The integral indicator of the evaluation of the general state severity in patients with inflammatory processes of the mandibular bone according to the data of peripheral clinical blood analysis.

*J Diagn Treat Oral Maxillofac Pathol* **2017**;1:168–174.

<http://dx.doi.org/10.23999/j.dtopm.2017.3-4.10>



## Question of the Etiology of Malignant Neoplasms\*

Oleksii O. Tymofieiev<sup>1,\*</sup>, Oleksandr O. Tymofieiev<sup>2</sup>, Natalia O. Ushko<sup>3</sup>, Mariia O. Yarifa<sup>4</sup>

<sup>1</sup> Chair of the Department of Maxillofacial Surgery, Shupyk National Medical Academy of Postgraduate Education, Kyiv, Ukraine (Prof, ScD)

<sup>2</sup> Associate Professor of the Dentistry Department of Shupyk National Medical Academy of Postgraduate Education (Assoc Prof, ScD)

<sup>3</sup> Associate Professor of the Maxillofacial Surgery Department of Shupyk National Medical Academy of Postgraduate Education (Assoc Prof, PhD)

<sup>4</sup> Associate Professor of Surgical Dentistry and Maxillofacial Surgery Department of PHEE "Kyiv Medical University" (PhD)

### ABOUT ARTICLE

#### Article history:

Paper received 10 September 2017

Accepted 18 September 2017

Available online 28 December 2017

#### Keywords:

Potentiometric indicators

Metal inclusions

Leukoplakia

Squamous cell carcinoma

Malignant neoplasms

### ABSTRACT

#### Purpose.

To determine the severity of potentiometric parameters in patients with malignant neoplasms of the oral mucosa and the presence of metal inclusions in the form of non-removable dentures made of dissimilar metals and their alloys.

#### Methods.

We examined of potentiometric parameters in 39 patients with metallic inclusions in the oral cavity, in which malignant tumors of the mucous membrane of the oral cavity (tongue, palate, mucous membrane of the alveolar process and the bottom of the oral cavity) were detected. All subjects were between the ages of 40 and 68 years.

#### Results.

High potentiometric indicators were revealed in patients with non-removable metal dentures, which are made of dissimilar metals and their alloys. The presence of defects in the lining of dentures, as well as metal parts of a non-removable structure or metal protective coating ("bald zones") increase the potentiometric parameters and increase the risk of malignant neoplasms of the mucous membranes.

#### Conclusions.

The presence of metal inclusions in the oral cavity in the form of permanent dentures can be one of the reasons for the development of malignant neoplasms of the mucous membranes. A significant increase (more than 3 times higher than the normal values) of potentiometric parameters in patients with malignant tumors of the mucous membranes with metallic inclusions in the oral cavity is observed not only between the metals of immovable dentures, but also between the metal denture and the mucosa of the alveolar process of the jaw, between different parts of the mucous membranes of the alveolar process.

© 2017 OMF Publishing, LLC. This is an open access article under the CC BY licence (<http://creativecommons.org/licenses/by-nc/4.0/>).

### Introduction

Unity of views on the significance of previous diseases and pathological processes in the development of malignant tumors of the oral mucosa is not present. It is known that these or other precancerous diseases or malignant tumors of the oral mucosa arise on the background of various factors contributing to their development. One of these factors is the electrochemical effect [1-12]. The most typical example of this can be galvanic currents arising in the oral cavity, which are caused by the presence in the oral cavity of orthopedic structures made of different metals and their alloys. In these cases, on the mucous membrane in the oral cavity (Fig 1) and

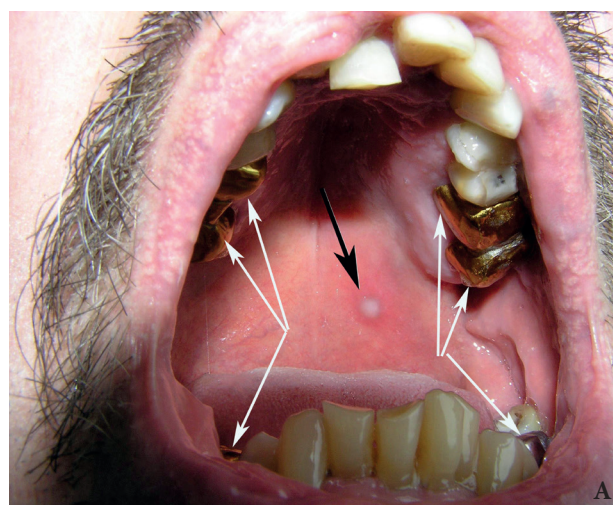


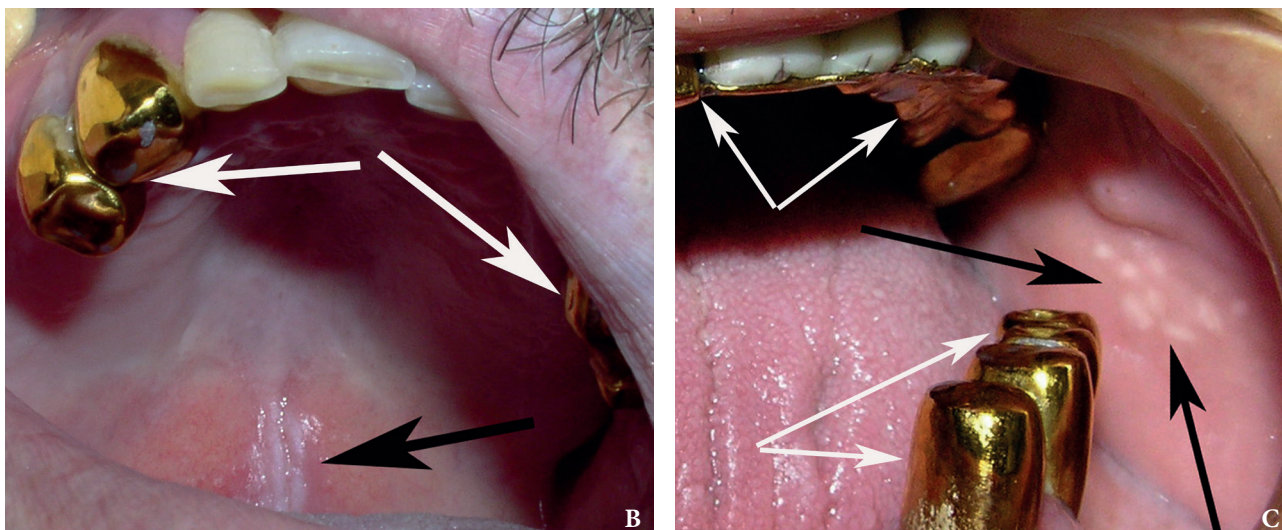
FIGURE 1. Black arrows (A-C) indicate foci of leukoplakia on the mucous membranes in the mouth. Metal inclusions are indicated by white arrows. (Fig 1 continued on the next page.)

\*This manuscript has not been presented

\* Corresponding author. Department of Maxillofacial Surgery, Shupyk NMAPE, 4-a Pidvysotskogo Street, Kyiv 01103, Ukraine. Tel., fax: +38 (044) 528 35 17.

E-mail address: [tymofeev@gmail.com](mailto:tymofeev@gmail.com) (O.O. Tymofieiev)

Instagram: [oleksii.tymofieiev](https://www.instagram.com/oleksii.tymofieiev); [dt\\_journal](https://www.instagram.com/dt_journal)



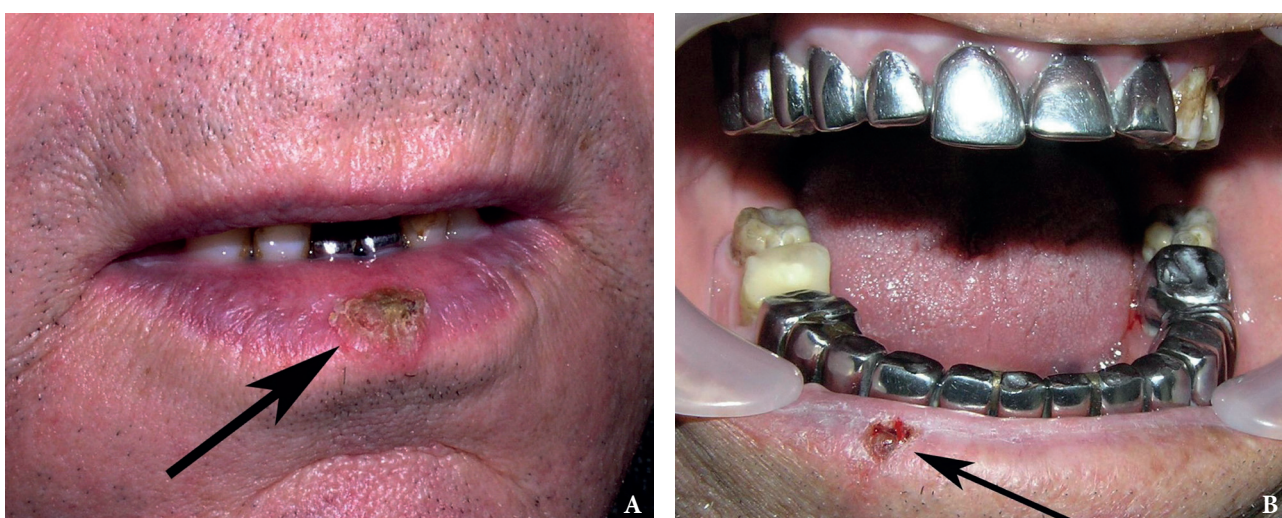**FIGURE 1. (cont'd).** Black arrows (A-C) indicate foci of leukoplakia on the mucous membranes in the mouth. Metal inclusions are indicated by white arrows.

on the red border of the lips (Fig 2), leukoplakia, hyperplasia and hyperkeratosis appear which serves as a background for the development of malignant tumors.

We found that in many patients with malignant tumors of the oral mucosa, the previous diseases were leukoplakia, which were detected in them for a long time (more than one year). Leukoplakia on the mucous membranes of the oral cavity (cheeks, retro-molar regions, tongue, alveolar process, etc.) in these patients

appeared on the background of their high galvanic potentials caused by the presence in the oral cavity of dissimilar metals from which non-removable dentures were made.

The purpose of the study is to determine the severity of potentiometric parameters in patients with malignant neoplasms of the oral mucosa and the presence of metal inclusions in the form of non-removable dentures made of dissimilar metals and their alloys.



**FIGURE 2.** Precancerous diseases (arrows) of vermilion border of the lower lip in patients with metallic inclusions located in the oral cavity (A, B).

## Materials and Methods

From 2008 to 2010, we examined 39 patients with metallic inclusions in the oral cavity, in which malignant tumors of the mucous membrane of the oral cavity (tongue, palate, mucous membrane of the alveolar process and the bottom of the oral cavity) were detected. All examined patients underwent general clinical examination (history, examination, palpation, radiography, etc.). The diagnosis of a malignant tumor, established by us, was necessarily confirmed by pathohistological examination [13-17]. All subjects were between the ages of 40 and 68 years.

To conduct potentiometric methods of examination, an automatic digital potentiometer (Pitterling Electronic GmbH  $\mu$ g-potential, Munchen, Germany) with 32 memory cells and a pair of measurement electrodes from the chromium-nickel alloy in fluoroplastic holders (manufactured in Germany). The device automatically detects a potential difference in the range of 0 to 999 mV, current power in the range of 0 to 99  $\mu$ A and electrical conductivity in the mouth in microsimens ( $\mu$ S). In the established measurement mode (10-20 seconds after switching on the device), when one of the electrodes contacts the metal surface (the tooth surface) and the second one – mucous membrane in the hyoid area, the digital values of the potential difference, current and electrical conductivity of the oral liquid are displayed on the screen. All subjects underwent measurements of potentiometric parameters (potential differences, current power, electrical conductivity of oral fluid) in the following areas (points):

- between metallic inclusions (M-M);
- between metallic inclusions and the mucosa of the alveolar process of the same jaw (M-APM);

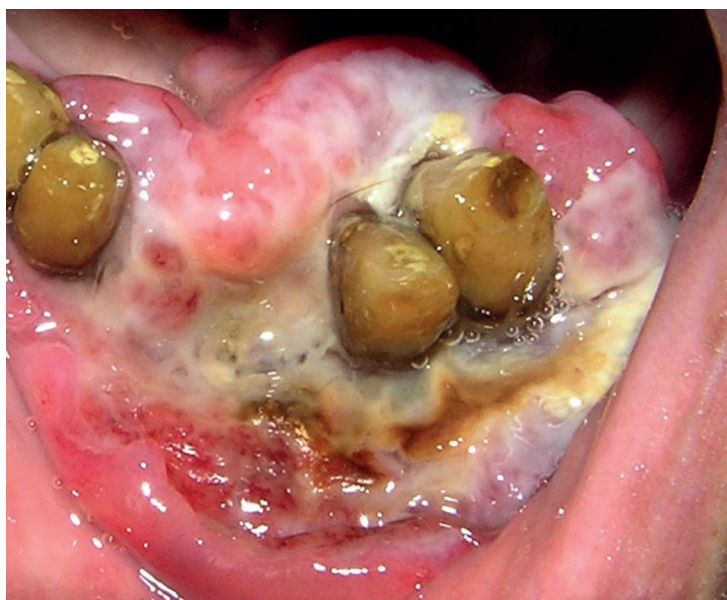– between the mucosa of the alveolar process of one and the other side of the jaw (APM-APM).

Contact thermometry was carried out using a TPEM-1 electrothermometer (Medtekhnik, Kharkiv, Ukraine) with point thermocouples (sensors) with a measuring range from 16 to 42 °C. The accuracy of registration is 0.2 °C. The contact time of the sensor with the oral mucosa was 20 seconds, the intervals between repeated examinations were 2 to 5 seconds. Touching the sensor was done with approximately the same pressure force. The local temperature was measured three times and the arithmetic mean was calculated. We measured the temperature on the investigated and healthy side. According to the recommendations of Tymofeiev (2002), the basis of the contact thermometry being conducted is not the measurement of absolute temperatures over the pathological focus, but the detection of the temperature difference at symmetrical sites ( $\Delta T$ ). Control has always been thermal asymmetry ( $\Delta T$ ) in symmetrical areas, found in practically healthy people of the same age and sex.

All the data obtained in the course of the study were processed mathematically with the Student's test. The parameters were considered reliable at  $p < 0.05$ .

## Results and Discussion

From the anamnesis of 39 patients with malignant tumors [18-22] of the oral cavity (Fig 3), we found out that prosthetics with non-removable metal dentures was performed in the period from 1.5 to 7 years before the appearance of a premolar disease (leukoplakia, chronic erosion or ulcers) or the tumor first clinical symptoms. 8 patients (20.5%) had a period of 1.5 to 2 years, 10 (25.6%) had 2 to 3 years, and 21 (53.9%) had more than 3 years.



**FIGURE 3.** Squamous cell carcinoma of the mucous membrane of the alveolar process of the mandible, which appeared under the metal non-movable denture. Appearance of the tumor after removal of the denture.

Before the denture, according to all the examinees, dentists did not reveal any pathological changes from the mucous membranes of the oral cavity.

In all 39 subjects (100%) with malignant neoplasms of the oral mucosa, we found non-removable metallic inclusions in the oral cavity (crowns and/or bridges of stainless steel, chromium-cobalt (chromium-nickel) alloy, nitride-titanium coating, cermet prosthesis). In 31 subjects (in 79.5%) in the oral cavity there were constructions made of different types of metals and their alloys.

When visual inspection of the surface of non-removable metal structures (dentures), which were in the area of the pathological focus, we found: the fractures in places of soldering – in 16 people (41.0%), cracks or complete violation of the integrity (fracture) of the fixed design of dentures in the place of soldering – in 12 people (30.8%), a dark oxide film at the location of the solder – in 17 people (43.6%), areas of corrosive lesions – in 12 people (30.8%), uneven distribution of the metal protection coating (MPC) from titanium nitride over the denture surface, i.e. found “bald” areas – in 14 people (35.9%). In 19 subjects (48.7%), these clinical symptoms were combined with each other, i.e. there were two or even three of these disorders (changes from a non-removable denture). In all examined patients with malignant tumors of the oral mucosa, we found metal dentures with defects.

Values of galvanic potentials between metallic inclusions (M-M) of the oral cavity (crowns and bridges) were  $187.9 \pm 21.2$  mV and ranged from 140 mV to 330 mV (Table 1). Values of potentials from 140 to 150 mV were detected in 5 out of 39 subjects (12.8%). Values of galvanic potentials from 160 to 200 mV were observed in 6 patients (15.4%), from 210 to 300 mV in 20 patients (51.3%), from 310 to 330 mV in 8 patients (20.5%).

The magnitude of the current between the metallic prostheses of the oral cavity (M-M) was  $18.5 \pm 3.6$   $\mu$ A and was in the range from 5  $\mu$ A to 39  $\mu$ A (Table 1). Current intensity less than 10  $\mu$ A was detected in 8 patients (20.5%), from 11 to 19  $\mu$ A – 18 patients (46.2%), from 20 to 29  $\mu$ A – in 10 patients (25.6%), more than 30 MA – in 3 subjects (7.7%).

The electrical conductivity of the oral liquid in the patients under examination between the metallic prostheses (M-M) was  $24.9 \pm 2.8$   $\mu$ S and was in the range from 8 to 53  $\mu$ S (Table 1). The electrical conductivity of the oral liquid was less than 10  $\mu$ S in 2 patients (5.1%), from 11 to 19  $\mu$ S in 15 patients (38.5%), from 20 to 29  $\mu$ S in 16 patients (41.0%), from 30 to 39  $\mu$ A in 2 patients (5.1%), from 40 to 49  $\mu$ S for 3 patients (7.7%) and more than 50  $\mu$ S for 1 patient (2.6%).

Values of galvanic potentials between metallic inclusions of the oral cavity (crowns and bridges) and mucosa of the alveolar process (M-APM) were  $176.8 \pm 16.3$  mV and ranged from 130 mV to 300 mV (Table 1). Values of potentials from 130 to 150 mV were detected in 7 out of 39 subjects (18.0%). Values of galvanic potentials from 160 to 200 mV – in 7 patients (18.0%), from 210 to

300 mV – in 25 patients (64.0%).

The magnitude of the current between the metallic prostheses of the oral cavity and the mucosa of the alveolar process (M-APM) was  $16.9 \pm 2.9$   $\mu$ A and ranged from 6  $\mu$ A to 33  $\mu$ A (Table 1). Current intensity less than 10  $\mu$ A was detected in 8 subjects (20.5%), from 11 to 19  $\mu$ A – 19 patients (48.7%), from 20 to 29  $\mu$ A – in 12 patients (30.8%).

The electrical conductivity of the oral fluid in the patients under examination between metallic prostheses and the mucosa of the alveolar process (M-APM) was  $23.4 \pm 2.6$   $\mu$ S and was in the range of 7 to 38  $\mu$ S (Table 1). The electrical conductivity of the oral fluid was less than 10  $\mu$ S in 3 patients (7.7%), 11 to 19  $\mu$ S in 16 patients (41.0%), and 20 to 29  $\mu$ S in 19 patients (48.7%), from 30 to 38  $\mu$ A – in 1 patient (2.6%).

Values of galvanic potentials between the mucous membranes of the alveolar processes (APM-APM) of the oral cavity were  $179.1 \pm 18.3$  mV and ranged from 130 mV to 360 mV (Table 1). Values of potentials from 130 to 150 mV were detected in 6 out of 39 subjects (15.4%). Values of galvanic potentials from 160 to 200 mV – in 6 patients (15.4%), from 210 to 300 mV – in 19 patients (48.7%), from 310 to 330 mV – in 8 patients (20.5%).

The magnitude of the strength of the current between the mucous membranes of the alveolar processes (APM-APM) of the oral cavity was  $18.9 \pm 2.8$   $\mu$ A and was in the range from 9  $\mu$ A to 35  $\mu$ A (Table 1). Current intensity less than 10  $\mu$ A was detected in 6 subjects (15.4%), from 11 to 19  $\mu$ A – 20 patients (51.3%), 20 to 29  $\mu$ A – in 8 patients (20.5%), more than 30 MA in 5 subjects (12.8%) The value of the electrical conductivity of the oral fluid in the patients under examination between the mucous membranes of the alveolar processes (APM-APM) was  $23.8 \pm 2.7$   $\mu$ S and was in the range from 7 to 46  $\mu$ S (Table 1). The electrical conductivity of the oral liquid was less than 10  $\mu$ S in 1 patient (2.6%), from 11 to 19  $\mu$ S in 14 patients (35.9%), from 20 to 29  $\mu$ S in 15 patients (38.5%), from 30 to 39  $\mu$ A in 2 patients (5.1%), from 40 to 46  $\mu$ S in 7 patients (17.9%). All the arithmetic mean values obtained during the survey are presented in Table 1. In the same table, the reliability of the obtained indices was measured at different places of measurement with respect to each other.

Based on the analysis of Table 1, we found that in patients with malignant tumors of the mucous membranes of the oral cavity (Fig 3), when there were non-removable metallic inclusions in the oral cavity, the levels of potentiometric parameters between the metallic inclusions increased significantly ( $p < 0.001$ ) (potential differences –  $187.9 \pm 21.2$  mV, current strength – up to  $18.5 \pm 3.6$   $\mu$ A and electrical conductivity of the oral liquid –  $24.9 \pm 2.8$   $\mu$ S), between metallic inclusions and the mucosa of the alveolar process (the potential difference is  $176.8 \pm 16.3$  mV, the amperage – about  $16.9 \pm 2.9$   $\mu$ A and the electrical conductivity of the oral fluid –  $23.4 \pm 2.6$   $\mu$ S) and between the mucous membranes of the alveolar processes (potential differences –  $179.1 \pm 18.3$  mV, current – up to  $18.9 \pm 2.8$   $\mu$ A and the electrical conductivity of the oral fluid is  $23.8 \pm 2.7$   $\mu$ S).

QUESTION OF THE ETIOLOGY OF ORAL MALIGNANT NEOPLASMS

TABLE 1. Potentiometric indicators in patients with malignant tumors of the mucous membranes of the oral cavity.

Observation Group		Number of Subjects	Indicators of Potentiometry		
			Potential Difference (mV)	Current Intensity ( $\mu$ A)	Electric Conductivity of Oral Liquid ( $\mu$ S)
Patients with malignant tumors of the oral mucosa	Between metallic inclusions M-M	39	187.9 $\pm$ 21.2 $p < 0.001$	18,5 $\pm$ 3.6 $p < 0.001$	24.9 $\pm$ 2.8 $p < 0.001$
	Between metallic inclusions and the mucosa of the alveolar process (M-APM)	39	176.8 $\pm$ 16.3 $p < 0.001$ $p_1 > 0.05$	16.9 $\pm$ 2.9 $p < 0.001$ $p_1 > 0.05$	23.4 $\pm$ 2.6 $p < 0.001$ $p_1 > 0.05$
	Between the mucous membranes of the alveolar process (APM-APM)	39	179.1 $\pm$ 18.3 $p < 0.001$ $p_2 > 0.05$	18.9 $\pm$ 2.8 $p < 0.001$ $p_2 > 0.05$	23.8 $\pm$ 2.7 $p < 0.001$ $p_2 > 0.05$
Control group (healthy people)		27	32,6 $\pm$ 2,9	2,9 $\pm$ 0,2	2,7 $\pm$ 0,2

$p$  – reliability of differences compared to healthy people (control group);  
 $p_1$  – reliability of differences between M-M and M-APM;  
 $p_2$  – reliability of the differences in the indicators between the M-APM and the APM-APM.

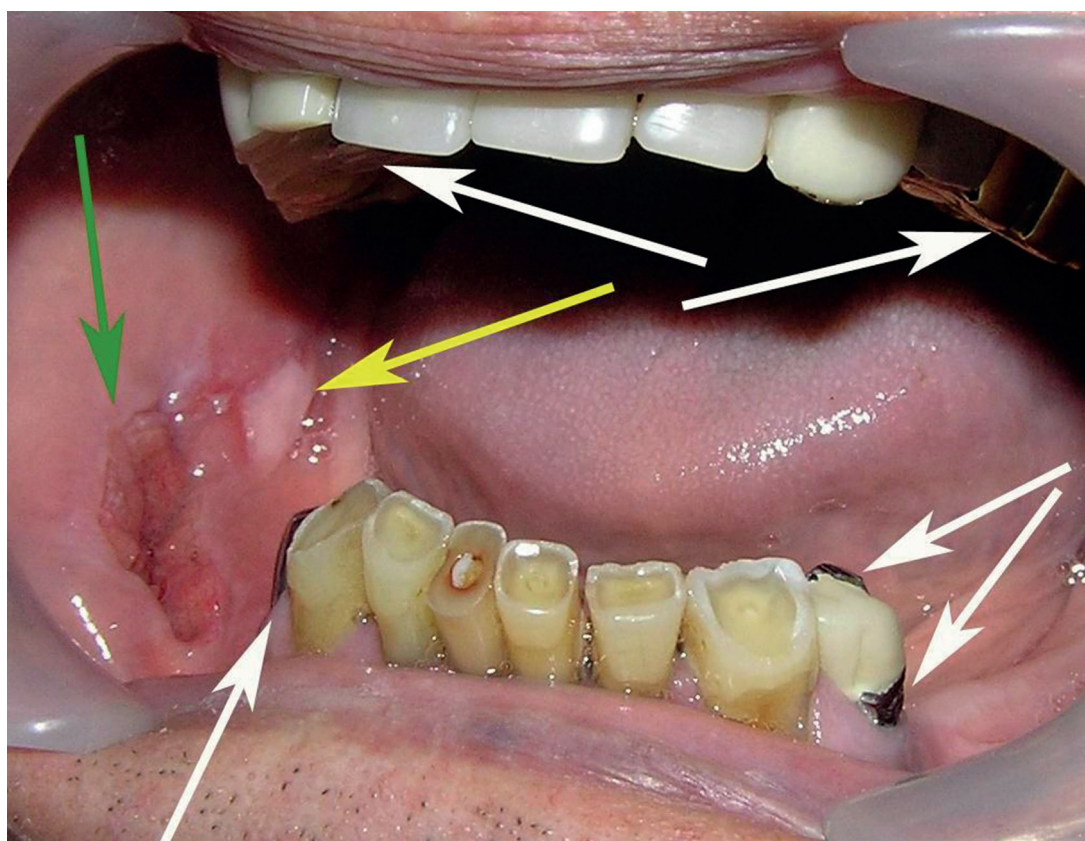


FIGURE 4. Erosive-ulcerative form of squamous cell carcinoma of the mucous membrane of the cheek (green arrow), flat form of leukoplakia (yellow arrow), metallic inclusions (white arrows).



The revealed indices of potential difference, current strength and electrical conductivity of the oral fluid in all patients with metallic inclusions in the oral cavity and malignant tumors of the mucosa of the bottom of the cavity and tongue exceeded the maximum values in healthy people by more than 2-3 or more times (the potential difference of 20- 60 mV, the current strength is from 2 to 5  $\mu$ A, the electrical conductivity of the oral liquid is from 2 to 6  $\mu$ S). It is necessary to pay special attention to the fact that potentiometric indicators, which were detected between metallic inclusions between (M-M); Between metallic inclusions and mucous membrane of the alveolar process of the same jaw (M-APM); Between the mucosa of the alveolar process of one and the other side of the jaw (APM-APM) significantly ( $p > 0.05$ ) did not differ. The latter indicated that high galvanic potentials were already detected in the thickness of the mucous membranes of the oral cavity.

Measurement of the thermoasymmetry of the mucosa of the alveolar processes of the upper and lower jaws (on the side of the tumor location and the healthy side) showed that the temperature difference (thermoasymmetry) was significantly ( $p < 0.05$ ) different from healthy people and was  $1.4 \pm 0.1$  °C (on the upper jaw) and  $1.3 \pm 0.1$  °C (on the lower jaw). In those places where the inflammatory phenomena were more active, the thermoasymmetry reached 1.6 °C.

Thus, based on our survey, it was found that high rates of galvanic currents in the oral cavity (with their prolonged existence) can be one of the factors that can cause the formation not only of premalignant diseases of the oral mucosa and the red border of the lips, but also promote the development of malignant tumors of the oral mucosa. More than 3 times higher than normal values (characteristic for healthy people) potentiometric

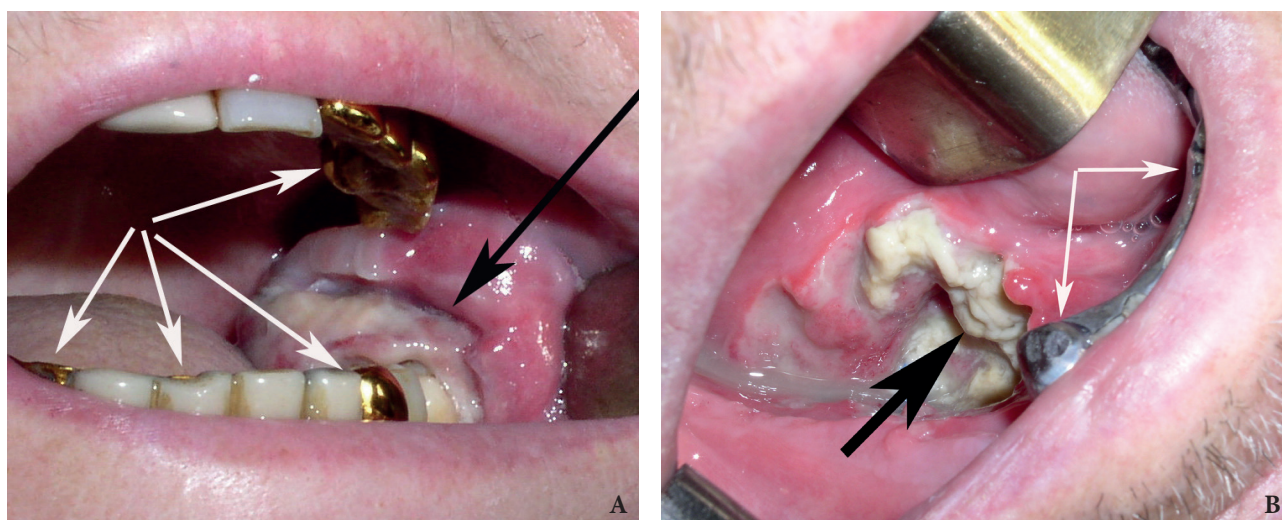
parameters in patients with malignant neoplasms of mucous membranes, in which metal inclusions are located in the oral cavity, differ. A significant increase in the potentiometric parameters not only between the metals of immovable dentures, but also between the metal denture and the mucosa of the alveolar process of the jaw, was found between the different sections of the mucous membranes of the alveolar process.

### Conclusions

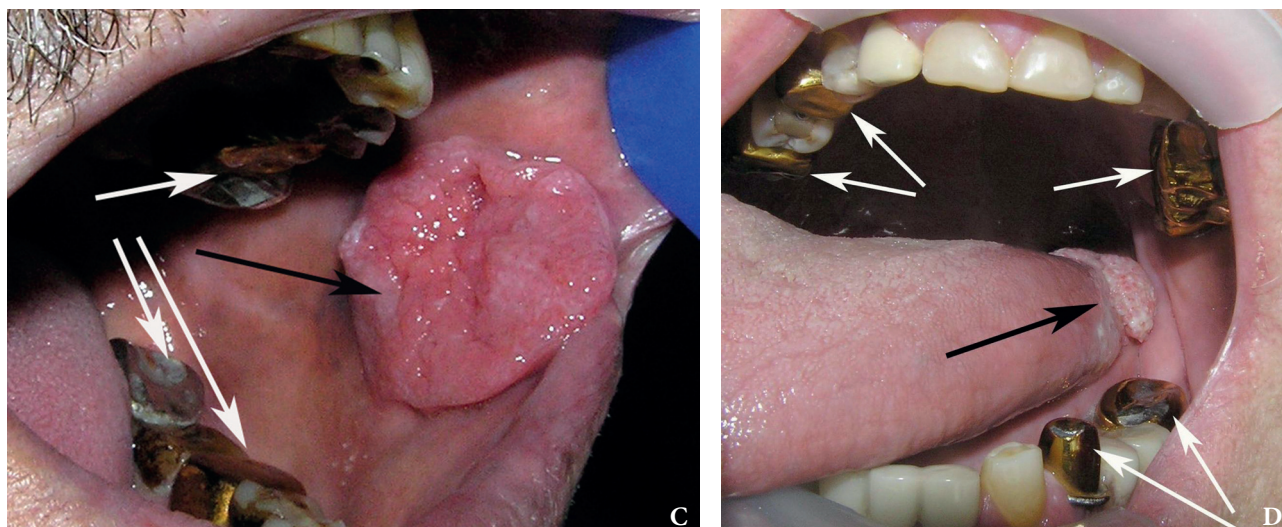
The presence of metal inclusions in the oral cavity in the form of permanent dentures can be one of the reasons for the development of malignant neoplasms [23-31] of the mucous membranes (Fig 5). A significant increase (more than 3 times higher than the normal values) of potentiometric parameters in patients with malignant tumors of the mucous membranes with metallic inclusions in the oral cavity is observed not only between the metals of immovable dentures, but also between the metal denture and the mucosa of the alveolar process of the jaw, between different parts of the mucous membranes of the alveolar process.

High potentiometric indicators were revealed in patients with non-removable metal dentures, which are made of dissimilar metals and their alloys. The presence of defects in the lining of dentures, as well as metal parts of a non-removable structure or metal protective coating ("bald zones") increase the potentiometric parameters and increase the risk of malignant neoplasms of the mucous membranes.

A survey of patients with malignant tumors showed that one of the factors of their development can be high galvanic currents that cause the appearance of cancer of the mucous membranes.



**FIGURE 5.** Different forms of squamous cell carcinoma (black arrows) of the mucous membranes (A-D), which are caused by the presence of metallic inclusions (white arrows) in the oral cavity. (Fig 5 continued on the next page.)



**FIGURE 5. (cont'd).** Different forms of squamous cell carcinoma (*black arrows*) of the mucous membranes (**A-D**), which are caused by the presence of metallic inclusions (*white arrows*) in the oral cavity.

### Funding

None.

### Conflict of Interests

None.

### Role of Authors

Oleksii O. Tymofieiev (concept of the paper, material collection, and editing)

Oleksandr O. Tymofieiev (material collection and writing)

Natalia O. Ushko (material collection and writing)

Mariia O. Yarifa (material collection and writing)

### Ethical Approval

Approval was obtained from the Medical Ethics Committee of the Shupyk National Medical Academy of Postgraduate Education, Kyiv, Ukraine.

### Patient Consent

Written patient consent was obtained to publish the clinical images.

### Acknowledgements

None.

### References

1. Tymofieiev OO. Manual of maxillofacial and oral surgery [Russian]. 5th ed. Kyiv: Chervona Ruta-Turs; 2012.
2. Tymofieiev OO. Essentials of maxillofacial surgery [Russian]. 1st ed. Moskow: Meditsinskoye Informatsionnoye

Agentstvo; 2007.

3. Nespriadko VP, Volynets VM. Peculiarities of the course of the intolerance symptom complex of alloys of metals according to clinical and laboratory studies. *Herald of Dentistry* 1997;2(14):220–4.
4. Onyschenko VS. Intolerance of metal alloys of dentures (clinical and laboratory research). ScD [dissertation]. Kyiv: Shupyk Kyiv Medical Academy of Postgraduate Education; 1995.
5. Tymofieiev OO, Gorobets EV. The etiological role of metallic inclusions of the oral cavity in the development of premalignant diseases and tumors of the maxillofacial region [Russian]. *Modern Dentistry* 2003;4(24):86–9.
6. Tymofieiev OO. The role of the galvanic factor in the development of malignant tumors of oral tissues [Russian]. *Modern Dentistry* 2005;4(32):120–3.
7. Tymofieiev OO. The role of the galvanic factor in the development of osteogenic tumors and tumor-like formations of the mucous membrane of the alveolar process [Russian]. *Modern Dentistry* 2008;1(41):150–4.
8. Onyschenko VS. The use of alloys for the manufacture of dentures. *Dental prosthetics* 2002;1:4–9.
9. Tymofieiev OO, Pavlenko OV. Potentiometric parameters in patients with metallic inclusions in the oral [Russian]. *Modern Dentistry* 2005;2(30):147–9.
10. Tymofieiev OO. Indicators of potentiometry and nonspecific resistance of the organism in patients with metallic inclusions in the oral cavity, fixed on dental implants and teeth [Russian]. *Modern Dentistry* 2005;4(32):133–8.
11. Tymofieiev OO, Pavlenko OV. Metallic inclusions in the oral cavity in orthopedic dentistry [Russian]. *Collection of Scientific Works of Stomatology Institute of NMAPE* 2007;2:70–4.
12. Tymofieiev OO, Pavlenko OV, Kaminsky VV. Metal inclusions fixed on dental implants [Russian]. *Collection of Scientific Works of Stomatology Institute of NMAPE* 2007;2:84–8.
13. Fernandes RP, Quimby A, Salman S. Comprehensive reconstruction of mandibular defects with free fibula flaps and endosseous implants. *J Diagn Treat Oral Maxillofac Pathol* 2017;1(1):6–10.

14. Tymofieiev OO, Ushko NO, Tymofieiev OO, Yarifa MO, Fesenko IeI. Prevention of inflammatory complications upon surgeries in maxillofacial region. *J Diagn Treat Oral Maxillofac Pathol* **2017**;1:105–12.
15. Maulinaa T, Iskandarsyahb A, Hardiantoa A, et al. The incidence of oral squamous cell carcinoma (OSCC) and its relationship with orofacial pain in oral cancer patients in West Java Province, Indonesia. *J Oral Maxillofac Surg Med Pathol* **2017**;29:29–32.
16. McMahon J, Devine JC, McCaul JA, McLellan DR, Farrow A. Use of Lugol's iodine in the resection of oral and oropharyngealsquamous cell carcinoma. *Br J Oral Maxillofac Surg* **2010**;48:84–7.
17. Umeda M, Shigeta T, Takahashi H, Minamikawa T, Komatsubara H, Oguni A, et al. Clinical evaluation of Lugol's iodine staining in the treatment of stage I–II squamous cell carcinoma of the tongue. *Int J Oral Maxillofac Surg* **2011**;40:593–6.
18. Woolgar JA, Triantafyllou A. A histopathological appraisal of surgical margins in oral and oropharyngeal cancer resection specimens. *Oral Oncol* **2005**;41:1034–43.
19. Weinstock YE, Alava 3rd I, Dierks EJ. Pitfalls in determining head and neck surgical margins. *Oral Maxillofac Surg Clin North Am* **2014**;26:151–62.
20. Yamada S, Kurita H, Shimane T, Kamata T, Uehara S, Tanaka H, Yamamoto T. Estimation of the width of free margin with a significant impact on local recurrence in surgical resection of oral squamous cell carcinoma. *Int J Oral Maxillofac Surg* **2016**;45(2):147–52.
21. Brown JS, Shaw RJ, Bekiroglu F, Rogers SN. Systematic review of the current evidence in the use of postoperative radiotherapy for oral squamous cell carcinoma. *Br J Oral Maxillofac Surg* **2012**;50:481–9.
22. Chen TC, Wang CP, Ko JY, Yang TL, Lou PJ. The impact of pathologic close margin on the survival of patients with early stage oral squamous cell carcinoma. *Oral Oncol* **2012**;48:623–8.
23. Sopka DM, Li T, Lango MN, Mehra R, Liu JC, Burtness B, et al. Dysplasia at the margin? Investigating the case for subsequent therapy in 'low-risk' squamous cell carcinoma of the oral tongue. *Oral Oncol* **2013**; 49:1083–7.
24. Hinerman RW, Mendenhall WM, Morris CG, Amdur RJ, Werning JW, Villaret DB. Postoperative irradiation for squamous cell carcinoma of the oral cavity: 35-year experience. *Head Neck* **2004**;26:984–94.
25. Brandwein-Gensler M, Teixeira MS, Lewis CM, Lee B, Rolnitzky L, Hille JJ, et al. Oral squamous cell carcinoma: histologic risk assessment, but not margin status, is strongly predictive of local disease-free and overall survival. *Am J Surg Pathol* **2005**;29: 167–78.
26. Smits RW, Koljenovic S, Hardillo JA, Ten Hove I, Meeuwis CA, Sewnaik A, et al. Resection margins in oral cancer surgery: room for improvement. *Head Neck* **2015**.
27. McDowell JD. An overview of epidemiology and common risk factors for oralsquamous cell carcinoma. *Otolaryngol Clin North Am* **2006**;39:277–94.
28. Harrison LB, Sessions RB, Hong WK. Head and neck cancer: a multidisciplinary approach. USA: Lippincott Williams and Wilkins; **2009**.
29. Hernández-Guerrero JC, Jacinto-Alemán LF, Jiménez-Farfan MD, Macario-Hernández A, Hernández-Flores F, Alcántara-Vázquez A. Prevalence trends of oral squamous cell carcinoma. Mexico City's General Hospital experience. *Med Oral Patol Oral Cir Bucal* **2013**;182:e306–11.
30. Neville BW, Day TA. Oral cancer and precancerous lesions. *Cancer J Clin* **2002**;524:195–215.
31. Feller L, Lemmer J. Oral squamous cell carcinoma: epidemiology, clinical pre-sentation, and treatment. *J Cancer Ther* **2012**;3:263–8.

Tymofieiev OO, Tymofieiev OO, Ushko NO, Yarifa MO.  
 Question of the etiology of malignant neoplasms.  
*J Diagn Treat Oral Maxillofac Pathol* **2017**;1:175–182.  
<http://dx.doi.org/10.23999/j.dtemp.2017.3-4.11>



## Prospects of Dental Implants Placement in Cases of Periodontal Disease\*

Oleksandr O. Tymofiev<sup>1,\*</sup>, Mariia O. Yarifa<sup>2</sup>

<sup>1</sup> Associate Professor of the Dentistry Department of Shupyk National Medical Academy of Postgraduate Education (Assoc Prof, ScD)

<sup>2</sup> Associate Professor of Surgical Dentistry and Maxillofacial Surgery Department of PHEE "Kyiv Medical University" (PhD)

### ABOUT ARTICLE

#### Article history:

Paper received 09 November 2017

Accepted 12 November 2017

Available online 28 December 2017

#### Keywords:

Peri-implantitis

Galvanosis

Galvanism

Dental implantation

Eludril

Elugel

Parodium

Elgydium

### ABSTRACT

#### Purpose.

Determining the effectiveness of Pierre Fabre Oral Care (French laboratory) hygienic remedies of oral care after conducting all stages of dental implantation in cases with periodontitis.

#### Methods.

A survey was held on 65 patients, divided into 2 observation groups: 33 patients with periodontal disease (chronic generalized periodontitis of mild and moderate severity), which during four weeks (one month) after dental implant installation were conducting hygienic care of oral cavity using remedies of Pierre Fabre Oral Care laboratory and 32 patients without periodontal disease and other accompanying diseases (practically healthy people), which next day after dental implant installation started doing hygienic care of oral cavity using traditional oral care products for duration of one month.

#### Results.

Based on acquired data, hygienic oral care using Pierre Fabre Oral Care laboratory products has proven to be effective in cases with periodontal disease after conducting surgical stage of dental implantation, which allowed reducing the amount of postoperative inflammatory complications.

#### Conclusion.

It is recommended to use hygienic oral care products of Pierre Fabre Oral Care laboratory after conducting dental implantation to prevent the occurrence of early and late inflammatory complications.

© 2017 OMF Publishing, LLC. This is an open access article under the CC BY licence (<http://creativecommons.org/licenses/by-nc/4.0/>).

### Introduction

Some of the relative local contraindications to dental implantation are periodontal diseases (periodontitis, gingivitis) and unsatisfactory oral hygiene, which is often present in cases with given pathology. Most frequent complication, which may appear in postoperative period in cases of periodontal disease is peri-implantitis. Frequency of complications, which appear after dental implantation, based on authors, is from 0.4% to 5% [1-7].

Success of dental implantation, after completion of its surgical stage, is possible only if the patient is correctly conducting oral care hygienic procedures in postoperative period. The lifespan of dental implants is affected by thorough abundance of oral hygiene similar to

one after surgical stage of dental implantation.

Metal dentures, fixed on dental implants, take part in electrochemical reactions and may be affected by corrosion, which slows regenerative processes of bone tissue in regions of conducted implantation and contributes to the development of postimplantation complications (Tymofiev, 2005; Tymofiev, Pavlenko, 2007; et al.).

In conditions of oral cavity metallic implants and their supraconstruction, as also non-removable metallic dentures, are entering an electrochemical reaction. Resulting difference in electrogalvanic potentials between metallic elements (implant, suprastructure, dentures) leads to formation of electric current, which is accompanied by release of products of electrolysis of metal alloys into the oral fluid with the spread and accumulation of them in the patient's body (Onischenko, 1995; Ilyk, 1999; Kordiyak, 2001; Leonenko, 2003; Tymofiev, 2006, et al.).

Usage of metallic dental implants with metallic contents (abutment, denture) in some cases may lead to development of complications in form of certain

\*This manuscript has not been presented

\* Corresponding author. Department of Dentistry, Shupyk NMAPE, 10-a Pymonenka Street, Kyiv 04112, Ukraine. Tel.: +38 (050) 584 77 37. E-mail address: [sanavistima@gmail.com](mailto:sanavistima@gmail.com) (O.O. Tymofiev)

clinical forms of intolerance (galvanosis) of metal alloys of dentures (galvanic, allergic, reflex, toxic or combined) or galvanism. In the galvanic and reflex form of intolerance to metal alloys, galvanic currents are the main active factor, in the case of allergic and toxic – the products of electrolysis of metal alloys, and when combined – galvanic currents and electrolysis products to the same extent. In cases of galvanism, there is no clinical symptomatology of the disease with significantly increased potentiometric parameters, which lead to the development of local complications in the oral cavity.

The purpose of the study is to determine the effectiveness of oral care hygiene products of the French laboratory Pierre Fabre Oral Care after all stages of dental implantation in cases with periodontal disease.

### Material and Methods

The examination was carried out on 65 patients, which were divided into 2 observation groups:

- main group – that is 33 patients with periodontal disease (chronic generalized periodontitis of mild and moderate severity) who, after setting dental implants for four weeks (one month), performed hygienic oral care with Pierre Fabre Oral Care (Pierre Fabre Pharmaceuticals, France);

- control group – 32 patients without periodontal disease and other local concomitant diseases (practically healthy people) which on the next day after the completion of the surgical stage of dental implantation performed oral hygiene with traditional care products for one month.

In all examined cases, we used dental implants (Alpha Bio system, Israel).

In the first observation group for oral hygiene we used products of the French laboratory Pierre Fabre Oral Care.

“Eludril®” is an antiseptic solution for mouth rinsing. 100 ml of the solution contains 0.5 ml (0.1%) of chlorhexidine digluconate and 0.5 g (0.5%) of chlorobutanol hemihydrate. Chlorhexidine digluconate has a bactericidal (wide active spectrum) and fungicidal action, also helps to remove dental plaque. The drug also contains sodium docusate, which prevents chlorhexidine from rinsing off the surface of the oral mucosa. The duration of the action is 8 hours. Chlorobutanol enhances the action of chlorhexidine and has a local analgesic effect.

“Elgidium clinics®” toothbrushes are designed for cleaning teeth several hours after the completion of surgery and until the complete healing of the postoperative wound. These toothbrushes are represented by three of their kind: postoperative (indicated by the numbers 7/100) – is intended for gentle massage of the gums and cleansing of the teeth within 7-10 days after surgery; surgical (indicated by

the numbers 15/100) – for a gradual return to normal tooth cleaning (used more often on the 7-10th day after surgery for the next two weeks); soft (can be indicated by the numbers 20/100) – used for daily brushing of teeth in the future.

When brushing the teeth (morning and evening), we recommended patients of the first group to use the toothpaste “Elgidium®” (antibacterial paste with chlorhexidine, 25% calcium carbonate and Irish moss). Toothpaste easily eliminates dental plaque and has anti-inflammatory and hemostatic effects. Patients brushed their teeth for 2-3 minutes twice a day.

“Elgidium trio compact®” mini-brushes are used to provide maximum hygiene in hard-to-reach areas between the teeth. The interdental toothbrushes (wide and narrow) are equipped with three replaceable brushes. A set of brushes with fibers of different diameters for wide interdental spaces consists of a microfiber of cylindrical shape with a diameter of 1.9 mm, thin fibers of a conical shape with a diameter of 4-3 mm, wide fibers of a conical shape with a diameter of 5-4 mm. A set of brushes with fibers of different diameters for narrow interdental spaces consists of a microfiber of cylindrical shape with a diameter of 1.9 mm, microfibers of a conical shape with a diameter of 2.7-2.5 mm, wide fibers of a conical shape 3.5-2.7 mm in diameter. Each kit contains two identical cartridges, one of which is a spare one. For the patient, only one set is needed with the required fiber diameter (indicated on the package in a colored circle). The set of brushes can be with fibers of the same diameter (for narrow or wide interdental spaces). The color of the circle in which the diameter value is indicated corresponds to the color of the mini brush that is fixed in the cartridge. Mini-brushes have an ultrathin rod, which easily bends and facilitates cleaning in hard-to-reach areas. Protective cartridge-handle allows compact and reliable storage of brushes. The interdental brush is inserted into the interdental space perpendicular to the tooth surface and moved by shifting movements inward and outward. Microfibers easily clean the interdental spaces.

To prevent the development of inflammatory complications after the surgical stage of dental implantation, the antiseptic periodontal gel “Elugel®” was used in the first observation group, which contains 0.2% chlorhexidine digluconate (has antibacterial properties and fungicidal action) and sodium hydroxide (changes the pH of saliva to alkaline side, which can replace soda rinses). After rinsing with Eludril, periodontal gel was applied in the morning to the suture material (postoperative wound), gum and teeth for 7-10 days. In the evening, for 7-10 days after the surgical stage of dental implantation, the applique of the gel with rhubarb extract – “Parodium®”, which contains 0.02% chlorhexidine digluconate (prophylactic dose), 0.2% rhubarb root extract and 0.00067% formaldehyde, was applied to the postoperative wound. Parodium has a

hemostatic and deodorant effect.

On all observed patients conventional clinical methods of examination were conducted: finding complaints, collecting anamnesis, examining the maxillofacial region and palpation of regional lymph nodes, examining the oral cavity, palpating the gums, percussion of the teeth, determining the mobility of teeth and the depth of the dentogingival pockets, radiography. Given that the patients of the first observation group had periodontal disease (chronic generalized periodontitis of mild and moderate severity), they underwent pathomorphological examinations of gingiva tissues in the areas where the dental implants placement was subsequently carried out. Material for pathohistological examination was taken by excision of soft tissues in their entire thickness during the surgical stage of dental implantation.

Half a year after the fixation of the cermet dentures to the installed dental implants, the patients underwent potentiometric examination. For this purpose we used the automatic digital potentiometer (Pitterling Electronic GmbH  $\mu\text{g}$ -potential, Munchen, Germany). All subjects underwent three-time measurement of potentiometric parameters in the same place with calculation of arithmetic mean value. The potentiometric parameters were measured in the following sections (points): between metallic inclusions (M-M); between metallic inclusions and dental implants (M-DI); between the mucosa of the alveolar bone and the dental implant (ABM-DI); between the mucosa of the alveolar bone and the metal of the dental prosthesis (ABM-M). Contact of the electrode of the potentiometer with the dental implant was carried out by touching directly the dental implant (more often in its neck region), if possible, or by carrying out on-bone (in the implant area) potentiometric measurements. An electrode-needle, introduced by Tymofeiev [8], was used to carry out potentiometer potentiometric measurements.

To assess the effectiveness of hygiene products use, survey methods were carried out. The effectiveness of hygiene products was determined by the following indicators: indices of hygiene of the oral cavity OHI-S (indices of oral hygiene – simplified) (Green, Vermilion, 1964); The Schiller-Pisarev test; Papillary-marginal-alveolar index (PMA); Gingivitis indices and plaque indices (PI-Plax Index) by Silness and L oe (1964, 1967).

The obtained digital data of laboratory examinations was processed by a conventional variational-statistical method using a personal computer and a package of statistical programs “SPSS 11.0 for Windows” and “Microsoft Excel 2016”. Reliability of the survey results was assessed by Student criteria. Differences were considered significant at  $p < 0.05$ .

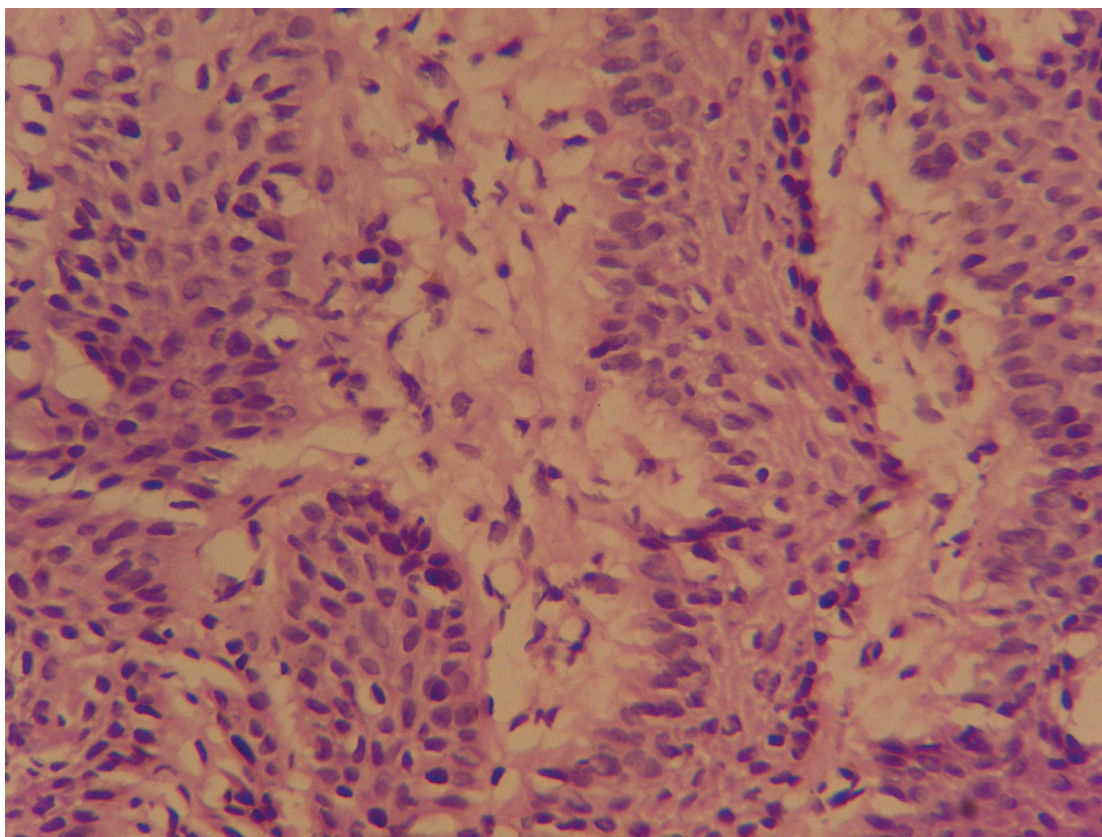
## Results

As already mentioned earlier, the patients of the main group were persons with periodontal diseases – chronic

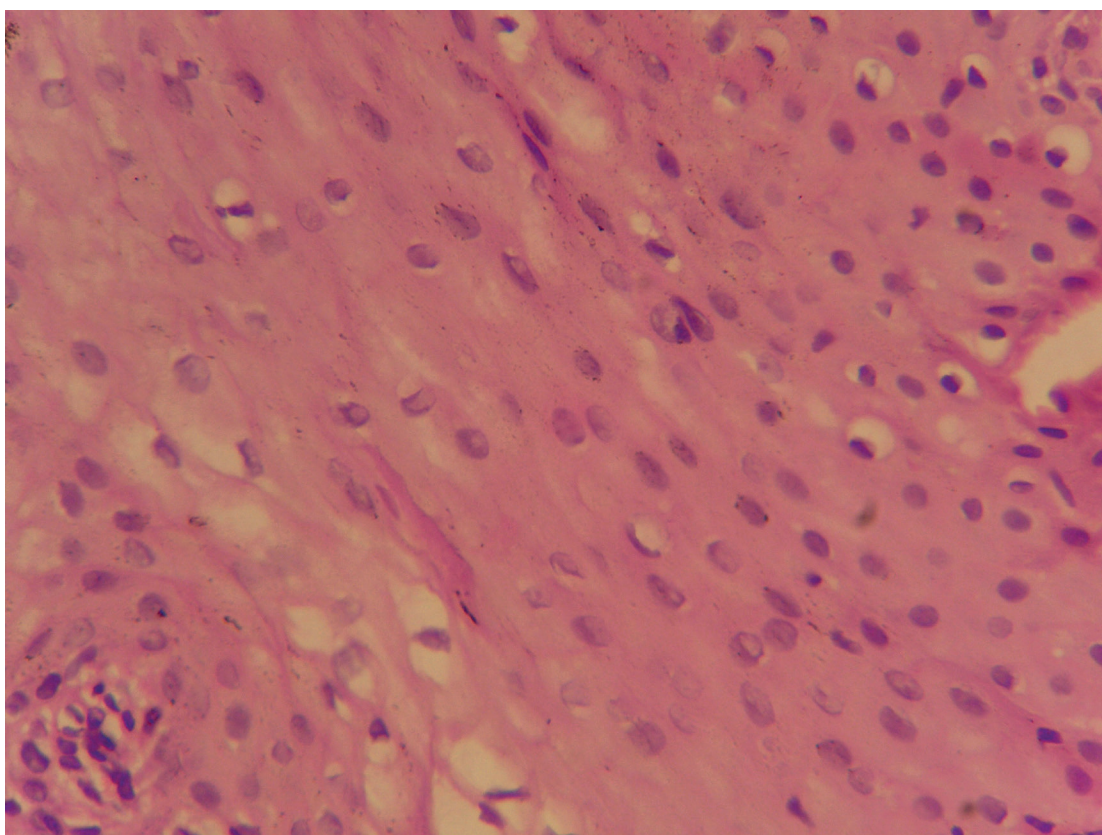
generalized periodontitis [9-13], the main symptoms of which were: chronic inflammation of the gingiva, presence of periodontal pockets, resorption of the bone tissue of the alveolar process, mobility of the teeth. In 17 out of 28 examined cases (60.7%) mild periodontitis was revealed: the depth of the periodontal pockets was less than 3.5 mm, mainly in the interdental space, there was no tooth mobility, their displacement was not expressed. 11 out of 28 patients (39.3%) had periodontitis of moderate severity: the depth of the periodontal (periodontal) pocket to 5 mm, the resorption of the bone tissue of the interdental partitions from 1/3 to 1/2 of their height, the mobility of the teeth was I-II degree, tremes were present, traumatic occlusion was expressed.

During the surgical stage of dental implantation, we took gum pieces for pathomorphological studies. In the cases with periodontal disease, basal cell hyperplasia of the epithelium of the mucosa with inverting growth and the formation of multiple protrusions of its own layer was shown (Fig 1), with violation of cell differentiation and thinning of the epithelial layer. Signs of parakeratosis (Fig 2), acanthosis and edema (Fig 3) have been noted in the epithelium of the mucous membrane of the alveolar bone. In the epithelium, pronounced dystrophic changes and disregeneration of the epithelial layer were observed. With the ulcerative form of chronic gingivitis, the granulation tissue in the gingiva was enlarged (Fig 4). In the presence of exacerbation of the inflammatory process, leukocyte infiltration in the layer of the integumentary flat epithelium of the gingival mucosa and focal destruction of epithelial cells were detected [14-17]. In the papillae of the mucous membrane of the alveolar bone, blood overflow of the vessels of the microvasculature was observed (Fig 5), as well as endothelial proliferation (Fig 6) and vascular thrombosis (Fig 7). There was an edema of intrinsic layer of the mucous membrane of the gum with the dilatation of the vessels of the microvasculature (Fig 8), fibrosis and focal perivascular hyalinosis (Fig 9). The cellular composition of the inflammatory infiltrate in its own layer of the mucosa was represented by the predominance of macrophage cells and eosinophils.

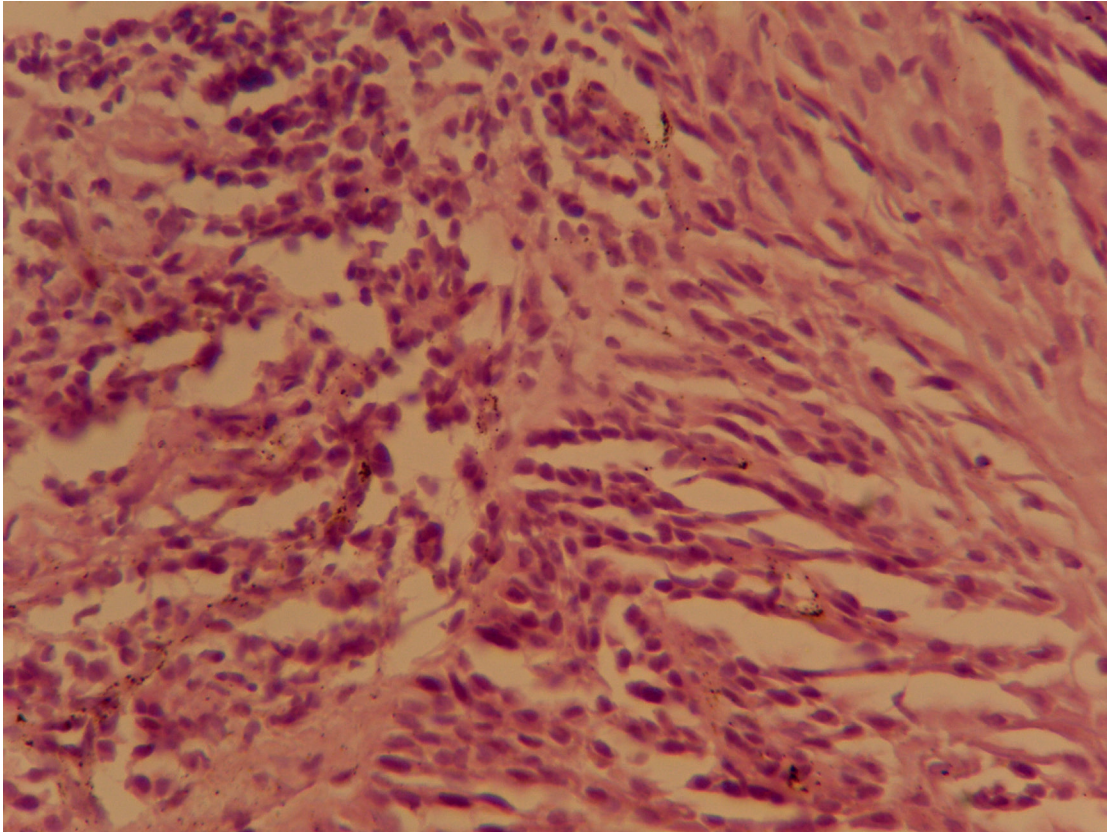
Evaluation of the hygienic Green-Vermillion (OHI-S) index was carried out on 29 primary and 27 control group patients after the surgical stage of treatment. We used the scheme proposed by Luts kaya *et al.* The day before the surgery (dental implantation), i.e. on the eve of the operation (Fig 10), values of this index in the main observation group were  $1.83 \pm 0.06$  conventional units (index score is high), which was assessed as unsatisfactory oral hygiene. In the control group –  $1.49 \pm 0.15$  conventional units (index score is average, and the assessment of oral hygiene is satisfactory) [18-25]. On the 7th day, this index in the main group was  $1.11 \pm 0.03$  units (index score is average, and the assessment of oral hygiene is satisfactory), in the control –  $1.21 \pm 0.10$  conventional units (index score is average, and the assessment of oral hygiene is satisfactory). On the 14th



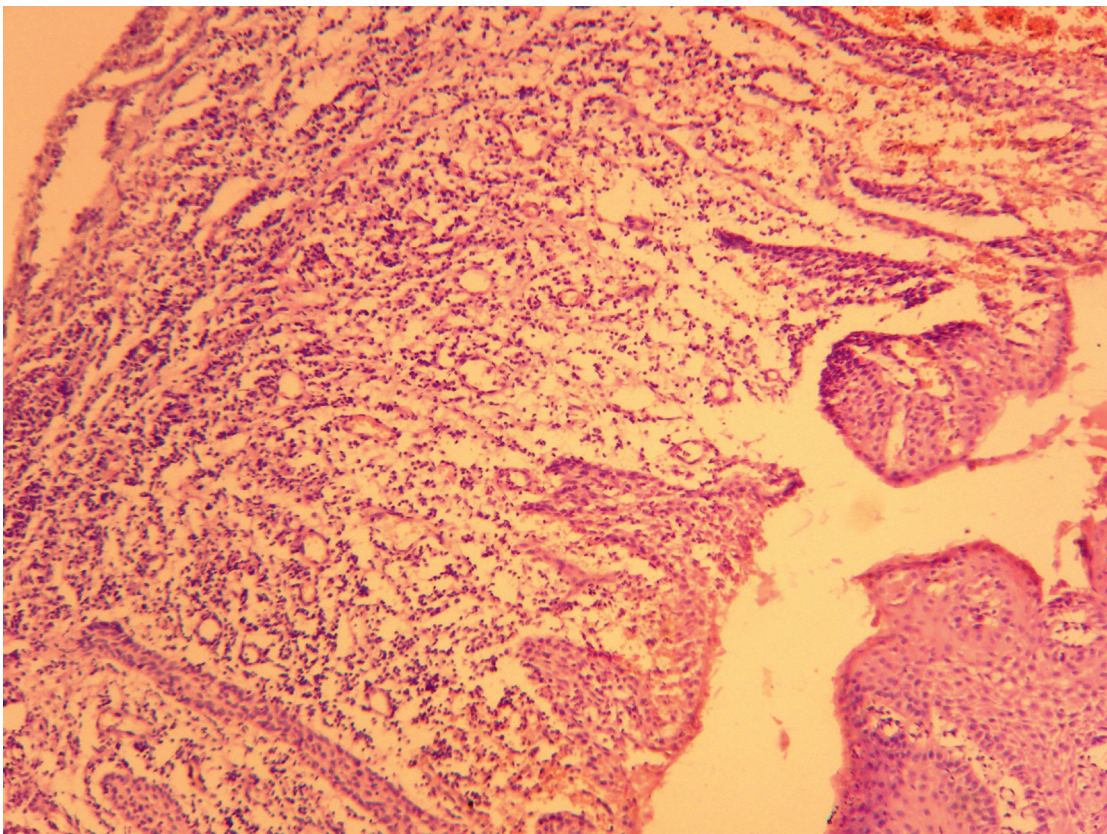
**FIGURE 1.** Basal cell hyperplasia of the mucosal epithelium with inverting growth and the formation of multiple protrusions of its own layer (hematoxylin and eosin stain, x400).



**FIGURE 2.** Signs of parakeratosis of the mucosal epithelium (hematoxylin and eosin stain, x400).

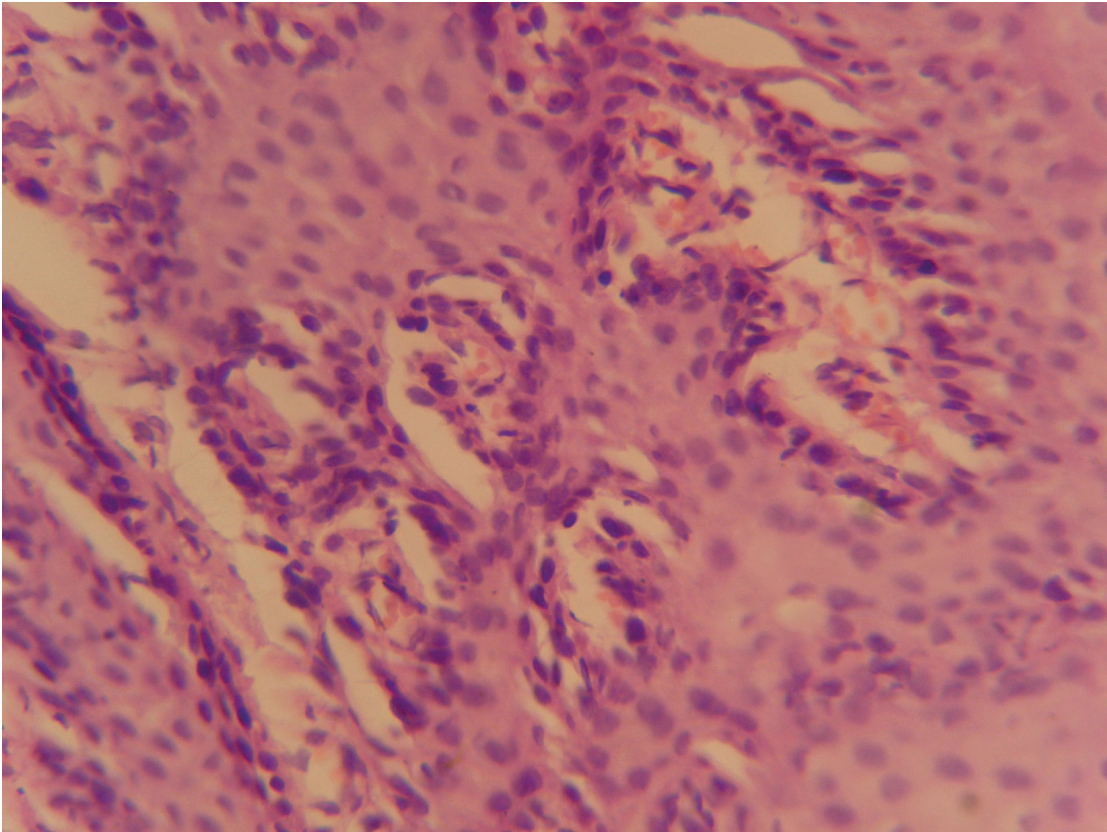


**FIGURE 3.** Hyperplasia of the mucosa with acanthosis of the cells and edema of the epithelial layer (hematoxylin and eosin stain, x400).

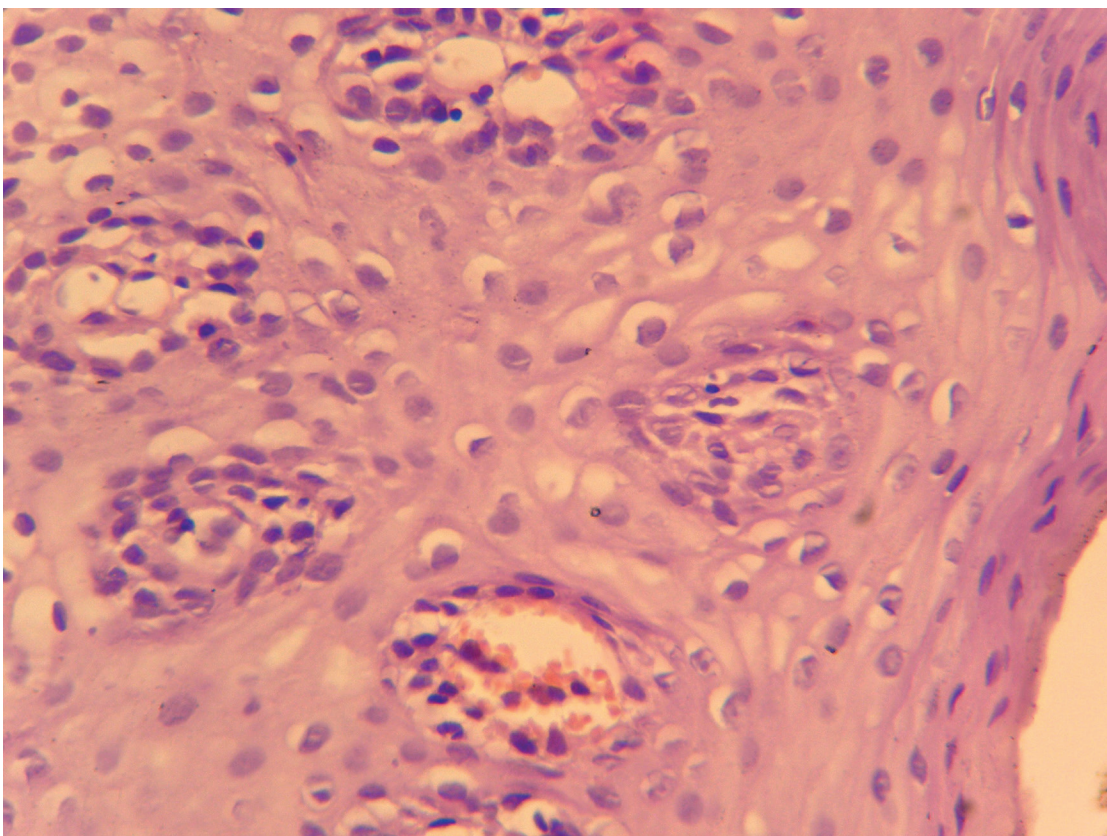


**FIGURE 4.** Formation of granulation tissue in the gingiva with ulcerative form of chronic gingivitis (hematoxylin and eosin stain, x100).

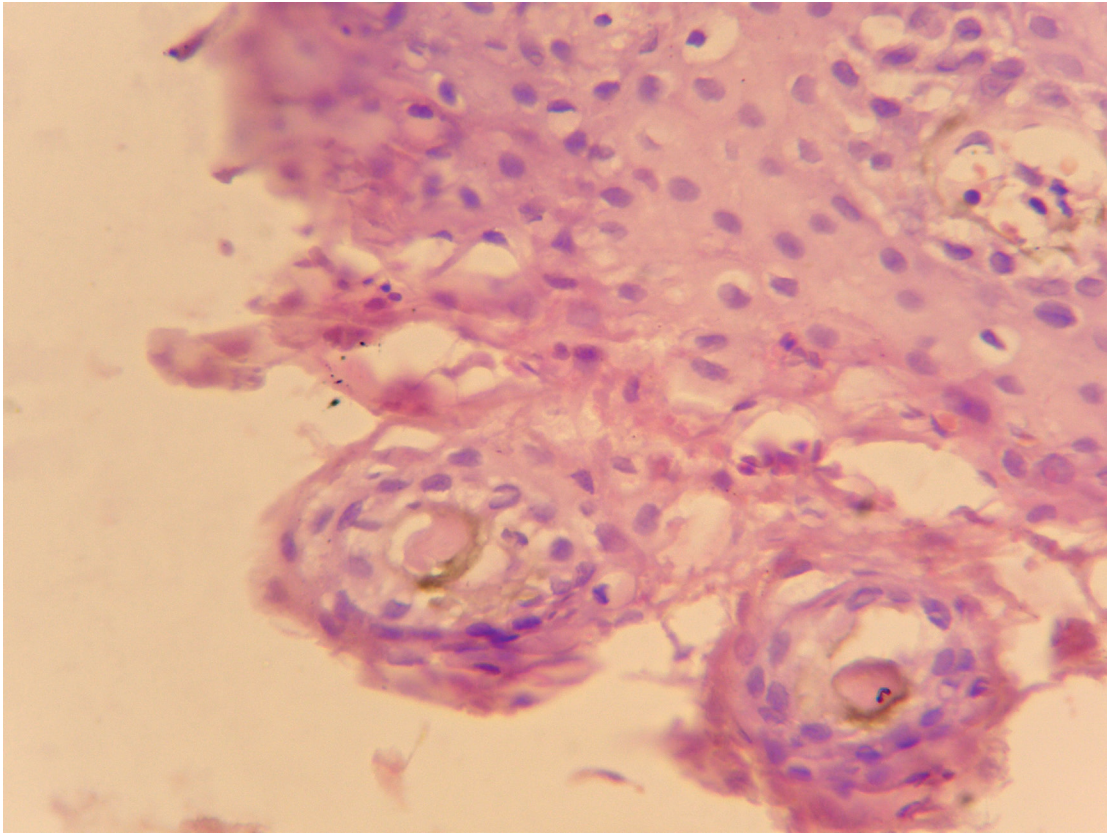




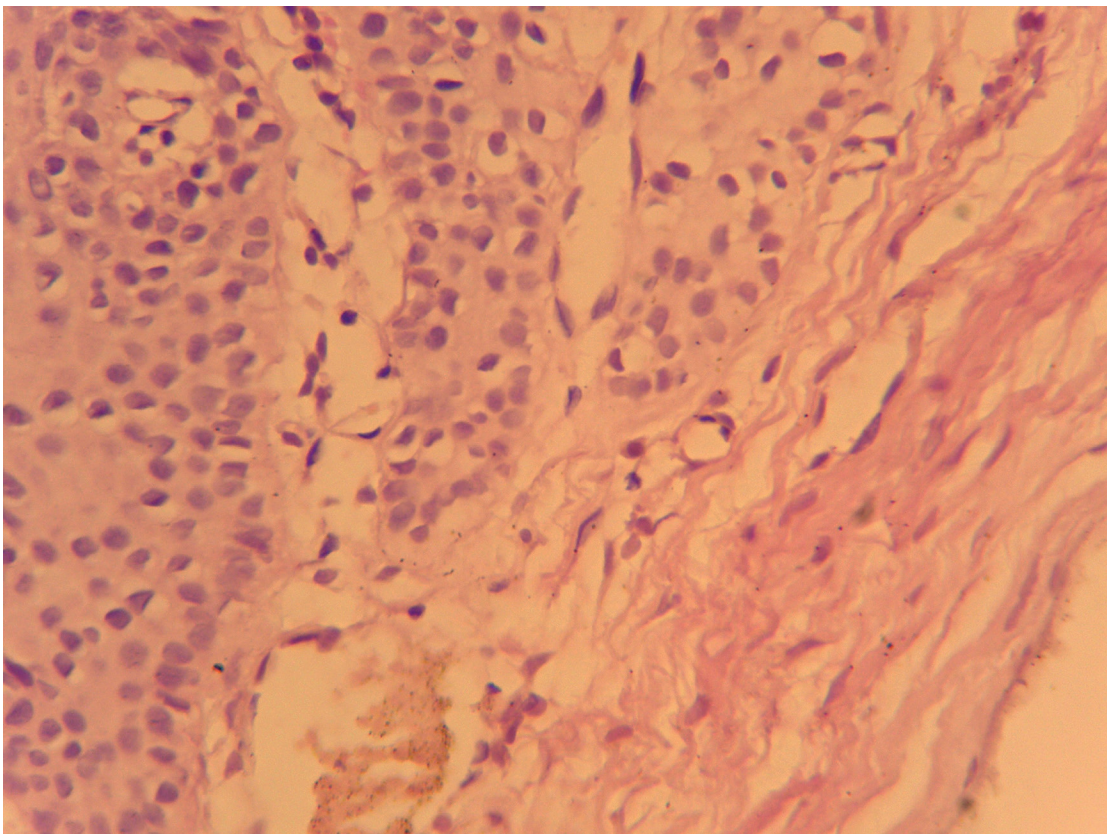
**FIGURE 5.** Blood overflow of vessels of the microvasculature in the papillae of its own layer of the mucous membrane (hematoxylin and eosin stain, x400).



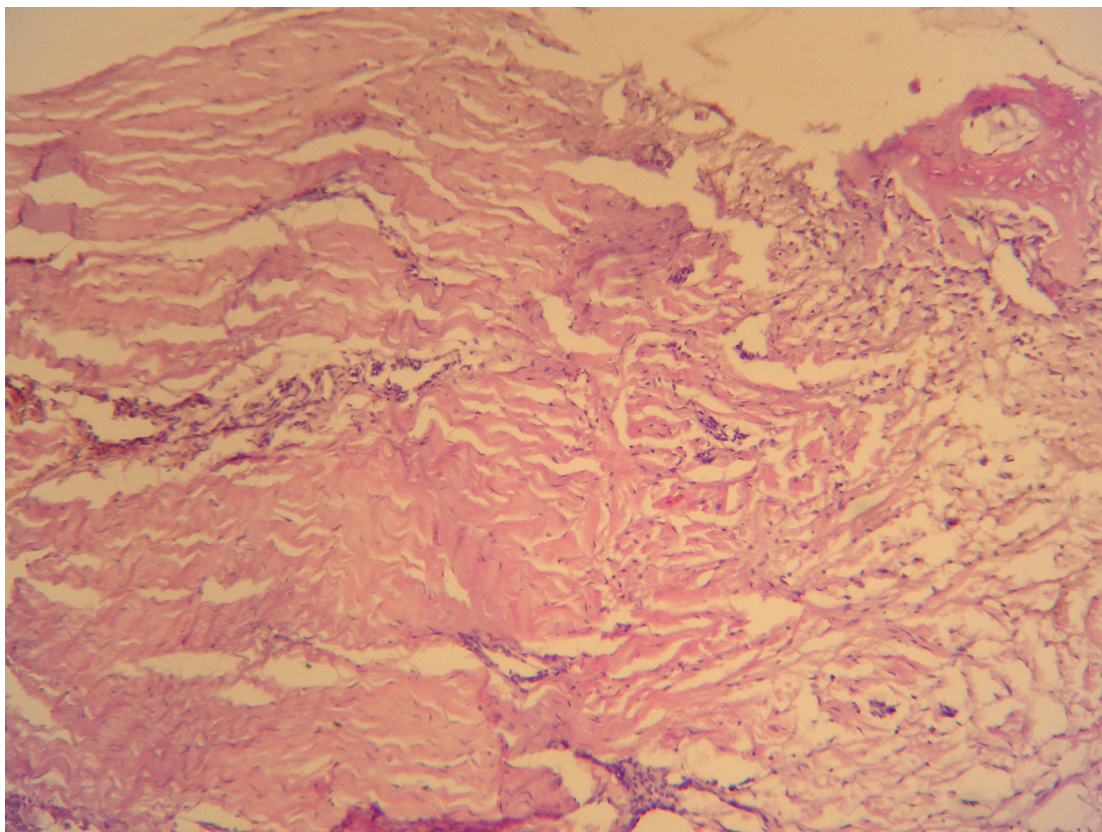
**FIGURE 6.** Proliferation of the endothelium of the vessels of the microvasculature of the papillae of its own layer of the mucous membrane (hematoxylin and eosin stain, x400).



**FIGURE 7.** Thrombosis of the vessels of the microvasculature in the papillae of intrinsic layer of the mucous membrane of the gum (hematoxylin and eosin stain, x400).



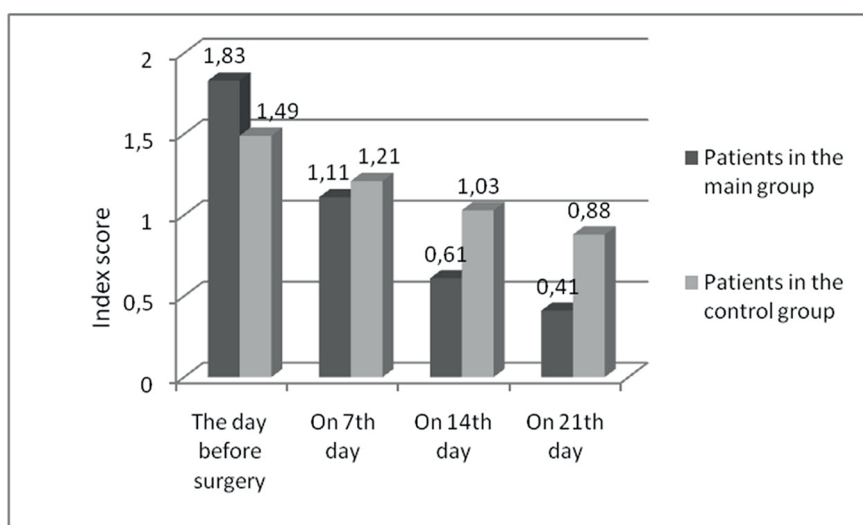
**FIGURE 8.** Edema of the intrinsic layer of the mucosa with the dilatation of the vessels of the microvasculature (hematoxylin and eosin stain, x400).



**FIGURE 9.** Fibrosis and focal perivascular hyalinosis of the intrinsic layer of the gingival mucosa (hematoxylin and eosin stain, x100).

day, this index in the main observation group was  $0.61 \pm 0.03$  units (Index score is low, and oral hygiene assessment is good), in the control –  $1.03 \pm 0.10$  conventional units (index score is average, and the assessment of oral hygiene is satisfactory). On the 21st day, this index in

the main group even more decreased and was equal to  $0.41 \pm 0.02$  conventional units (index score is low, and oral hygiene assessment is good), in control –  $0.88 \pm 0.14$  conventional units (index score is average, and the assessment of oral hygiene is satisfactory).



**FIGURE 10.** Changes in the Green-Vermillion index.

Before the operative intervention (dental implantation), i.e. on the eve of the operation (day before), the Schiller-Pisarev test (iodine number of Svrakov) scores in the cases of the main observation group were  $3.5 \pm 0.3$  points, which indicated a moderate inflammatory process, and in the control group  $3.2 \pm 0.4$  points (Fig 11). On the 7th day after the operation, for the patients of the main observation group, the iodine number of Svrakov was  $2.0 \pm 0.3$  points, which indicated the presence of a poorly expressed inflammatory process,

and in the control group –  $3.0 \pm 0.3$  points (moderately expressed inflammatory process). On the 14th day in the main observation group, the iodine number of Svrakov was  $1.5 \pm 0.1$  points (a mild inflammatory process), in the control group –  $2.8 \pm 0.3$  points (moderately pronounced inflammatory process). On the 21st day after the operation, in the main observation group, the iodine number of Svrakov was  $1.4 \pm 0.1$  points (a mild inflammatory process), in the control group –  $2.4 \pm 0.3$  points (mild inflammatory process).

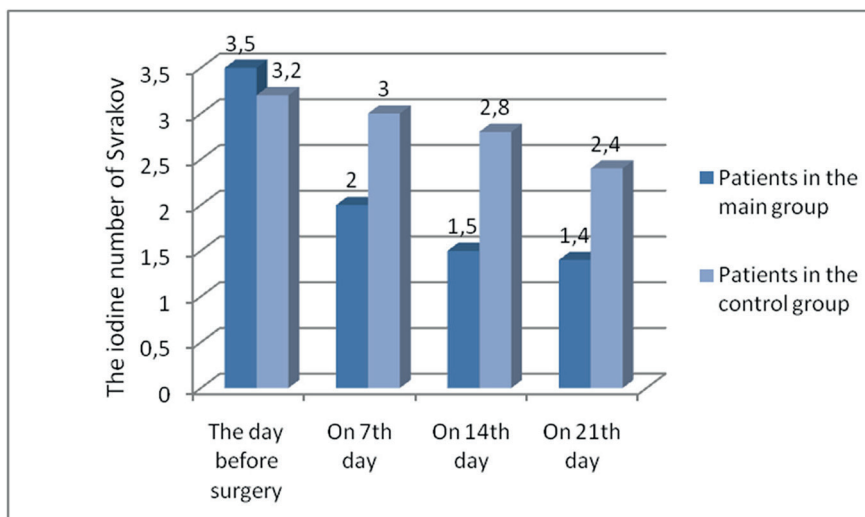


FIGURE 11. Changes in the Schiller-Pisarev test.

Before the operative intervention (dental implantation), i.e. on the eve of the operation (day before), the papillary-marginal-alveolar index (PMA) in the main group (Fig 12) was  $24.0 \pm 1.1\%$ , and in the control group –  $22.4 \pm 1.2\%$  (estimation criterion of PMA index – mild severity of gingivitis). On the 7th day after the operation, the PMA index in the main group was

$18.3 \pm 0.8\%$ , in the control group it was  $21.1 \pm 1.2\%$ . On the 14th day after the operation, the PMA index in the main observation group was  $9.6 \pm 0.7\%$ , in the control group –  $19.8 \pm 1.1\%$ . On the 21st day after the operation, the PMA index in the main group was  $4.8 \pm 0.4\%$ , in the control group –  $17.3 \pm 1.3\%$  (estimation criterion of PMA index – mild severity of gingivitis).

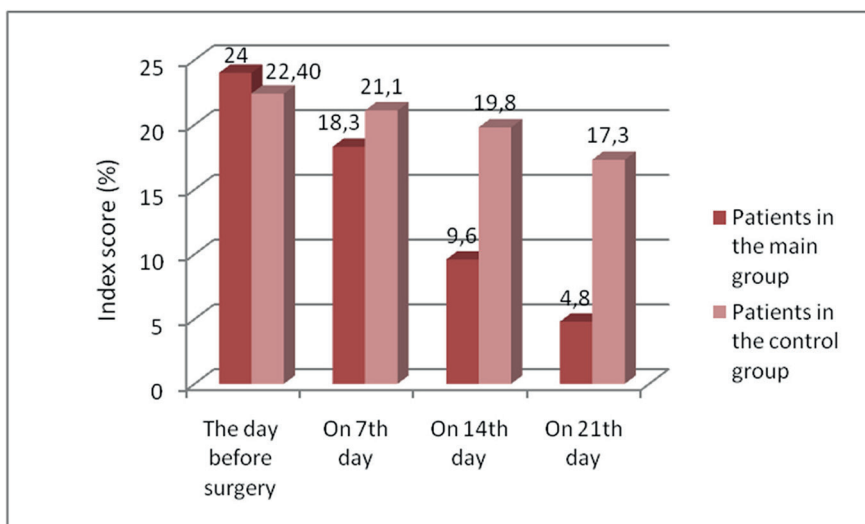


FIGURE 12. Changes in the papillary-marginal-alveolar index (PMA).

The index of gingivitis (IG) of patients of the main observation group (Fig 13) one day before the surgery was  $2.2 \pm 0.1$  points (severe degree of gingivitis), in the control group  $1.5 \pm 0.2$  points (average degree of gingivitis). On the 7th day after the operation, the index of gingivitis in cases of the main group was  $1.5 \pm 0.1$  points (average degree of gingivitis), in the control group –  $1.2 \pm 0.2$  points (average

degree of gingivitis). On the 14th day in patients, the gingivitis index in the main observation group was  $0.9 \pm 0.1$  points (mild gingivitis), in the control group –  $1.2 \pm 0.2$  points (average degree of gingivitis). On the 21st day after the operation, in the main group, the index of gingivitis was  $0.4 \pm 0.1$  points (mild gingivitis), in the control group –  $1.1 \pm 0.1$  points (average degree of gingivitis).

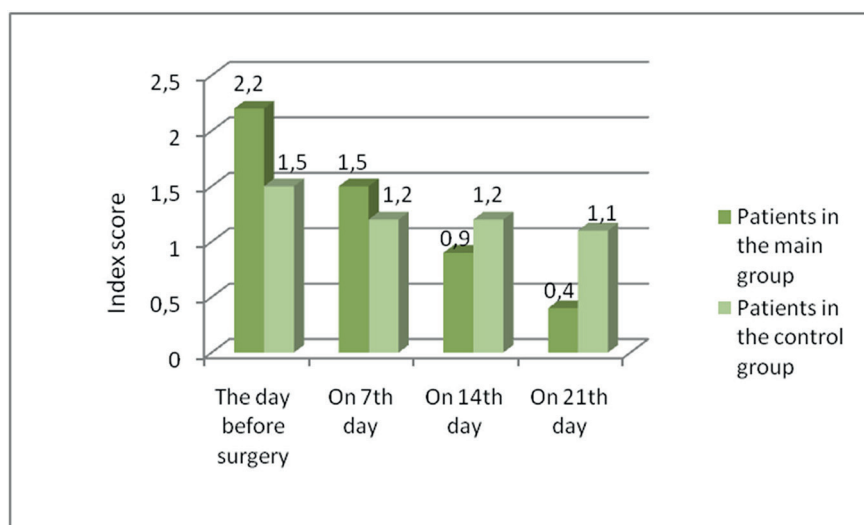


FIGURE 13. Changes in the index of gingivitis (IG).

The index of dental plaque (PI-Plax Index) for patients of the main observation group one day before the surgery was  $1.6 \pm 0.1$ , in the control group –  $1.2 \pm 0.1$  (Fig 14). On the 7th day after the operation, the index of plaque of the patients of the main group was  $1.0 \pm 0.1$ , in the control group –  $1.0 \pm$

$0.1$ . On the 14th day the index of dental plaque in the main observation group was  $0.7 \pm 0.1$ , and in the control group –  $1.0 \pm 0.1$ . On the 21st day after the operation, the index of dental plaque in cases of the main group was  $0.4 \pm 0.1$  points, and in the control group –  $0.9 \pm 0.1$  points, i.e. 2 times higher.

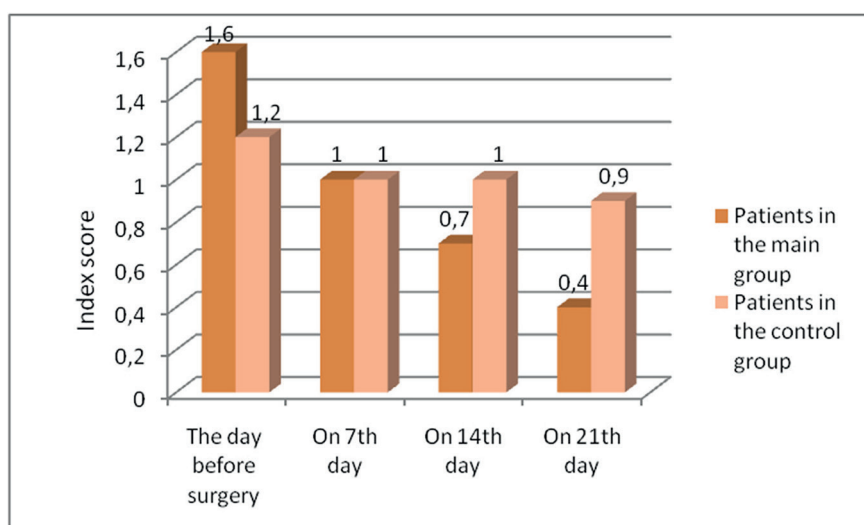


FIGURE 14. Changes in the index of dental plaque (PI-Plax Index).

The Green-Vermillion index, the Schiller-Pisarev test, the papillary-marginal alveolar index, the index of gingivitis and dental plaque of the patients of the main group (after hygienic care of the oral cavity with use of the Pierre Fabre Oral Kea laboratory production) was significantly lower than in the control group ( $p < 0.001$ ).

Early complications in the postoperative period in the main observation group, we observed only in 3 cases (9.1%) – a partial divergence of the sutures. In the control group, early postoperative complications were observed in 8 cases (25.0%). Complications in the control group were the following: mucositis (inflammation of the mucous membrane in the area of the transgingival part of the implant without lysis of bone tissue) – in 3 cases (9.4%); partial divergence of sutures on the postoperative wound – in 4 cases (12.5%); Inflammatory infiltration of maxillary soft tissues and periimplantitis – in 1 case (3.1%) [26-28].

Patients of the main observation group used oral hygiene products of the Pierre Fabre Oral Care laboratory not only in the early postoperative period, but also after the installation of dentures. Patients were examined dynamically during observation.

The values of potentiometric measurements in cases of primary observation group are presented in Table 1.

Healthy people (27 persons) potentiometric parameters were as follows: potential difference –  $32.6 \pm 2.9$  mV; Current intensity –  $2.9 \pm 0.2$   $\mu$ A; The electrical

conductivity of the oral fluid is  $2.7 \pm 0.2$   $\mu$ S.

Analyzing the potentiometric parameters that we obtained between metallic inclusions (M-M) from the main observation group patients (33 people), we established the following (Table 1): potential difference was  $38.8 \pm 2.7$  mV ( $p > 0.05$ ); current strength –  $3.5 \pm 0.3$   $\mu$ A ( $p > 0.05$ ); electrical conductivity of the oral fluid –  $3.0 \pm 0.3$   $\mu$ S ( $p > 0.05$ ). The potentiometric parameters obtained between metallic inclusions and mucous membrane of the alveolar bone (M-ABM) in the main observation group (33 people) were as follows (Table 1): the potential difference was  $40.6 \pm 3.1$  mV ( $p > 0.05$ ); current strength –  $3.7 \pm 0.3$   $\mu$ A ( $p > 0.05$ ); electrical conductivity of the oral fluid –  $3.4 \pm 0.3$   $\mu$ S ( $p > 0.05$ ). The potentiometric parameters between the dental implants and the mucosa of the alveolar bone (DI-ABM) in the surveyed primary observation group (33 patients) were as follows (Table 1): the potential difference was  $37.3 \pm 2.4$  mV ( $p > 0.05$ ); current strength -  $3.4 \pm 0.2$   $\mu$ A ( $p > 0.05$ ); electrical conductivity of the oral fluid –  $3.1 \pm 0.2$   $\mu$ S ( $p > 0.05$ ).

The potentiometric parameters between the dental implants and the non-removable denture metal (DI-M) in the surveyed primary observation group (33 people) were as follows (Table 1): potential difference was  $37.0 \pm 2.1$  mV ( $p > 0.05$ ); current strength –  $3.4 \pm 0.2$   $\mu$ A ( $p > 0.05$ ); electrical conductivity of the oral fluid –  $2.9 \pm 0.2$   $\mu$ S ( $p > 0.05$ ).

TABLE 1. Potentiometric values of the main observation group patients.

Observation Group		Number of Patients	Potentiometric Values		
			Potential Difference (mV)	Current Strength ( $\mu$ A)	Electrical Conductivity of the Oral Fluid ( $\mu$ S)
Main observation group	Between metallic inclusions (M-M)	33	$38.8 \pm 2.7$ $p > 0.05$	$3.5 \pm 0.3$ $p > 0.05$	$3.0 \pm 0.3$ $p > 0.05$
	Between metallic inclusions and alveolar bone mucosa (M-ABM)	33	$40.6 \pm 3.1$ $P > 0.05$	$3.7 \pm 0.3$ $p > 0.05$	$3.4 \pm 0.3$ $p > 0.05$
	Between dental implants and alveolar bone mucosa (DI-ABM)	33	$37.3 \pm 2.4$ $p > 0.05$	$3.4 \pm 0.2$ $p > 0.05$	$3.1 \pm 0.2$ $p > 0.05$
	Between dental implants and non-removable denture metal (DI-M)	33	$37.0 \pm 2.1$ $p > 0.05$	$3.4 \pm 0.2$ $p > 0.05$	$2.9 \pm 0.2$ $p > 0.05$
Control group (healthy people)		27	$32.6 \pm 2.9$	$2.9 \pm 0.2$	$2.7 \pm 0.2$

$p$  – reliability of differences in comparison with healthy people.

All the potentiometric parameters obtained by us in the primary observation group (with periodontal disease) did not differ significantly from the norm (healthy people) and the control group of patients (without periodontal disease).

On the control orthopantomograms made both in the early and late periods after the dental implantation, in the cases of the main group (with periodontal disease) we observed no bone changes.

### Conclusion

Based on the data obtained, it can be concluded that complex oral hygiene care by production of the Pierre Fabre Oral Care laboratory is the most effective, in comparison with traditional means of hygienic care, in cases with periodontal disease after dental implantation. Using the products of the laboratory Pierre Fabre Oral Care (Eludril, Elugel, Parodium, and Elgidium) it is proved that they have a significant antibacterial, anti-inflammatory, analgesic and antagonistic effect. The use of oral hygiene products by Pierre Fabre Oral Care made it possible to reduce the number of early postoperative inflammatory complications by 3 times and prevent the development of late postimplantation complications.

The Pierre Fabre Oral Care oral hygiene products are recommended for patients after dental implantation to prevent early and late inflammatory complications [29].

### Funding

None.

### Conflict of Interests

None.

### Role of Authors

Oleksandr O. Tymofieiev (concept of the paper, material collection, and editing)

Mariia O. Yarifa (material collection and writing)

### Ethical Approval

Approval was obtained from the Medical Ethics Committee of the Shupyk National Medical Academy of Postgraduate Education, Kyiv, Ukraine.

### Patient Consent

No needed.

### Acknowledgements

None.

### References

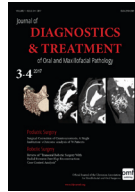1. Tymofieiev OO. Surgical methods of dental implantation [Russian]. 1st ed. Kyiv: Chervona Ruta-Turs; 2007.
2. Kulakov AA. Surgical aspects of rehabilitation of patients with dentition defects in the use of various dental implant systems [Russian]. ScD [dissertation]. Moscow; 1997.
3. Tymofieiev OO, Pavlenko OV. Potentiometric parameters in patients with metallic inclusions in the oral [Russian]. *Modern Dentistry* 2005;2(30):147–9.
4. Tymofieiev OO. Indicators of potentiometry and nonspecific resistance of the organism in patients with metallic inclusions in the oral cavity, fixed on dental implants and teeth [Russian]. *Modern Dentistry* 2005;4(32):133–8.
5. Tymofieiev OO, Pavlenko OV. Metallic inclusions in the oral cavity in orthopedic dentistry [Russian]. *Collection of Scientific Works of Stomatology Institute of NMAPE* 2007;2:70–4.
6. Tymofieiev OO. Needle-electrode for interstitial potentiometric measurements [Russian]. *Modern Dentistry* 2009;4(48):81.
7. Alsaadi G, Quirynen M, Komarek A, van Steenberghe D. Impact of local and systemic factors on the incidence of oral implant failures, up to abutment connection. *J Clin Periodontol* 2007;34:610–7.
8. Mello CC, Lemos CAA, Verri FR, et al. Immediate implant placement into fresh extraction sockets versus delayed implants into healed sockets: A systematic review and meta-analysis. *Int J Oral Maxillofac Surg* 2017;46(9):1162–77.
9. Lemes H, Sartori IA, Cardoso LC, Ponzoni D. Behaviour of the buccal crestal bone levels after immediate placement of implants subjected to immediate loading. *Int J Oral Maxillofac Surg* 2015;44:389–94.
10. Chrcanovic BR, Albrektsson T, Wennerberg A. Periodontally compromised vs. periodontally healthy patients and dental implants: a systematic review and meta-analysis. *J Dent* 2014;42:1509–27.
11. Lindeboom JA, Tjiok Y, Kroon FH. Immediate placement of implants in periapical infected sites: a prospective randomized study in 50 patients. *Oral Surg Oral Med Oral Pathol Oral Radiol Endod* 2006;101:705–10.
12. Agliardi E, Panigatti S, Clerico M, Villa C, Malo P. Immediate rehabilitation of the edentulous jaws with full fixed prostheses supported by four implants: interim results of a single cohort prospective study. *Clin Oral Implants Res* 2010;21:459–65.
13. Grandi T, Guazzi P, Samarani R, Grandi G. Immediate provisionalisation of single postextractive implants versus implants placed in healed sites in the anterior maxilla: 1-year results from a multicentre controlled cohort study. *Eur J Oral Implantol* 2013;6:285–95.
14. Atieh MA, Alsabeeha NH, Duncan WJ, et al. Immediate single implant restorations in mandibular molar extraction sockets: a controlled clinical trial. *Clin Oral Implants Res* 2013;24:484–96.
15. Hammerle CH, Chen ST, Wilson Jr TG. Consensus statements and recommended clinical procedures regarding the placement of implants in extraction sockets. *Int J Oral Maxillofac Implants* 2004;19(Suppl):26–8.
16. Chen ST, Buser D. Esthetic outcomes following immediate and early implant placement in the anterior maxilla—a systematic review. *Int J Oral Maxillofac Implants* 2014;29(Suppl):186–215.

17. Moher D, Liberati A, Tetzlaff J, Altman DG. Preferred reporting items for systematic reviews and meta-analyses: the PRISMA statement. *Int J Surg* **2010**;8:336–41.
18. Goiato MC, dos Santos DM, Santiago Jr JF, Moreno A, Pellizzer EP. Longevity of dental implants in type IV bone: a systematic review. *Int J Oral Maxillofac Surg* **2014**;43:1108–16.
19. Batista VE, Santiago Junior JF, Almeida DA, et al. The effect of offset implant configuration on bone stress distribution: a systematic review. *J Prosthodont* **2015**;24:93–9.
20. Lemos CA, Mello CC, Dos Santos DM, et al. Effects of platelet-rich plasma in association with bone grafts in maxillary sinus augmentation: a systematic review and metaanalysis. *Int J Oral Maxillofac Surg* **2016**;45:517–25.
21. Lemos CA, de Souza Batista VE, Almeida DA, et al. Evaluation of cement-retained versus screw-retained implant-supported restorations for marginal bone loss: A systematic review and meta-analysis. *J Prosthet Dent* **2016**;115:419–27.
22. Lemos CA, Ferro-Alves ML, Okamoto R, et al. Short dental implants versus standard dental implants placed in the posterior jaws: a systematic review and meta-analysis. *J Dent* **2016**;47:8–17.
23. Luongo G, Lenzi C, Raes F, et al. Immediate functional loading of single implants: a 1-year interim report of a 5-year prospective multicentre study. *Eur J Oral Implantol* **2014**; 7:187–99.
24. Oxby G, Oxby F, Oxby J, Saltvik T, Nilsson P. Early Loading of Fluoridated Implants Placed in Fresh Extraction Sockets and Healed Bone: A 3- to 5-year clinical and radiographic follow-up study of 39 consecutive patients. *Clin Implant Dent Relat Res* **2015**;17:898–907.
25. Palattella P, Torsello F, Cordaro L. Two-year prospective clinical comparison of immediate replacement vs: immediate restoration of single tooth in the esthetic zone. *Clin Oral Implants Res* **2008**;19:1148–53.
26. Rieder D, Eggert J, Krafft T, et al. Impact of placement and restoration timing on singleimplant esthetic outcome – a randomized clinical trial. *Clin Oral Implants Res* **2016**;27:e80–86.
27. Siciliano VI, Salvi GE, Matarasso S, et al. Soft tissues healing at immediate transmucosal implants placed into molar extraction sites with buccal selfcontained dehiscences: A 12-month controlled clinical trial. *Clin Oral Implants Res* **2009**;20:482–8.
28. Siebers D, Gehrke P, Schliephake H. Delayed function of dental implants: a 1- to 7-year follow-up study of 222 implants. *Int J Oral Maxillofac Implants* **2010**;25:1195–202.
29. Tymofieiev OO, Ushko NO, Tymofieiev OO, Yarifa MO, Fesenko IeI. Prevention of inflammatory complications upon surgeries in maxillofacial region. *J Diagn Treat Oral Maxillofac Pathol* **2017**;1:105–12.

Tymofieiev OO, Yarifa MO.  
 Prospects of dental implants placement in cases of periodontal disease.  
*J Diagn Treat Oral Maxillofac Pathol* **2017**;1:183–195.  
<http://dx.doi.org/10.23999/j.dtomp.2017.3-4.12>



# Review of events

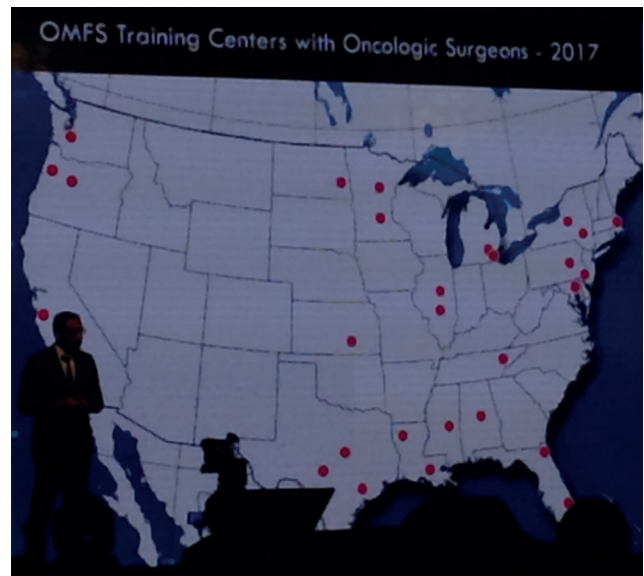
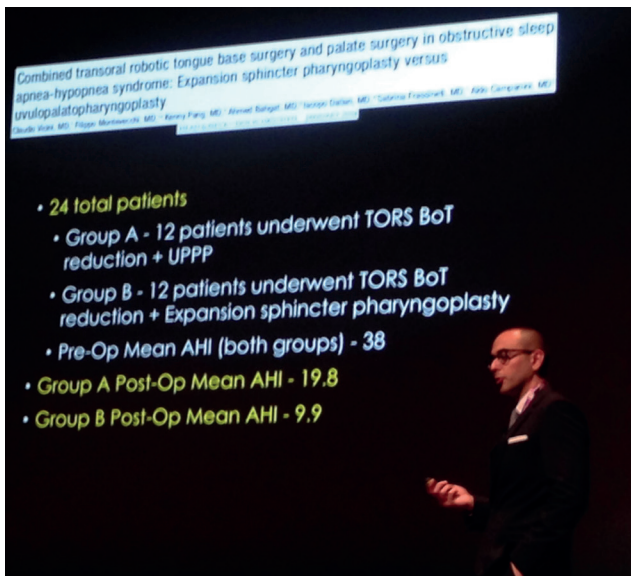


“The only real luxury is the luxury of human communication”  
Antoine de Saint-Exupery, the writer

## 23rd International Conference on Oral and Maxillofacial Surgery (ICOMS) 2017

The ICOMS this year was held in Hong Kong on March 31 – April 3. Organizers of the Conference (International Association of Oral and Maxillofacial Surgeons and Hong Kong Association of Oral and Maxillofacial Surgeons) do their best connecting professionals from all corners of the world. “Sharing ideas and building bonds” – under that credo the event was held. The topics of the 4 days scientific program consisted of all aspects of maxillofacial and head and neck surgery (Head and Neck Oncology, Cleft and Craniofacial, Trauma and Deformities, TMJ, Pathology, Orthognathic and Aesthetic Surgery, etc.). At first time

the ICOMS participants can meet at one event three publications dedicated to our specialty – *International Journal of Oral and Maxillofacial Surgery* ([www.ijoms.com](http://www.ijoms.com)), *Craniofacial Trauma & Reconstruction* ([www.thieme-connect.com](http://www.thieme-connect.com)), and *Diagnostics and Treatment of Oral and Maxillofacial Pathology* ([www.dtjournal.org](http://www.dtjournal.org)). Special attention of participants was paid to the cutting-edge direction – robotic surgery (Fig 1A) and its advantages. The Presidential lecture of the Conference (Fig 1B) received a long standing ovation symbolizing the endeavoring movement forward of the specialty and surgeons which moves it in the right direction. And with great impatience, the participants are already waiting for the next meeting in Brazil in 2019 ([www.icoms2019.com.br](http://www.icoms2019.com.br)).



**FIGURE 1.** International Conference on Oral and Maxillofacial Surgery ([www.icoms2017.com](http://www.icoms2017.com)), 31 March – 3 April 2017, Hong Kong. Lecture of Salam O. Salman (Assis Prof, USA) *Modern Management of Obstructive Sleep Apnea: Beyond MMA* (A) depicted new aspects of robotic surgery. The Presidential lecture of Rui P. Fernandes (Assoc Prof, USA) *Expansion of Oral and Maxillofacial Surgery: Luxury or Necessity?* (B) showed the visitors how an oral and maxillofacial surgery changed through the past century. (Fig 1 continued on the next page.)



**FIGURE 1. (cont'd).** Common picture (C) after Presidential lecture united the experts from all corners of the globe. *"It was a magnificent, fascinating, glorious, and so much needed event"* – Ariana A. Khadem, Editor – Review of Events.

### 121st American Academy of Otolaryngology Annual Meeting (AAO-HNSF & OTO Expo 2017)

The AAO-HNSF Annual Meeting and OTO Experience had reached its 121<sup>st</sup> anniversary in 2017. The event was held in Chicago, on 10-13 September. The main aim of the event was to maintain the networking between the otolaryngologists and head and neck surgeons. The event was directed at the exchange of clinical and scientific experiences of surgeons from different countries. The event was attended by more than thousand of Academy members, physicians without a membership, allied health professionals, and medical companies that exhibited their production. Among the attendees of the event were a lot of researches in otolaryngology, senior academic professors, department chairs, residents and fellows. There were held special instruction courses, miniseminars, oral presentations regarding the latest scientific findings, Honorary Guest lectures, and scientific poster presentations. The event accumulated more than 400 scientific poster presentations regarding different areas of otolaryngology; the presentations contained case studies, research findings, and new practices and approaches towards different surgical procedures. The AAO-HNSF Annual Meeting and OTO experience is one of the biggest events in the world that is held for the professional communication and exchange between practicing otolaryngologists and head and neck surgeons. It was not only a meeting of the greatest professionals in their field who want to stay up-to-date in their specialty, it was also a meeting of old friends, and a possibility to get to know new fellow colleagues; because as we know – in every professional field the most important key for growth is communication.

### European Association For Osseointegration Annual Meeting 2017 (EAO 2017)

This year the beautiful Spanish city Madrid was hosting a special event for European maxillofacial surgeons: the 26<sup>th</sup> EAO Annual Scientific Meeting and 47 Congreso Annual de SEPES were held on the behalf of the European Association of Osseointegration and la Sociedad Española de Prótesis Estomatológica y Estética. The main distinguishing feature of the event was a joint congress between two associations. It allowed bringing together two communities, and making the professional exchange even more productive. On the 7<sup>th</sup> of October all the members of the meeting were able to attend the EAO-SEPES fifth SEPA European Symposium. The main topic of this congress was predictable: Twenty-five years of Implant Dentistry. What have we learned? The congress was organized on a top level, with world-level maxillofacial surgery speakers. We also saw that the audience was rather active in the discussion of the topics that were highlighted. Another distinguishing detail was the welcoming of Latin America as a guest region. A lot of European clinicians and scientists presented the results of their hard work in the form of oral presentations and posters. This was a truly brilliant experience for all the attendees of the congress: what can be better than the intellectually stimulating company of the best maxillofacial surgeons of Europe paired with the magic atmosphere of the city Madrid? We are looking forward to the next EAO meeting with excitement!

### French Society for Oral and Maxillofacial Surgery 53rd Congress 2017


The 53<sup>rd</sup> French Society Congress for Oral and

Maxillofacial Surgery was held this year in one of the oldest French cities, Marseilles. Marseilles is not a coincidental choice. Across the fact that this city is one of the world's culture capitals, its location is not to be underestimated: it contains 3 of the most beautiful coasts in the world, and is in the top 10 seaside cities of our planet according to the National Geographic. The event had gathered different specialists: oral surgeons, maxillofacial surgeons, and dentists. One of the brightest parts of the event was the "2017 recipes for the young surgeon", and the pre-congress course that focused on face esthetics. This shows how the physician society stays up-to-date in a world where good appearance and symmetry starts to become of a bigger importance for more and more people. However, the congress was also focused on classic topics regarding the biggest areas of concern in maxillofacial pathology: 3D reconstruction, maxillofacial trauma and oncology, TMJ disorders, digital photography, piezosurgery, and of course, implantology. The most interesting aspect for young specialists was the open workshops, where they could train their skills on new surgical techniques and materials. The second day was fully devoted to presentations by the most distinguished European lecturers. The audience of these lectures was approximately 900 people. The day was closed by a Gala dinner in the Eugenie Room on the sea, where all the participants had the possibility to enjoy the beauty of the evening Marseilles. The third day was the French speakers' day. Topics like orthognathic surgery, malformations, trauma, and implantology were discussed.

Surely, poster presentations were not missing at this event. The last day was held in light of esthetics, and the second part of it contained some political activities.

### Plastic Surgery the Meeting, 2017

Plastic Surgery the Meeting, the 86<sup>th</sup> annual conference of the American Society of Plastic Surgeons this year was held in Orlando on October 6-10. This conference is known as the main educational and networking meeting not only for surgeons from the United States, but also for specialists across the world. Among the attendees were residents, researchers and clinicians. All of them had one goal – to expand their knowledge, be up-to-date with the novelties of the plastic surgery industry, and improve the treatment outcomes. The event was held in light of presentation and discussion of the advanced techniques in the branch. The conference was divided into seven main topics: esthetic, breast, craniomaxillofacial, reconstructive surgery, and research technology. There were approximately 3000 participants of the event. This means that the informational exchange was very effective, and it did definitely bring light on some common clinical problems that most physicians face in their daily practice. Extremely interested for participants was a PRSTechTalk at the event (Fig 2). The conference also included workshops and demonstrations. This allows applying these new principles and techniques further in their clinic, and improving the patients' recovery.



**FIGURE 2.** Instagram post of *Plastic and Reconstructive Surgery*® (Impact Factor of the Journal is 3.784): "Amazing #PRSTechTalk at #PST17 on #socialmedia and #plasticsurgery !with @drheatherfurnas, @olivierbranford, @tonyyoumnd and @josefhadeedmd !!!" at October 8, 2017.

Editor – Review of Events  
Ariana A. Khadem, DDS (Kyiv, Ukraine)  
[ariana.khadem@dtjournal.org](mailto:ariana.khadem@dtjournal.org)

# Future Events

for 2018-2020

## 2018

### **Mayo Clinic 11th Annual Multidisciplinary Transoral Surgery for Head and Neck Cancer 2018**

February 12 – 14, 2018  
Scottsdale, Arizona, USA

[www.ce.mayo.edu/otorhinolaryngology/content/11th-annual-multidisciplinary-transoral-surgery-head-and-neck-cancer-2018](http://www.ce.mayo.edu/otorhinolaryngology/content/11th-annual-multidisciplinary-transoral-surgery-head-and-neck-cancer-2018)

### **London FACT Interactive Lectures and Cadaveric Dissection Course**

March 5 – 6, 2018  
Manchester, UK

[www.londonfact.co.uk/product/interactive-lectures-cadaveric-dissection/](http://www.londonfact.co.uk/product/interactive-lectures-cadaveric-dissection/)

### **American Cleft Palate-Craniofacial Association 75th Annual Meeting**

April 10 – 14, 2018  
Pittsburgh, Pennsylvania, USA

[www.meeting.acpa-cpf.org](http://www.meeting.acpa-cpf.org)

### **24 Congress of the European Association for Cranio-Maxillo-Facial Surgery**

September 18 – 21, 2018  
Munich, Germany

[www.2018.eacmfcongress.org](http://www.2018.eacmfcongress.org)

### **Plastic Surgery The Meeting**

September 28 – October 2, 2018  
Chicago, Illinois, USA

[www.plasticsurgery.org](http://www.plasticsurgery.org)

### **122 American Academy of Otolaryngology Annual Meeting (AAO-HNSF & OTO Expo 2017)**

October 7 – 10, 2018  
Atlanta, Georgia, USA

[www.entannualmeeting.org](http://www.entannualmeeting.org)

### **100th Annual Meeting of American Association of Oral and Maxillofacial Surgeons**

#### **Scientific Sessions & Exhibition**

October 8 – 13, 2018  
Chicago, Illinois, USA

[www.aaoms.org](http://www.aaoms.org)

### **Association of Oral & Maxillofacial Surgeons of India 43rd Annual Conference 2018 (AOMSI 2018)**

October 11 – 13, 2018  
Chennai, India

[www.43chennai.aomsi.com](http://www.43chennai.aomsi.com)

### **13th Asian Congress on Oral and Maxillofacial Surgery**

November 8 – 11, 2018  
Taipei, Taiwan

[www.2018acom.com](http://www.2018acom.com)

## 2019

### **24rd International Conference on Oral and Maxillofacial Surgery**

May 21 – 24, 2019  
Rio de Janeiro, Brazil

[www.icoms2019.com.br](http://www.icoms2019.com.br)

### **18th Meeting of the International Society of Craniofacial Surgery**

September 16 – 19, 2019  
Paris, France

[www.iscfs.org](http://www.iscfs.org)

## 2020

### **14th International Facial Nerve Symposium**

2020  
South Korea

[www.internationalfacialnerve.org](http://www.internationalfacialnerve.org)

# Submission of Articles

## Papers for the Publication

- original papers
- clinical cases (case reports)
- surgical notes
- radiological notes
- reports of new equipment, instruments or technical innovations
- journal or book reviews
- reviews of other journals articles
- letters to the Editor

## Article and Abstracts

Article must be written in English.

The authors from the Russian-speaking countries must send an abstract of the article in Russian. The authors from Ukraine must send an abstract of the article in Ukrainian and Russian.

One co-author is denominated as the corresponding author with all contact details:

- Postal address (ZIP code of a country, City, Street, phone and fax number)
- E-mail address

The abstract should include full title of the article, full names and surnames of the co-authors, affiliation, scientific degree, specialty. Also the abstract should include short information about article content: purpose, material and methods, results, conclusions. Example how the Abstract should be looked like the authors can get from the published articles in current issue.

## Figures and Tables

Photographs, CT and MRI images, sonograms should be submitted in original with resolution of at least 300 dpi and saved in JPEG or TIFF file format.

## Fundings

The authors should indicate the sources of funding that were allocated for the preparation of the article, if such were the case.

## Conflicts of Interest

At the end of the article the authors should specify about conflicts of interest (e.g., no conflict of interest).

## Role of Co-authors in Writing

After specifying conflicts of interest the role of co-authors in writing of the article (concept and design of the study; material collection, material processing, statistical data processing, writing text, editing, etc.) should be designated.

## Patient Consent

Written patient consent should be obtained to publish the clinical images of the patients.

## Acknowledgments

The authors can acknowledge the persons or institutions which they helped or useful in writing an article.

The Journal is recommended to use that internet source for the articles preparing according to *Vancouver References Style*: <http://libguides.murdoch.edu.au/Vancouver/journal>

## Examples How to Form a Reference List

List all references in numerical order in the text.

Making a list of references from articles, books, internet links, etc.:

*Example for the articles:*

Fernandes RP, Quimby A, Salman S. Comprehensive reconstruction of mandibular defects with free fibula flaps and endosseous implants. *J Diagn Treat Oral Maxillofac Pathol* **2017**;1(1):6–10.

*Example for the articles with more than three authors:*

Neto AMR, Monteiro JL, Borba PM, et al. TMJ's posterolateral dislocation with tympanic plate fracture – case report. *J Diagn Treat Oral Maxillofac Pathol* **2017**;1:59–64.

*Example for the articles from the Journal Supplement:*

Hammerle CH, Chen ST, Wilson Jr TG. Consensus statements and recommended clinical procedures regarding the placement of implants in extraction sockets. *Int J Oral Maxillofac Implants* **2004**;19(Suppl):26–8.

or

Hammerle CH, Chen ST, Wilson Jr TG. Consensus statements and recommended clinical procedures regarding the placement of implants in extraction sockets. *Int J Oral Maxillofac Implants* **2004**;19:S26–8.

*Examples for the book chapters:*

Yuen HY, Ahuja AT. Benign clinical conditions in the adjacent neck. In: Sofferman RA, Ahuja AT, editors. *Ultrasound of the thyroid and parathyroid glands*. Springer, **2012**:229–33.

*Example for the books:*

Baskin J, Duick D, Levine R. *Thyroid ultrasound and ultrasound guided FNA*. 2nd ed. New York: Springer; 2008.

*Example for the PhD/ScD work (dissertation for candidate/doctor of science):*

Borkowski MM. *Infant sleep and feeding: a telephone survey of Hispanic Americans*. PhD [dissertation]. Mount Pleasant (MI): Central Michigan University; 2002.

Kopchak AV. *Clinico-biological and biomechanical study of methods for surgical treatment of mandibular fractures*. ScD [dissertation]. Kyiv: Bogomolets National Medical University; 2014.

*Example for references in Cyrillic:*

Please indicate the language of writing in square brackets [Ukrainian] or [Russian].

Tymofieiev OO. *Manual of maxillofacial and oral surgery* [Russian]. 5th ed. Kyiv: Chervona Ruta-Turs; **2012**.

Tymofieiev OO. *Diseases of the salivary glands* [Ukrainian]. 1st ed. Lviv: VNLT-Klasyka; **2007**.

*Examples for the internet links:*

Seave A. Elsevier CEO using unique data sets and analytic processes to maintain competitive edge. *The Forbes*. February 25, 2016. Available at: <https://www.forbes.com/sites/avaseave/2016/02/25/elsevier-ceo-using-unique-data-sets-and-analytic-processes-to-maintain-competitive-edge/#1d9e4b3979c2/>. Accessed February 25, 2016.

Adult improving access to psychological therapies programme. NHS England. Available from URL: <https://www.england.nhs.uk/mental-health/adults/iapt/> (last accessed 3 March **2017**).

McManus S, Meltzer H, Brugha T, et al., editors. *Adult psychiatric morbidity in England, 2007: results of a household survey*. The NHS Information Centre for health and social care; 2017. Available from URL: <http://www.hscic.gov.uk/catalogue/PUB02931/adul-psyc-morb-reshou-sur-eng-2007-rep.pdf> (last accessed 3 March **2017**).

*Example for conference paper in print proceedings:*

Christensen S, Oppacher F. An analysis of Koza's computational effort statistic for genetic programming. In: Foster JA, Lutton E, Miller J, Ryan C, Tettamanzi AG, editors. *Genetic programming: EuroGP 2002: Proceedings of the 5th European Conference on Genetic Programming; 2002 Apr 3-5; Kinsdale, Ireland*. Berlin: Springer; **2002**. p. 182-91.

*Example for conference paper from the internet:*

Cloherly SL, Dokos S, Lovell NH. Qualitative support for the gradient model of cardiac pacemaker heterogeneity. In: Proceedings of the 2005 IEEE Engineering in Medicine and Biology 27 Annual Conference; 2005 Sep 1-4; Shanghai, China. New York: IEEE; **2005** [cited 2010 Sep 2]. p. 133-6. Available from: IEEE Xplore.

*Example for A-V materials (DVD):*

Acland RD, presenter. Acland's DVD atlas of human anatomy [DVD]. Baltimore (MD): Lippincott Williams & Wilkins; **2004**.

*Example for A-V materials (YouTube/Vimeo video):*

NRK. Medieval helpdesk with English subtitles [video file]. **2007** Feb 26 [cited 2014 Jan 28]. Available from: <http://www.youtube.com/watch?v=pQHx-SjgQvQ>

*Example for A-V materials (Video recording):*

Hillel J, writer. Out of sight out of mind: indigenous people's health in Australia [videorecording]. Bendigo: Video Education Australasia; **2003**.

*Example for Readers/Study Guides:*

Lynch M. God's signature: DNA profiling, the new gold standard in forensic science. Endeavour. 2003;27(2):93-7. Reprinted In: Forensic Investigation (BIO373) unit reader for forensic DNA component. Murdoch (WA): Murdoch University; **2005**.

*Example for newspaper articles in print:*

Hatch, B. Smoke lingers for those who keep hospitality flowing. Australian Financial Review. **2006** Jul 13: 14.

*Example for newspaper article from the internet:*

Devlin, H. Neuron breakthrough offers hope on Alzheimer's and Parkinson's. The Times [newspaper on the Internet]. **2010** Jan 28 [cited 2010 Jan 31]. Available from: <http://www.timesonline.co.uk/tol/news/science/medicine/article7005401.ece>.

*Example for conversation citation:*

In a conversation with a colleague from the School of Population Health (Jameson LI **2002**, oral communication, 7th August)...

*Example for e-mail citation:*

Smith P. New research projects in gastroenterology [online]. E-mail to Matthew Hart (mh@hospital.wa.gov.au) **2000** Feb 5 [cited 2000 Mar 17].

## **Spelling and Grammar Check**

The article should be 'spell checked' and 'grammar checked'. You can use American or British usage, but do not use mixture of them. Authors for whom English is not their native language should add an editing certificate (the international company that can provide editing is: [www.enago.com](http://www.enago.com)).

## **Free Access for All Articles**

The journal offers the free access to all articles guiding by the main principle of the journal policy, to give a possibility to colleagues from all countries (even from low-income) to use data for the development of specialties related with Oral and Maxillofacial Area.

Editorial of the Journal independently assigns for the articles Index of the Universal Decimal Classification (UDC) according to the requirements of Higher Attestation Commission of Ukraine and Digital Object Identifier (DOI) according to the international standards.

## **Questions?**

[i.i.fesenko@dtjournal.org](mailto:i.i.fesenko@dtjournal.org)