

# DT Journal

6<sup>2023</sup>

**Journal of Diagnostics and  
Treatment of Oral and  
Maxillofacial Pathology**



Editors  
Oleksii Tymofieiev • Rui Fernandes  
(Kyiv, Ukraine • Jacksonville, FL, USA)



Official Journal of the  
Ukrainian Association for  
Maxillofacial and Oral Surgeons

[DTJournal.org](http://DTJournal.org)

# TANTUM VERDE®

QUICK RELIEF FROM PAIN  
AND INFLAMMATION IN THE  
MOUTH AND THROAT<sup>1</sup>

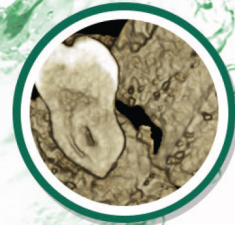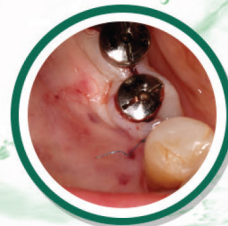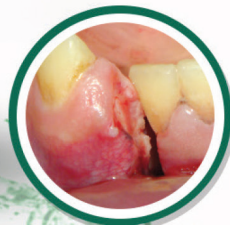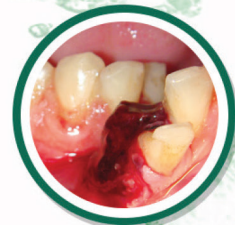**AN INTEGRAL COMPONENT OF THE TREATMENT  
OF PAIN AND INFLAMMATION IN THE ORAL CAVITY  
IN 60 COUNTRIES WORLDWIDE!<sup>2</sup>**



Reg. № UA/3920/01/01

**LOCAL ANESTHETIC  
AND ANTI-INFLAMMATORY  
EFFECT<sup>1</sup>**

- **JAWS  
FRACTURES<sup>3</sup>**
- **IMPLANTS  
PLACEMENT<sup>4</sup>**
- **WOUNDS OF ORAL  
CAVITY<sup>5</sup>**



#### SUMMARY OF PRODUCT CHARACTERISTICS

**NAME OF THE MEDICINAL PRODUCT.** Tantum Verde 0.15% mouthwash. **QUALITATIVE AND QUANTITATIVE COMPOSITION.** Each 100 ml contains: active ingredient: benzydamine hydrochloride 0.15 g (equivalent to 0.134 g of benzydamine). **Therapeutic indications.** Treatment of symptoms such as irritation/inflammation including those associated with pain in the oropharyngeal cavity (e.g. gingivitis, stomatitis and pharyngitis), including those resulting from conservative or extractive dental therapy. **Posology and method of administration.** Pour 15 ml of Tantum Verde mouthwash into the measuring cup, 2-3 times per day, using it either at full concentration or diluted. If diluted, add 15 ml of water to the graduated cup. Do not exceed the recommended dosage. **Contraindications.** Hypersensitivity to benzydamine or to any of the excipient. **PHARMACOLOGICAL PROPERTIES. Pharmacodynamic properties.** Pharmacotherapeutic group: Stomatologic drugs: other agents for local oral treatment, ATC code: A01AD02. Clinical studies demonstrate that benzydamine is effective in relieving suffering from localised irritation of the mouth and pharynx. In addition, benzydamine possesses a moderate local anaesthetic effect. **Pharmacokinetic properties. Absorption.** Absorption through the oropharyngeal mucosa is demonstrated by the presence of measurable quantities of benzydamine in human plasma. These levels are insufficient to produce systemic effects. **Distribution.** When applied locally, benzydamine has been shown to accumulate in inflamed tissues where it reaches effective concentrations because of its capacity to penetrate the epithelial lining.

**Information about medicines. Information for health care professionals for use in professional activities.**

1. Інструкція для медичного застосування лікарського засобу Тантум Верде®, розчин для ротової порожнини, РПН № UA/3920/01/01, затверджено Наказом Міністерства охорони здоров'я України № 636 від 01.10.2015.

2. <http://www.angelini-pharma.com/wps/wcm/connect/com/home/Angelini+Pharma+in+the+world/>

3. Тимофеев А.А. и др. "Особенности гигиены полости рта для профилактики воспалительных осложнений при переломах нижней челюсти". Современная стоматология 2015;1(75):52-8.

4, 4.5. Tymofiejew O.O. et al "Prevention of inflammatory complications upon surgeries in maxillofacial region". J Diagn Treat Oral Maxillofac Pathol. 2017;1:105-12.

Clinical and CT images are courtesy of: Ievgen Fesenko (Department of Oral & Maxillofacial Surgery, PHEI "Kyiv Medical University", Kyiv, Ukraine), Oleg Mastakov ("SCIEDECE—Scientific Center of Dentistry & Ultrasound Surgery" Kyiv, Ukraine)



04119, Kiev, Melnikova str. 83D, of. 404.

Tel.: (044) 538-01-26

Fax: (044) 538-01-27



# About the Journal: Aims and Scope

JUNE 2023 • VOLUME 7 • ISSUE 6  
www.djournal.org

## Official Title

*Journal of Diagnostics and Treatment of Oral and Maxillofacial Pathology*

## Standard Abbreviation: ISO 4

*J. Diagn. Treat. Oral Maxillofac. Pathol.*

## Acronym

JDTOMP

## International Standard Serial Number (ISSN)

Electronic ISSN 2522-1965

## Aims & Scope

This is a monthly peer-reviewed oral and maxillofacial surgery journal focused on: microvascular and jaw reconstructive surgery, dental implants, salivary gland tumors/diseases, TMJ lesions, virtual surgical planning, implementation of ultrasonography into the practice of oral and maxillofacial surgeons.

## Editorial Board (EB) Composition

- EB shows significant geographic diversity representing 30 opinion leaders from 13 countries: Brazil, Canada, Colombia, Greece, Hong Kong (SAR, China), India, Israel, Italy, Slovak Republic, Spain, Ukraine, United Arab Emirates, and United States.
- The majority of the EB Members have a discernible publication history in Scopus, Web of Science, and journals with a high impact factor.
- The publication records of all EB members are consistent with the stated scope and published content of the journal.
- The journal has a several full-time professional editors.
- Gender distribution of the editors: 10% women, 90% men, 0% non-binary/other, and 0% prefer not to disclose.

## Frequency

12 issues a year (from January 2020)

## Publication History

2017: 4 issues a year

2018: 4 issues a year

2019: 10 issues a year

From 2020: 12 issues a year

## Publishing Model

*Journal of Diagnostics and Treatment of Oral and Maxillofacial Pathology* is a fully online-only open access and peer-reviewed publication.

## Type of Peer Review

The journal employs “double blind” reviewing.

## Article Publishing Charge (APC)

The APC in this journal is US \$500 and US \$250 (excluding taxes) depending on the article’s type. Details at website: [dtjournal.org](http://dtjournal.org).

## 13 Types of Articles Currently Published by the Journal

Editorials/Guest Editorials/Post Scriptum Editorials, Images, Case Reports/Case Series, Original Articles, Review Articles, Discussions, Paper Scans (*synonyms*: Review of Articles, Literature Scan), Book Scans (*synonym*: Book Reviews), Letters to the Editor (*synonym*: Letters), and Viewpoints.

## State Registration: Ministry of Justice of Ukraine

Registration: Jul 28, 2016 (Certificate: KB № 22251-12151 P)

Re-registration: May 21, 2019 (Certificate: KB № 23999-13839 IIP)

Re-registration: Aug 10, 2021 (Certificate: KB № 24951-14891 IIP)

## Co-Founders

1. Shupyk National Healthcare University of Ukraine (formerly known as Shupyk National Medical Academy of Postgraduate Education).
2. Private Higher Educational Establishment “Kyiv Medical University.”
3. OMF Publishing, Limited Liability Company.

## Publisher

OMF Publishing, LLC is an academic publisher focused on medical and linguistic sciences.

Address: 13-A Simferopolska Street, office 121, Kyiv 02096, Ukraine.

## Crossref Membership

OMF Publishing, LLC is a member of Publishers International Linking Association, Inc. which doing business as a Crossref. OMF Publishing’s active membership: From February 2017 to present.

## Official Journal of the Association

Ukrainian Association for Maxillofacial and Oral Surgeons

## Ukrainian Association for Maxillofacial and Oral Surgeons (UAMOS)

Address: 4-A Profesora Pidvysotskoho Street, Kyiv 01103, Ukraine. Tel., fax: +38 044 528 35 17.

Website: [uamos.org](http://uamos.org).

© 2023 OMF PUBLISHING, LLC



# Editorial Board

JUNE 2023 • VOLUME 7 • ISSUE 6  
www.djournal.org

## Editor in Chief

**Oleksii O. Tymofiev, ScD**  
Kyiv, Ukraine

## Deputy Editor in Chief

**Rui P. Fernandes, MD, DMD, FACS, FRCS(Ed)**  
Jacksonville, Florida, United States

## Section Editors

### Bone Augmentation Techniques

**Nardy Casap, MD, DMD**  
Jerusalem, Israel

### Business

**Ivan V. Nagorniak, MSc, PhD**  
Kyiv, Ukraine

### Craniofacial Deformities

**Sunil Richardson, MDS**  
Nagercoil, Tamil Nadu, India

### Facial Feminization Surgery

**Kyle Keojampa, MD, FACS**  
Los Angeles, California, United States

### Facial Plastic Surgery

**Tirbod Fattahi, MD, DDS, FACS**  
Jacksonville, Florida, United States

### Head & Neck Oncologic Surgery

**Todd C. Hanna, MD, DDS, FACS**  
New York, New York, United States

### Head & Neck Radiology

**Anil T. Ahuja, MBBS, MD, FRCR, FHKCR, FHKAM**  
Hong Kong, SAR, China

### Images

**Camilo Mosquera, DDS**  
Bogotá, D.C., Colombia

### Orthognathic Surgery

**Mario Brinhole**  
São Paulo, São Paulo, Brazil

### Robotic Surgery

**Salam O. Salman, MD, DDS, FACS**  
Jacksonville, Florida, United States

### TMJ Lesions/Disorders

**Belmiro C. Vasconcelos, DDS, PhD**  
Recife, Pernambuco, Brazil

## Editorial Board Members

**Oleh M. Antonyshyn, MD, FRCS(C)**  
Toronto, Ontario, Canada

**Anthony M. Bunnell, MD, DMD, FACS**  
Jacksonville, Florida, United States

**Nur A. Hatab, DMD, PhD**  
Ras Al Khaimah, United Arab Emirates

**Michael T. Kase, DMD**  
Birmingham, Alabama, United States

**Andrey V. Kopchak, ScD**  
Kyiv, Ukraine

**Olindo Massarelli, MD, PhD, FEBOMFS**  
Sassari, Italy

**Anastasiya Quimby, DDS, MD**  
Fort Lauderdale, Florida, United States

**Daniel Robles Cantero, DDS, MSc**  
Madrid, Spain

**Peter Stanko, MD, PhD**  
Bratislava, Slovak Republic

**Rostyslav M. Stupnytskyi, ScD**  
Kyiv, Ukraine

**Olexander O. Tymofiev, ScD**  
Kyiv, Ukraine

**Natalia O. Ushko, ScD**  
Kyiv, Ukraine

**Andrew Yampolsky, DDS, MD**  
Philadelphia, Pennsylvania, United States

## Web & Social Media Editor

**João L. Monteiro, DDS**  
Boston, Massachusetts, United States

## Director, Journal Development Department

**Evangelos G. Kilipiris, DMD**  
Thessaloniki, Greece | Bratislava, Slovak Republic

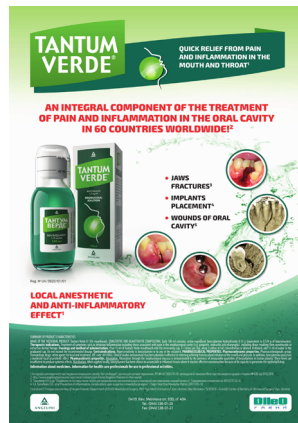## Managing Editor

**Ievgen I. Fesenko, PhD**  
Kyiv, Ukraine

## Resident Ambassador

**John M. Le, DDS, MD**  
Birmingham, Alabama, United States





# TANTUM VERDE®

INFORMATION LEAFLET  
for the medicinal product

## **Composition:**

*active substance:* **benzydamine hydrochloride;**

100 mL of solution contain benzydamine hydrochloride 0.15 g;

*excipients:* ethanol 96%, glycerol, methyl parahydroxybenzoate (E 218), flavor (menthol), saccharin, sodium hydrocarbonate, Polysorbate 20, Quinoline Yellow (E 104), Patent Blue V (E 131), purified water.

**Dosage form.** Oromucosal solution.

*Basic physical and chemical properties:* a clear green liquid with a typical mint flavor.

**Pharmacotherapeutic group.** Dental preparations. Other agents for local oral treatment.

ATC code: A01A D02.

## **Pharmacological properties.**

### *Pharmacodynamics.*

Benzydamine is a non-steroidal anti-inflammatory drug (NSAID) with analgesic and antiexudative properties.

Clinical studies have shown that benzydamine is effective in the relief of symptoms accompanying localized irritation conditions of the oral cavity and pharynx. Moreover, benzydamine has anti-inflammatory and local analgesic properties, and also exerts a local anesthetic effect on the oral mucosa.

### *Pharmacokinetics.*

Absorption through the oral and pharyngeal mucosa has been proven by the presence of measurable quantities of benzydamine in human plasma. However, they are insufficient to produce any systemic pharmacological effect. The excretion occurs mainly in urine, mostly as inactive metabolites or conjugated compounds.

When applied locally, benzydamine has been shown to cumulate in inflamed tissues in an effective concentration

due to its ability to permeate through the mucous membrane.

## **Clinical particulars.**

### **Indications.**

Symptomatic treatment of oropharyngeal irritation and inflammation; to relieve pain caused by gingivitis, stomatitis, pharyngitis; in dentistry after tooth extraction or as a preventive measure.

### **Contraindications.**

Hypersensitivity to the active substance or to any other ingredients of the product.

### **Interaction with other medicinal products and other types of interaction.**

No drug interaction studies have been performed.

### **Warnings and precautions.**

If sensitivity develops with long-term use, the treatment should be discontinued and a doctor should be consulted to get appropriate treatment.

In some patients, buccal/pharyngeal ulceration may be caused by severe pathological processes. Therefore, the patients, whose symptoms worsen or do not improve within 3 days or who appear feverish or develop other symptoms, should seek advice of a physician or a dentist, as appropriate.

Benzydamine is not recommended for use in patients hypersensitive to acetylsalicylic acid or other non-steroidal anti-inflammatory drugs (NSAIDs).

The product can trigger bronchospasm in patients suffering from or with a history of asthma. Such patients should be warned of this.

For athletes: the use of medicinal products containing ethyl alcohol might result in positive antidoping tests considering the limits established by some sports federations.

#### *Use during pregnancy or breast-feeding*

No adequate data are currently available on the use of benzydamine in pregnant and breastfeeding women. Excretion of the product into breast milk has not been studied. The findings of animal studies are insufficient to make any conclusions about the effects of this product during pregnancy and lactation.

The potential risk for humans is unknown.

TANTUM VERDE should not be used during pregnancy or breast-feeding.

#### *Effects on reaction time when driving or using machines*

When used in recommended doses, the product does not produce any effect on the ability to drive and operate machinery.

#### **Method of administration and doses.**

Pour 15 mL of TANTUM VERDE solution from the bottle into the measuring cup and gargle with undiluted or diluted product (15 mL of the measured solution can be diluted with 15 mL of water). Gargle 2 or 3 times daily. Do not exceed the recommended dose.

#### *Children.*

The product should not be used in children under 12 years due to a possibility of ingestion of the solution when gargling.

#### **Overdosage.**

No overdose has been reported with benzydamine when used locally. However, it is known that benzydamine, when ingested in high doses (hundreds times higher than those possible with this dosage form), especially in children, can cause agitation, convulsions, tremor, nausea, increased sweating, ataxia, and vomiting. Such acute overdose requires immediate gastric lavage, treatment of fluid/salt imbalance, symptomatic treatment, and adequate hydration.

#### **Adverse reactions.**

Within each frequency group, the undesirable effects are presented in order of their decreasing seriousness.

Adverse reactions are classified according to their frequency: very common ( $\geq 1/10$ ); common ( $\geq 1/100$  to  $<1/10$ ); uncommon ( $\geq 1/1,000$  to  $<1/100$ ); rare ( $\geq 1/10,000$  to  $<1/1,000$ ); very rare ( $<1/10,000$ ); frequency unknown (cannot be estimated from the available data).

*Gastrointestinal disorders:* rare – burning mouth, dry mouth; *unknown* – oral hypesthesia, nausea, vomiting, tongue edema and discoloration, dysgeusia.

*Immune system disorders:* rare – hypersensitivity reaction, *unknown* – anaphylactic reaction.

*Respiratory, thoracic and mediastinal disorders:* very rare – laryngospasm; *unknown* – bronchospasm.

*Skin and subcutaneous tissue disorders:* uncommon – photosensitivity; very rare – angioedema; *unknown* – rash, pruritus, urticaria.

*Nervous system disorders:* *unknown* – dizziness, headache.

TANTUM VERDE contains methyl parahydroxybenzoate, which can cause allergic reactions (including delayed-type reactions).

**Shelf life.** 4 years.

#### **Storage conditions.**

Do not store above 25°C. Keep out of reach of children.

#### **Packaging.**

120 mL of solution in a bottle with a measuring cup; 1 bottle per cardboard box.

#### **Dispensing category.**

Over-the-counter medicinal product.

#### **Manufacturer.**

Aziende Chimiche Riunite Angelini Francesco A.C.R.A.F. S.p.A., Italy.

Location of the manufacturer and its business address. Via Vecchia del Pinocchio, 22 – 60100 Ancona (AN), Italy.

#### **Date of the last revision of the text.**

September 26, 2018.

Information leaflet is

**APPROVED** by

Order of the

**Ministry of Health of Ukraine**

No. 636 dated 01.10.2015

**Registration Certificate**

No. UA/3920/01/01

# Our Supporters

JUNE 2023 • VOLUME 7 • ISSUE 6  
www.dtjournal.org



**FIGURE.** Evangelos G. Kilipiris, MD, DMD from the National Institute of Children’s Diseases and Faculty of Medicine at Comenius University, Bratislava, Slovak Republic. A kind support of Dr. Kilipiris during the 5 years at the position of Director, Journal Development Department helped our journal to move forward and to evolve. An honorary plaque was presented to him on behalf of the Chief Editor with words “To a Founding Director, Author of Multiple Articles and Reviews, Great Thanks and Appreciation.” Photo was taken on November 23, 2021.



# Content

of the Volume 7 • Issue 6 • June 2023

A1 **Publisher & Editorial Office Information**


A2 **Editorial Board**

A5 **Our Supporters**

A6 **Content, Courtesy, & Erratum**

CASE

- 51 **Giant Aneurysmal Bone Cyst of the Mandibular Condyle Mimicking Parotid Tumor: A Case Report and 22-Year Follow-Up**  
Ghassan Dhaif, Mohamed Ghassan Dhaif, & Amit Sethi

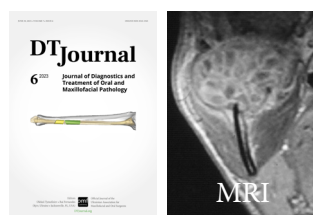


COURTESY

*Journal's* cover image (virtual surgical planning for a segmental mandibular reconstruction with fibula transplant) is courtesy of Rui P. Fernandes, MD, DMD, FACS, FRCS.

Image was taken from the article: Fernandes RP, Quimby A, Salman S. Comprehensive reconstruction of mandibular defects with free fibula flaps and endosseous implants. *J Diagn Treat Oral Maxillofac Pathol* 2017;1(1):6–10.

<https://doi.org/10.23999/j.dtomp.2017.1.1>



## CASE

# Giant Aneurysmal Bone Cyst of the Mandibular Condyle Mimicking Parotid Tumor: A Case Report and 22-Year Follow-Up

Ghassan Dhaif,<sup>a,\*</sup> Mohamed Ghassan Dhaif,<sup>b,\*</sup> & Amit Sethi<sup>c</sup>

## ABSTRACT

**Background:** Aneurysmal bone cyst (ABC) is a rare benign non-odontogenic cyst that occurs most commonly in the posterior mandible. Occurrence in the mandibular condyle is rare. We present a case that was initially misdiagnosed as a parotid gland tumor and later was found to be an ABC.

**Case Presentation:** A 19-year-old man presents with a painless firm swelling on the right preauricular region. Panoramic imaging revealed a radiolucent lesion in the right condyle and ascending ramus of the mandible with complete erosion of the bony surface losing the condyle configuration. The lesion was excised, and the mandible was curetted. A split-thickness left clavicular joint graft was harvested for reconstruction of the right condyle of the mandible. The pathology report confirmed the diagnosis of aneurysmal bone cyst. The patient was followed for 22 years without any evidence of recurrence.

**Conclusions:** Tumors of the jaws and cystic lesions may mimic benign salivary gland pathology. Appropriate clinical and radiographic examination should be utilized to exclude this from the differential diagnosis. Complete surgical excision of the lesion and reconstruction of the condyle may be utilized to provide patients with good results.

**Keywords:** Reconstructive surgical procedures, aneurysmal bone cyst, pseudocyst, benign bone lesions, mandibular condyle.

<sup>a</sup> Dr. Ghassan Dhaif, FFD, RCSI, Consultant Oral & Maxillofacial Surgeon, Ibn Al-Nafees Hospital, Manama, Bahrain.  
ORCID: <https://orcid.org/0009-0002-8638-8474>

<sup>b</sup> Dr. Mohamed Ghassan Dhaif, DMD, MA, Henry M. Goldman School of Dental Medicine, Boston University, Boston, MA, USA.  
ORCID: <https://orcid.org/0000-0002-8438-0797>

<sup>c</sup> Dr. Amit Sethi, DDS, MDS, Clinical Assistant Professor, Department of Oral and Maxillofacial Surgery, Henry M. Goldman School of Dental Medicine, Boston University, Boston, MA, USA.  
ORCID: <https://orcid.org/0000-0003-2813-2016>

\* Corresponding author's address: Dr. Mohamed Ghassan Dhaif, DMD, MA, Henry M. Goldman School of Dental Medicine, Boston University, Boston, MA, USA.  
E-mail: [mdhaif@bu.edu](mailto:mdhaif@bu.edu) (Mohamed Dhaif)

Please cite this article as: Dhaif G, Dhaif M, Sethi A. Giant aneurysmal bone cyst of the mandibular condyle mimicking parotid tumor: a case report and 22-year follow-up. J Diagn Treat Oral Maxillofac Pathol 2023;7(6):51–62.

The 'MRI' abbreviation at the upper right icon means that article contains magnetic resonance imaging (MRI).

Paper received 02 June 2023  
Accepted revised version 11 June 2023  
Available online 16 June 2023

<https://doi.org/10.23999/j.dtmp.2023.6.1>

© 2023 OMF Publishing LLC. This is an open access article under the CC BY license (<https://creativecommons.org/licenses/by-nc/4.0/>).

## BACKGROUND

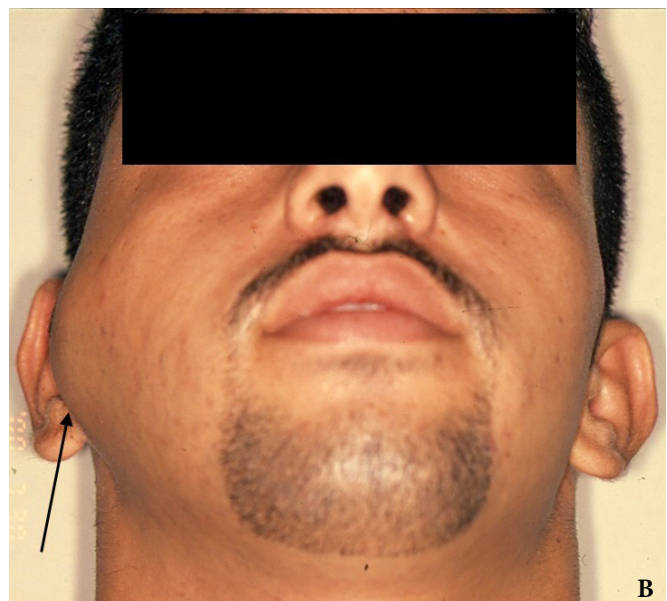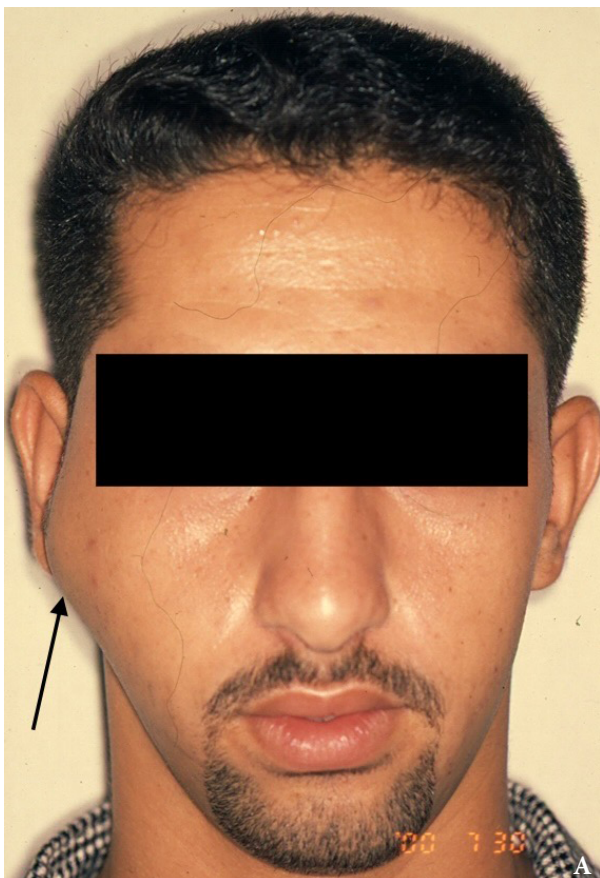**A**neurysmal bone cysts (ABCs) are rare, benign, non-odontogenic cysts, accounting for less than 1% of all non-epithelial cysts in the jaw.<sup>1</sup> These cysts typically affect patients aged 10-30 years, with no discernable sex predilection.<sup>2</sup> They are more commonly found in the posterior mandible than in the maxilla.<sup>3</sup> However, the occurrence of an aneurysmal bone cyst in the mandibular condyle is rare, and the etiology of these cysts remains unknown and enigmatic.<sup>4</sup> Although several theories have been proposed, the precise nature of their pathogenesis is still unclear. Aneurysmal bone cysts exhibit a distinct clinical presentation and are generally asymptomatic. In most instances, the lesion appears as an indolent, painless, radiolucent lesion during routine radiographic assessments or after significant bony expansion has occurred.<sup>5</sup>

In this paper, we present a rare case of an aneurysmal bone cyst in the mandibular condyle, with a 22-year follow-up after surgical intervention

and discuss the management challenges that were encountered during the treatment process.

## CASE REPORT

A 19-year-old male patient was referred to the Department of Oral and Maxillofacial Surgery at the Salmania Medical Complex in Bahrain by an ear, nose, and throat (ENT) surgeon for evaluation of a mass in the right preauricular region. Initially, the patient was referred from a health center to the ENT Department for assessment of a possible benign parotid tumor. The patient's past medical history was non-contributory. Physical examination revealed a painless, firm swelling in the right preauricular region, significantly stretching the skin, and elevating the right earlobe (**Fig 1**). Facial nerve functions were preserved, and no palpable lymph nodes were detected in the face or neck. Maximum mouth opening was within normal limits, but deviation of the mandible to the left side occurred upon opening. There was no clicking or locking of the temporomandibular joint (TMJ).



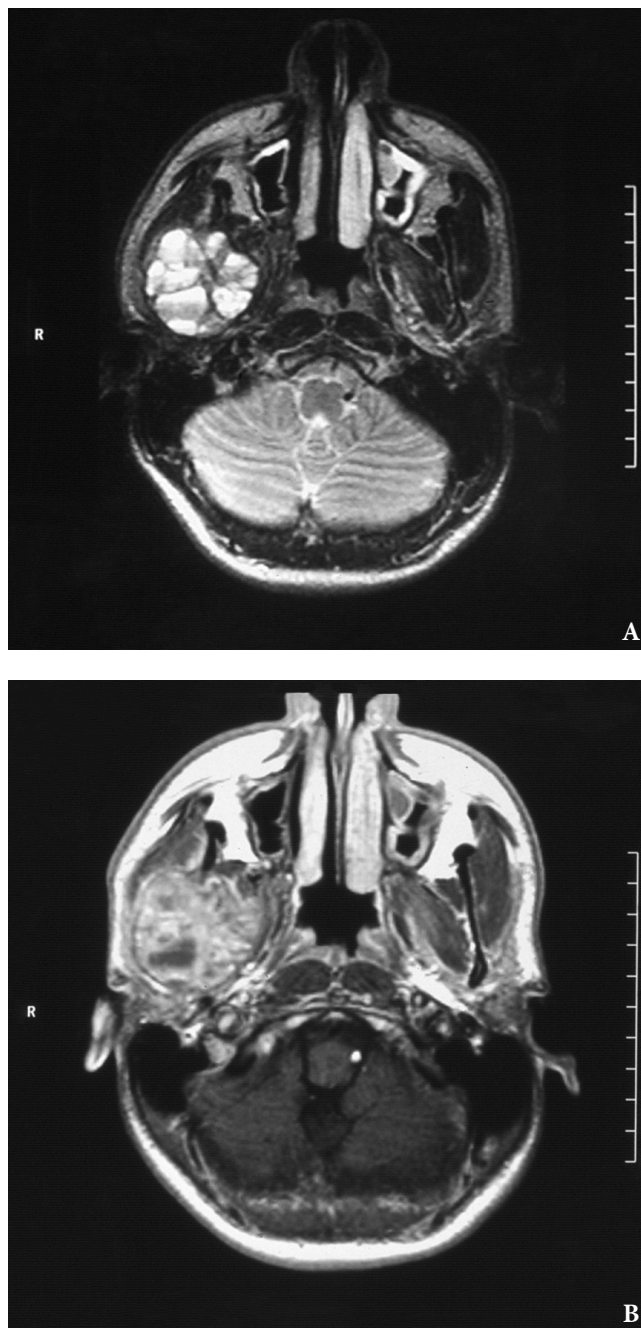
**FIGURE 1.** Patient on presentation (**A, B**) showing diffuse mass (*arrow*) on the right preauricular region.



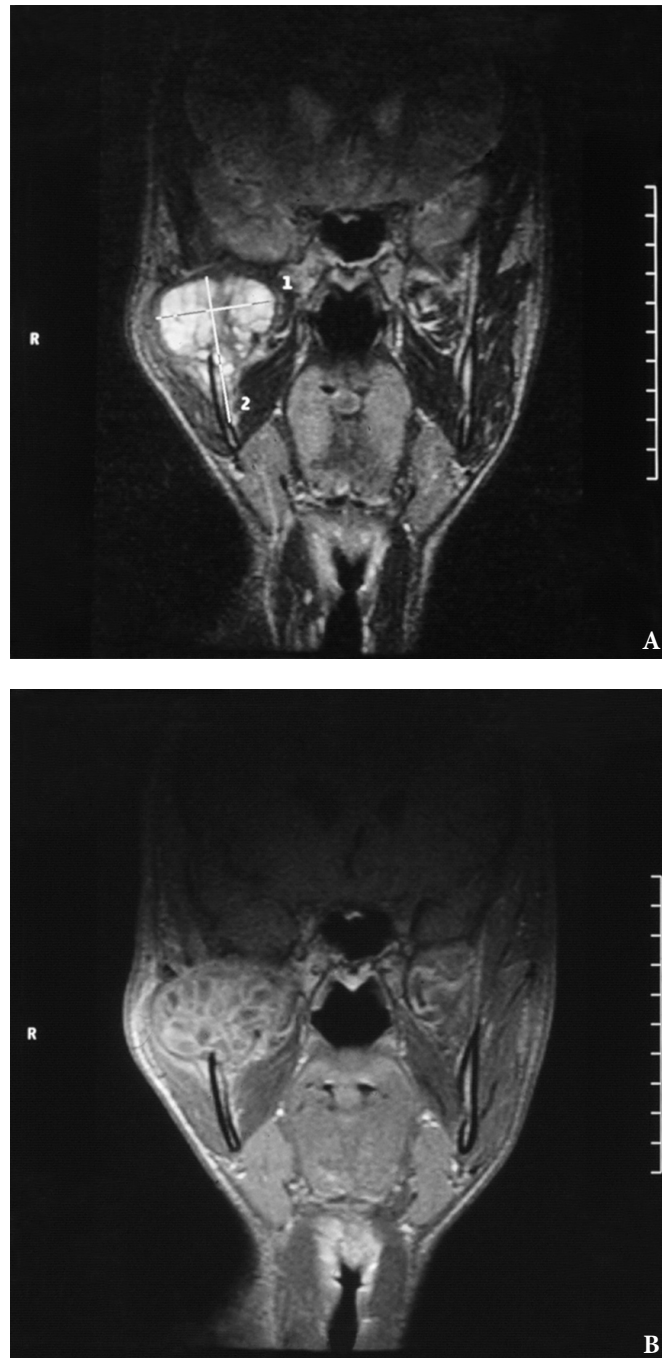
## GIANT PSEUDOCYST

Intraorally, the parotid duct appeared normal in color, with normal salivary flow and no evidence of pus discharge. The patient did not recall any history of trauma to the region or any recent dental procedures. A plain radiograph of the skull showed no evidence of stones or calcifications in the right parotid gland. The magnetic resonance imaging (MRI) of the head and neck region revealed a

normal parotid gland with no evidence of any pathology in the gland or its surrounding tissues. However, there was a large destructive mixed radiopaque/radiolucent on the right mandibular condyle extending superiorly and encroaching on the skull base, and posterosuperiorly invading the infratemporal region (Fig 2). There were multiple calcifications in the lumen of the lesion (Fig 3).



**FIGURE 2.** Axial MRI scans (**A**, pre contrast; **B**, post contrast) showing a mixed lesion in the right condyle of the mandible expanding medially and superiorly. R, right side.



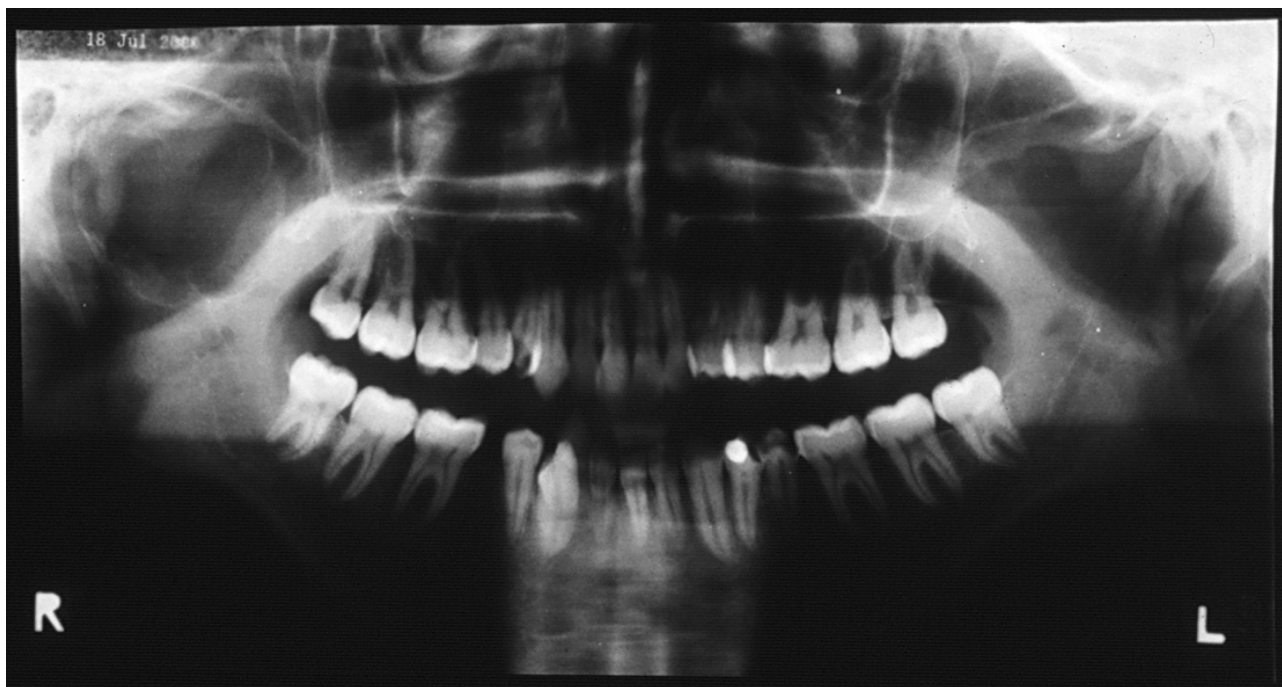**FIGURE 3.** Coronal MRI scans (**A**, pre contrast; **B**, post contrast) showing a destructive lesion on the right mandibular condyle with obvious erosion of the middle cranial fossa. R, right side.

These findings did not suggest parotid gland pathology but rather a tumor or cystic lesion of the jaws. The patient was subsequently referred to our department for further investigation and management. Panoramic radiograph revealed a radiolucent lesion in the right condyle and ascending ramus of the mandible, with complete

erosion of the bony surface, resulting in the loss of condylar configuration (Fig 4). The lesion displayed a poorly defined scalloped border and extended inferiorly to the inferior dental foramen. The coronoid process could not be visualized from this view, giving the illusion of erosion by the lesion. However, no paresthesia was noted along

the distribution of the inferior alveolar nerve or its terminal branch. Aspiration yielded dark straw-colored fluid mixed with blood. Routine blood investigations, including complete blood count, erythrocyte sedimentation rate, differential white blood count, serum calcium, phosphorus, and

alkaline phosphatase, were all within normal limits. Differential diagnoses for this case included simple bone cyst, traumatic bone cyst, aneurysmal bone cyst, calcifying odontogenic cyst, adenomatoid odontogenic tumor, central giant cell granuloma, or ameloblastoma.



**FIGURE 4.** Preoperative panoramic radiograph showing extensive destruction of the right mandibular condyle by the lytic lesion. R, right side; L, left side.

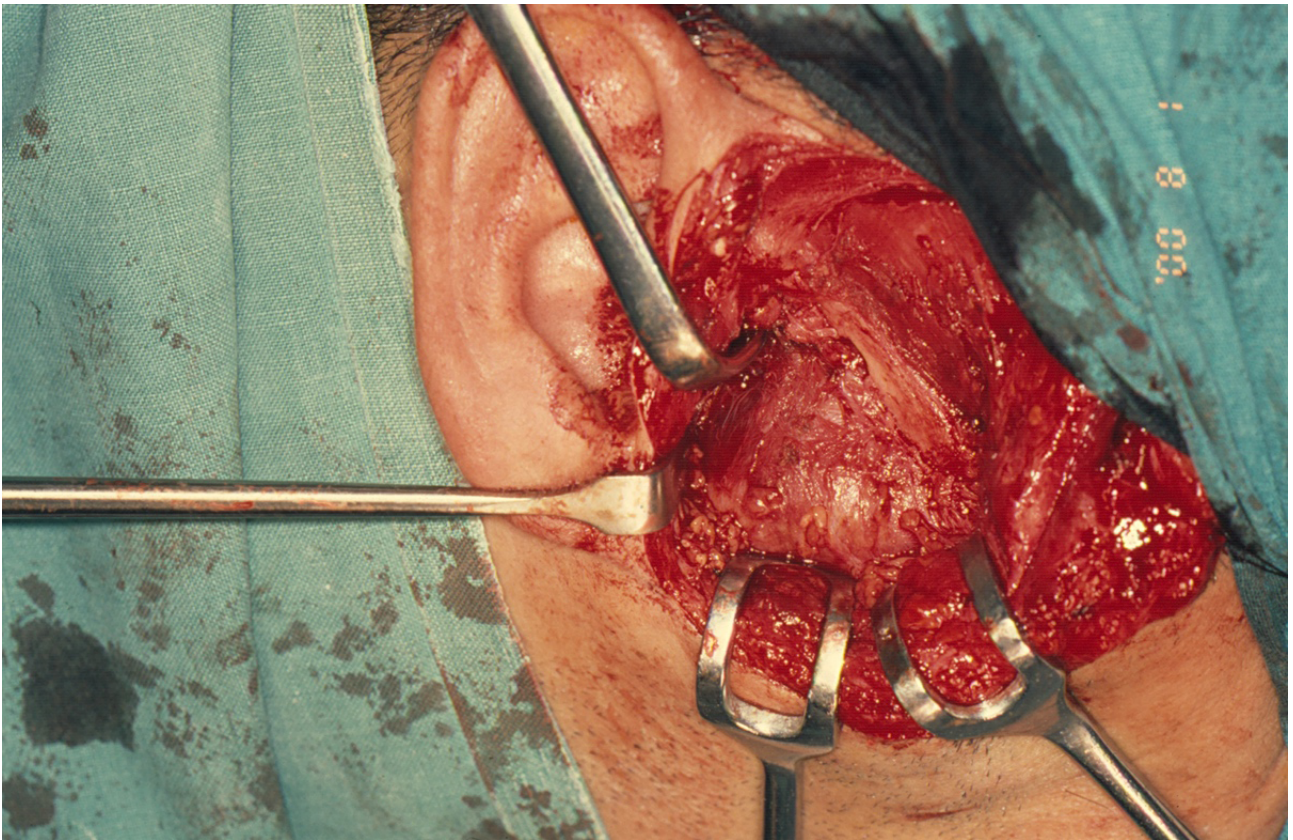
Under general anesthesia, a right preauricular incision with temporal extension was made (Fig 5). The zygomatic arch, condylar fossa, and ascending ramus on the right side were identified. A soft, brown, and vascular mass was observed, stretching the capsule of the right TMJ. The mass measured approximately 10 × 8 × 7 cm. The bone was completely eroded up to the junction between the right angle of the mandible and ascending ramus. Medially, it was difficult to ascertain the exact extent of the mass. The mass was carefully dissected from the surrounding normal tissues. Extensive bleeding from the maxillary artery, encompassed by the mass, was encountered. The artery was identified and ligated. The remaining part of the mandible was curetted to ensure complete excision of the lesion. The articular disc of the right TMJ was absent, and the articular fossa was significantly thinned due to pressure resorption.

A sternoclavicular joint graft closely resembles

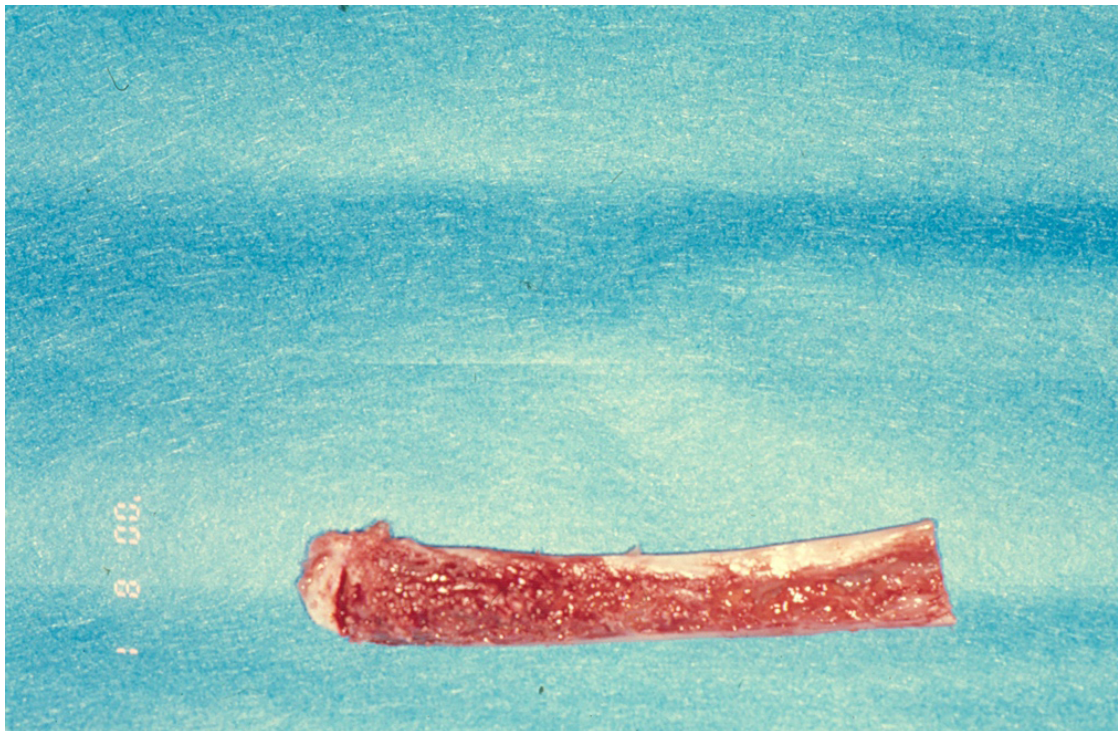
the TMJ both morphologically and histologically, as both joints are covered in fibrocartilage. Although costochondral grafts continue to be used for TMJ reconstruction, they are associated with unpredictable growth, warpage, and potential for fracture.<sup>6</sup> Consequently, a split-thickness left clavicular joint graft was harvested to reconstruct the right mandibular condyle (Fig 6). To ensure vascularization, the graft was perforated and secured using four 20-mm (KLS Martin, Tuttlingen, Germany) bone screws (Fig 7).

Postoperative care for the patient entailed arch bar placement with elastics for six weeks, during which the patient was instructed to maintain a soft diet. At the six-week follow-up, the arch bars were removed, and examination revealed good mouth opening. A routine postoperative panoramic radiograph demonstrated stable fixation of the right clavicular joint (Fig 8). The final pathology report confirmed the diagnosis of an aneurysmal bone cyst (Fig 9).



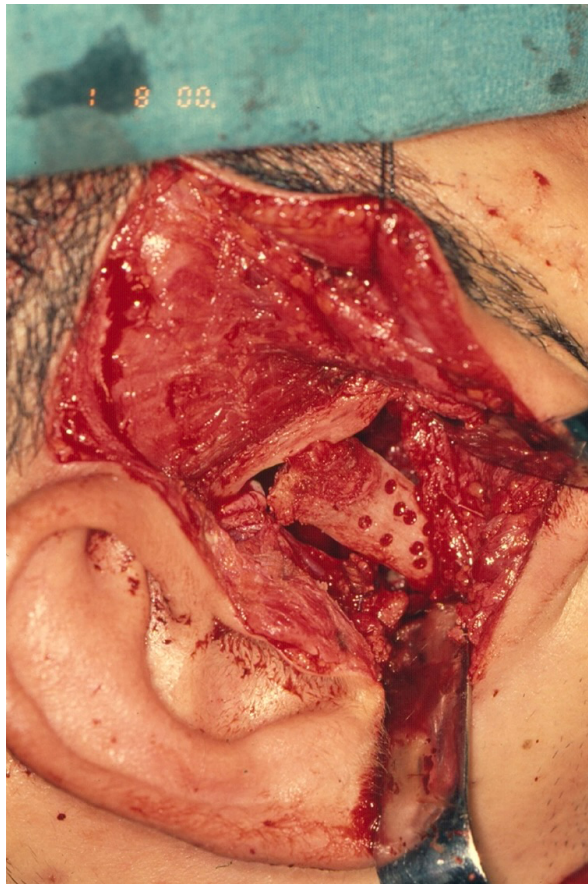


**FIGURE 5.** Preauricular approach for the mass in right condyle of the mandible. Protrusion of the mass from the condylar fossa is noted.

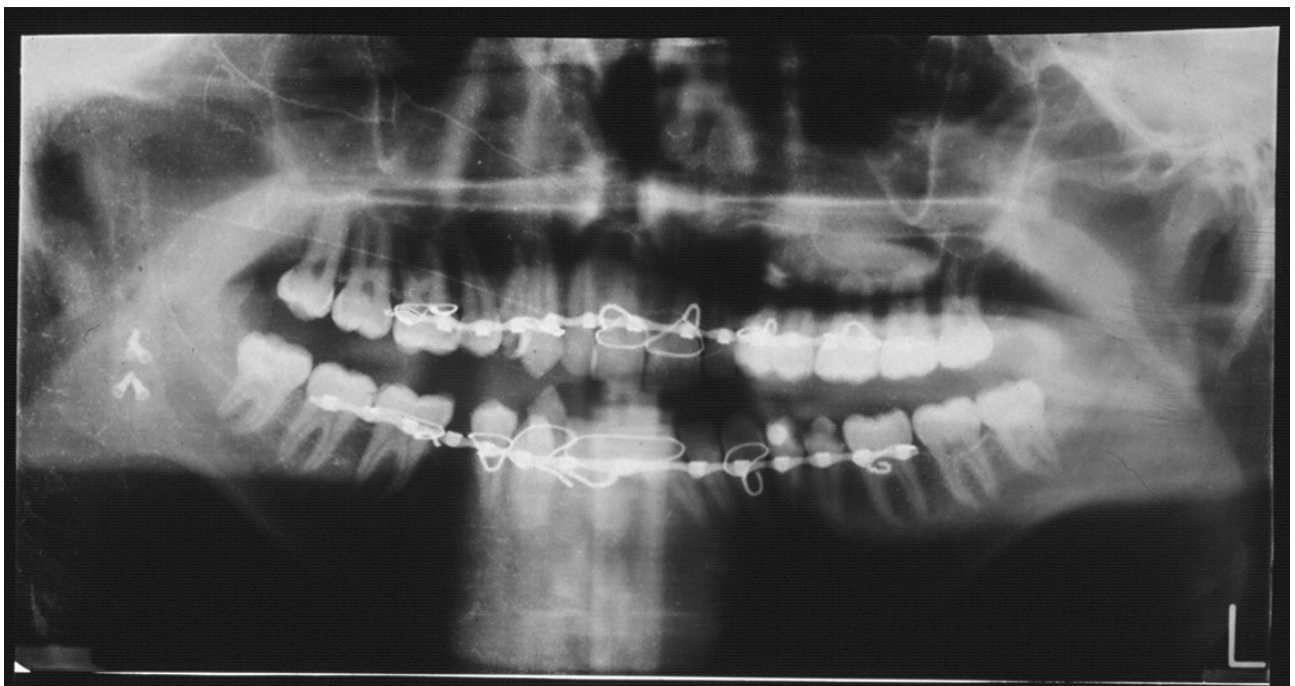


**FIGURE 6.** Harvested left clavicular graft with articular cap.



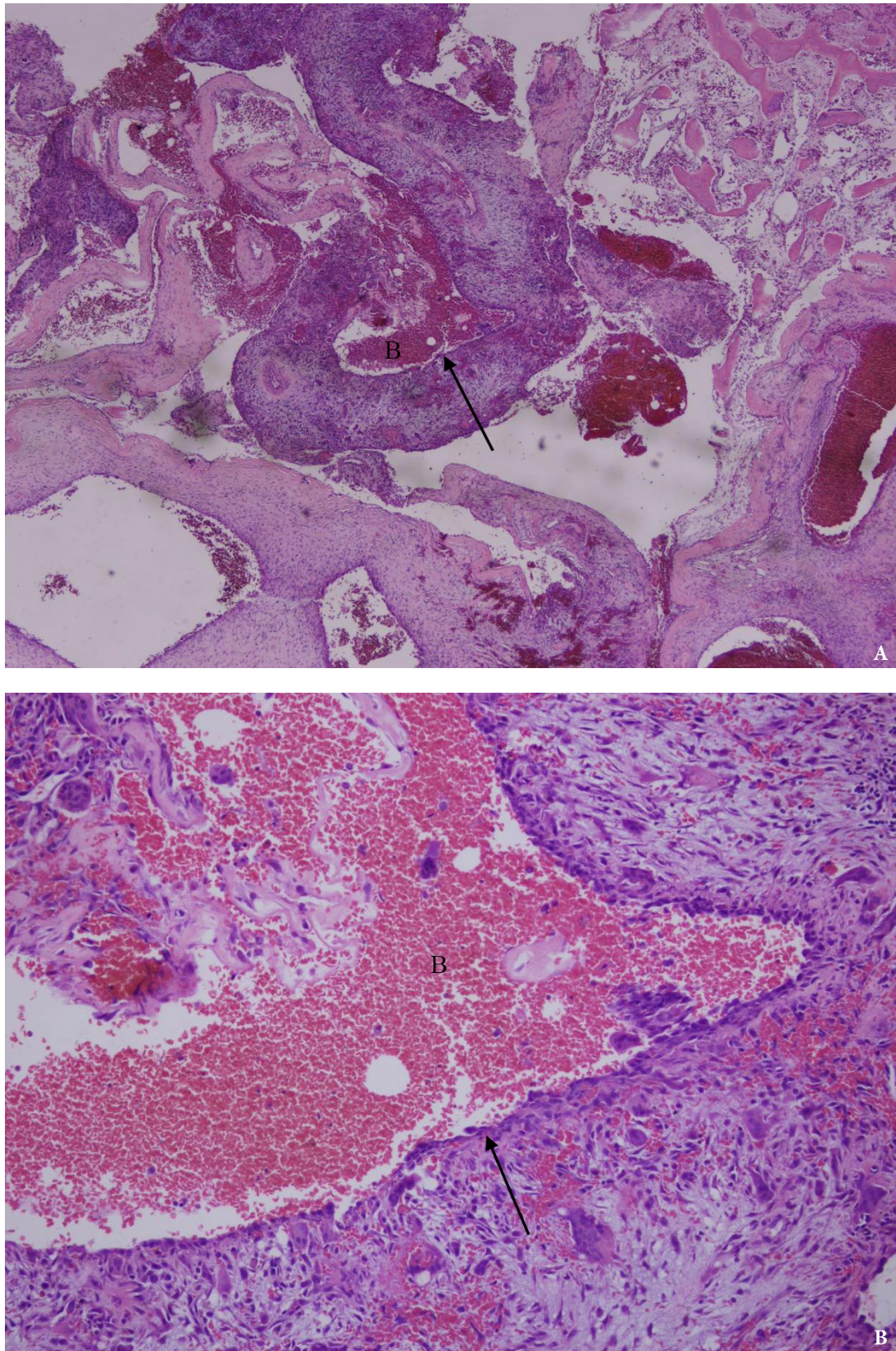


**FIGURE 7.** Reconstruction of the right condyle with a perforated clavicular joint.



**FIGURE 8.** Postoperative panoramic radiograph showing good reconstruction of the right condyle of the mandible. L, left side.





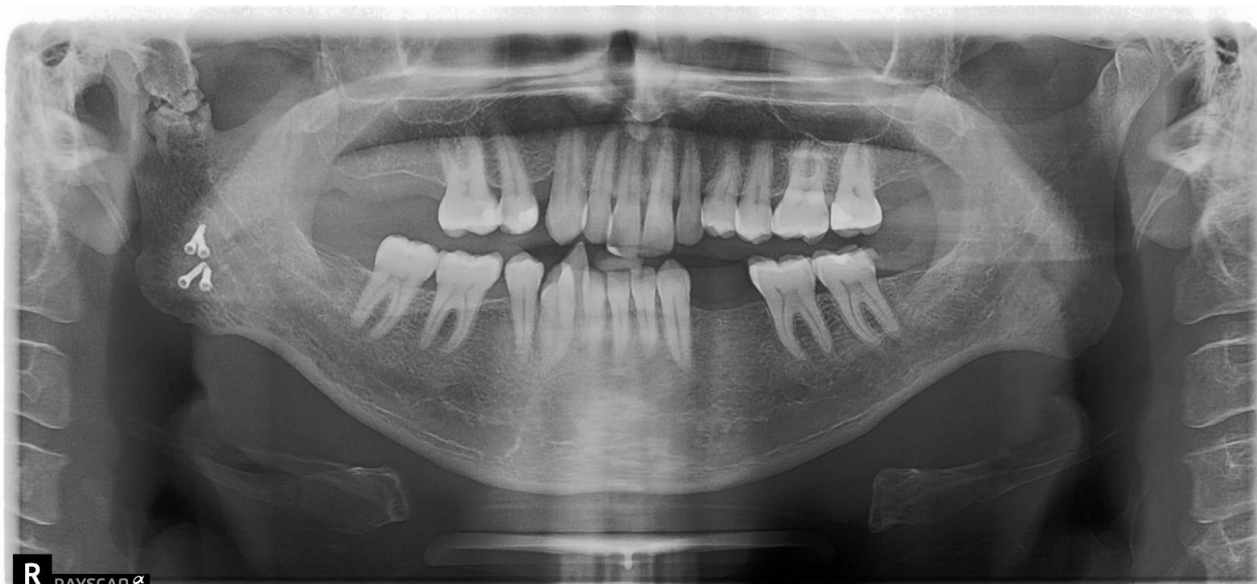**FIGURE 9.** Histopathological slides illustrating cystic spaces filled with blood under hematoxylin and eosin staining. *Arrow* denotes cyst wall populated with giant cells. '*B*' denotes cyst cavity filled with blood. Image **A** is under 40x magnification and image **B** under 200x magnification.



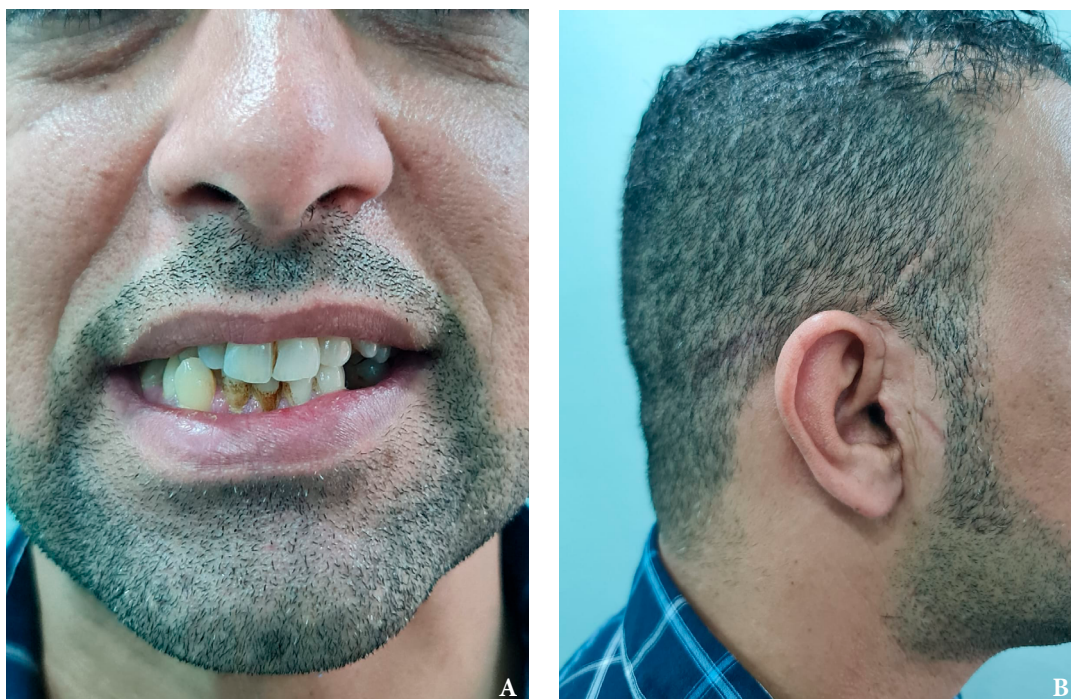## GIANT PSEUDOCYST

Over a 22-year follow-up period, no signs of recurrence were observed (Fig 10). Furthermore, facial symmetry and normal joint function were successfully restored (Fig 11). At the 22-year follow-up post-surgery, fragmentation was noted in the affected right condylar head (Fig 12), which

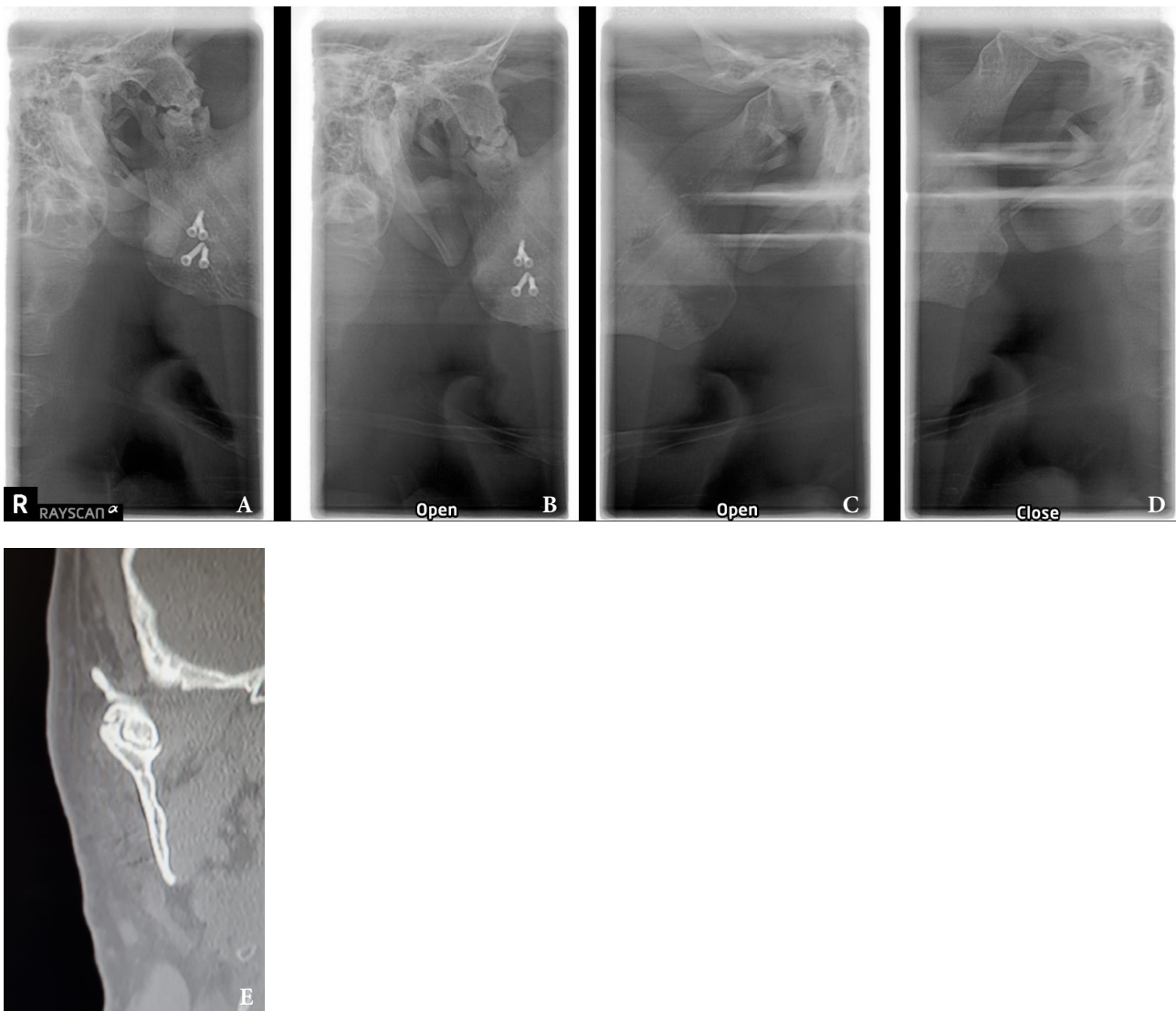
subsequently healed normally. Possible contributing factors for this development include the extended duration of follow-up, the patient's loss of posterior teeth, and subsequent joint overloading. This is also a recognized drawback of utilizing the sternoclavicular joint for TMJ reconstruction.



**FIGURE 10.** Panoramic radiograph 22 years postoperatively showing complete resolution of the lesion and fragmentation on right mandibular condyle. R, right side.



**FIGURE 11.** 22-year postoperative view of the patient (A, B).



**FIGURE 12.** Imaging during closed and open mouth position on 22-year follow-up. **A:** Radiograph of the right TMJ with the mouth closed; **B:** Radiograph of the right TMJ with the mouth open; **C:** Radiograph of the left TMJ with the mouth open; **D:** Radiograph of the left TMJ with the mouth closed; **E:** Coronal computed tomography scan with the mouth closed.

## DISCUSSION

The ABC remains enigmatic, with its origin still obscure and the precise pathological nature yet to be determined.<sup>1</sup> Although considered a non-odontogenic epithelial cyst, it is not a true bone cyst.<sup>2</sup> ABCs are more commonly found in long bones or vertebral columns, rather than in the jaws.<sup>3</sup>

The etiology and pathogenesis of aneurysmal bone cysts are not fully understood, and there is debate as to whether they arise *de novo* or result from a vascular accident in a pre-existing lesion.<sup>4</sup> Some propose that the development of ABCs may

occur in a pre-existing intra-bony lesion due to a dilated vessel.<sup>4</sup> Others argue that the transformation of a primary lesion, such as central giant cell granuloma or fibrous dysplasia, into an aneurysmal bone cyst may be initiated by microcysts. These microcysts may then enlarge and coalesce, causing rupture of adjacent vasculature.<sup>5</sup> Subsequently, an increase in intracystic pressure and bone resorption would follow in the cascade process, making ABCs a secondary phenomenon.

Most reported cases involve patients younger than 30 years old, with a higher prevalence among females.<sup>5</sup> ABCs are more common in the mandible,

particularly in the molar region.

The clinical presentation of patients with aneurysmal bone cysts is remarkably variable. However, patients typically present with a painless, firm, or hard facial swelling that is insidious in onset.<sup>7</sup> This swelling often results from the perforation of the outer cortex of the bone and subsequent protrusion into the surrounding soft tissue.<sup>8</sup>

In some cases, ABCs may be detected during routine radiographic assessments of teeth or adjacent structures. Tooth mobility is uncommon, and teeth generally retain their vitality.<sup>9</sup>

The radiographic appearance of the aneurysmal bone cyst is variable and nonspecific. Several descriptions have been described in the literature depending on the amount of bony destruction and perforation of the bony cortex and periosteal reaction. ABCs can manifest as either unilocular or multilocular radiolucencies associated with discernible cortical expansion and thinning. They are often characterized by a soap-bubble or moth-eaten appearance, and sometimes a sclerotic border is quite evident as a result of new reactive bone formation.<sup>2</sup>

Radiographic assessment of ABCs is crucial for proper preoperative evaluation, surgical planning, and determination of lesion extensiveness. Panoramic radiographs, posteroanterior (PA) views of the jaws, computerized tomography, and MRI are all essential, depending on the location, degree of bony lesion, and associated involvement of soft tissues.

The microscopic appearance of ABCs is characterized by spaces of varying sizes filled with blood and surrounded by bland fibroblast/myofibroblast-like spindle cells (Fig 9). A noticeable presence of multinucleated giant cells can be observed in these tissues.<sup>11</sup> Although this is pathognomonic of ABCs, microscopic examination should always be complemented by thorough clinical and radiographic assessments.

Various treatment options have been proposed in the literature, including enucleation, curettage, marsupialization, and bone resection. Conservative treatment is typically undertaken for smaller lesions to minimize surgical risks and morbidity. However, larger lesions with evidence of soft tissue involvement should be addressed through en-bloc resection and immediate reconstruction to prevent recurrence and the need for secondary surgical intervention.

Recurrence rates reported in the literature vary depending on the treatment option employed, with

rates as high as 50%.<sup>12</sup> Regular monitoring of the lesion is crucial to enable early intervention in the event of a recurrence. Consequently, every effort should be made to ensure complete resection with an adequate safety margin.

## CONCLUSIONS

In the case we present, the patient exhibited a preauricular painless swelling initially believed to be a parotid tumor. However, MR imaging ruled out this provisional diagnosis. Consequently, it is essential to recognize that tumors of the jaws and cystic lesions may mimic benign salivary gland pathology. Every effort should be made to exclude this possibility through comprehensive clinical and appropriate radiographic examinations.<sup>13</sup>

## ETHICS APPROVAL

Not applicable.

## CONSENT

Written informed consent was obtained from the patient for publication of this report and accompanying images.

## COMPETING INTERESTS

Authors declare that they have no competing interests.

## AVAILABILITY OF DATA AND MATERIALS

Data sharing is not applicable to this article since no dataset was generated or analyzed during the current study.

## FUNDING

This work was carried out without funding support.

## AUTHORS' CONTRIBUTIONS

All the authors contributed to the work described in the paper. GD was the operator of this case and conceived of the study. MD and AS drafted the manuscript. AS contributed to critical revising. All authors read and approved the final manuscript.

## ACKNOWLEDGEMENTS

Not applicable.

## REFERENCES (13)

1. Park W, Nam W, Park H, Kim HJ. Intraosseous lesion in mandibular condyle mimicking temporomandibular disorders: report of 3 cases. *J Orofac Pain* **2008**;22(1):65–70.
2. Warner BF, Luna MA, Robert Newland T. Temporomandibular joint neoplasms and pseudotumors. *Adv Anat Pathol* **2000**;7(6):365–81. <https://doi.org/10.1097/00125480-200007060-00004>
3. Waldron CA. Fibro-osseous lesions of the jaws. *J Oral Maxillofac Surg* **1993**;51(8):828–35. [https://doi.org/10.1016/s0278-2391\(10\)80097-7](https://doi.org/10.1016/s0278-2391(10)80097-7)
4. Rapidis AD, Vallianatou D, Apostolidis C, Lagogiannis G. Large lytic lesion of the ascending ramus, the condyle, and the infratemporal region. *J Oral Maxillofac Surg* **2004**;62(8):996–1001. <https://doi.org/10.1016/j.joms.2004.04.009>
5. Struthers PJ, Shear M. Aneurysmal bone cyst of the jaws. (I). Clinicopathological features. *Int J Oral Surg* **1984**;13(2):85–91. [https://doi.org/10.1016/s0300-9785\(84\)80077-0](https://doi.org/10.1016/s0300-9785(84)80077-0)
6. Wolford LM, Cottrell DA, Henry C. Sternoclavicular grafts for temporomandibular joint reconstruction. *J Oral Maxillofac Surg* **1994**;52(2):119–29. [https://doi.org/10.1016/0278-2391\(94\)90391-3](https://doi.org/10.1016/0278-2391(94)90391-3)
7. Struthers PJ, Shear M. Aneurysmal bone cyst of the jaws. (II). Pathogenesis. *Int J Oral Surg* **1984**;13(2):92–100. [https://doi.org/10.1016/s0300-9785\(84\)80078-2](https://doi.org/10.1016/s0300-9785(84)80078-2)
8. Motamedi MHK. Destructive aneurysmal bone cyst of the mandibular condyle: Report of a case and review of the literature. *J Oral Maxillofac Surg* **2002**;60(11):1357–61. <https://doi.org/10.1053/joms.2002.35744>
9. Telfer MR, Jones GM, Pell GM, Eveson JW. Primary bone cyst of the mandibular condyle. *Br J Oral Maxillofac Surg* **1990**;28(5):340–3. [https://doi.org/10.1016/0266-4356\(90\)90112-x](https://doi.org/10.1016/0266-4356(90)90112-x)
10. Gadre KS, Zubahy RA. Aneurysmal bone cyst of the mandibular condyle: Report of a case. *J Oral Maxillofac Surg* **2000**;58(4):439–43. [https://doi.org/10.1016/s0278-2391\(00\)90932-7](https://doi.org/10.1016/s0278-2391(00)90932-7)
11. Lee J, Huang H. Soft tissue special issue: giant cell-rich lesions of the head and neck region. *Head Neck Pathol* **2020**;14(1):97–108. <https://doi.org/10.1007%2Fs12105-019-01086-2>
12. Mankin HJ, Hornicek FJ, Ortiz-Cruz E, et al. Aneurysmal bone cyst: a review of 150 patients. *J Clin Oncol* **2005**;23(27):6756–62. <https://doi.org/10.1200/jco.2005.15.255>
13. Toljanic JA, Lechewski E, Huvos AG, et al. Aneurysmal bone cysts of the jaws: a case study and review of the literature. *Oral Surg Oral Med Oral Pathol* **1987**;64(1):72–7. [https://doi.org/10.1016/0030-4220\(87\)90119-8](https://doi.org/10.1016/0030-4220(87)90119-8)



# U-Impl<sup>®</sup>

SWITZERLAND



№ R3M 804 252 B2

Сертифікат відповідності  
технічного регламенту  
щодо медичних виробів



Switzerland Aarbergerstrasse 107A, CH-2502  
Biel, Phone/Fax +41 323230188  
info@u-impl.com  
www.u-impl.com