

DT Journal

8 2023

**Journal of Diagnostics and
Treatment of Oral and
Maxillofacial Pathology**



Editors
Oleksii Tymofieiev • Rui Fernandes
(Kyiv, Ukraine • Jacksonville, FL, USA)



Official Journal of the
Ukrainian Association for
Maxillofacial and Oral Surgeons

DTJournal.org

TANTUM VERDE®

QUICK RELIEF FROM PAIN
AND INFLAMMATION IN THE
MOUTH AND THROAT¹

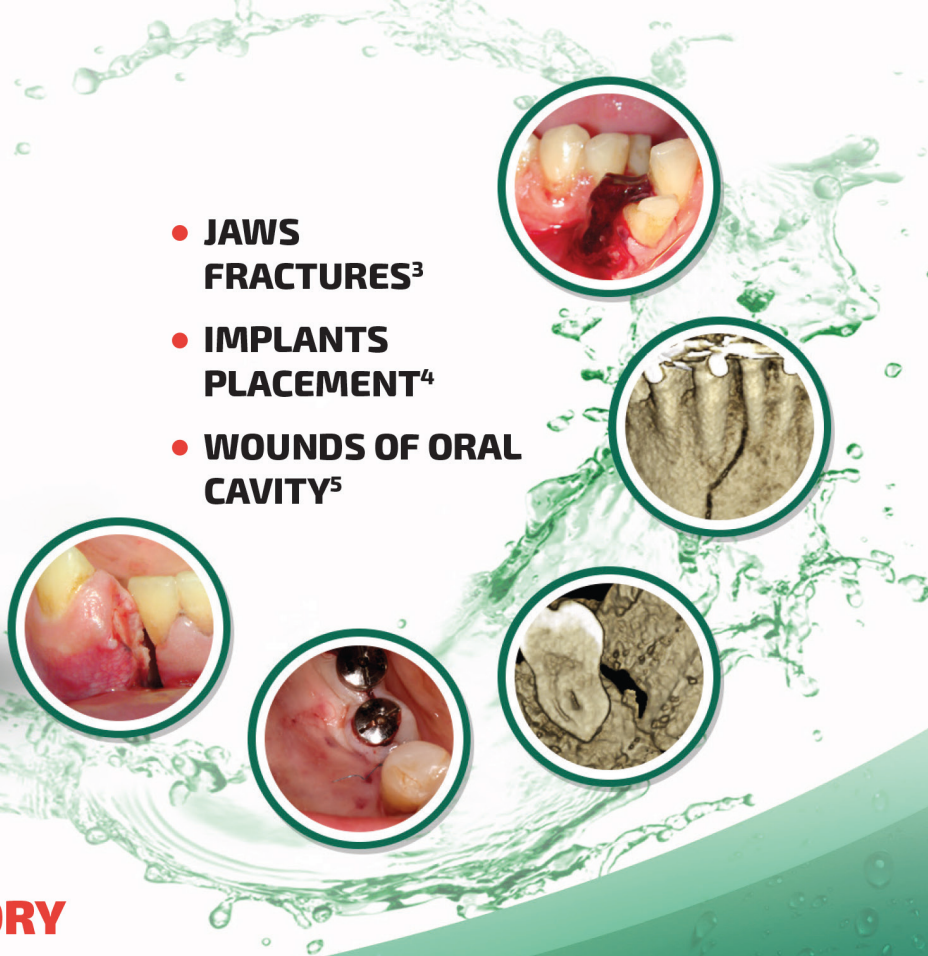
**AN INTEGRAL COMPONENT OF THE TREATMENT
OF PAIN AND INFLAMMATION IN THE ORAL CAVITY
IN 60 COUNTRIES WORLDWIDE!²**



Reg. № UA/3920/01/01

**LOCAL ANESTHETIC
AND ANTI-INFLAMMATORY
EFFECT¹**

- **JAWS
FRACTURES³**
- **IMPLANTS
PLACEMENT⁴**
- **WOUNDS OF ORAL
CAVITY⁵**



SUMMARY OF PRODUCT CHARACTERISTICS

NAME OF THE MEDICINAL PRODUCT. Tantum Verde 0.15% mouthwash. **QUALITATIVE AND QUANTITATIVE COMPOSITION.** Each 100 ml contains: active ingredient: benzydamine hydrochloride 0.15 g (equivalent to 0.134 g of benzydamine). **Therapeutic indications.** Treatment of symptoms such as irritation/inflammation including those associated with pain in the oropharyngeal cavity (e.g. gingivitis, stomatitis and pharyngitis), including those resulting from conservative or extractive dental therapy. **Posology and method of administration.** Pour 15 ml of Tantum Verde mouthwash into the measuring cup, 2-3 times per day, using it either at full concentration or diluted. If diluted, add 15 ml of water to the graduated cup. Do not exceed the recommended dosage. **Contraindications.** Hypersensitivity to benzydamine or to any of the excipient. **PHARMACOLOGICAL PROPERTIES. Pharmacodynamic properties.** Pharmacotherapeutic group: Stomatologic drugs: other agents for local oral treatment, ATC code: A01AD02. Clinical studies demonstrate that benzydamine is effective in relieving suffering from localised irritation of the mouth and pharynx. In addition, benzydamine possesses a moderate local anaesthetic effect. **Pharmacokinetic properties. Absorption.** Absorption through the oropharyngeal mucosa is demonstrated by the presence of measurable quantities of benzydamine in human plasma. These levels are insufficient to produce systemic effects. **Distribution.** When applied locally, benzydamine has been shown to accumulate in inflamed tissues where it reaches effective concentrations because of its capacity to penetrate the epithelial lining.

Information about medicines. Information for health care professionals for use in professional activities.

1. Інструкція для медичного застосування лікарського засобу Тантум Верде®, розчин для ротової порожнини, РПН № UA/3920/01/01, затверджено Наказом Міністерства охорони здоров'я України № 636 від 01.10.2015.

2. <http://www.angelini-pharma.com/wps/wcm/connect/com/home/Angelini+Pharma+in+the+world/>

3. Тимофеев А.А. и др. "Особенности гигиены полости рта для профилактики воспалительных осложнений при переломах нижней челюсти". Современная стоматология 2015;1(75):52-8.

4, 4.5. Tymofiejew O.O. et al "Prevention of inflammatory complications upon surgeries in maxillofacial region". J Diagn Treat Oral Maxillofac Pathol. 2017;1:105-12.

Clinical and CT images are courtesy of: Ievgen Fesenko (Department of Oral & Maxillofacial Surgery, PHEI "Kyiv Medical University", Kyiv, Ukraine), Oleg Mastakov ("SCIEDECE—Scientific Center of Dentistry & Ultrasound Surgery" Kyiv, Ukraine)



04119, Kiev, Melnikova str. 83D, of. 404.
Tel.: (044) 538-01-26
Fax: (044) 538-01-27



About the Journal: Aims and Scope

AUGUST 2023 • VOLUME 7 • ISSUE 8
www.djournal.org

Official Title

Journal of Diagnostics and Treatment of Oral and Maxillofacial Pathology

Standard Abbreviation: ISO 4

J. Diagn. Treat. Oral Maxillofac. Pathol.

Acronym

JDTOMP

International Standard Serial Number (ISSN)

Electronic ISSN 2522-1965

Aims & Scope

This is a monthly peer-reviewed oral and maxillofacial surgery journal focused on: microvascular and jaw reconstructive surgery, dental implants, salivary gland tumors/diseases, TMJ lesions, virtual surgical planning, implementation of ultrasonography into the practice of oral and maxillofacial surgeons.

Editorial Board (EB) Composition

- EB shows significant geographic diversity representing 30 opinion leaders from 13 countries: Brazil, Canada, Colombia, Greece, Hong Kong (SAR, China), India, Israel, Italy, Slovak Republic, Spain, Ukraine, United Arab Emirates, and United States.
- The majority of the EB Members have a discernible publication history in Scopus, Web of Science, and journals with a high impact factor.
- The publication records of all EB members are consistent with the stated scope and published content of the journal.
- The journal has a several full-time professional editors.
- Gender distribution of the editors: 10% women, 90% men, 0% non-binary/other, and 0% prefer not to disclose.

Frequency

12 issues a year (from January 2020)

Publication History

2017: 4 issues a year

2018: 4 issues a year

2019: 10 issues a year

From 2020: 12 issues a year

Publishing Model

Journal of Diagnostics and Treatment of Oral and Maxillofacial Pathology is a fully online-only open access and peer-reviewed publication.

Type of Peer Review

The journal employs “double blind” reviewing.

Article Publishing Charge (APC)

The APC in this journal is US \$500 and US \$250 (excluding taxes) depending on the article’s type. Details at website: dtjournal.org.

13 Types of Articles Currently Published by the Journal

Editorials/Guest Editorials/Post Scriptum Editorials, Images, Case Reports/Case Series, Original Articles, Review Articles, Discussions, Paper Scans (*synonyms*: Review of Articles, Literature Scan), Book Scans (*synonym*: Book Reviews), Letters to the Editor (*synonym*: Letters), and Viewpoints.

State Registration: Ministry of Justice of Ukraine

Registration: Jul 28, 2016 (Certificate: KB № 22251-12151 P)

Re-registration: May 21, 2019 (Certificate: KB № 23999-13839 IIP)

Re-registration: Aug 10, 2021 (Certificate: KB № 24951-14891 IIP)

Co-Founders

1. Shupyk National Healthcare University of Ukraine (formerly known as Shupyk National Medical Academy of Postgraduate Education).
2. Private Higher Educational Establishment “Kyiv Medical University.”
3. OMF Publishing, Limited Liability Company.

Publisher

OMF Publishing, LLC is an academic publisher focused on medical and linguistic sciences.

Address: 13-A Simferopolska Street, office 121, Kyiv 02096, Ukraine.

Crossref Membership

OMF Publishing, LLC is a member of Publishers International Linking Association, Inc. which doing business as a Crossref. OMF Publishing’s active membership: From February 2017 to present.

Official Journal of the Association

Ukrainian Association for Maxillofacial and Oral Surgeons

Ukrainian Association for Maxillofacial and Oral Surgeons (UAMOS)

Address: 4-A Profesora Pidvysotskoho Street, Kyiv 01103, Ukraine.

Tel., fax: +38 044 528 35 17.

Website: uamos.org.

© 2023 OMF PUBLISHING, LLC

Editorial Board

AUGUST 2023 • VOLUME 7 • ISSUE 8
www.djournal.org

Editor in Chief

Oleksii O. Tymofiev, ScD
Kyiv, Ukraine

Deputy Editor in Chief

Rui P. Fernandes, MD, DMD, FACS, FRCS(Ed)
Jacksonville, Florida, United States

Section Editors

Bone Augmentation Techniques

Nardy Casap, MD, DMD
Jerusalem, Israel

Business

Ivan V. Nagorniak, MSc, PhD
Kyiv, Ukraine

Craniofacial Deformities

Sunil Richardson, MDS
Nagercoil, Tamil Nadu, India

Facial Feminization Surgery

Kyle Keojampa, MD, FACS
Los Angeles, California, United States

Facial Plastic Surgery

Tirbod Fattahi, MD, DDS, FACS
Jacksonville, Florida, United States

Head & Neck Oncologic Surgery

Todd C. Hanna, MD, DDS, FACS
New York, New York, United States

Head & Neck Radiology

Anil T. Ahuja, MBBS, MD, FRCR, FHKCR, FHKAM
Hong Kong, SAR, China

Images

Camilo Mosquera, DDS
Bogotá, D.C., Colombia

Orthognathic Surgery

Mario Brinhole
São Paulo, São Paulo, Brazil

Robotic Surgery

Salam O. Salman, MD, DDS, FACS
Jacksonville, Florida, United States

TMJ Lesions/Disorders

Belmiro C. Vasconcelos, DDS, PhD
Recife, Pernambuco, Brazil

Editorial Board Members

Oleh M. Antonyshyn, MD, FRCS(C)
Toronto, Ontario, Canada

Anthony M. Bunnell, MD, DMD, FACS
Jacksonville, Florida, United States

Nur A. Hatab, DMD, PhD
Ras Al Khaimah, United Arab Emirates

Michael T. Kase, DMD
Birmingham, Alabama, United States

Andrey V. Kopchak, ScD
Kyiv, Ukraine

Olindo Massarelli, MD, PhD, FEBOMFS
Sassari, Italy

Anastasiya Quimby, DDS, MD
Fort Lauderdale, Florida, United States

Daniel Robles Cantero, DDS, MSc
Madrid, Spain

Peter Stanko, MD, PhD
Bratislava, Slovak Republic

Rostyslav M. Stupnytskyi, ScD
Kyiv, Ukraine

Olexander O. Tymofiev, ScD
Kyiv, Ukraine

Natalia O. Ushko, ScD
Kyiv, Ukraine

Andrew Yampolsky, DDS, MD
Philadelphia, Pennsylvania, United States

Web & Social Media Editor

João L. Monteiro, DDS
Boston, Massachusetts, United States

Director, Journal Development Department

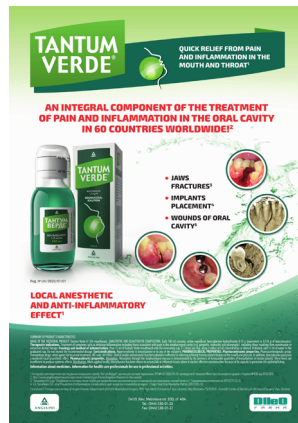Evangelos G. Kilipiris, DMD
Thessaloniki, Greece | Bratislava, Slovak Republic

Managing Editor

Ievgen I. Fesenko, PhD
Kyiv, Ukraine

Resident Ambassador

John M. Le, MD, DDS
Birmingham, Alabama, United States



TANTUM VERDE®

INFORMATION LEAFLET
for the medicinal product

Composition:

active substance: **benzydamine hydrochloride;**

100 mL of solution contain benzydamine hydrochloride 0.15 g;

excipients: ethanol 96%, glycerol, methyl parahydroxybenzoate (E 218), flavor (menthol), saccharin, sodium hydrocarbonate, Polysorbate 20, Quinoline Yellow (E 104), Patent Blue V (E 131), purified water.

Dosage form. Oromucosal solution.

Basic physical and chemical properties: a clear green liquid with a typical mint flavor.

Pharmacotherapeutic group. Dental preparations. Other agents for local oral treatment.

ATC code: A01A D02.

Pharmacological properties.

Pharmacodynamics.

Benzydamine is a non-steroidal anti-inflammatory drug (NSAID) with analgesic and antiexudative properties.

Clinical studies have shown that benzydamine is effective in the relief of symptoms accompanying localized irritation conditions of the oral cavity and pharynx. Moreover, benzydamine has anti-inflammatory and local analgesic properties, and also exerts a local anesthetic effect on the oral mucosa.

Pharmacokinetics.

Absorption through the oral and pharyngeal mucosa has been proven by the presence of measurable quantities of benzydamine in human plasma. However, they are insufficient to produce any systemic pharmacological effect. The excretion occurs mainly in urine, mostly as inactive metabolites or conjugated compounds.

When applied locally, benzydamine has been shown to cumulate in inflamed tissues in an effective concentration

due to its ability to permeate through the mucous membrane.

Clinical particulars.

Indications.

Symptomatic treatment of oropharyngeal irritation and inflammation; to relieve pain caused by gingivitis, stomatitis, pharyngitis; in dentistry after tooth extraction or as a preventive measure.

Contraindications.

Hypersensitivity to the active substance or to any other ingredients of the product.

Interaction with other medicinal products and other types of interaction.

No drug interaction studies have been performed.

Warnings and precautions.

If sensitivity develops with long-term use, the treatment should be discontinued and a doctor should be consulted to get appropriate treatment.

In some patients, buccal/pharyngeal ulceration may be caused by severe pathological processes. Therefore, the patients, whose symptoms worsen or do not improve within 3 days or who appear feverish or develop other symptoms, should seek advice of a physician or a dentist, as appropriate.

Benzydamine is not recommended for use in patients hypersensitive to acetylsalicylic acid or other non-steroidal anti-inflammatory drugs (NSAIDs).

The product can trigger bronchospasm in patients suffering from or with a history of asthma. Such patients should be warned of this.

For athletes: the use of medicinal products containing ethyl alcohol might result in positive antidoping tests considering the limits established by some sports federations.

Use during pregnancy or breast-feeding

No adequate data are currently available on the use of benzydamine in pregnant and breastfeeding women. Excretion of the product into breast milk has not been studied. The findings of animal studies are insufficient to make any conclusions about the effects of this product during pregnancy and lactation.

The potential risk for humans is unknown.

TANTUM VERDE should not be used during pregnancy or breast-feeding.

Effects on reaction time when driving or using machines

When used in recommended doses, the product does not produce any effect on the ability to drive and operate machinery.

Method of administration and doses.

Pour 15 mL of TANTUM VERDE solution from the bottle into the measuring cup and gargle with undiluted or diluted product (15 mL of the measured solution can be diluted with 15 mL of water). Gargle 2 or 3 times daily. Do not exceed the recommended dose.

Children.

The product should not be used in children under 12 years due to a possibility of ingestion of the solution when gargling.

Overdosage.

No overdose has been reported with benzydamine when used locally. However, it is known that benzydamine, when ingested in high doses (hundreds times higher than those possible with this dosage form), especially in children, can cause agitation, convulsions, tremor, nausea, increased sweating, ataxia, and vomiting. Such acute overdose requires immediate gastric lavage, treatment of fluid/salt imbalance, symptomatic treatment, and adequate hydration.

Adverse reactions.

Within each frequency group, the undesirable effects are presented in order of their decreasing seriousness.

Adverse reactions are classified according to their frequency: very common ($\geq 1/10$); common ($\geq 1/100$ to $<1/10$); uncommon ($\geq 1/1,000$ to $<1/100$); rare ($\geq 1/10,000$ to $<1/1,000$); very rare ($<1/10,000$); frequency unknown (cannot be estimated from the available data).

Gastrointestinal disorders: rare – burning mouth, dry mouth; *unknown* – oral hypesthesia, nausea, vomiting, tongue edema and discoloration, dysgeusia.

Immune system disorders: rare – hypersensitivity reaction, *unknown* – anaphylactic reaction.

Respiratory, thoracic and mediastinal disorders: very rare – laryngospasm; *unknown* – bronchospasm.

Skin and subcutaneous tissue disorders: uncommon – photosensitivity; very rare – angioedema; *unknown* – rash, pruritus, urticaria.

Nervous system disorders: *unknown* – dizziness, headache.

TANTUM VERDE contains methyl parahydroxybenzoate, which can cause allergic reactions (including delayed-type reactions).

Shelf life. 4 years.

Storage conditions.

Do not store above 25°C. Keep out of reach of children.

Packaging.

120 mL of solution in a bottle with a measuring cup; 1 bottle per cardboard box.

Dispensing category.

Over-the-counter medicinal product.

Manufacturer.

Aziende Chimiche Riunite Angelini Francesco A.C.R.A.F. S.p.A., Italy.

Location of the manufacturer and its business address. Via Vecchia del Pinocchio, 22 – 60100 Ancona (AN), Italy.

Date of the last revision of the text.

September 26, 2018.

Information leaflet is

APPROVED by

Order of the

Ministry of Health of Ukraine

No. 636 dated 01.10.2015

Registration Certificate

No. UA/3920/01/01

Our Supporters

AUGUST 2023 • VOLUME 7 • ISSUE 8
www.djournal.org



FIGURE. Evangelos G. Kilipiris, MD, DMD from the National Institute of Children's Diseases and Faculty of Medicine at Comenius University, Bratislava, Slovak Republic. A kind support of Dr. Kilipiris during the 5 years at the position of Director, Journal Development Department helped our journal to move forward and to evolve. An honorary plaque was presented to him on behalf of the Chief Editor with words "To a Founding Director, Author of Multiple Articles and Reviews, Great Thanks and Appreciation." Photo was taken on November 23, 2021.

Content

of the Volume 7 • Issue 8 • August 2023

A1 **Publisher & Editorial Office Information**

A2 **Editorial Board**

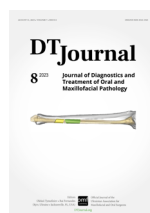A5 **Our Supporters**

A6 **Content, Courtesy, & Erratum**

CASE

87 **An Unusual Presentation of a Neck Mass – Traumatic Pseudoaneurysm Following Third Molar Surgery: A Case Report**

Chad Dammling, John M. Le, Lior Aljadeff, Jesse G. A. Jones, Mark Ogilvie, & Anthony B. Morlandt

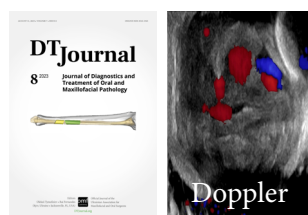

COURTESY

Journal's cover image (virtual surgical planning for a segmental mandibular reconstruction with fibula transplant) is courtesy of Rui P. Fernandes, MD, DMD, FACS, FRCS.

Image was taken from the article: Fernandes RP, Quimby A, Salman S. Comprehensive reconstruction of mandibular defects with free fibula flaps and endosseous implants. *J Diagn Treat Oral Maxillofac Pathol* 2017;1(1):6–10.

<https://doi.org/10.23999/j.dtomp.2017.1.1>



CASE

An Unusual Presentation of a Neck Mass – Traumatic Pseudoaneurysm Following Third Molar Surgery: A Case Report

Chad Dammling,^a John M. Le,^{b,*} Lior Aljadeff,^c Jesse G. A. Jones,^d Mark Ogilvie,^e & Anthony B. Morlandt^f

ABSTRACT

Traumatic pseudoaneurysm (TPA) is an extremely rare complication following a tooth extraction. TPAs are vascular lesions that occur due to extravasated blood that is still contained by the adventitia or adjacent soft tissue. This sac of blood may continue to expand, leading to superimposed infection, severe hemorrhage, or thromboembolism. In the maxillofacial region, TPA is most often associated with penetrating trauma, condylar fractures, or orthognathic surgery and can present days to weeks following the inciting event. The purpose of this paper is to review the management of a rare facial artery TPA following routine mandibular third molar tooth extraction in a 19-year-old healthy male. A computed tomography angiography and color Doppler ultrasound were used for diagnosis of the TPA. The initial treatment involved endovascular embolization followed by surgical excision due to the delayed appearance of a large 3-cm upper neck mass. While TPA is a rare complication following third molar surgery, we report the first case presenting to the head and neck surgeon as a unilateral neck mass following definitive endovascular therapy.

Keywords: traumatic pseudoaneurysm, dentoalveolar surgery, maxillofacial complications, endovascular embolization, third molar surgery, neck mass, cervical pathology

^a Chad Dammling, DDS, MD; Resident, Department of Oral and Maxillofacial Surgery – School of Dentistry University of Alabama at Birmingham, Birmingham, AL, 35233, USA. E-mail: dammling@gmail.com.

^b John M. Le, DDS, MD; Resident, Department of Oral and Maxillofacial Surgery – School of Dentistry University of Alabama at Birmingham, Birmingham, AL, 35233, USA. E-mail: johnmle@gmail.com. ORCID: <https://orcid.org/0000-0002-4836-2487>

^c Lior Aljadeff, DDS, MD; Fellow, Section of Oral Oncology, Department of Oral and Maxillofacial Surgery – School of Dentistry, University of Alabama at Birmingham, Birmingham, AL, 35233, USA. E-mail: lior.aljadeff@gmail.com. ORCID: <https://orcid.org/0000-0002-7317-8526>

^d Jesse G.A. Jones, MD; Assistant Professor, Departments of Neurosurgery and Radiology, Heersink School of Medicine, University of Alabama at Birmingham, Birmingham, AL, USA. E-mail: jessejones@uabmc.edu.

^e Mark Ogilvie, MD; Interventional Neuroradiology Fellow (2022), Department of Neurosurgery, Heersink School of Medicine, University of Alabama at Birmingham, Birmingham, AL, USA. E-mail: ogilvie1@gmail.com.

^f Anthony B. Morlandt, DDS, MD, FACS; Endowed Peter D. Waite Professor and Chief of Oral Oncology, Department of Oral and Maxillofacial Surgery – School of Dentistry, University of Alabama at Birmingham, Birmingham, AL 35233, USA. E-mail: morlandt@uab.edu. E-mail: <https://orcid.org/0000-0002-9267-3960>

* **Correspondence:** John M. Le, DDS, MD, Address: Department of Oral and Maxillofacial Surgery, School of Dentistry, Rm 419, 1919 7th Ave S., Birmingham, AL 35233. Fax 205.975.6671. Phone 562.290.7761. E-mail: johnmle@gmail.com (John M. Le).

Please cite this article as: Dammling C, Le JM, Aljadeff L, Jones JGA, Ogilvie M, Morlandt AB. An unusual presentation of a neck mass – traumatic pseudoaneurysm following third molar surgery: a case report. *J Diagn Treat Oral Maxillofac Pathol* 2023;7(8):87–93.

The word 'Doppler' at the upper right icon means that article contains color Doppler sonogram.

Paper received 27 July 2023
Accepted 11 August 2023
Available online 13 August 2023

<https://doi.org/10.23999/j.dtopm.2023.8.1>

© 2023 OMF Publishing LLC. This is an open access article under the CC BY license (<https://creativecommons.org/licenses/by-nc/4.0/>).

INTRODUCTION

Third molar surgery, also known as wisdom tooth extraction, is one of the most common procedures performed by the oral and maxillofacial surgeon with a generally low complication rate.¹⁻³ Adverse events most often include infection, alveolar osteitis, bleeding, or swelling.³ Less common complications include paresthesia, mandibular fracture and displacement of teeth or instruments. Traumatic pseudoaneurysm (TPA) formation is an extremely rare complication which has been reported in the literature as a potential sequela following tooth extraction.³⁻¹¹ In the maxillofacial region, TPA is most often associated with penetrating trauma, condylar fractures, and orthognathic surgery and involves the branches of the internal maxillary artery.^{3,4} TPA occurs when there is disruption in the vascular endothelium followed by blood extravasation into the adventitia or adjacent soft tissue. The resulting collection of blood may continue to expand, leading superimposed infection, severe hemorrhage, or thromboembolism. These lesions lack an intact

muscularis layer and are surrounded by a weak connective tissue pseudocapsule. Management can involve both surgical and endovascular treatments. Minimally invasive catheter-based embolization is the favored technique as it avoids the morbidity of an open surgical procedure.¹² In this case report, we review the current diagnostic imaging modalities and endovascular treatment paradigm for traumatic pseudoaneurysm of the facial artery following third molar tooth extraction. Several months following a catheter-based embolization procedure, the patient underwent surgical excision of the organized thrombus which presented as a well-lateralized level II neck mass.

CASE SUMMARY

A 19-year-old male with no significant medical history presented to our clinic for evaluation of firm, non-pulsatile, and non-painful mass at the left angle of the mandible that had been present for 3 months (Fig 1). Upon further investigation, the patient recalled having a routine and uneventful



FIGURE 1. Clinical photo demonstrating 3-cm mass at the left mandibular angle.

third molar tooth extraction several months prior. He developed acute neck swelling shortly thereafter and sought medical attention at a nearby emergency department. A computed tomography angiography (CTA) demonstrated a 3-cm left-sided facial artery pseudoaneurysm containing arterial blood and thrombus (Fig 2A and 2B). Ultrasound with color Doppler showed turbulent bidirectional blood flow in a “yin-yang” pattern highly suggestive of TPA (Fig 2C). Following a thorough discussion of the risks and benefits of embolization, the Interventional Neuroradiology service then treated the patient with endovascular therapy. A 5-french sheath (Terumo, Somerset, NJ) was placed into the right radial artery under ultrasound guidance. An anti-spasmodic cocktail of nitroglycerin, heparin and verapamil was given intra-arterially. A left common carotid artery angiogram confirmed the TSA arising from a 2nd order branch of the facial artery (Fig 3A). A microcatheter (Echelon 10, Medtronic, Minneapolis, MN) was then advanced into the left external carotid and facial arteries and a super selective angiogram performed. With the microcatheter tip just proximal to the TPA, an embolization coil (Axium, EV3 Neurovascular, Irvine, CA) was detached at its orifice. Next, a liquid embolic (Trufill, Cerenovus, Irvine, CA) admixed 1:1 with lipiodol was infused around the coil to completely occlude arterial inflow to the TSA (Fig 3D).

An immediate post-embolization angiogram

demonstrated facial artery occlusion distal to the submental branch, at the proximal aspect of the TSA. However, the facial artery reconstituted distally by way of its anastomosis with the lingual artery, and this allowed minimal delayed filling of the TSA in retrograde fashion (Fig 3B and 3C). The patient was discharged home the same day and instructed to perform manual compression of the TSA twice daily for 20 minutes at a time to help ensure thrombosis. At 1-month clinic follow-up, the patient denied any further pulsatile symptoms or bleeding although noted slight facial asymmetry around the previous pseudoaneurysm (Fig 4A). Two months later, the patient presented to the Oral Oncology service complaining of a painless left upper neck mass. Computed tomography demonstrated a well-circumscribed, scarred mass in the region of the previous pseudoaneurysm. Under general anesthesia, a horizontal incision was made in a natural skin crease directly overlying the lesion. Subplatysmal flaps were elevated, and the lesion was identified under the superficial layer of the deep cervical fascia (Fig 4B). Both superior and inferior to the lesion, several feeder branches of the external carotid system were identified, suture ligated, and divided. The lesion was then dissected from the mylohyoid and posterior belly of the digastric muscles and excised (Fig 4C and 4D). The patient tolerated the procedure well and had an uneventful postoperative course. He was content with both functional and cosmetic outcomes.

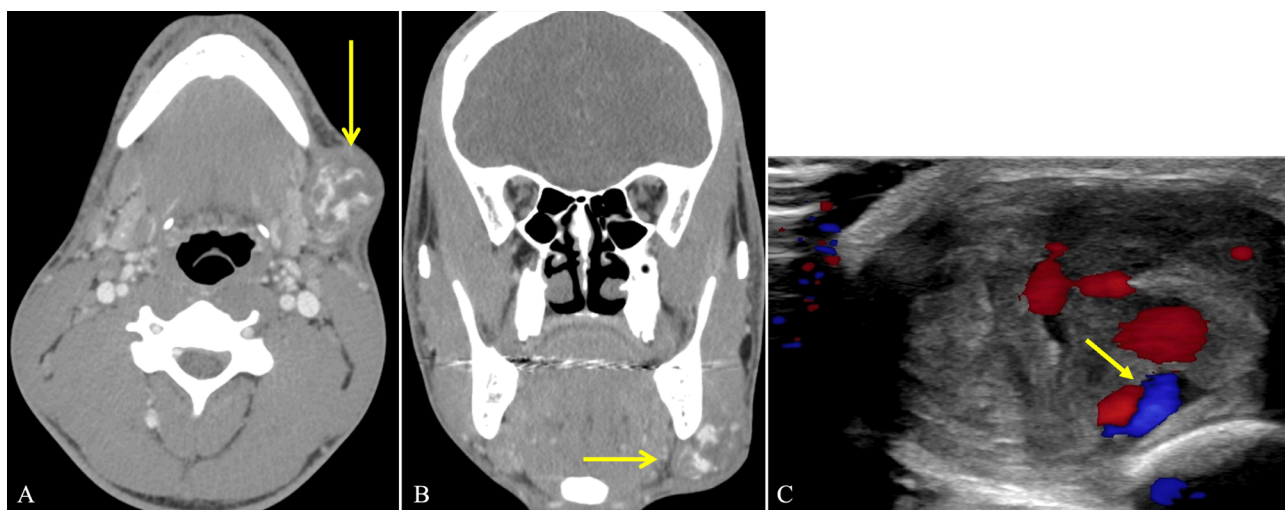


FIGURE 2. Computed tomography angiography of axial (A) and coronal (B) views of the 3-cm pseudoaneurysm (yellow arrow) located at the left mandibular angle and a color Doppler ultrasound (C) of the mass demonstrating “yin-yang” pattern (yellow arrow) consistent with a partially thrombosed pseudoaneurysm.

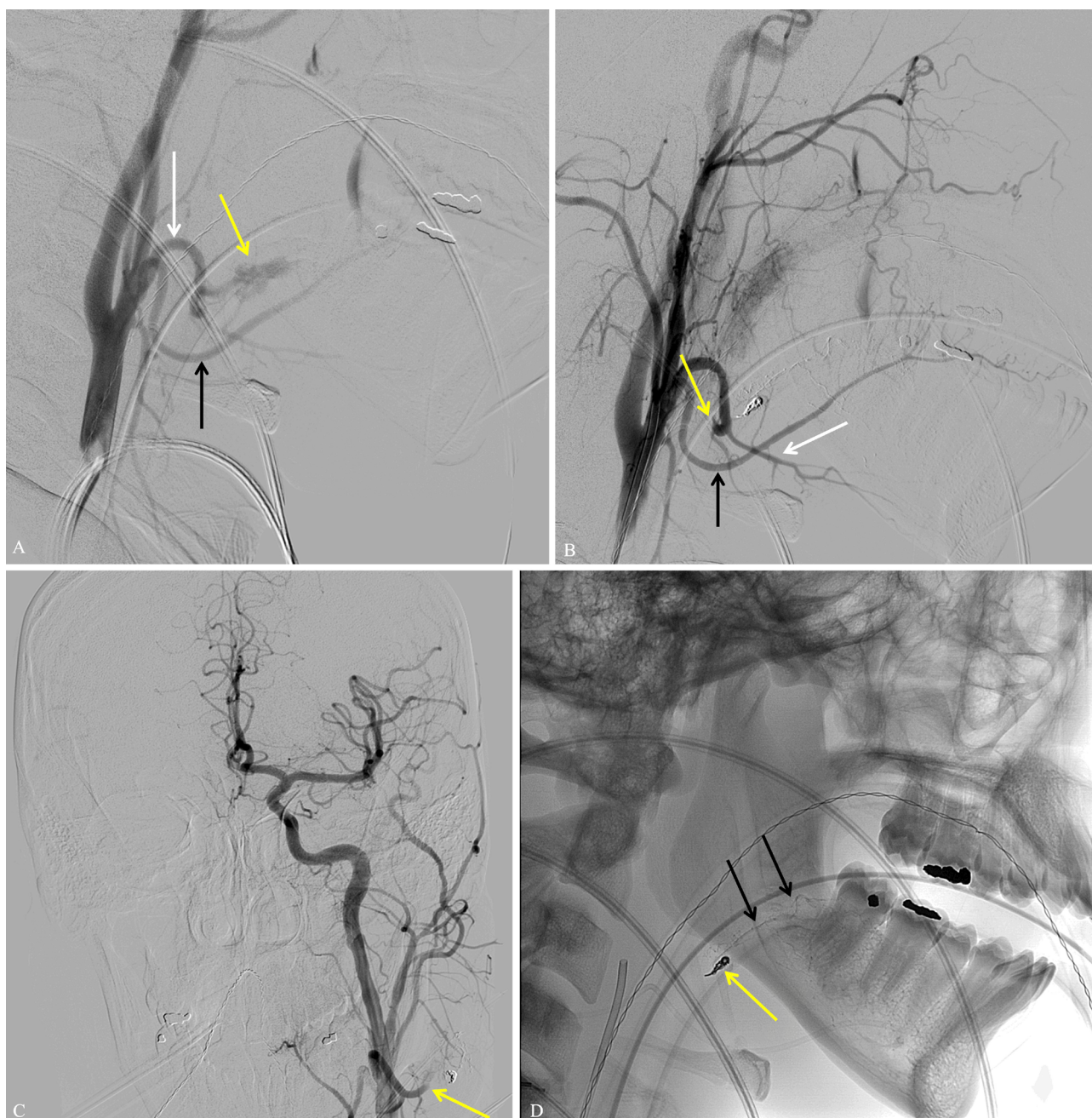


FIGURE 3. (A) Lateral digital subtraction angiogram (DSA) from the left common carotid artery demonstrating pseudoaneurysm (*yellow arrow*) coming off the 2nd order branch of the facial artery (*white arrow*). The lingual artery in inferior to the facial artery (*black arrow*). (B) Post-embolization DSA demonstrating successful cessation of flow in 2nd order facial artery and pseudoaneurysm and preservation of flow in the other 2nd order branch off facial artery, submental artery (*white arrow*). The lingual artery is inferior (*black arrow*). (C) Anterior-to-posterior DSA demonstrating normal cerebral angiogram and successful 2nd order facial artery embolization (*yellow arrow*). (D) Lateral radiograph post embolization demonstrating coil pack (*yellow arrow*) and glue in adjacent 3rd order facial artery branches (*black arrows*) in region of wisdom tooth extraction.

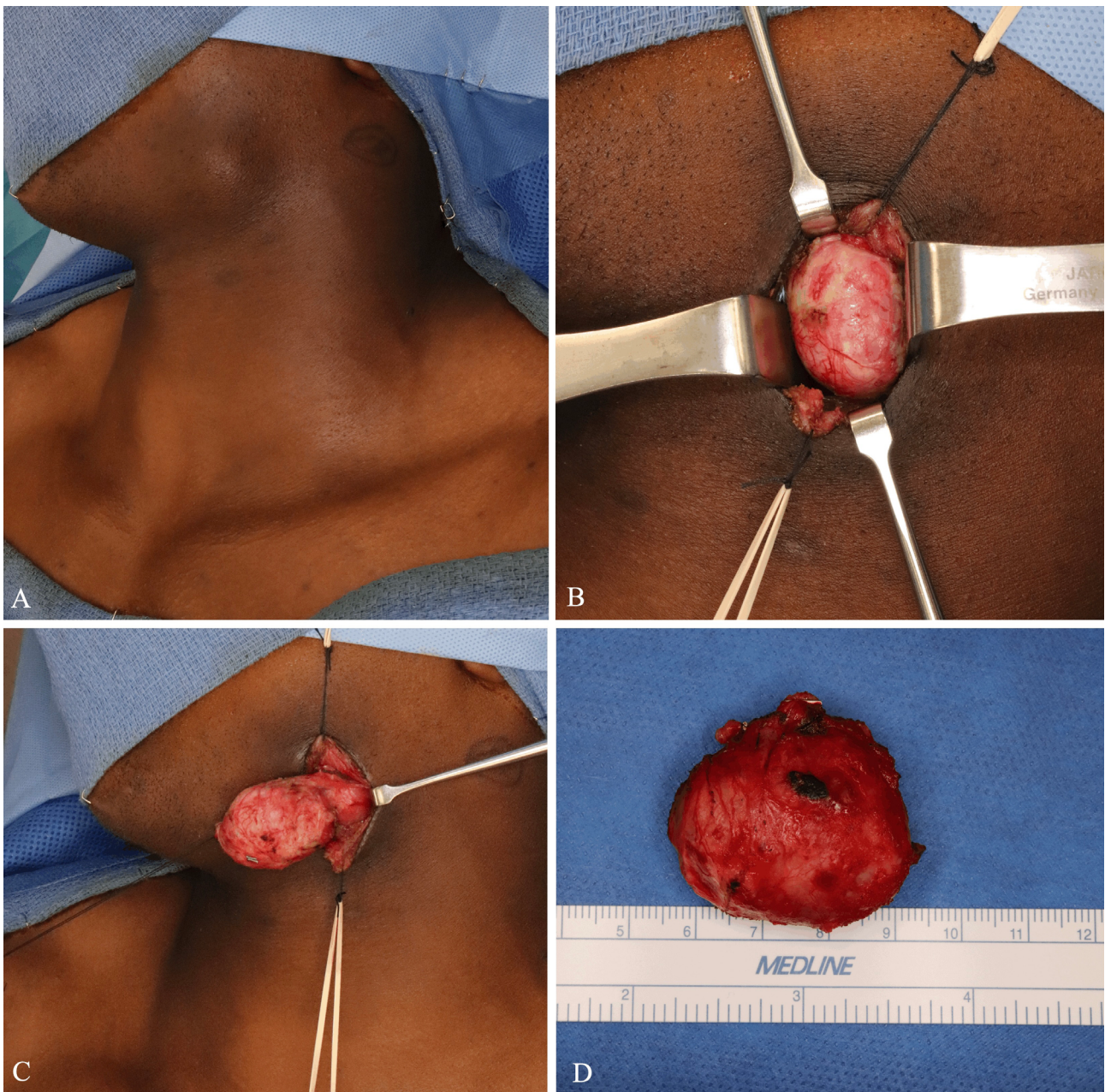


FIGURE 4. (A) Residual mass following embolization of the facial artery. (B) Isolation of the mass. (C) Removal of the mass from the underlying fibromuscular tissue using circumferential blunt dissection. (D) Completed excised specimen.

DISCUSSION

TPA in the maxillofacial region is extremely rare and has been reported to occur following penetrating trauma, condylar fractures, orthognathic surgery, and dental extractions. The mandibular portion of the internal maxillary artery is at frequent risk of injury with subcondylar fractures due to its close approximation with the condylar neck. During orthognathic surgery, both the facial artery and descending palatine arteries are at risk for TPA formation due to the proximity of these vessels to the osteotomy sites.¹³ TPA related to dental extractions have been reported to occur at the lingual artery, internal maxillary artery, facial artery, and inferior alveolar artery.^{3,6-10,14,15} When there is clinical concern for the occurrence of a TPA, a CTA remains the preferred diagnostic modality for initial evaluation.¹¹ However, when a CTA cannot be obtained, the utilization of ultrasonography and color Doppler can also verify a pseudoaneurysm with the visualization of bidirectional blood flow as shown in this case.

The inferior alveolar branch of the internal maxillary artery provides vascular supply to the mandible and dentition via the mandibular foramen and more commonly associated with injury following dentoalveolar surgery. Meanwhile, injury to the facial artery, as described in this case report, is much less common and may relate to excessive lateral dissection during flap elevation for mandibular third molars. In addition, the anastomoses between the facial and inferior alveolar arteries via mylohyoid and submental branches should also be evaluated at the time of catheter angiography when vessel injury is suspected.¹⁶

Treatment for TPA most commonly involves endovascular therapy with interventional radiology. Endovascular treatments for TPA are diverse and include gel foam, cyano-acrylate, ethylene vinyl alcohol (EVOH), coils, particles, and ethanol. Acute complications associated with endovascular treatment can include facial palsy, stroke, or central retinal artery occlusion due to thromboembolic events.¹¹ Small TSAs may be saturated with liquid embolic to prevent retrograde filling. However, the same technique is impractical for large TPA as the embolic will harden and result in a palpable mass. In most scenarios, the arterial segment distal to the TPA cannot be catheterized and so proximal inflow alone is occluded. In some cases, like the one presented here, retrograde filling may occur and oppose complete thrombosis.

The authors recommend daily manual compression to counteract this occurrence and hasten resolution. Additional surgery may be indicated to remove the residual thrombus, which may present clinically as a mass that can be unaesthetic as shown in this case.

CONCLUSION

In this case, a TPA that had occurred following routine third molar surgery initially presented to our clinic as a unilateral neck mass. Initially, the TPA was treated by endovascular coil embolization with complete resolution, and the residual organized thrombus mass was completely excised 2 months later to correct the patient's facial deformity. While TPA in the maxillofacial region following routine third molar surgery is an uncommon complication, early recognition using diagnostic imaging followed by treatment collaboration with neuroradiology is essential in preventing more serious complications.

ACKNOWLEDGEMENTS

Not applicable.

AUTHORS' CONTRIBUTIONS

All authors made substantial contributions to the conception, design of the study, analysis and interpretation, composition of the manuscript, and final approval of the manuscript.

FINANCIAL SUPPORT AND SPONSORSHIP

None.

CONFLICTS OF INTEREST

All authors declared that there are no conflicts of interest.

CONSENT FOR PUBLICATION

The author declares that signed Informed Consents were obtained for publication of patient's images in this manuscript.

REFERENCES (16)

1. Bui CH, Seldin EB, Dodson TB. Types, frequencies, and risk factors for complications after third molar

- extraction. *J Oral Maxillofac Surg* **2003**;61(12):1379–89.
<https://doi.org/10.1016/j.joms.2003.04.001>
2. Rafetto LK, Synan W. Surgical management of third molars. *Atlas Oral Maxillofac Surg Clin North Am* **2012**;20(2):197–223.
<https://doi.org/10.1016/j.cxom.2012.07.002>
 3. Heifetz-Li JJ, Abdelsamie S. Pseudoaneurysm following “routine” third molar extraction: a case report and review of the literature. *Oral Maxillofac Surg Cases* **2022**;8(1):100249.
<https://doi.org/10.1016/j.omsc.2022.100249>
 4. Pukenas BA, Albuquerque FC, Pukenas MJ, et al. Novel endovascular treatment of enlarging facial artery pseudoaneurysm resulting from molar extraction: a case report. *J Oral Maxillofac Surg* **2012**;70(3):e185–e189.
<https://doi.org/10.1016/j.joms.2011.10.031>
 5. Stiefel MF, Park MS, McDougall CG, et al. Endovascular treatment of hemorrhagic alveolar artery pseudoaneurysm after tooth extraction: a case report. *J Oral Maxillofac Surg* **2010**;68(9):2325–8.
<https://doi.org/10.1016/j.joms.2009.12.011>
 6. Koga M, Toyofuku S, Aoki M, et al. Use of transcatheter arterial embolization to treat a case of massive arterial bleeding caused by a traumatic aneurysm developing after tooth extraction (Japanese). *Jpn J Oral Maxillofacial Surg* **2005**;51(1):63–6.
<https://doi.org/10.5794/JJOMS.51.63>
 7. De Lucas EM, Gutierrez A, Gonzalez Mandly A, et al. Life-threatening pseudo-aneurysm of the facial artery after dental extraction: successful treatment with emergent endovascular embolization. *Oral Surg Oral Med Oral Pathol Oral Radiol Endod* **2008**;106(1):129–32.
<https://doi.org/10.1016/j.tripleo.2007.09.031>
 8. Salgarelli A, Morana G, Beltramello A, Nocini PF. Pseudoaneurysm of the lingual artery: a case report. *J Oral Maxillofac Surg* **1997**;55(8):860–4.
[https://doi.org/10.1016/s0278-2391\(97\)90351-7](https://doi.org/10.1016/s0278-2391(97)90351-7)
 9. Marco de Lucas E, Gutiérrez A, González Mandly A, et al. Life-threatening pseudoaneurysm of the facial artery after dental extraction: successful treatment with emergent endovascular embolization. *Oral Surg Oral Med Oral Pathol Oral Radiol Endod* **2008**;106(1):129–32.
<https://doi.org/10.1016/j.tripleo.2007.09.031>
 10. Rayati F, Parsa H, Abed PF, Karagah T. Facial artery pseudoaneurysm following surgical removal of a mandibular molar. *J Oral Maxillofac Surg* **2010**;68(7):1683–5.
<https://doi.org/10.1016/j.joms.2009.07.078>
 11. Rawat SK, Singh D, Suresh Babu P, George R, Mongia P. Traumatic pseudoaneurysm: a life-threatening complication after surgical extraction of impacted maxillary third molar. *J Maxillofac Oral Surg* **2019**;18(1):57–60.
<https://doi.org/10.1007/s12663-018-1118-z>
 12. Bianchi B, Verazzani, A, Ferri A, et al. Endovascular embolization for the management of inferior alveolar artery bleeding after a third molar extraction: a case report. *Quintessence Int* **2016**;47(3):227–31.
<https://doi.org/10.3290/j.qi.a35261>
 13. Jo HW, Kim YS, Kang DH, et al. Pseudoaneurysm of the facial artery occurred after mandibular sagittal split ramus osteotomy. *Oral Maxillofac Surg* **2013**;17(2):151–4.
<https://doi.org/10.1007/s10006-012-0339-4>
 14. Sagara Y, Kiyosue H, Tanoue S, et al. Selective transarterial embolization with n-butyl-2-cyanoacrylate for the treatment of arterial hemorrhage after third molar extraction. *Neuroradiology* **2013**;55(6):725–32.
<https://doi.org/10.1007/s00234-013-1158-5>
 15. Wasson M, Ghodke B, Dillon JK. Exsanguinating hemorrhage following third molar extraction: report of a case and discussion of materials and methods in selective embolization. *J Oral Maxillofac Surg* **2012**;70(10):2271–5.
<https://doi.org/10.1016/j.joms.2012.03.003>
 16. Harrigan M, Deveikis J. Essential neurovascular anatomy. In: Harrigan M, Deveikis J, editors. Handbook of cerebrovascular disease and neurointerventional technique. 3rd edition. Cham, Switzerland: Springer International Publishing, **2018**. pp. 3–98.
<https://doi.org/10.1007/978-1-61779-946-4>

U-Impl[®]

SWITZERLAND



№ R3M 804 252 B2

Сертифікат відповідності
технічного регламенту
щодо медичних виробів



Switzerland Aarbergerstrasse 107A, CH-2502
Biel, Phone/Fax +41 323230188
info@u-impl.com
www.u-impl.com